COLUMBIA LIBRARIES OFFSITE
HEALTH SCIENCES STANDARD
HX00044822



RK501 W21
1920
X
Columbia University
in the City of New York
School of Dental and Oral Surgery

Reference Library

Digitized by the Internet Archive
in 2010 with funding from
Open Knowledge Commons

http://www.archive.org/details/americantextbook00ward

LIST OF CONTRIBUTORS.

BUNTING, RUSSELL W., D.D.Sc.
CAPON, WILLIAM A., D.D.S.
CONZETT, JOHN V., D.D.Sc.
COOLIDGE, EDGAR D., D.D.S.
HOPEWELL-SMITH, ARTHUR, Sc.D., M.R.C.S.
LYONS, CHALMERS J., D.D.Sc.
NOYES, FREDERICK B., B.A., D.D.S.
PRINZ, HERMANN, A.M., M.D., D.D.S.
THOMA, KURT H., D.M.D.
VOLLAND, ROSCOE H., M.D., D.D.S.
WARD, MARCUS L., D.D.Sc.

THE

AMERICAN TEXT-BOOK

OF

OPERATIVE DENTISTRY.

IN CONTRIBUTIONS BY EMINENT AUTHORITIES

EDITED BY

MARCUS L. WARD, D.D.Sc.

PROFESSOR OF DENTAL METALLURGY AND CROWN AND BRIDGE WORK, AND DEAN OF THE COLLEGE OF DENTAL SURGERY, UNIVERSITY OF MICHIGAN

FIFTH EDITION, THOROUGHLY REVISED

ILLUSTRATED WITH 762 ENGRAVINGS AND A COLORED PLATE

LEA & FEBIGER

PHILADELPHIA AND NEW YORK

1920

Dentistry 6-8101

RK50
W21
1920

COPYRIGHT
LEA & FEBIGER
1920

WITH THE CONSENT OF THE CONTRIBUTORS

THIS VOLUME

IS DEDICATED TO THOSE WHO HAVE AIDED IN THE DEVELOPMENT OF

OPERATIVE DENTISTRY

TO WHOM IT HAS NOT BEEN POSSIBLE TO GIVE CREDIT

PREFACE.

THE demand for a new edition of the *American Text-book of Operative Dentistry* has necessitated much more than a mere revision of the previous text. The work has been largely rewritten and the fifth edition is therefore practically a new book. Such a radical change has been rendered necessary by the rapid evolution which has taken place throughout the entire domain of the science and art of dentistry since the publication of the previous edition. The accumulation of new data, the investigation of the deeper problems of dental science, and the modification exerted by these factors upon the practice of dentistry have wrought changes that in certain departments are little less than revolutionary. So rapid and far-reaching in their effects are many of the changes which have taken place that the whole subject of operative dentistry has been and still is in a state of flux.

The mirroring of the progressive movement in operative dentistry will be evident in the plan as well as in the text of this work. The constantly growing demand for preventive dentistry has made it necessary to treat several subjects in a much more extensive manner than has been done in former editions in order that the undergraduate student may more intelligently comprehend preventive dentistry in its relation to all other operative procedures.

It is fully recognized that the scientific basis of many of the subjects which constitute preventive dentistry in its broadest sense is much more fully elaborated in the present work than would be justifiable in a treatise or text-book devoted exclusively to operative dentistry as an art; but as there appears to be a demand upon the part of students and practitioners for a volume furnishing a comprehensive view of the fundamental principles upon which alone an intelligent and rational practice may be based, the treatment of the subject of operative dentistry in the present work has been extended to include those principles.

Certain differences of opinion will be occasionally manifest in the work in the treatment of allied subjects by different authors. While such differences are, of course, not desirable, and while no conflict of opinion will be noticed with respect to established scientific principles,

it is manifestly impossible to secure unanimity upon subjects which have not as yet reached a stage of development entitling them to classification among the exact sciences, and which are subject to the variations in methods of procedure of different individuals. For example, it will be observed that all the contributors to this work have used the nomenclature advocated by Dr. G. V. Black in describing the teeth and their anatomy except the three who have written chapters who are associated with departments of general and comparative anatomy. The latter have used the words canine, premolar, etc., which appear to some general and comparative anatomists as the logical terms, while the former have adhered to the use of the terms cuspid and bicuspid, etc., in accordance with more common usage. As dentistry continues to develop as a branch of medicine, it appears possible that the opinion of the anatomist will prevail and some of the terms now generally used by the dental profession to describe the teeth, and which seem to have been useful in the development of operative dentistry, will be displaced by terms more accordant with the fundamental subjects of general and comparative anatomy. Such differences of opinion are not at present reconcilable, and cannot be, until the bar of professional judgment has decided which school of thought is based upon the better observation and experience.

The progress in the development of the fundamental principles and technic of correcting mal-occlusion has been so rapid that orthodontia has become a specialty with a scope so broad that it has seemed wise to include in this work only the principles of orthodontia that a general practitioner should know in order to enable him to advise intelligently those who are in his care. In submitting this work to the critical consideration of former contributors to the subject, fellow-teachers and students, it is the desire of the editor to do so with the highest respect for orthodontia as a progressive and preventive measure—his only reason for curtailing the subject in this volume being inability to allow a sufficient space for an appropriate presentation of the subject in its present state of development.

The progressive movement in operative dentistry is still further reflected in the chapter on roentgen diagnosis. A study of the advances which have taken place in the field of roentgenology reveals, besides important additions to our knowledge, a vastly more important advance manifested in a better understanding of the value of the roentgenogram in determining pathologic conditions, the result being more rational practice.

Chapters XII and XIV are devoted to an equally progressive development in the discovery of new substitutes for cocain which are less toxic and equally effective in the removal of pain. With marked

improvement in the technic of handling these new products local anesthesia has become much more generally used by practitioners of dentistry than before. It has been recognized that local anesthesia was more desirable than any other anesthetic in many respects when the operation was to be performed in the dental office where it was difficult to prepare the patient properly and equally difficult to protect him after the operation. Not until the advent of the new product novocain or procain, together with improved technic, however, could local anesthesia be used so satisfactorily for so many operations, especially the extraction of teeth.

The recent attention given to work in cavity preparation by studying the location and direction of progress of caries and the extension of the cavity walls into relatively immune areas for caries prevention has seemed to warrant a somewhat lengthy consideration of this subject, first, because in itself, it is a preventive measure, and second, because it has been regarded fundamental to all work which involves restorations for lost tooth tissue.

To have made this work in true monographic style with references to all of the authors of every statement would have resulted in a book of impracticable size and form. The policy that has been adopted provides, as a rule, for reference to authorities for facts that have not received general recognition.

The editor takes this occasion to express his deep sense of appreciation of the uniform courtesy and spirit of helpfulness which have characterized the attitude of all his collaborators in this work, and their willingness to sacrifice personal interests to the thoroughness and accuracy of the work as a whole. To express adequately my appreciation of the generous support accorded by my colleagues, Drs. Bunting and Lyons and Miss Nita Faught and Miss Hazel V. Kramer in the preparation of this work is not possible. Second, only to the contributors, should these persons who have been intimately associated with me, receive credit for any help that this work may be to the progress of dentistry.

MARCUS L. WARD.

LIST OF CONTRIBUTORS.

RUSSELL W. BUNTING, D.D.Sc.,
Professor of Dental Histology and Pathology, University of Michigan.

WILLIAM A. CAPON, D.D.S.,
Assistant Professor of Dental Ceramics, The Thomas W. Evans Museum and Dental Institute, School of Dentistry, University of Pennsylvania.

JOHN V. CONZETT, D.D.Sc.,
Author of Many Valuable Articles on Operative Dentistry.

EDGAR D. COOLIDGE, D.D.S.,
Professor and Head of the Department of Materia Medica and Therapeutics, University of Illinois.

ARTHUR HOPEWELL-SMITH, Sc.D., L.D.S., M.R.C.S., L.R.C.P.,
Professor of Dental Histology, Histopathology and Comparative Odontology, The Thomas W. Evans Museum and Dental Institute, School of Dentistry, University of Pennsylvania.

CHALMERS J. LYONS, D.D.Sc.,
Professor of Oral Surgery and Consulting Dental Surgeon to the University Hospital, University of Michigan.

FREDERICK B. NOYES, B.A., D.D.S.,
Professor and Head of the Department of Orthodontia and Dental Histology, University of Illinois.

HERMANN PRINZ, A.M., M.D., D.D.S.,
Professor of Materia Medica and Therapeutics, The Thomas W. Evans Museum and Dental Institute, School of Dentistry, University of Pennsylvania.

KURT H. THOMA, D.M.D.,
Lecturer on Oral Histology and Pathology, Harvard University.

ROSCOE H. VOLLAND, M.D., D.D.S.,
Professor of Oral Pathology and Operative Technic, Iowa University.

MARCUS L. WARD, D.D.Sc.,
Professor of Dental Metallurgy and Crown and Bridge Work, Dean, College of Dental Surgery, University of Michigan.

CONTENTS.

CHAPTER I.

THE ANATOMY OF THE TEETH OF MAN 17
By Arthur Hopewell-Smith, Sc.D., L.D.S., M.R.C.S., L.R.C.P.

CHAPTER II.

DENTAL HISTOLOGY WITH REFERENCE TO OPERATIVE DENTISTRY 54
By Frederick B. Noyes, B.A., D.D.S.

CHAPTER III.

PREVENTIVE DENTISTRY 122
By Russell W. Bunting, D.D.Sc.

CHAPTER IV.

INSTRUMENTATION, CAVITY PREPARATION, AND THE FILLING OF TEETH WITH GOLD FOIL, GOLD INLAYS, AMALGAM, CEMENTS AND GUTTA-PERCHA 179
By John V. Conzett, D.D.Sc., and Roscoe H. Volland, M.D., D.D.S.

CHAPTER V.

GOLD INLAYS AS BRIDGE ATTACHMENTS 284
By Marcus L. Ward, D.D.Sc.

CHAPTER VI.

HIGH FUSING PORCELAIN INLAYS 299
By William A. Capon, D.D.S.

CHAPTER VII.

PROPERTIES OF FILLING MATERIALS 339
By Marcus L. Ward, D.D.Sc.

CHAPTER VIII.

THERAPEUTIC PROCEDURES IN THE TREATMENT OF INFECTED ROOT CANALS 411
By Herman Prinz, A.M., M.D., D.D.S.

CHAPTER IX.

THE PREPARATION AND FILLING OF ROOT CANALS . . . 431
By Edgar D. Coolidge, D.D.S.

CHAPTER X.

PATHOLOGY AND TREATMENT OF HYPERSENSITIVE DENTIN 454
By Hermann Prinz, A.M., M.D., D.D.S.

CHAPTER XI.

DISCOLORED TEETH AND THEIR TREATMENT 467
By Hermann Prinz, A.M., M.D., D.D.S.

CHAPTER XII.

LOCAL ANESTHESIA 498
By Hermann Prinz, A.M., M.D., D.D.S.

CHAPTER XIII.

PYORRHEA ALVEOLARIS 527
By Russell W. Bunting, D.D.Sc.

CHAPTER XIV.

EXTRACTION OF TEETH, AND OTHER SURGICAL PROCEDURES 583
By Chalmers J. Lyons, D.D.Sc.

CHAPTER XV.

PRINCIPLES OF ORTHODONTIA FOR THE GENERAL PRACTITIONER 653
By Frederick B. Noyes, B.A., D.D.S.

CHAPTER XVI.

ROENTGEN DIAGNOSIS IN DENTISTRY 675
By Kurt H. Thoma, D.M.D.

OPERATIVE DENTISTRY.

CHAPTER I.

THE ANATOMY OF THE TEETH OF MAN.

By ARTHUR HOPEWELL-SMITH, Sc.D., L.R.C.P., M.R.C.S., L.D.S.

Introduction.—In determining the nature of his contribution to this volume the author has been actuated by the main conception of presenting the subject with due regard to the scope and character of the entire work, to the average requirements of the general reader, and to the limitations of allotted space. It is obvious that for a fuller treatment of the subject text-books especially dealing with dental anatomy should be consulted. Complete discussions of many of its branches are not germane to the consideration of special technical methods of immediate interest to the practitioner, important though they undoubtedly are to the anatomist, pathologist and surgeon.

Consequently, this chapter includes brief descriptions of the anatomy of the dental organs which should influence daily clinical work, and omits much of purely academic interest. The facts of dental histology and histogenesis, the problems of dental physiology, and the resultant principles of dental pathology cannot be here set forth: they must be sought for elsewhere.

At the same time it must be noted that the earnest, progressive seeker after truth should not be contented with what is here so concisely detailed. Many recent advances have been made; but many debated and debatable side issues increasingly demand attention. Many old theories have been, and will still continue to be relegated to the past, and the newer teachings of anatomy, medicine, surgery and pathology employed and applied to the study of the science and art of dental surgery.

The reader will be well advised, therefore, to refer to modern text-books, written for the specific purpose of providing an enlarged, sure, clarified, common-sense and scientific basis for the building up of the

higher degrees of knowledge and learning demanded today of the practitioner of dental surgery.

The use of a stricter nomenclature, the appeal of a closer correlation of science and practice, the recognition of the fact that the teeth are organs of the body, acting *in suis modibus* as part controllers of its well-being, should be strongly insisted upon, if advancement in the interpretation of symptoms and the diagnosis and treatment of diseases of the oral cavity is desired, as it is certainly desirable.

In view of the foregoing the subject may be shortly considered under the following headings: (I) Definitions. (II) Numeration. (III) Morphology. (IV) Articulation. (V) Descriptive Gross Anatomy. (VI) Relationships.

I. DEFINITIONS.

A. Collective.—Teeth may be defined as hard bodies generally* found in the mouth, developed from the ectoderm and mesoderm, articulated to the skeleton but not forming part of it, whose major general functions are concerned with the comminution of food.

B. Individual.—The teeth of man, as of all the *primates*, are classified as incisors, canines, premolars and molars—so-called from their predominant anatomic and physiologic characteristics, *viz.*, those used for sectorial purposes, those greatly developed in the *canidæ* (dogs, wolves, etc.), those occupying a position in front of the molars, and those used after the fashion of a flat millstone for grinding food.

The *maxillary incisors* in each half of each jaw are two in number, in articulation with the premaxillary bones, that is, the bones which intervene between the right and left premaxillary suture. They are called the first and second incisors. The older terminology—"centrals" and "laterals"—is incorrect for several reasons. The words have no specific meaning. The so-called "central" is central to no anatomic entity. It occupies a position either to the right or to the left of the interpremaxillary suture—which corresponds to the midline of the jaws and face—on the *endognathion*,[1] and is probably the homologue of the first incisor of mammalian dentitions. The so-called "lateral" similarly may assume a position in the dental arch on either side of the labial or palatal surfaces of the first incisor, appears to be the homologue of the second incisor in the mammalian dentitions, and is in articulation with the *mesognathion*.[1] The *mandibular incisors* are those teeth attached to the lower jaw which, in occlusion, correspond directly with the upper teeth.

* Teeth may also be found in the nasal fossæ,[10] sigmoid notch of the mandible,[12] ovarian teratomata,[4] and testes,[5] and attached to the temporal bone[6] and external auditory meatus.[7]

The *maxillary canine* is that tooth—no matter what its shape or size—which is in articulation with the maxillary bone (the *exognathion*),[1] in that region immediately beyond the premaxillary suture. The *mandibular canine* is that tooth in the mandible which in occlusion passes in front of its maxillary congener. In the *carnivora*, for instance, a space exists between the maxillary incisors and canine for the purposes of the accommodation of this tooth. This space is termed a "diastema," literally meaning "an interval." It is occasionally found in man as a normal interruption to the regularity of the dental arch. In the typically herbivorous animal there are no incisors or canines in the upper jaw. The front portion of the mandible, however, carries four teeth on each side of the suture at the *symphysis menti*. Of these the fourth or outermost, is small and incisiform in shape. It is, nevertheless, a canine, its period of development and eruption being considerably later than that of the three incisors, it being impossible for mammals (except the polyprotodont marsupials) normally to possess more than three incisors on each side of the middle line of the face.

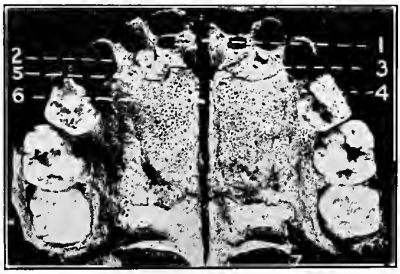

FIG. 1.—Palatal aspect of maxillæ of child aged five and a half years, showing various sutures. *1*, interpremaxillary suture; *2*, *endognathion; 3*, *mesognathion; 4*, *exognathion; 5*, premaxillary suture; *6*, median maxillary suture.

The *premolars* are two in number on either side of each jaw. They are so-called because they are situated immediately in front of the permanent molars, and in eruption have displaced two predecessors, *viz.*, the deciduous molars. They are termed the first and second premolars, though they probably represent the third and fourth premolars of the typical mammalian dentition. These teeth have been generally known as "bicuspids," But recent trend of thought, determined by a careful examination of many specimens in the mouth of man, and by a study of the anatomic relationships of man to the *primates*, show that the term is a misnomer, for the following reasons: the crowns of many maxillary canines possess a prominent cusp on their lingual aspects. Incisors frequently have a well-defined prominent lingual tubercle. In both instances this is an elevation of the internal

part of the cingulum. They are, therefore, bicuspidate. Further, the first mandibular premolar has often the lingual cusp so ill-defined and underdeveloped that it appears merely as a raised tubercle and cannot properly be called a cusp. The second mandibular premolar is frequently tricuspidate, and may on occasion be multi-tuberculate. These objections cannot be raised, however, if the teeth are considered as the homologues of the mammalian dentition.

The *permanent molars* are three in number in each half of each jaw, erupt in typical diphyodonts behind the milk molars, and have no predecessors. The existence of a fourth molar is impossible; no typical mammal possesses such a tooth. The "fourth molar" of some authors[8] is a more or less molariform supernumerary tooth. The *deciduous molars* are those teeth which have been displaced during the growth and eruption of the subjacent premolars. They are correctly termed the first, second and third molars in the first instance and the first and second molars in the second instance.

II. NUMERATION.

There is a marked reduction in the number of the teeth of man compared with that of the typical mammalian dentition, as seen, for example, in the mole, young horse and pig. Here the full dental formula gives on one side of either jaw three incisors, a canine, four premolars and three molars. Adopting the usual symbols this may be represented graphically:

$\mathrm{I}\ \frac{3}{3}$, $\mathrm{C}\ \frac{1}{1}$, $\mathrm{Pm}\ \frac{4}{4}$, $\mathrm{M},\ \frac{3}{3} = 22$ or $\times\ 2 = 44$ in the entire oral cavity. The normal human permanent dentition is denominationally and numerically expressed thus:

$$1\ \tfrac{2}{2},\ \mathrm{C}\ \tfrac{1}{1},\ \mathrm{Pm}\ \tfrac{2}{2},\ \mathrm{M}\ \tfrac{3}{3} = 16, \text{ or } \times\ 2 = 32;$$

and the deciduous series:

$$\mathrm{i}\ \tfrac{2}{2},\ \mathrm{c}\ \tfrac{1}{1},\ \mathrm{m}\ \tfrac{2}{2} = 10, \text{ or } \times\ 2 = 20.$$

Reasons for the Departure from the Typical Mammalian Formula.—Examination of the preceding formulæ shows that man has twelve permanent teeth less than the typical number—four incisors and eight premolars. The factors in the production of this condition are probably[26] as follows:

1. Incomplete evolution of certain teeth which are practically functionless, such as the third molars, following the rule of degeneracy of other organs of the body, as exemplified, for instance, in the vermiform appendix and the *plica semilunaris*, which are important in the rabbit, and as the third eyelid of birds and lizards, etc.

2. The progressive enlargement of the most actively functional organs, as typified in the comparatively great size of the fourth premolar in the *felidæ*, the dynamic effects of unusually great muscular action in the zygomatic region; and

FIG. 2.—Left side of jaws of man with permanent teeth *in situ*.

3. The shortening of the length of the entire jaw of man in comparison with that of many of the mammalian series of animals. This reduction in the antero-posterior direction results in the crowding out of teeth which, as organs for the comminution of food, can best be spared. While the general size and shape of the teeth of modern man have undergone little change during his evolution, his jaws have. There is less room in his mouth for the attachment of his teeth than there was in the more spacious oral cavity of his prehistoric simian ancestor.

III. MORPHOLOGY.

In attempting to affix the conception of a geometrical basis to any consideration of the shapes of the organs of man, it must be remembered that, in spite of the necessity, when describing such organs, of adopting mathematical ideals, it was probably never the intention on the part of nature to construct an architectural type which would be completely subservient to geometrical pattern or design. If it were so, then of

all the organs of the body his teeth lend themselves most to this treatment; more so than his palate or his dental arches.

It is usual, however, to describe the shapes of the teeth as being dependent, especially as far as the roots are concerned, on the morphological variations of that geometrical figure known as a cone. The roots of human teeth are conical, thoroughly adapted to their unique articulation with the alveolar processes of the jaws. Roots may be cylindrical, flattened laterally, straight, curved or twisted.

With regard to the evolution of the pattern of their crowns three schools of thought may be cited as holding concurrent views, varying chiefly by reason of the differences of the viewpoint of their genesis and development.

Of these the simpler is the theory of (A) the fusionists,[20 21 25 27] who hold that in consequence of the decrease in shape and size of the jaws, haplodont (cone-shaped) teeth may exist *per se*, or, becoming fused, may produce a molariform pattern. (B) The trituberculists[11 23] have advanced the theory that, during the course of evolution from the primitive type, haplodont teeth may develop on the chief cone, subsidiary cusps in anterior, posterior and lateral directions. A further extension of the tubercular theory may be called (C) the multitubercular theory,[14]

A discussion as to the merits of, and objections to, these views is not relevant to this article. It may, however, suffice to say that probably the crowns of the human incisors are merely flattened cones, that the canine largely retains its primitive shape, while the molariform crowns of the three posterior teeth are chiefly due to a longitudinal fusion of original haplodont cones. In the case of the premolars it is believed that the internal cusp is a modification of the cingulum, in which an elevation of its inner part produces a tubercle of varying proportions.

The reasons for the diversities in shape of the crowns of teeth may be ascribed to the operations of the laws of adaptive modification, which demonstrate that, following the deterioration and suppression of disused and unwanted organs and the more complete morphological development of really necessary and much used organs, certain slow, progressive modifications from few and simple forms occur. Of all the teeth the third maxillary molar and probably the second maxillary incisor are the least used as mechanical agents. These teeth, particularly the former, have a tendency to undergo suppression and to evince in their coronal patterns traces of retrogressive and unstable characteristics. In short: the law which governs the fixed morphological features of the teeth is founded upon the requirements of nature in connection with the provision of an organ or of several

organs most suitably designed and constructed to accomplish the very definite purpose for which they were intended.

Succession.—Man, like most animals, is a diphyodont animal, *i. e.*, he possesses two sets of teeth, the deciduous or milk, and the permanent series. A third set, occasionally spoken of by the unlearned, cannot exist. Vestigial dental remains are exceptionally found in the human jaws and are believed by some evolutionists[21] to point to a reversion to a reptilian dentition in which a polyphyodont condition obtains.

IV. ARTICULATION.

Teeth are attached to the jaws by means of a unique joint or articulation, termed "gomphosis," exactly imitating the arrangement of a nail or peg when received into a hole or mortise in a piece of wood; hence the term. Gomphosis is a variety of synarthrosis[15 24]—a fixed, immovable joint, as exemplified in the methods of union of the bones of the cranium. It is limited to the teeth. The socket containing the cone-shaped root is termed the alveolus, and those portions of the jaws which support the sockets are called the alveolar processes. The teeth are immovably held in position through the cementum on the inner side by a strong fibrous attachment to the *lamina dura*—a thin sheet of compact bone surrounding their alveolar sockets on the outer side—through the intervention of a dense, firm layer of connective tissue called the alveolo-dental periosteum.

Just as it may be affirmed without fear of refutation that the masticatory organs of modern men are degenerate and unfitted to perform properly their functions throughout the lifetime of the individual, so may it be stated that their sockets are equally unsuited to their desired requirements. It is the rule that they should atrophy and disappear with the incidence of age.

The terminal margins of the sockets of the teeth of man are of a degenerate character for the following reasons:[17]

1. Absence of muscular attachment. No muscles or parts of muscles arise from or are inserted into the alveolar processes of the jaws, except a few stray fibers of the buccinator in the neighborhood of the maxillary molars. The fundamental function of bone is therefore entirely absent in this situation.

2. The unique character of the structure of the bone does not completely conform either to the compact or cancellous varieties.

3. Inadequacy of the blood supply tends to produce anemia of the parts, and this, when long continued, is likely to lead to atrophy.

4. Physiologic resistance to disease and nutritional equilibrium are

easily and readily lowered and disturbed by the extreme tenuity and other histologic features of the external and internal alveolar plates.

5. There is a modification of the usual function of bones, which, in this particular instance, is only required to support and afford attachment to the roots of teeth.

V. DESCRIPTIVE GROSS ANATOMY.

A. The Permanent Series.—1. **The Maxillary Teeth.**—THE FIRST INCISOR.—In articulation with the *endognathion* and placed on either side of the intermaxillary suture, which corresponds to the midline of the jaw and face, this tooth with its congener of the opposite side forms one of the most striking objects of the dental series. The graceful size and shape of its crown make it of great importance in its relationship to the other teeth and to the æsthetic bearing it has on the features generally.

It is usually placed in close proximity to its fellow in the other maxilla, but frequently in early life a space exists between the two first incisors. This is due to an excessive development and consequent enlargement of the bone of the alveolar sockets of the teeth, particularly at the side nearest the suture, a hypertrophy probably induced and continued by the presence and action of a large *frenum labii*, which is inserted into the soft tissues of the labial aspect of the alveolar process.

The *crown* has four surfaces, six borders, and two angles, named respectively (1) labial, or vestibular, or external, or anterior, (2) lingual, caval, internal, or posterior, (3) mesial[1] and (4) distal; incisive edge or inferior border, gingival edge or superior border, and mesio-anterior and mesio-posterior and disto-anterior and disto-posterior borders. The angles are mesial and distal.

Surfaces.—The *labial* is the largest of all the surfaces. It is markedly convex from above downward and from side to side. Its upper border is narrow and rounder than the lower, thus making it triangular in outline. Smooth usually, it may be traversed by numerous horizontal ridges or pits or depressions, and is frequently discolored and pig-

[1] The terms "mesial" and "distal," common in clinical parlance, are not strictly anatomically correct. It is the rule in general anatomy to designate that part or surface of a long bone nearest to the larger joint as "proximal," that away from the large joint "distal." Thus, in the femur the part of the bone at the hip is called the "proximal extremity," that at the knee the "distal extremity." So it should be with the teeth. Owing to the shape of the dental arches the mesial surfaces of the incisors face in exactly the same direction—toward the midline—as do the lingual surfaces of the premolars and molars, their distal surfaces as the buccal surfaces of these teeth. It is more in accordance with anatomic usage to consider the so-called "mesial surface," *i. e.*, the part further away from the joint, viz., the temporo-mandibular articulation—as the "distal surface," and the so-called "distal" as the "proximal surface." For the convenience of the reader, however, the usual clinical terms will be here adopted.

mented as the result of either congenital or acquired conditions. Occasionally a median vertical ridge may divide the surface into two unequal parts.

The *lingual* surface is remarkable for its pronounced double concavities. Smaller than the above, with thickened and elevated boundaries, it is triangular in shape, the base being at the incisive edge. A diminutive cusp or tubercle frequently appears at the gingival margin. It represents an elevation of the cingulum.

On the *mesial* aspect the crown is slightly convex in both vertical and lateral directions. It is enclosed by the rounded mesio-anterior and mesio-posterior borders, which in many instances are scarcely elevated from the general level of the surface and therefore indistinguishable to any extent. The upper borders follow more or less closely the outline of the surface itself. Of its two parts, that directed to the external side is shorter than that directed to the internal side.

The *distal* surface is more convex than the former, a little larger generally, as a consequence of the superior border not curving downward so markedly. The whole of this doubly-convex surface passes into the disto-anterior and disto-posterior borders without any perceptible interruption.

The *incisive* edge is blunt, slightly convex and slightly thicker toward the mesial side. Three tubercles may be present here at birth.

The *gingival* edge varies over the different aspects of the crown. On the labial side it forms part of the circumference of a circle. Lingually it is considerably flattened—nearly in a straight line, mesially it dips down some considerable distance near the middle portion toward the mesial angle, and distally it is less curved than in the last-named situation.

The *mesio-anterior, mesio-posterior, disto-anterior* and *disto-posterior* borders are all rounded and smooth, and in the majority of instances are not elevated over and above the surfaces which they enclose.

Of the *angles,* the mesial is nearly a right angle, the distal is obtuse.

The *neck* of the tooth is clearly defined, on account of the prominence of the free edge of enamel and its relationship with the cementum above. It does not lie in the same horizontal plane, but as it passes around the tooth it is elevated or depressed, according to the situation. Thus labially and lingually it is very much raised, distally and mesially it is considerably depressed toward the incisive border of the crown.

The *root* is normally almost a cylindrical cone and the alveolar socket also necessarily cylindrical. Usually straight, it may be deflected slightly toward the middle line. Flattened laterally, it becomes at times somewhat triangular in outline. It may rarely be bifurcated, the second root being placed on the lingual side.

The *pulp cavity* generally follows in shape the outline of the tooth itself, *viz.*, two cones of dissimilar size placed together at their bases. Of these the radicular portion is considerably the larger. Viewed in a mesio-distal direction the lower part of the pulp cavity is the broadest, and is divided into three cornua, of which the central—the smallest—disappears at about the fifteenth year. The root canal is tube-like, narrow and straight.

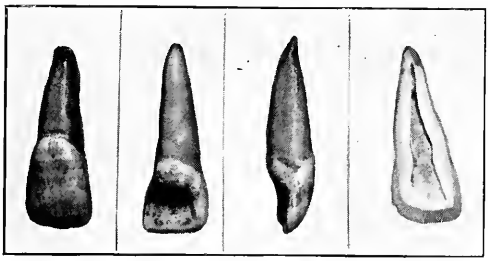

A *B* *C* *D*

Fig. 3.—Maxillary first incisor. *A*, labial surface; *B*, lingual surface; *C*, mesial surface; *D*, mesio-distal section.

The *calcification* of this tooth begins during the first year after birth;[9] its apical foramen forms about the tenth to eleventh years,[9] and it is erupted at the seventh year and ninth month.[19]

Length, approximately 25 mm.;[18] *width*, 9 mm.

Identification, from a number of specimens isolated from the mouth, can be effected by placing the tooth in a horizontal position, with convex coronal surface upward and root away from the observer, and noting the more acute angle of the incisive edge. This points to the side to which the tooth belongs.

Methods of normal *occlusion*. This tooth completely overlaps the upper sixth of the labial surfaces of the first and second mandibular incisors.

The Second Incisor.—This tooth, the second from the midline of the face, in articulation with the *mesognathion*, is situated on the distal side of the first incisor. It is frequently suppressed. It simulates, though on a smaller scale, the first incisor in its main architectural features.

Similarly to the first incisor the *crown* has four surfaces, six borders and two angles.

Of all the *surfaces* the *labial* is the largest, and differs from that of the other incisor in the more pronounced diminution in size as it approaches the gingival margin. Hence the whole aspect is very triangular in outline. Markedly convex in both directions it assumes

a transitional type of shape between the flatter first incisor and the more conical canine. Of the two convexities, that from side to side is the more appreciable. Its superficial markings are not so well defined as in the other incisor.

Lingually the appearance of the crown follows that of the first incisor, save that it is smaller in every dimension. Its concavities are greater. A slight vertical ridge may be formed at times on this surface, separating two deep concavities. The internal cingulum may be modified into a cusp.

The *mesial* surface is slightly larger than the distal. It is flattened from side to side and slightly convex from above downward. It passes imperceptibly into the mesio-anterior and mesio-posterior borders.

The *distal* surface is much more convex in both directions than the former. It is smaller in area, being vertically shorter and encroached upon by the disto-anterior and disto-posterior borders.

The *incisive* edge is broad and round and does not present the blade-like appearance as in the first incisor. It is short in a mesio-distal direction, largely through the shape of the distal angle. Three tubercles may frequently be seen.

The *gingival* edge is very narrow compared with the former, particularly on its labial aspect. It forms the arc of a much smaller circle than in the first incisor. The cervical edge of enamel in this locality is not very pronounced.

Of the *borders,* all are considerably rounded, flat and broad, so much so that it is often impossible to define the actual limits of surface and border. This condition is more obvious on the distal than on the mesial side.

The *angles* are obtuse, particularly the distal.

The *neck* copies that of the first incisor, but the undulations are less marked and the constriction less severe.

The Root.—Cone-shaped and flattened laterally the labial and lingual sides of the root are broader than the other two surfaces. Of these two the lingual is the narrower. The root is generally straight but may be deflected toward the distal side, and may be bifurcated. When *in situ* it has a tendency to be directed toward the midline of the palate. Hence it follows that a dento-alveolar abscess resulting from a septic pulp points over the palate in the *cavum oris.*

The Pulp Cavity.—Compared with the general size of the tooth itself the pulp cavity is the largest of all; compared with that of the first incisor it is a little smaller in every dimension. Two cornua exist, as in the last-named tooth; the one on the mesial side being frequently the largest. The root canal is a narrow tube; an accessory root canal is a fairly common abnormality.

Calcification begins during the first twelve months, finishes with the formation of the apical foramen at the tenth to the eleventh year, and the tooth is erupted at about the third year and ninth month.

It *measures* approximately 23 by 6.5 mm. in greatest length and diameter.

Identify similarly to the first incisor.

Occlusion.—The lingual surface occludes with the upper sixth of half the labial surfaces of the mandibular second incisor and canine.

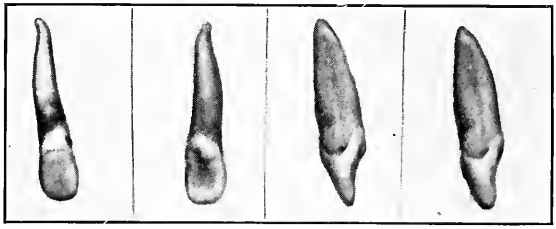

A *B* *C* *D*

FIG. 4.—Maxillary second incisor. *A*, labial surface; *B*, lingual surface; *C*, mesial surface; *D*, distal surface.

THE CANINE.—This important tooth is the third from the midline of the face, its socket occupying the alveolar process of the *exognathion*. Situated at the angle of the alveolar processes of the upper jaw, in possession of a large root, and producing the canine eminence behind the canine fossa on the facial surface of the maxillary bone, the tooth is remarkable for its size, strength and general appearance. It is by far the largest tooth in the anterior part of the dental series.

The *crown*, a somewhat flattened cone, has four surfaces, six borders and two angles.

The *labial* surface, the largest of the four, is slightly convex from above downward and more so from side to side. It forms the rough outline of a pentagon, having one side above at the gingival margin, a second and third below at the cutting edge, and in front and behind a fourth and a fifth, joining the extremities of the others. Frequently this surface is divided by a median ridge into two unequal parts, of which the anterior is the smaller.

On the *lingual* surface, which presents the outline of a five-sided figure, are two deep depressions separated by a vertical ridge, which terminates below at the extremity of the cusp, and above very often in an accessory cusp of varying size, which, like that of the first incisor, represents an elevation of the internal cingulum. Of these concavities that on the distal side is the larger.

The *mesial* surface is flattened and smaller in extent than that of

the opposite side through the undue encroachment of the root at the cervical margin. It is flat, triangular, with an indented base and broad apex, and is generally on the same level as that of the root. Hence the upper edge of enamel is very slightly elevated.

Distally a unique characteristic of the canine appears. This is a prominence, not amounting to a definite tubercle or cusp, large in extent, and situated at the lower part of the surface at the junction of what would represent in the incisors the disto-anterior and disto-posterior borders. The upper border of this surface is almost on a horizontal plane. The canine does not usually possess any well-defined borders. All its surfaces are more or less rounded and smooth.

Of the *angles* the distal is the more obtuse. At times they may be raised into prominences which give the appearance of a tricuspidate tooth.

The *neck* forms a gentle undulating line which, labially, is part of a flattened arc of a circle, and extends downward slightly on the mesial and distal aspects, ending lingually in a nearly horizontal direction.

The *root* is an extremely elongated, flattened cone, of which the mesial aspect is the broader and the lingual the narrower in diameter. Two vertical grooves can usually be noted, that on the mesial side being the deeper. The root, when unduly lengthy, may communicate with the maxillary sinus.

The *pulp cavity* extends into the coronal region in the form of one cornu. In the crown it is almost triangular in outline; at the neck nearly cylindrical; at the junction of the upper two-thirds and the lower third compressed from side to side; and at the apex cylindrical.

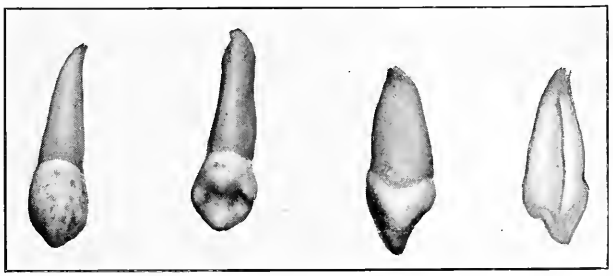

A *B* *C* *D*

FIG. 5.—Maxillary canine. *A*, labial surface; *B*, lingual surface; *C*, mesial surface; *D*, labio-lingual section.

Calcification begins during the third year and is completed from the twelfth to the thirteenth. Eruption occurs at about the tenth year and

sixth month, thus preceding the complete formation of the apical foramen.

Average *length* and *width* 27 mm. and 8 mm.

Identification can be effected by the same means as for the incisors. The disto-coronal prominence points to the side opposite to that to which the tooth belongs.

Occlusion.—By its lingual surface it occludes with the labial aspect of the corresponding tooth in the lower jaw and the anterior part of the upper portion of the labial surface of the mandibular first premolar.

THE FIRST PREMOLAR.—Fourth from the front this tooth in man probably represents the third premolar of the typical mammalian dentition, thus following the general rule that when premolars are absent from the dentition of an animal those nearest the canine are the most likely to be suppressed. The definition of the premolars already given suffices to indicate that these teeth are situated in the jaw in front of the permanent molars and that they have displaced deciduous molariform predecessors. It should further be noted, as will presently appear, that a second mandibular premolar may present many cusps or tubercles, and cannot, therefore, be strictly called a "bicuspid" at all.

This tooth may be in relation with the antrum of Highmore in its facial portion.

Totally unlike the preceding, the first premolar possesses a crown with five surfaces, a neck, and a root or roots.

The *crown* presents for examination a labial, lingual, mesial, distal and a morsal or occluding surface.

The shape of the *labial* surface in typical examples combines the mathematical outlines of the pointed cutting edge of the canine and the constricted neck of the second incisor. It is slightly convex from above downward and more so from side to side. The median ridge and lateral vertical grooves commonly seen on the corresponding surface of the canine are often here entirely absent, the whole area being quite smooth. The general outline resembles somewhat that of a diamond, with the upper angle flattened.

A great resemblance exists between the *lingual* surface and the former, the main difference being that its superficies is less in all directions, and the upper angle of the diamond is flatter. No grooves or ridges normally exist.

The quadrilateral face of the *mesial* surface is notable for the thickening of its lower border, which in some cases may amount almost to a unique elevation of the cingulum. It is slightly concave vertically and in a labio-lingual direction.

The *distal* surface is similar to the above, but instead of being slightly

concave it is somewhat convex. It is rather larger in area, with rounded borders.

The *morsal* or occluding surface is roughly trapezoidal in outline. Its mesio-distal diameter is considerably less than its other diameters. The labial border of the figure is the largest of the four, the next largest being the posterior or distal border. The surface is not plain, but is divided topographically into elevations or cusps, depressions or sulci or fissures. Almost in the center of this surface extends a short, deep sulcus which runs forward nearly parallel with the intermaxillary suture. At its anterior (mesial) extremity it runs at an angle outward and forward; at its posterior (distal) end it runs at a more obtuse angle outward and backward. Frequently in the latter situation it bifurcates. The chief cusp is on the external part of this surface. It is very large and round on its morsal aspect, sharp and pyramidal on its labial aspect. It is separated by the antero-posterior sulcus from the smaller, blunter internal or lingual cusp. In well-formed specimens the whole of this cusp is round, but in many examples the outermost cusp is apparently formed by the union of four ridges of enamel, one passing forward to the outer mesial angle, another backward to the outer distal angle, another toward the center of the surface, and another uniting with a possibly existing vertical ridge on the labial or buccal surface of the crown. If the sulcus bifurcates at one or either extremity one or two additional eminences of enamel are produced. It is therefore possible on the lingual side of this surface for two additional cusps to be observed.

The *neck* is placed in a nearly horizontal plane, slight undulations occurring on all four faces of the root.

The *root* or *roots*. In about 60 per cent. of cases the first premolar is birooted. In single-rooted specimens, both very flattened surfaces usually present a more or less deep groove, that on the mesial being greater than that on the other side. If these grooves attain any great depth during development the tooth then becomes bifid and birooted, each portion containing a typically-shaped pulp canal. These roots may be quite distinct throughout their whole extent, but generally they are united through two-thirds of their length. Occasionally one lingual and two buccal roots are found. This is probably an expression of atavism. The apical region is frequently divergent and deflected backward.

In the *pulp cavity*, which closely conforms to the shape of the crown, the cornu found on the buccal side is the more extensive, penetrating far into the cusp; if two pulp canals exist the division from the common pulp chamber in the crown occurs at the cervical region. The greatest diameter of the pulp cavity is in the labio-lingual direction.

Calcification commences at about the fourth year, and the apical foramen becomes formed between the eleventh and twelfth. Eruption takes place at about the ninth year, or the ninth year and sixth month.

Length, 20 mm.; *width,* 6.5 mm.

Identification.—The side of the mouth to which the tooth belongs is indicated by the deeper of the two grooves of the root, when the tooth is placed with its crown toward the observer and its larger external cusp also in the same direction.

Occlusion occurs by means of the lingual cusps of the crown coming into contact with the distal ridges of the cusp of the mandibular first premolar, and the mesial ridges of both cusps of the second premolar.

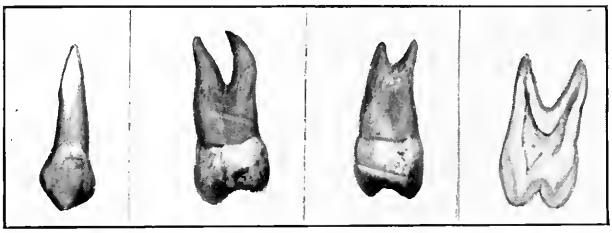

A *B* *C* *D*

FIG. 6.—Maxillary first premolar. *A*, buccal surface; *B*, distal surface; *C*, mesial surface; *D*, bucco-lingual section.

THE SECOND PREMOLAR.—The homologue of the fourth premolar of the typical mammalian dentition, this tooth is the fifth from the midline of the jaws and face. It is more constant than the preceding in its morphologic characteristics, and hence appears to undergo fewer anatomic variations. In comparison with the first premolar its crown is generally slightly smaller, shorter, rounder, and its cusp less pointed. The bucco-lingual axis is directed inward and slightly backward, the morsal sulcus, therefore, slightly backward and outward. It appears normally to possess one root and therefore one pulp canal; but two, if not three root canals are quite common. In the latter case a bifurcation of the buccal root has occurred, more or less along its completed length, and the third canal opens into a common pulp cavity with the other two. Frequent connection with the maxillary sinus exists.

The Crown.—Of all four surfaces the *labial* or buccal is slightly convex, being flatter than that of the first premolar from above downward, and more convex than that tooth from side to side. It is diamond-shaped, and usually free from vertical ridges or grooves.

Lingually the crown matches very closely the corresponding surface of the first premolar. Indeed it is impossible when regarding these

teeth, which have been removed from the same mouth, to determine, by mere inspection of the lingual surfaces, which is the first or which is the second premolar. If there is a difference, it is that the second has a rounder cusp. For the size of the tooth the upper border of this surface is wider antero-posteriorly and less curved than obtains in the former.

Of the *mesial* surface the convexity is not remarkable, but *distally* it is. Their upper borders pass almost imperceptibly into the line of the neck of the tooth.

The *morsal* surface resembles that of the first premolar. It is subject to greater variations, however; its sulcus is shallower and shorter than that there seen. Frequently three slight elevations extend outward from the sulcus, separated by four short, narrow grooves, of which the middle are the most pronounced. This divides the surface into several tubercles; as many as five may be present. It is this fact which serves on occasion to differentiate this tooth from the first premolar. The sulcus may bifurcate at its anterior extremity and thus produce another tubercle, which may sometimes attain the size of a definite cusp.

The plane of the *neck* is normally horizontal.

The *root* is generally very conical in longitudinal outline. Transversely flattened, it exhibits but seldom the definite deep grooves associated with its neighbors. It is not often deflected, but may be bifurcated and possess three root canals.

The *pulp cavity* is large in a buccolingual section and extremely narrow in a mesiodistal section. Its cornua do not extend far into the cusps of the tooth. Of the two the outermost is the greater.

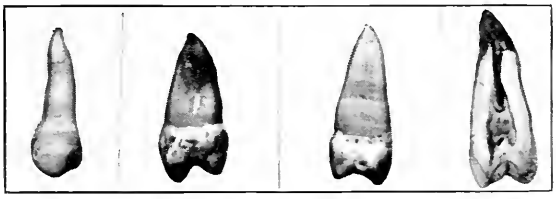

A *B* *C* *D*

FIG. 7.—Maxillary second premolar. *A*, buccal surface; *B*, mesial surface; *C*, dista surface; *D*, bucco-lingual section.

Calcification begins during the fifth year. The apical foramen is closed during the eleventh to the twelfth year, eruption taking place at the tenth year and third month.

Length, 22 mm.; *width*, 5 mm.

Identification.—It is impossible to determine to which side of the mouth this tooth belongs.

In *occlusion* the tooth comes into contact with both the mandibular second premolar and first molar; in the first instance by means of its internal cusp and the posterior ridges of the two cusps of the premolar and in the other by means of its internal cusp and the mesio-buccal and mesio-lingual cusps of the molar.

The First Molar.—Of all the teeth of the human dentition this is undoubtedly the most important. From the viewpoints of palæontology, histogenesis, homology, pathology, surgery and orthodontics, it may be regarded as the most interesting.

The sixth tooth from the midline of the face attains the highest degree of development in size of all the other posterior members of the series. This is its most striking feature, for the morsal surface of its crown is nearly as great as that of the two premolars put together. It is in association, through its anterior buccal root, with the floor of the antrum, and communicates with the *cavum oris* by means of its palatine root and *vestibulum oris* by means of its buccal root. Obliquity of the crown is always accompanied by marked obliquity of the roots. It presents for examination a crown, neck and three roots.

The *crown* exhibits five surfaces: (i) buccal or external, (ii) lingual or palatine, (iii) mesial, (iv) distal, and (v) morsal or occlusal.

Quadrilateral in outline the *buccal* surface extends in the antero-posterior diameter a distance fully twice that of the same diameter of either of the premolars, while its vertical measurements are less than those of the same tooth. It is slightly convex in both directions and is frequently divided into two unequal parts by a perpendicular groove which begins at a slight distance below the cervical margin. Its upper border is short and straight. Its lower border is distinguished by two similar-sized curves—the external portions of the buccal cusps —of which the convexities look downward.

The *lingual* surface resembles the preceding to some extent, the main points of difference being the flatter inferior border, the rounder character of the angles of the same and the marked prominence of the vertical groove which often curves backward in its lower part. The distal portion of this surface is much more convex than the mesial.

Roughly rhomboidal in outline the *mesial* extensive, flat surface possesses on its lower palatine aspect a pronounced, highly convex slope downward and forward. Its upper border occupies a horizontal plane, but the lower border is deeply indented near the middle and internally carried considerably downward.

Unlike the former the *distal* quadrilateral surface is more generally convex in both directions, the convexity being accentuated toward the palatine side. It is free from grooves, and its junction with the neck is hardly perceptible.

The *morsal* surface in outline is roughly quadrilateral, with rounded angles. It possesses four cusps, an oblique ridge and two main sulci or fissures. According to their position so are the cusps named. They are called the antero-external, or mesio-buccal, the postero-external, or disto-buccal, the antero-internal, or mesio-lingual, and postero-internal, or disto-lingual.

Of these the largest, most pyramidal and most prominent, is the antero-internal cusp. It is joined to the postero-internal cusp by the oblique ridge, which, near the middle, is traversed by a slight depression, amounting almost to a groove. These two cusps are separated from the other two by the anterior and posterior sulci, the former short, deep, bending at its middle at an acute angle, and thus passing at first from without inward in a straight line, and then suddenly bending forward; and the other beginning near the middle of the surface, sometimes in a pit, and running inward and slightly forward. The antero-external cusp is somewhat triangular in outline and the postero-internal considerably flattened from side to side and from before backward. With regard to size it is thus obvious that the dimensions of the individual cusps decrease in the following order: antero-internal, antero-external, postero-external and postero-internal. A fifth cusp may be present as an elevation of the cingulum at the side of the anterior internal cusp.

The *neck* occupies a horizontal plane and is unmarked by any notable deviations from a straight line. In section the tooth is rhomboidal in outline at the neck and is also more extensive on the lingual than on the opposite side.

The Roots.—This tooth possesses three roots: (1) The anterior buccal root is broad in the bucco-lingual direction, much flattened and cone-shaped, its central axis looking upward and slightly outward and forward. It is often grooved, especially on its inner side; hence two root canals may exist, both of which terminate in a common apical foramen. (2) The posterior buccal is considerably shorter and smaller than the foregoing, probably normally more divergent, slightly grooved, and consequently less likely to contain two root canals. (3) The palatine root is a prominent feature of this tooth. Very divergent, and thus ensuring great stability and strength in its articulation with the maxilla, it is the least flattened of the three. It is frequently deflected and twisted. It measures approximately half an inch in length, the lengths of the others being about three-eighths inch.

The *pulp cavity* closely follows in its outline the shape of the crown. At its roof it has three cornua, each extending somewhat into each cusp, and on the floor or "infundibulum" the three openings of the root canal, that on the palatine side being cylindrical, the others laterally flattened.

Calcification occurs in the first instance in about the eighth month of intra-uterine life and is completed during the eleventh or twelfth year, eruption taking place at the sixth year and sixth month.

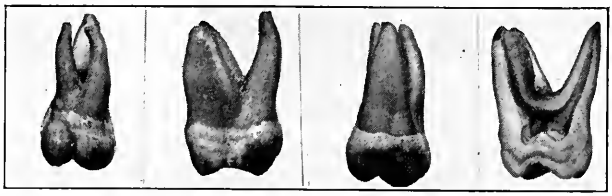

A *B* *C* *D*

FIG. 8.—Maxillary first molar. *A*, buccal surface; *B*, mesial surface; *C*, lingual or palatal surface; *D*, bucco-lingual section.

Length.—From the apex of the palatine root to the most prominent part of the crown is 22 mm., of the buccal root to the anterior part of the internal border 21 mm., and of the disto-buccal root to the posterior part of the external border 19 mm.

Identification.—The end of the oblique ridge nearest the observer will point to the side to which the tooth belongs if the tooth is held crown uppermost and the palatine root away from him.

Occlusion.—The mesio-buccal cusp is received into the central sulcus of its lower congener, the disto-buccal cusp into the disto-lingual and disto-buccal cusps and the mesio-buccal and mesio-lingual cusps of the mandibular second molar.

THE SECOND MOLAR.—Intermediate in size between the first and third molars, this tooth, in general, follows the architectural plan of the first-named, particularly on the buccal portions of crown and roots. The greatest deviation in pattern from the first molar is to be found on the lingual side. The opening of Stenson's duct is usually opposite this tooth. This is the seventh tooth from the front of the mouth. It has a crown, neck and three roots.

The *coronal* portion of the tooth is smaller, less quadrilateral in outline, and its usual features more pronounced than the former; thus the buccal cusps are separated by deeper sulci and hence appear to be more pronounced than in the first molar.

The *buccal* surface is flattened from above downward and slightly convex from side to side. Often crossed by a broad horizontal depression, it is fairly quadrangular in outline, its longest border being the inferior which, like that of the first molar, is divided by a fissure into two uneven parts, and is doubly curved on account of the elevations of the buccal cusps.

The most noticeable feature on the *lingual* side is the marked sloping

of the distal part and the very slight elevation of the line of the lower border. It is thus dissimilar to what obtains in the first molar.

The *mesial* surface is considerably broader in its bucco-lingual diameter than its height. It is slightly convex and shelves off toward the inner side.

The *distal* surface is extremely convex in both directions and short in the superior and inferior diameter. In both cases the upper border, represented by the neck, is practically a straight line, while the lower border is very diversified in this respect, particularly on the distal side.

Differing in a remarkable degree from that of the first molar, the *morsal* surface of this tooth presents usually the four cusps of the typical molar, but in many instances three cusps only are seen, *viz.*, antero-external, postero-external and internal. When four are present they are the homologues of those of the first molar. The large antero-internal cusp is united with the postero-internal by an inconspicuous oblique ridge, which is commonly traversed by a shallow sulcus. The two outer cusps exhibit the usual mammilliform shapes of a typical molar. They are separated by a deep fissure which ends at a point near the center of the buccal surface. The antero-internal cusp is frequently fused to the postero-internal cusp, the two forming a large irregular eminence with pointed extremity and sloping sides. A vertical depression, amounting sometimes to a fossa or pit, may here be seen.

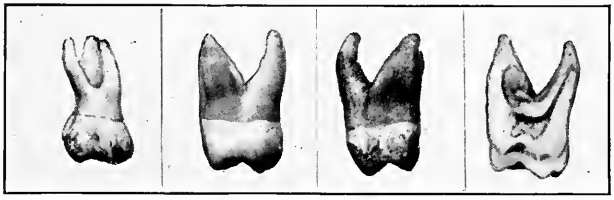

A *B* *C* *D*

FIG. 9.—Maxillary second molar. *A*, buccal surface; *B*, mesial surface; *C*, distal surface; *D*, bucco-lingual section.

The *neck* lies in a horizontal plane and probably, when compared with that of the first molar is somewhat more constricted.

The Roots.—The divergency of the three roots of the first molar are not so marked in this tooth. Of smaller build, there is a tendency for their union, especially of the palatine and the anterior buccal. Obliquity of the crown frequently obtains, with consequent obliquity of the roots. Deflection backward of all three is quite common.

Pulp Cavity.—The coronal part is broad in the bucco-palatine direction, narrow in the other. The floor of the cavity is flat or depressed. The root canals are exceedingly flattened from side to side.

Calcification commences at the fifth year, being completed between the sixteenth and eighteenth. The tooth begins to erupt about the end of the eleventh year.

Length, 22 mm.; *width,* 11 mm.

Identification, as in the first molar.

Occlusion.—The mesio-buccal cusp occludes with the central part of the morsal surface of the mandibular second molar and the disto-buccal cusp with both the distal cusps of the second molar and the mesial cusps of the third molar.

The Third Molar.—More variations in size, shape, position and anatomic features of the crown and roots exist in this than in any other member of the dental series. Frequently suppressed it is the smallest of the three molars and totally dissimilar in pattern to the first molar. The crown presents five surfaces for examination.

Buccally there is a close resemblance to the corresponding surface of the second and first molars. It is, however, more convex in both directions, particularly from side to side; less extensive in the mesio-distal diameter and its lower border less distinctive and more rounded. A vertical shallow groove divides it into two unequal parts, of which the anterior is the greater. The upper border is flat, the angles round, especially that on the disto-buccal side.

On the *lingual* side the tendency to a shelving or sloping of the distal portion, noticed in the middle molar, is much more accentuated here. The whole surface is slightly convex from above downward, but laterally this convexity is greatly pronounced.

The *mesial* surface is broad and flat, and when the tooth is *in situ* is close up against the distal surface of the second molar, thus considerably reducing the capacity of the interproximate space.

Distally the crown is markedly convex, narrower from above downward than in a lateral direction.

The *morsal* surface of the crown, on comparison with the other molars is small, quadricuspid in about 50 per cent. of cases, and tricuspid in about 50 per cent. of cases, and notable in the absence of any deep sulci, fissures or elevated cusps. In the tricuspid form the internal cusp is the largest, the postero-external the smallest. The crown is frequently divided into seven or eight tubercles, each separated by short, shallow and wide grooves; each also passing in every direction from a short, central, deep sulcus running across the antero-posterior diameter of the tooth.

The *neck* is more constricted on the distal than the mesial surface. It lies in a horizontal plane.

Possessing normally three *roots,* which may be separate and somewhat divergent, or confluent, as usually happens—roots which are

short, small, deflected backward—this tooth may exhibit at times four, five or six roots. The obliquity of the crown in these conditions is repeated in the obliquity of the roots, which are often misshapen and tortuous, the palatal root or roots being the most inconspicuous of all.

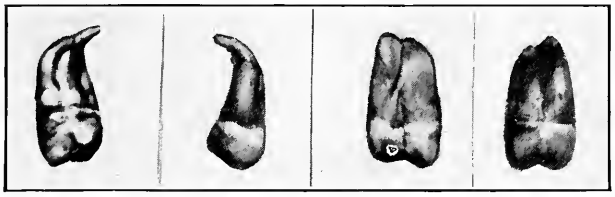

A *B* *C* *D*

FIG. 10.—Maxillary third molar. *A*, buccal surface; *B*, palatal surface; *C*, mesial surface; *D*, distal surface.

Triangular in outline and in shape the *pulp cavity* varies just as much as the pattern of the crown. When triangular in outline the buccal wall is the shortest; its "infundibulum" or base is absent; the orifices of the root canals close together and exceedingly minute.

Calcification begins during the ninth year, is completed between the eighteenth and twentieth years and the tooth begins to erupt at about the eighteenth to twentieth year.

Length, 20 mm.; *width*, 11 mm.

Identification.—Can be effected by placing the tooth in the position described for the first molar, when the flattened mesial surface of the crown will point to the side to which the tooth belongs.

Occlusion.—In this the only tooth of the maxillary series occluding with one mandibular tooth, the large central sulcus accommodates the external and distal cusps and thus slightly overlaps the tooth on the buccal as well as the distal side.

2. **The Mandibular Teeth.**—THE FIRST INCISOR.—Situated on either side of the alveolar process of the mandible at the *symphysis menti*, which, in the junction of the two halves of the bone, as a rule, leaves no traces in fully-formed conditions, this tooth is the homologue of the first mandibular incisor in anthropoid apes and is the corresponding tooth in occlusion with its maxillary namesake. It is probably less variable in pattern and situation than any other tooth, and in the absence of a tendency to formation of a cingulum, differs thus very markedly from its congener in the upper jaw. It possesses a crown, neck, root and pulp cavity.

The *crown* is well proportioned. Fashioned like a flattened cone and thus chisel-shaped, smooth with, at times, obvious imbrication lines on the triangular *labial* side, it is more convex from above downward

than from side to side, being devoid of a perpendicular groove. It is broad at its superior or incisive edge, which at birth is often surmounted by three tubercles, as in the maxillary teeth, and rapidly narrows as it approaches the very inconspicuous inferior or gingival border.

The *lingual* surface is concave in both directions, that from side to side being particularly noticeable. The triangular proportions of the labial surface appear here, but are more accentuated on account of the somewhat greater elevation of the sides of the triangle, particularly at its apex. This surface is nearly always free from depressions or grooves.

Mesially, a flat triangular surface, with its indistinguishable base below at the gingival margin, and its apex at the mesial angle of the incisive edge, it exhibits generally the same features on the *distal* aspect of the crown, which, however, may be slightly concave in the vertical and a little convex in the transverse direction. The mesial surface is slightly larger than that on the opposite side.

The *borders* and *angles* are similar to those described in connection with the maxillary tooth.

The *neck* is slightly constricted and therefore inconspicuous. It is curved downward on the labial and lingual sides.

The *root* is long, narrow in the antero-posterior diameter, but broad and flattened in the other direction. Its anterior side is slightly longer, less convex, and broader than the other. The flattening of the sides may amount at times to a shallow grooving extending nearly all the length of the distal aspect of the root.

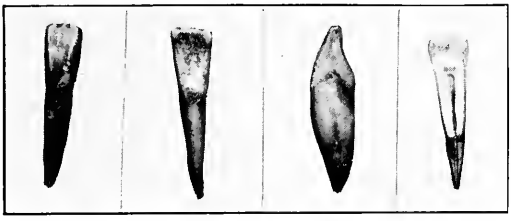

A *B* *C* *D*

FIG. 11.—Mandibular first incisor. *A*, labial surface; *B*, lingual surface; *C*, mesial surface; *D*, mesio-distal section.

The outline of the *pulp cavity* follows that of the external portion of the tooth, being quite narrow from side to side, and broad in labio-lingual section. The root canal may be bifurcated, but this is not a usual condition.

Calcification of this tooth begins during the first twelve months after birth, and the apical foramen is formed by the tenth year. In 30 per cent. of cases the tooth is erupted about the sixth year and sixth month.

Extreme *length*, 23 mm.; extreme *width*, 6 mm.

Identification.—In a horizontal position, with root toward the observer, the longer side of the tooth indicates the side which it occupies when *in situ*.

Occlusion occurs on the labial side with the lingual aspect of the crown of the maxillary first incisor.

The Second Incisor.—A reversal of the anatomic characteristics of the upper incisor is found here in the fact that while the maxillary second incisor is considerably smaller than the first incisor the mandibular second incisor is larger than that just described. In some jaws there is great disparity in size, but in well-constructed typical instances differences in the dimensions of the two are not so marked.

Crown.—Triangular in outline, the *labial* surface is broad at the base and incisive edge and narrow at the gingival margin, but the angles are not so acute as in the first incisor. The surface is a little more convex in both directions than that tooth. It has a long upper border.

Lingually the surface is the counterpart of the first incisor. In some cases the concavities are slightly more pronounced. There is no attempt at the formation of an internal cusp, as in the upper tooth, consequently no pits or fissures are here observed.

The *mesial* surface is long and either flattened or slightly concave. Its superficies is trangular, with the base below and apex above, forming with the incisive edge an acute angle.

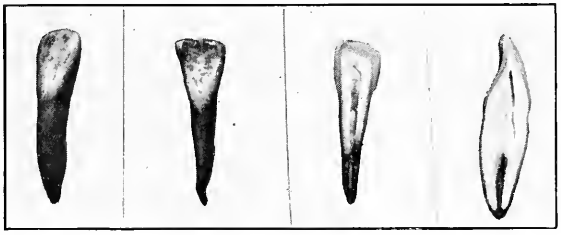

A *B* *C* *D*

Fig. 12.—Mandibular second incisor. *A*, labial surface; *B*, lingual surface; *C*, mesio-distal section; *D*, labio-lingual section.

Distally the surface is short, flat, or slightly concave, and its angle at the incisive edge nearly a right angle.

The Neck.—The coronal and radicular portions blend imperceptibly into one another and the junction of the two usually cannot be seen except on the lingual side.

The *root* is longer in this than in the preceding tooth. It is straight, narrow from before backward, and broad from side to side. A median

vertical groove often extends down its entire length on both sides, and is generally more marked on the side toward the canine.

The *pulp cavity* resembles that of the first incisor, being extremely flattened about the midportion of the root, but cylindrical in the coronal and apical regions. In its coronal parts it extends somewhat suddenly to form a not inconsiderable-sized cavity.

Calcification, root formation and eruption occur at the ages of the first year, tenth to twelfth, and seven and a half years respectively.

Length, 24.5 mm.; *width*, 6 mm.

Identification as in the mandibular first incisor.

Occlusion takes place with the lingual aspect of the crowns of the maxillary first and second incisors.

THE CANINE.—This tooth affords a good example of the transitional type of organ from the chisel-like incisive crown of the anterior teeth to the semi-molariform pattern of the posterior teeth. The intermediate character of the coronal features here is justly noticeable. Occasionally it may be an enormous tooth, especially in length. In typical specimens the buccal aspect of its crown has a greater superficies than any other mandibular tooth.

Crown.—On its *buccal* side the crown presents an extensive surface for examination. A vertical parallelogram, its upper border is pointed, the apex being nearer the front than the back, thus dividing the incisive edge into two unequal parts, of which the posterior may measure twice the length of the anterior. The surface is convex in both directions, more in the vertical than in the horizontal. A slight perpendicular ridge of enamel may frequently be found here. The lower border is in a straight line.

On the *lingual* surface a large, shallow concavity appears. This is deeper from side to side than above downward. The floor of the cavity is not smooth but overrun sometimes by one or more vertical ridges, separated by grooves of varying depth and length. The borders of this surface are much rounded, especially at their lower part, where an elevation of the cingulum may occasionally be seen. A canine with a lingual cusp always belongs to the upper, never to the lower jaw.

The *mesial* surface is triangular in outline, being similar in shape and size to the distal surface of the second incisor. It is flat and extensive and passes imperceptibly over to the root by means of an inconspicuous neck.

The *distal* surface differs in a marked degree from that last described, in that its surface is convex in both directions, particularly the vertical, and joins with the sloping upper border of the crown to make a prominent "contact point" with the neighboring tooth. It bends in very suddenly toward the constricted neck, and thus is produced one side of an unusually large interproximate space.

The most conspicuous part of the *neck* is on the labial and lingual surfaces.

The *root* assumes great dimensions. It is broad at the cervical margin, is usually straight, *i. e.*, has the same longitudinal axis as the whole of the tooth, but in every instance is inclined to be deflected somewhat toward the distal side. Shallow grooves exist mesially and distally. Of the four aspects of the root the lingual and the mesial are the narrower. Bifurcation of the root canal is fairly common, and the development of an extra lingual root not infrequent.

The *pulp cavity* bears some resemblance in shape to that of the maxillary canine. It is large in the labio-lingual diameter, narrow and tube-like in the mesio-distal section.

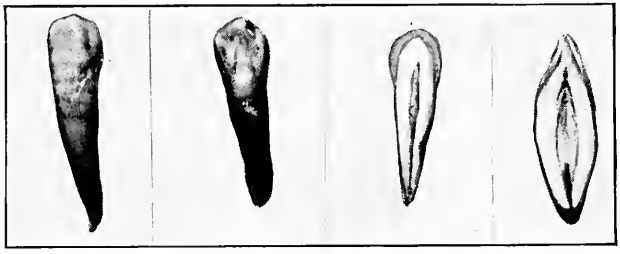

A *B* *C* *D*

FIG. 13.—Mandibular canine. *A*, labial surface; *B*, lingual surface; *C*, mesio-distal section; *D*, labio-lingual section.

Calcification begins with the third year, is concluded at about the twelfth or thirteenth, and the tooth begins to erupt in company with its maxillary *confrère* before calcification is complete, about the eleventh year and third month.

Length, 31 mm.; *width*, 12 mm.

Identification.—Placed horizontally, with root toward the observer, the shorter of the two portions of the cutting edge is directed toward the side to which the tooth belongs.

In *occlusion* the labial surface is in contact with the lingual surface of the maxillary canine, and also of the distal portion of the same surface of the second incisor.

THE FIRST PREMOLAR.—Most interesting of all teeth from a morphological point of view, this tooth, even better than the preceding, exhibits and illustrates a gradational type between a tooth, with a thin, incisive edge and that with a broad morsal surface. Though there are no two teeth absolutely alike in shape and pattern, there is generally a close similarity in the design of the corresponding teeth in each half of the jaw. A variation exists here, for the two first pre-

molars may be entirely different, one presenting a crown like an underdeveloped canine, the other molariform in general appearance.

The typical *crown* imitates the architectural features of the maxillary canine, as will be described below.

Externally the *buccal* coronal surface closely resembles that of the anterior tooth. It is less high, however, and approaches a pentagonal form with a pointed upper extremity. It is markedly convex from side to side; less so in the other direction. Its upper border is like that of the canine.

The *lingual* surface is very inconspicuous. It is convex from before backward, less so from above downward. It is four times as long as it is broad, and surmounted by a tubercle which extends over the coronal surface.

The *mesial* convex surface is more extensive than the opposite, sloping obliquely inward from its junction with the buccal surface.

The area of the *distal* surface is much smaller than that on the mesial side, due to the encroachment of the backward slope of the morsal surface of the tooth.

Morsally, a unique appearance is presented by the absence or suppression of the internal cusp, so conspicuous in the maxillary premolar. That the internal cingulum is raised on this surface is obvious, for frequently not only does it form a thickened tubercle, but a marked ridge, which passes immediately upward to terminate in the apex of the incisive edge, and is derived from the same elevated crest. Further, from the base of this ridge also, frequently short thick bands elevate themselves upward and forward and upward and backward. The consequence of the production of these ridges is the formation of deep pits on the mesial and distal aspects of the crown. Of these the latter is the deeper. This triangular surface may exhibit four or five tubercles, or two cusps, one prominent, the other less pronounced.

The *neck* occupies a horizontal plane. It is frequently almost invisible, owing to its lack of constriction.

On the faces of the *root,* which follows with but little deviation the line of the central longitudinal axis of the tooth itself, the broader are on the buccal and mesial sides. Grooves existing on the mesial and distal sides may be deepened to such an extent as to give the appearance of the bifurcation or the production of a third root. In the case of the latter the root is placed in an antero-external position.

The *pulp cavity* simulates in outline the general contour of the crown. A small cornu may insinuate itself toward the lingual tubercle. Usually the pulp chamber is a slightly flattened cylinder. In the case of an additional root or roots the canals are cylindrical.

Calcification begins about the fourth year. The apical foramen is completed at the eleventh to the twelfth year, eruption taking place at the ninth year and tenth month.

Length, 25 mm.; *width,* 7 mm.

Identification.—In a vertical position, with the extremely rounded labial surface of the crown nearest the observer, the round mesial surface, with its fossa, points to the side to which the tooth belongs.

Occlusion. The mesial and coronal surfaces interdigitate with the distal aspect of the crowns of the maxillary canine and its distal surfaces with the inner cusp of the maxillary first premolar.

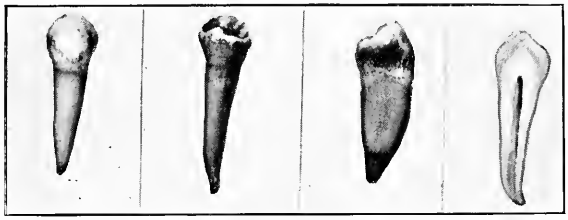

A *B* *C* *D*

FIG. 14.—Mandibular first premolar. *A*, buccal surface; *B*, lingual surface; *C*, distal surface; *D*, labio-lingual section.

THE SECOND PREMOLAR.—The main architectural features of this tooth are entirely different from those just described. It approximates more closely that of the upper second premolar, save that in typical specimens it is smaller in every particular. The crown is large, with rounded angles, and its inner portion raised more nearly on a level with the occlusal surface of the first molar than in the anterior tooth.

The *crown* possesses five surfaces. Of these the *buccal* is the largest, being almost identical in shape, size and contour with that of the first premolar. It may measure a little less in the vertical direction. The cusp is round.

Lingually—a fairly convex surface—the crown is wider from before backward than from above downward, and thus presents the outlines of a flat parellelogram.

Of the *mesial* and *distal* surfaces the former is larger, smoother and more flattened than the latter, the presence of a cusp at the upper part of the latter giving it an undue prominence over that of the other side.

The *morsal* surface is somewhat square in outline; all of its four borders are rounded, its cusps and tubercles less marked than those of the upper tooth. The sulcus is fairly deep, runs from before backward, and divides behind into two and sometimes three branches, enclosing

elevations of enamel which, not being pronounced enough to designate as cusps, are more correctly described as tubercles. The largest of these is often placed most distally.

The *neck* is but slightly discernible on its convex distal side. It lies in a horizontal plane.

The *root* is unusually long and large. Its buccal side is wider than the opposite and its anterior aspect flat or slightly convex, its distal surface concave or grooved.

The *pulp cavity* possesses two marked cornua, of which the larger is contained in the labial cusp. The pulp canal is single and much flattened from side to side.

A *B* *C* *D*

FIG. 15.—Mandibular second premolar. *A*, buccal surface; *B*, mesial surface; *C*, mesio-distal section; *D*, bucco-lingual section.

Calcification begins between the fourth and fifth years, is completed seven years later, and the tooth erupts at a date prior to its completion, namely, about the tenth year and sixth month.

Length, 23 mm.; *width*, 8 mm.

Identification.—It is generally almost impossible to determine whether the second premolar belongs to the right or the left side of the mandible.

Occlusion.—This tooth occludes with the maxillary premolars, its mesial coronal surfaces coming into contact with the distal surfaces of the upper first premolar and its distal surfaces with the mesial aspects of the crown of the second premolar.

THE FIRST MOLAR.—Upon this tooth the dentition of man probably is principally dependent for the greatest stress and strain in the dental arch, its position in the middle of the masticatory field giving it an importance which is second only to that of its maxillary homologue. It possesses a considerable degree of anatomical interest also, for its morsal surface presents for examination a larger and more complicated arrangement of parts than obtains in any other tooth. Its relations to the sciences of palæontology, anthropology and biology, in addition to those of surgery and orthodontics, invest it with a degree of interest which is unique. The obliquity which is so common a

feature of the crown of the maxillary molar is here noticeable; the tooth is therefore more or less variable in form.

A crown, neck and two roots are to be described.

The *crown* has five surfaces: mesial, distal, buccal, lingual and morsal.

The *mesial* surface is smooth and equally convex in both directions. It has a curious outline, roughly similar to that of an isosceles triangle with an extended base and considerably flattened apex, of which the outer straight line bends inward rather more than the opposite, making a more acute angle at its junction with the base than the internal, which contains almost a right angle. Its upper surface is marked by the presence of two shorter and smaller apices—the anterior portions of the antero-external and antero-internal cusps. The "contact point" of this surface is to the outer side of the midline and about midway between the neck and the upper border.

Distally the surface is fairly quadrangular in outline, broader in the bucco-lingual diameter, and relieved by the elevation of the distal surface of the fifth or distal cusp. Thus the upper border presents three elevations of varying size, of which the most distal is the shortest and most conspicuous.

A *B* *C* *D*

FIG. 16.—Mandibular first molar. *A*, buccal surface; *B*, lingual surface; *C*, mesial surface; *D*, distal surface.

Of all the *buccal* surfaces of the teeth, that of this tooth is by far the largest. It frequently measures 12 mm. from before backward, approximately about 3 mm. longer than that which obtains in the upper tooth. It is exceedingly convex, from above downward, giving the appearance of being inclined inward, less convex from side to side. In outline it assumes the form of a rough parallelogram, with a flat, straight base and somewhat divergent sides, and an indented upper border raised into three points, of which the anterior is broad and round, the middle sharp and the posterior small and blunt. A groove passes between the two first named and frequently terminates in a conspicuous pit, a favorite site for dental caries.

The *lingual* surface resembles somewhat remarkably the buccal

surfaces of the maxillary first and second molars, the points in the upper border, however, being sharper than the rounder elevations in the last named. Its smooth, slightly convex area is contained in a fairly regular parallelogram, of which the upper and lower sides are the longer. A pit or fossa is seldom, if ever, noticeable on this surface.

Morsally this tooth presents a trapezoidal figure with five cusps and five fissures. Of all the sides the anterior is the most nearly straight, the distal the most acute, the innermost the longest and the outermost divided into two even parts. The cusps are named according to their position: (i) Antero-external or mesio-buccal; (ii) antero-internal or mesio-lingual; (iii) postero-external or disto-buccal; (iv) postero-internal or disto-lingual; (v) distal. The chief characteristics of the individual cusps are as follows: mesio-buccal, the largest, most rounded, with shelving outer part; mesio-lingual, the most acutely pointed; disto-buccal, narrow from front to back, somewhat wedge-shaped, with blunt apex; disto-lingual, short, triangular, frequently subdivided into three small tubercles by two short grooves passing inward; and distal, small, prismatic in outline and possessing an acute cusp.

The fissures vary greatly in depth, direction and dimensions. As they are situated, so are they named. Thus, taking their origin from the center of the crown the *anterior* separates the two mesial cusps, and as it reaches its termination often bifurcates widely and so produces an extra cusp, which is then named the mesial cusp; the *posterior* running irregularly backward and enclosing in its bifurcation the distal cusp; the *buccal* passing directly outward, separating the two buccal cusps and extending over the ridge to the pit on the buccal side; and the *lingual*, separating the two inner cusps and terminating just short of the upper border of the lingual surface. The short fifth fissure is centrally placed and unites the others together.

The *neck* is usually indistinct, quadrangular in outline and in the same horizontal plane.

The *roots* are two in number: anterior or mesial, and posterior or distal. The former is broad, extremely flattened from before backward, slightly deflected backward, somewhat triangular in shape, and grooved on both sides, that on the distal side being the more pronounced; the latter is smaller, more nearly straight, narrower and grooved on its anterior aspect.

The *pulp cavity* is irregularly square in its coronal portion, with extensive cornu at its upper corners. There is no cornua, as a rule, beneath the distal cusp. Three pulp canals are frequently found, two in the mesial root and one in the distal. Of these the former are small,

flattened laterally; the latter large and much flattened from side to side.

Calcification begins during the eighth month of intra-uterine life. The roots are completely formed by the ninth to the tenth years, and eruption takes place at the sixth year and sixth month.

Length, 21 mm.; *width*, 12 mm.

Identification can be effected by holding the tooth crown uppermost, with the small triangular distal cusp away from the observer, the pit on the buccal surface (or the very rounded character of the latter if there is no pit) points to the side opposite to that to which the tooth belongs.

Occlusion.—The mesio-buccal cusp occludes with the distal ridges of both cusps of the maxillary second premolar, and the mesio-buccal and mesio-lingual cusps of the maxillary first molar; and its disto-buccal cusp with the central part of the morsal surface of the same tooth.

The Second Molar.—This tooth is modeled on a different architectural plan from that of the preceding. It differs in the facts that it is smaller, more symmetrical in shape, its cusps more proportionally equal in size. It has no fifth cusp and its roots are closer together than in the first molar.

The *crown* has five surfaces. *Mesially* the surface is slightly convex, square in outline, with its superior border raised into two blunt points, the sides of the mesial cusps. The lower border slopes gently downward and outward. On the *distal* side a greater convexity of the surface is observed over any other. Its upper border is nearly horizontal, being relieved somewhat by the presence of two blunt apices. With the exception of the superior surface the *buccal* aspect of the crown is the largest of all. Quadrangular in outline, its anterior and posterior borders are more nearly parallel than in the first molar. It is smooth and convex in both directions, especially the vertical. It is seldom disfigured by the presence of a pit or fossa. The *lingual* surface is broader antero-posteriorly than vertically. Slightly convex, it presents a similar appearance to that of the opposite side. The *occlusal* surface is remarkable for the regular arrangement of its constituent parts. Its four cusps, mesio-buccal or antero-external, disto-buccal or postero-external, mesio-lingual or antero-internal, and disto-lingual or postero-internal, are distinctly uniform in character, outline, size, shape and height. If there is a difference the mesio-buccal cusp is the most important and pronounced. The fissures emanate from a common central spot in the middle of the crown. They vary slightly in depth, run in straight lines, pass directly forward (mesial fissure), backward (distal), outward (buccal), and inward (lingual) and seldom bifurcate or extend over the sides of the crown.

The constriction of the horizontally placed *neck* is unusually marked.

Similarly to the first molar there are two *roots*. Generally speaking they are smaller, more confluent and less compressed from side to side than those of the aforementioned tooth. The mesial is the larger and broader and deflected somewhat backward; the distal, the straighter and frequently the shorter and narrower. The distal root is not grooved.

The *pulp cavity* follows in shape the general outline of the crown; the root canals, of the roots, that on the mesial side being much flattened laterally, the other more nearly cylindrical.

A *B* *C* *D*

FIG. 17.—Mandibular second molar. *A*, buccal surface; *B*, lingual surface; *C*, mesial surface; *D*, mesio-distal section.

Calcification occupies about eleven or twelve years, the first signs appearing at the fifth year and the apical foramina completed by the sixteenth or seventeenth year. Eruption begins about the eleventh year.

Length, 23 mm.; *width*, 11 mm.

Identification.—A typical tooth has, as already indicated, a square crown. If such a tooth is held crown uppermost, with the larger root nearest the observer, the flatter of the two lateral surfaces will point to the side to which the tooth belongs.

Occlusion.—The mesio-buccal cusp occludes with the disto-buccal and disto-lingual cusps of the maxillary first molar, and the mesio-buccal and mesio-lingual cusps of the second molar. Its disto-lingual cusp interdigitates with the central part of the morsal surface of the maxillary second molar.

THE THIRD MOLAR.—Typical examples of this tooth are difficult to find. It undergoes, however, fewer variations in size and pattern of crown and shape of roots than its maxillary congener. In a well-developed jaw it is a large tooth; even in a small jaw it is still a relatively large tooth. While not subject to much change in architectural details it is frequently misplaced, and its surgical affections most important in their induction of severe systemic and general disturbances.

The *crown* occupies nearly the upper half of the entire superficies. This is more noticeable, perhaps, on its distal than on its mesial side.

The *mesial* surface is convex, slopes inward and is higher on the internal than on the buccal side. The upper border is raised into two more or less definite projections or points.

Distally the surface is markedly convex. The amelo-cemental junction at the neck is fully constricted. This surface is fairly square in outline, and its upper border relieved by three or more blunt, variable points.

A *B* *C* *D*

FIG. 18.—Mandibular third molar. *A*, buccal surface; *B*, lingual surface; *C*, mesial surface; *D*, distal surface.

The *buccal* surface is much broader than deep. It is very convex, particularly behind, where its distal angle is considerably rounded. The *lingual* surface is broad from before backward, shallow from above downward, the line of its upper border being deeply indented in the center.

The *occlusal* surface presents many varieties of shape, outline, size and pattern. It may be rounded or flattened, arched or tuberculate; it may be roughly hexagonal; it may be broader antero-posteriorly than bucco-lingually; it may have four, five, six, seven or eight cusps of every different shape and size. It may closely simulate the pattern of its neighbor; it may be entire dissimilar, presenting superficial pits, grooves, fissures, fossæ and the like. The table-land may be raised up into one large cusp toward the lingual side of this surface with, at its base, numerous tubercles, which sometimes are conical, oval, oblong, round or pointed. Well-formed teeth exhibit fissures which run in similar directions to those of the second molar, but are generally shallower and less regular in general character.

The *cervical* margin is well marked and nearly horizontal.

The *roots* are diminutive and disproportionate to the size of the crown; inclined somewhat backward; usually confluent; occasionally separate and in rare instances allowing the passage of the mandibular nerve between them. Usually two are present, but there may be three or even four, all of which rapidly taper down at their apices to a fine point.

The shape of the common *pulp cavity* is governed by that of the

crown. The canals are small and irregular, depending upon the general shape and character of the roots themselves.

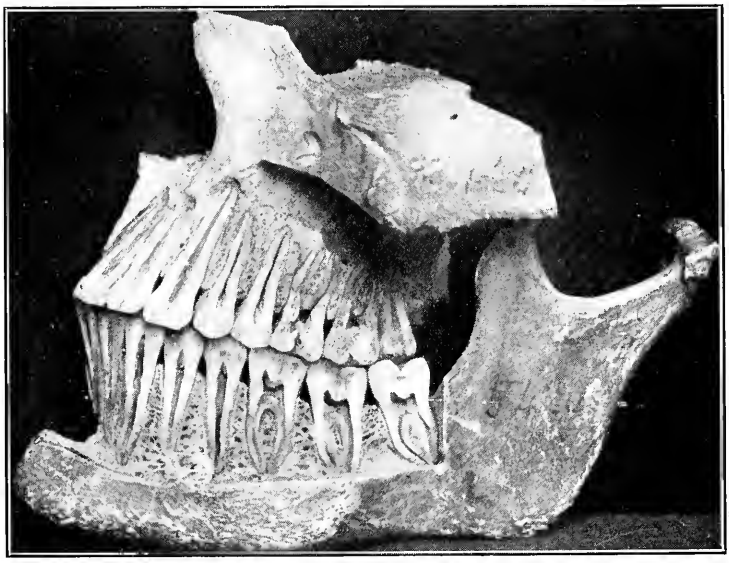

FIG. 19.—Vertical section through the left maxilla and mandible of man, with the external alveolar plates removed, to show the general arrangement of the roots of the teeth *in situ*, and the shapes, sizes and positions of their pulp cavities and root canals.

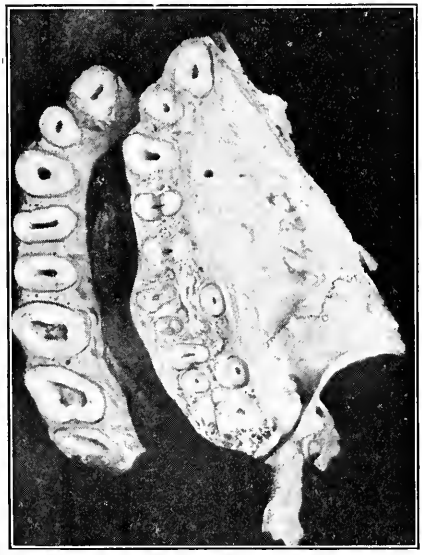

A *B*

FIG. 20.—Horizontal sections through the alveolar process of the right maxilla of man with the permanent teeth *in situ* at (*A*) the gingival margins, at (*B*) the root portions, showing the shapes, sizes and positions of the pulp cavities and root canals.

A B

FIG. 21.—Horizontal sections through the alveolar process of right half of mandible of man with the teeth *in situ* at (*A*) the gingival margins, at (*B*) the root portions, showing the shapes, sizes and positions of the pulp cavities and root canals.

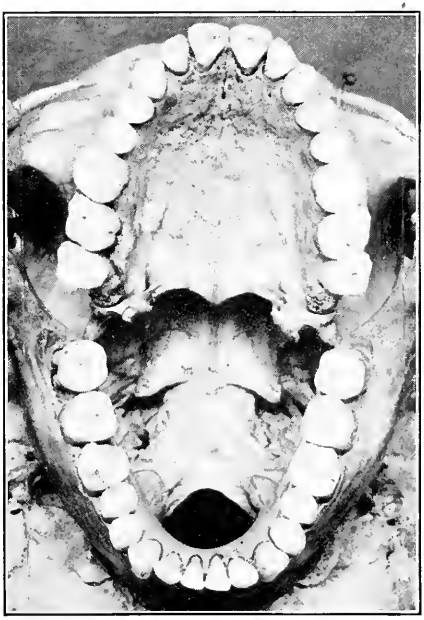

FIG. 22.—The occlusal surfaces of the permanent teeth *in situ*. The dental arch is elliptical in shape in the maxilla, and parabolic in the mandible—a condition which obtains in 70 *per cent.* of cases.

Length, 16 mm.; *width*, 10 mm.

Identification.—Typical specimens may be identified as in the case of the second molar, but it most frequently happens that it is impossible to determine to which side of the mouth the tooth belongs.

Calcification commences between the eighth and ninth year and continues until the eighteenth to the twentieth year. Eruption takes place during any period between the twentieth and twenty-fifth years.

Occlusion.—The mesial cusps occlude with the ridges of the distal cusps of the maxillary second molar and the remainder of its morsal surface with the anterior half of the maxillary third molar.

B. The Deciduous Series.—It is unnecessary, in the author's judgment, to describe in detail in this article the anatomy of the deciduous teeth. A few observations, however, are desirable to complete what has already been written about the human dentition.

Ten in number in each jaw, the deciduous teeth represent on a smaller scale somewhat closely the main architectural features of the permanent dentition. They differ in the following particulars: their general smallness; their rounded, short coronal surfaces; their great disparity in size with one another, particularly in case of the second incisor and second molar; the universal simplicity of their coronal patterns, and unusually constricted necks, due, not to an elevation of the enamel but to a curious outward bending of the dentin beneath.

The *incisors* are remarkable in that their labial and lingual surfaces are broader from side to side than from above downward, those of the first incisor being nearly twice the width of the other two. This is particularly noticeable in the maxillary arch. The outermost incisors are very conical in shape. The *canines* have broader crowns than the incisors. The roots of the maxillary teeth are extremely long, measuring nearly twice the length of those of the first incisors. The *first molars* may frequently be mistaken for a small first premolar. All molars possess five surfaces which correspond in name with those of the permanent series. The crowns usually are smaller than those of the second molars, but may on occasion be larger. Each possesses one large inner cusp and the three small tubercles, or two cusps arranged as a buccal ridge. The central sulcus is shallow and may bifurcate toward the outer side. Its three roots are smaller than in the second molar and widely divergent.

The crowns of the *second molars* possess four well-marked cusps, of which the largest is either the antero-internal or the antero-external, the oblique ridge being well developed and running in the same direction as in the permanent teeth. The mandibular second molar has five cusps, three on the buccal and two on the lingual side, the

smallest usually being the postero-buccal. The two roots are short, widely separated, fairly straight and laterally flattened.

The teeth vary in *size*[13] from 3.8 mm. in the mandibular first incisor to 8.5 mm. in the second maxillary molar.

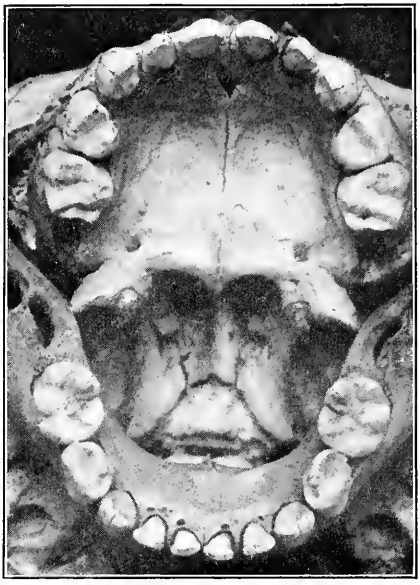

FIG. 23.—The occlusal surfaces of the deciduous teeth *in situ*.

Calcification occurs approximately as follows: The first and second incisors about the fourth month of intra-uterine life; the canine and first molar about the fifth, and the second molar about the fifth to the sixth month. At birth calcification has proceeded to the extent of the formation of half the crown of the first incisor, one-third of that of the second incisor, one-sixth of that of the canine, the upper part of that of the first molar and the cusps of the second molar. They erupt in the following order: first incisor, second incisor, first molar, canine and second molar and at the following approximate dates after birth: first incisor from the sixth to tenth month, second incisor from the eighth to twentieth month, canine fifteenth to the thirty-third month, first molar twelfth to the twenty-sixth month and second molar twenty-eighth to the thirtieth month.

VI. RELATIONSHIPS.

The Dental Arches.—In shape the upper is elliptical, the lower assuming a parabolic curve. The maxillary teeth in normal occlusion

slightly overlap the mandibular teeth. The curve of von Spee, produced by a slight concavity in the plane of the occlusal surfaces of

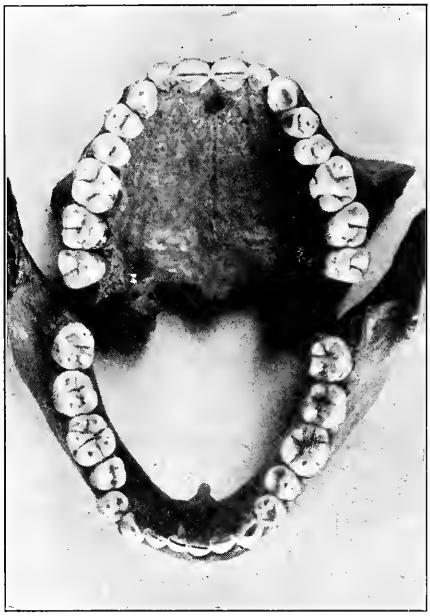

FIG. 24.—Semi-elliptical maxillary and mandibular dental arches—a condition which obtains in 20 per cent. of cases.

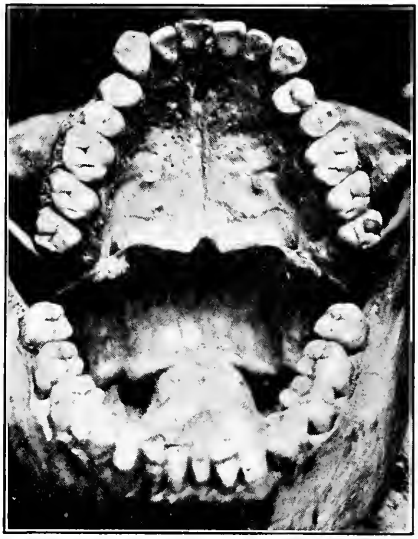

FIG. 25.—The divergent arch—a condition which obtains in 6 *per cent.* of cases.

the mandibular teeth and a corresponding convexity in that in the maxillary organs, is not always present; it is probable that the normal arrangement of the parts is for both occlusal surfaces to lie in a horizontal plane.

The Vascular System.—The vascular system is derived from the internal maxillary artery. The *anterior dental* branch of the infra-orbital division of the third or ultimate stage supplies the maxillary incisors and canines, the *posterior dental* branch the premolars and molars.

FIG. 26.—The hyperbolic arch—a condition which obtains in 4 *per cent.* of cases.

In the lower jaw the *mandibular* or *inferior dental artery* supplies all the teeth, a special branch—the *incisive*—passing directly to the incisors and canines.

The Nervous System.—The *trigeminal* or *trifacial* nerve—the largest of the cranial nerves, sensory in its upper two divisions and sensory and motor in its lower third division—endows the teeth with sensation. The *antero-superior dental* nerve is distributed to the maxillary incisors and canines, the *middle dental* to the premolars and the *posterior dental* to the molars.

The *mandibular* or *inferior dental* nerve is in relation with the molars, premolars and canines in its posterior part, while anteriorly it transmits an *incisive* branch to the incisors.

The Lymphatic System.—There is no direct connection between the pulps of the teeth and the lymph nodes of face and neck, but the afferent channels and vessels of the gingival tissues, in common with those of the cheeks, lips and anterior part of the tongue, communicate with four or five submaxillary nodes found in the submaxillary triangle on the surface of the submaxillary gland. They all discharge their streams into the superficial and deep cervical nodes which accompany the external and internal jugular veins respectively.

BIBLIOGRAPHY.

1. Albrecht: "Bec-de-lièvre," Société d'Anthropologie, Bruxelles, 1882.
2. Black, G. V.: "Descriptive Anatomy of the Human Teeth," 1902.
3. Black, G. V.: "A Work on Operative Dentistry," 1908, vol. i.
4, 5, 6 and 7. Bland-Sutton: "Tumors, Innocent and Malignant," 1906.
8. Bolk: "Die Ontogenie der Primatenzähne (Odontolog. Studien L), 1913.
9. Broomell and Fischelis: "Anatomy and Histology of the Mouth and Teeth," 1914.
10. Colyer, J. F.: "John Hunter and Odontology," 1913.
11. Cope: "The Tritubercular Molar in Human Dentition." Journal of Morphology, 1888.
12. Cryer: "The Internal Anatomy of the Face," 1916.
13. Dolamore: "The Relation of the Deciduous to the Permanent Dentition." Royal Dental Hospital Gazette, 1908.
14. Forsyth Major: "On some Miocene Squirrels, with Remarks on the Dentition and Calcification of the Sciurinæ." Proc. Zoöl. Soc., London, 1893.
15. Gray: "Anatomy: Descriptive and Applied," edited by E. A. Spitzka, 1913.
16, 17. Hopewell-Smith: "The Normal and Histological Pathology of the Mouth," 1918.
18. Hopewell-Smith: "An Introduction to Dental Anatomy and Physiology," 1913.
19. James, W. W. and Pitts, A. T.: "Some Notes on the Dates of Eruption in Four Thousand Eight Hundred and Fifty Children, Aged Under Twelve," Proc. Roy. Soc. Med., 1912.
20. Kukenthal: "Zur Dentitionfrage," Anatom. Anzeiger, 1895.
21. Leche: Morph. Jahrbuch, 1892. Biblio-theca Zoölogica, 1895.
22. Marett Tims: "Evolution of the Teeth in the Mammalia." Jour. Anat. and Phys., 1903.
23. Osborn: "Evolution of the Mammalian Molars to and from the Tritubercular Type." Amer. Naturalist, 1888.
24. Piersol: "Human Anatomy," 1918.
25. Röse: "Ueber die Enstehung und Formabänderungen der Menschlichen Molaren. Anat. Anzeiger, 1892.
26. Tomes, C. S.: "A Manual of Dental Anatomy," seventh edit., 1914.
27. Virchow: "Retention, Heterotypie und Ueberzahl von Zähnen." Verhand. d. Berliner anthrop. Gesellschaft, 1886.

CHAPTER II.

DENTAL HISTOLOGY, WITH REFERENCE TO OPERATIVE DENTISTRY.[1]

By FREDERICK B. NOYES, B.A., D.D.S.

In the fifteen years or more that have elapsed since this chapter was prepared for the third edition of this work, there have been important additions to our knowledge of the structure of the teeth and their supporting tissues. But more important even than these additions and changes in our knowledge of the facts are the development in the dental profession and the recognition of the relation of the mouth conditions to general systemic conditions and the health of the individual. This development has changed the interest in dental histology from one field to another.

When the chapter was first written dental histology was being studied chiefly in its relation to the technical procedures of operative dentistry and we may say with fairness that the study of the structure of the enamel with reference to dental caries and the preparation of cavities was its most important phase. The study of the microscopic structure of the enamel of the tooth crown greatly improved the preparation of cavities, increased facility and rapidity of operation and also improved the resulting filling operations. The facts are just as important as ever but to a great extent they have already made their imprint upon dental practice.

Today the most important question before the dental profession, and the one in which the medical profession is most interested, is the fate of the pulpless tooth and the relation of pathologic condition of the supporting tissues to the health of the organism as a whole. Dental histology must be studied from this point of view, and when the facts, so far as they are known, are reviewed from this standpoint, our knowledge is found to be deplorably inadequate and defective. The rational solution of the relation of the pulpless tooth to the human organism cannot be reached until our knowledge of structural facts has been greatly extended. It is important, however, to review the facts as

[1] In the preparation of this material I am indebted to Dr. G. V. Black for the use of his large and valuable collection of microscopic slides, and for much advice and many suggestions.

they are now known with reference to these problems. They are not new problems, but the focus is now centered upon them.

From the standpoint of comparative anatomy, the teeth are found to be not a part of the osseous system, but appendages of the skin, and are to be compared with such structures in the body as the nails and the hair. The teeth are a part of the exo-skeleton, and their relation to the bones of the endo-skeleton is entirely secondary, for the purpose of strength, the bone growing up around the tooth to support it.

If we examine the skin of such an animal as the shark, we find the entire surface covered with small calcified bodies which are really small, simple, cone-shaped teeth. The mouth cavity is to be regarded,

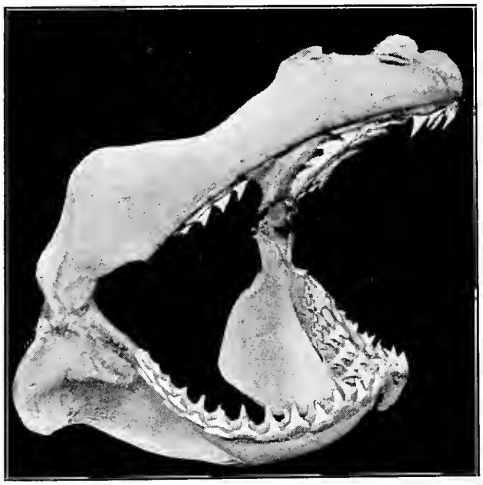

FIG. 27.—Shark's skull (Lamna cornubica), showing succession of teeth.

when viewed in the light of its development, as a part of the outside surface of the body which has been enclosed by the development of the neighboring parts, and the dermal scales or rudimentary teeth which were found in the skin covering the arches which form the jaws have undergone special development for the purposes of seizing and masticating the food. In the simplest forms there is only a development in size and shape of these scales, and they are supported only by the connective tissue which underlies the skin. These teeth are easily torn off in the attempt to hold a resisting prey, and, as in the shark, they are constantly being replaced by new ones (Fig. 27). In the more highly developed forms there is a growth of the bone of the arch forming the jaw upward around the bases of these scale-like teeth, to support them more firmly and render them more useful.

If we compare the structure of the hair with that of the tooth, we find in the case of the hair a horny structure formed by epithelial cells resting upon a papilla of connective tissue; in the case of the tooth, a calcified structure formed by epithelial cells resting upon a papilla of connective tissue which is also partially calcified.

The relation of the bones of the jaws to the teeth is entirely a secondary and transient one. The bone grows up around the roots of the teeth to support them, and is destroyed and removed with the loss of the teeth or the cessation of their function. In this way the develop-

FIG. 28.—Changes in the mandible with age; buccal and lingual view.

ment of the alveolar process takes place around the temporary teeth; all of this bone surrounding their roots is absorbed and removed with the loss of the temporary dentition, and a new alveolar process grows up around the roots of the permanent teeth as they are formed. This development of bone around the roots of the teeth leads to the changes in the shape of the body of the lower jaw, increasing the thickness above the mental foramen and the inferior dental canal. When the teeth are finally lost this bone is again removed and the body of the jaw reduced in thickness from above downward (Fig. 28). These phenomena are of importance in their bearing upon the causes and treatment of diseased

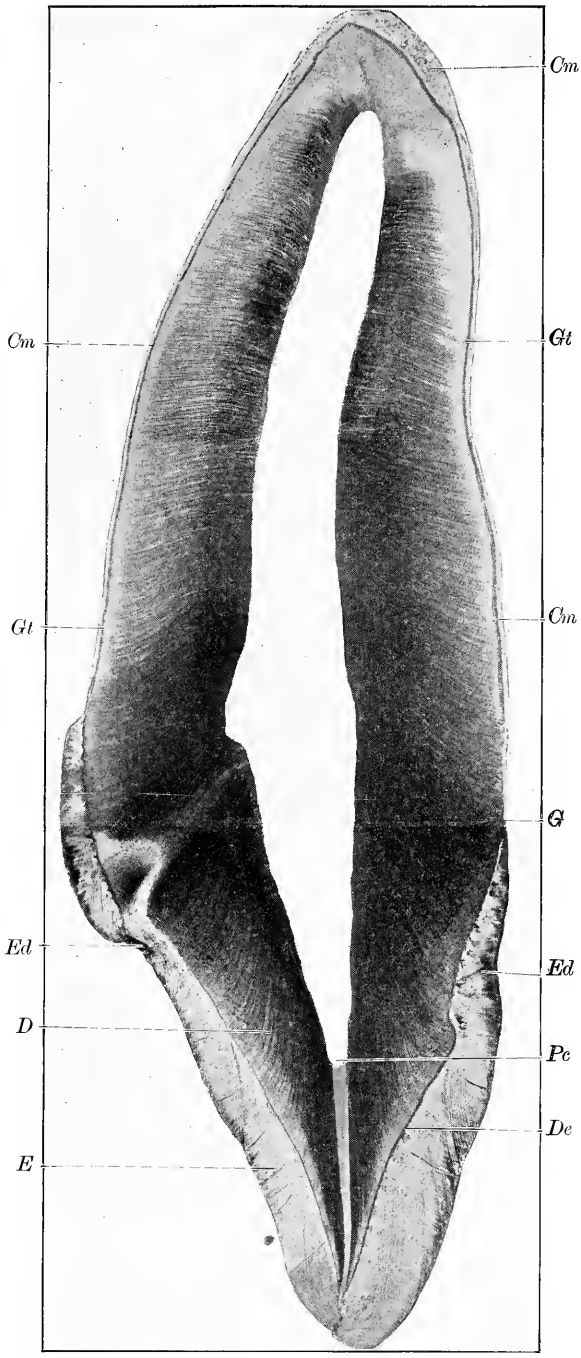

FIG. 29.—Ground section of a canine: *E*, enamel; *Cm*, cementum; *D*, dentin; *Pc*, pulp chamber; *De*, dento-enamel junction; *Ed*, enamel defect; *G*, junction of enamel and cementum at the gingival line; *Gt*, granular layer of Tomes. (Reduced from photo-micrograph made in three sections.)

conditions of the teeth, particularly those which involve the supporting tissues.

Dental Tissues.—The human teeth are made up of four tissues (Fig. 29).

1. The enamel covers the exposed portion of the tooth, or crown, and gives the detail of crown form. Its function is to protect the tooth against the wear of friction.

2. The dentin forms the mass of the tooth and determines its class form, the number of cusps and the number of roots being indicated by the dentin form.

3. Cementum covers the dentin beyond the border of the enamel, overlapping it slightly at the gingival line and forming the surface of the root. Its function is to furnish the attachment of the fibers of the peridental membrane, which fasten the tooth to the bone.

4. The pulp or soft tissue filling the central cavity in the dentin is the remains of the formative organ which has given rise to the dentin. Its functions are the formation of dentin and a sensory function.

In describing the structure of the teeth and the arrangement of the structural elements of the tissues, directions are described with reference to three planes:

The mesio-disto-axial plane, a plane passing through the center of the crown from mesial to distal and parallel with the long axis of the tooth.

The bucco-linguo-axial plane, a plane passing through the center of the crown from buccal to lingual and parallel with the long axis of the tooth.

The horizontal plane, at right angles to the axial planes.

The Supporting Tissues.—The human teeth are supported on the maxillary bones, their alveolar processes growing up around the roots of the teeth, so that the roots fit into the holes in the bone. The calcified structures of the tooth and bone are not, however, united, but the roots are surrounded by a fibrous membrane, the peridental membrane, or pericementum, which fastens the tooth to the bone.

ENAMEL.

The enamel differs from all other calcified tissues in the nature of the structural elements of which this tissue is made up, in the degree of calcification, and in origin, being the only calcified tissue derived from the epiblast.

The enamel is formed from an epithelial organ derived from the epithelium of the mouth cavity and indirectly from the epiblastic germ layer, while all other calcified tissues are products of the meso-

blast. In the case of bone and dentin, the formative tissue is persistent. It is possible in the bone at least, therefore, to have degenerative and regenerative changes, or the removal of part of the calcium salts and their replacement through the agency of the formative tissue; while in the enamel no such regenerative change is possible, as the formative tissue disappeared when the tissue was completed and before the eruption of the tooth.

The enamel is the hardest of human tissues. Chemically it is composed of the phosphates and carbonates of calcium and magnesium and a very small amount of the fluorids, water, also a very small amount of organic matter, if any.[1] The enamel in the natural condition, bathed in the fluids of the mouth, contains a considerable amount of water. If dried at a little above the boiling-point of water, it gives up part of it and shrinks considerably, so as to crack in fine checks. If heated almost to redness, it suddenly gives off from 3 to 5 per cent. (of the dry weight) of water with almost explosive violence. These facts were demonstrated some years ago by Charles Tomes,[2] and account for most of what was formerly recorded as organic matter in old analyses.

If we observe under the microscope the action of acids upon thin sections of enamel, when the inorganic salts are entirely removed, the structure of the tissue vanishes, there being no trace of organic matrix left as in the case of bone or dentin. In the growth of bone and dentin the formative tissue produces first an organic matrix in the form of the tissue, and into this inorganic salts are deposited, combining with the organic substances of the matrix. This union is comparatively weak, however, for by the action of acids the combination is broken up and the inorganic salts are dissolved; or by heat the organic matter is removed, and in either case the form of the tissue will be maintained.

In the case of the enamel, the formative organ produces organic substances containing inorganic salts, and the substances are arranged in the form of the tissue after the manner of a matrix; but finally, under the action of the formative organ all of the organic matter is removed and substituted by inorganic salts, whatever organic matter is found in the fully formed tissue being the result of imperfect execution of the plan.

[1] von Bibra gives the following analysis of enamel:

Calcium phosphate and fluorid		89.82
Calcium carbonate		4.37
Magnesium phosphate		1.34
Other salts		0.38
Cartilage		3.39
Fat		0.20
Total organic	3.59	
Total inorganic	96.41	

[2] Journal of Physiology, 1896.

The enamel is composed of two structural elements, the *enamel rods*, or prisms, sometimes called enamel fibers, and the *interprismatic* or *cementing substance*, both of which are calcified. It is to the arrangement of these structural elements that the characteristics of the tissue with which we are most concerned in operative procedures are due.

While both the prisms and interprismatic substances of the enamel are calcified, or, better, composed of inorganic salts, the two substances —that is, the substance of the rods and the substance between the rods—show markedly different properties both chemical and physical. If treated with acid, the interprismatic substance is acted upon more rapidly than the rods, so that the latter become more conspicuous.

FIG. 30.—Isolated enamel rods. (About 1000 ×.)

By this means sections of the enamel may be etched to render it easier to study the direction and arrangement of the rods. If the action of the acid is carried far enough, the rods will fall apart before they are themselves entirely dissolved. Fig. 30 is from the debris in a carious cavity, and shows rods isolated by the action of the acids of caries.

The interprismatic substance is not as strong as the rods, so that in splitting or breaking the enamel the tissue separates on the lines of the cementing substance, occasionally breaking across a few rods but following their general direction, the lines running between rods, not at their centers.

In cleaving the enamel the chisel does not enter the tissue separating rod from rod, but the edge engages with the surface, and the force

applied at an acute angle with the direction of the rods fractures the tissue in the lines of least resistance. If the edge be keenly sharp, it will enter the tissue slightly, and then the bevel acts as a wedge in addition to the force applied to the shaft of the instrument; but if the edge be dull, it will rest across the ends of many rods, will not engage with the surface, and the force applied will break and crumble the tissue but will not cleave it.

The enamel rods, or prisms, are long, slender prismatic rods or fibers, five- or six-sided, pointed at both ends and alternately expanded and constricted throughout their length. They are from 3.4 to 4.5 microns[1] in diameter, some of them apparently reaching the entire distance from the surface of the dentin to the surface of the enamel; but as the diameter of the rods is the same at their outer and inner ends, and as the crown surface is much greater than the surface of dentin covered by enamel, there are many rods which do not extend through the entire thickness. These short rods end in tapering points between the converging rods which extend the entire distance. To express this in terms of development: as the formation of enamel begins at the surface of the dentin, the increasing area of crown surface requires more ameloblasts, and as new ameloblasts take their place in the layer, the formation of new enamel rods begins between the rods which were previously forming. These short rods are most numerous over the marginal ridges and at the points of the cusps, and will be considered more fully in connection with those positions.

In ground sections cut at right angles to the direction of the rods,[2] the tissue has the appearance of a mosaic floor, the outline of the rods being more distinct if they have been marked out by treating the section slightly with acid (Fig. 31). In longitudinal sections (Fig. 32) the sides of the rods are not smooth and even like the sides of a lead pencil, but are alternately expanded and constricted. They are well illustrated by taking balls of soft clay and sticking them together one above another to form a rod, then putting a number of rods together so that by mutual pressure they take hexagonal forms. This illustrates also the manner of growth of the tissue in formation. The expansions and constrictions can be seen in rods that have been scraped from a cleaved surface of enamel, but better by isolating rods by the slight action of dilute acid (Fig. 33).

In the construction of the tissue the rods are so arranged that the expansions of one rod come opposite to the expansions in the adjoining

[1] A micron is the unit of microscopic measurement, and is equal to one-thousandth of a millimeter.

[2] In describing the direction of enamel rods they are always considered as extending from the dentin to the surface, and the angle is formed at the surface of the dentin with the locating plane, either horizontal or axial.

rods, and do not interlock with their constructions. This arrangement leaves alternately a greater and a less amount of cementing substance between them.



FIG. 31.—Transverse section of enamel rods. (About 80 ×.)



FIG. 32.—Enamel rods in thin etched section. (About 800 ×.)

When observed under the microscope, the enamel rods show a characteristic appearance of light and dark lines running across them. These markings are similar to the striations of voluntary muscle fibers,

and are described as the striation of the enamel. It is seen not only in isolated rods, but also in sections ground in their direction (Fig. 34). This appearance of striation in the enamel is caused by the alternate

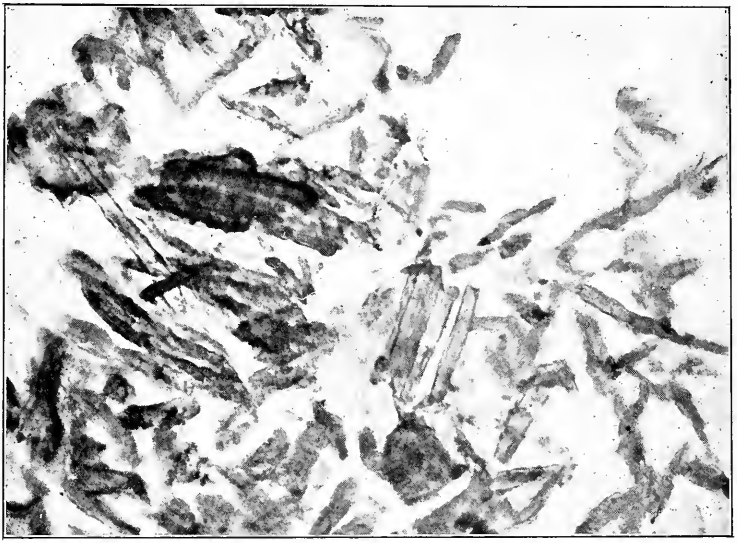

FIG. 33.—Enamel rods isolated by scraping. (About 800 ×.)



FIG. 34.—Enamel showing striation. (About 1000 ×.)

expansions and constrictions of the rods refracting the light like a lens. In sections the expansions in adjoining rods are opposite to each other, the difference in the refracting power of the prismatic and interprismatic substances producing the same effect.

The appearance of striation is the record in the fully formed tissue of the manner of growth, each dark stripe, or expansion, in a rod representing a globule of partially calcified material. The ameloblasts build up the rods by the addition of globule after globule, surrounding them with a cementing substance and completing the calcification of both. In this sense the striation of the enamel may be said to record the growth of the individual rods.

While the enamel is a very hard substance when its structure is complete and perfect, its most striking physical characteristic is a tendency to split or crack in the direction of its structural elements when a break has been made in the tissue. While it is difficult to cut across the rods or make an opening on a perfect surface, if a break has



FIG. 35.—Enamel showing direction of cleavage. (About 70 ×.)

been established it is comparatively easy to split off the tissue from the sides of the opening when the rods lie parallel with each other. Fig. 35 shows a field of enamel illustrating the way in which the tissue splits or cleaves in the direction of the rods.

Upon the axial surfaces the enamel rods are usually straight and parallel with each other, except where there has been some flaw or disturbance in development; but upon the occlusal surface, although sometimes straight, they are very often much twisted and wound round each other, especially at their inner ends. This difference in the arrangement of the rods causes the greatest difference in the feeling of the tissue under cutting instruments. Such a specimen of enamel as shown in Fig. 36 can be cut away easily, the tissue breaking through to the dentin and splitting off in chunks; while a specimen like Fig. 37 will



FIG. 36.—Straight enamel rods. (About 80 ×.)

FIG. 37.—Gnarled enamel. (About 80 ×.)

not cleave if supported upon sound dentin. If the outer ends of the rods are straight, they will split part way to the dentin (Fig. 38); but where they begin to twist round each other they will break across the rods. If the dentin is removed from under such enamel, it will break in an irregular way through the gnarled portion.

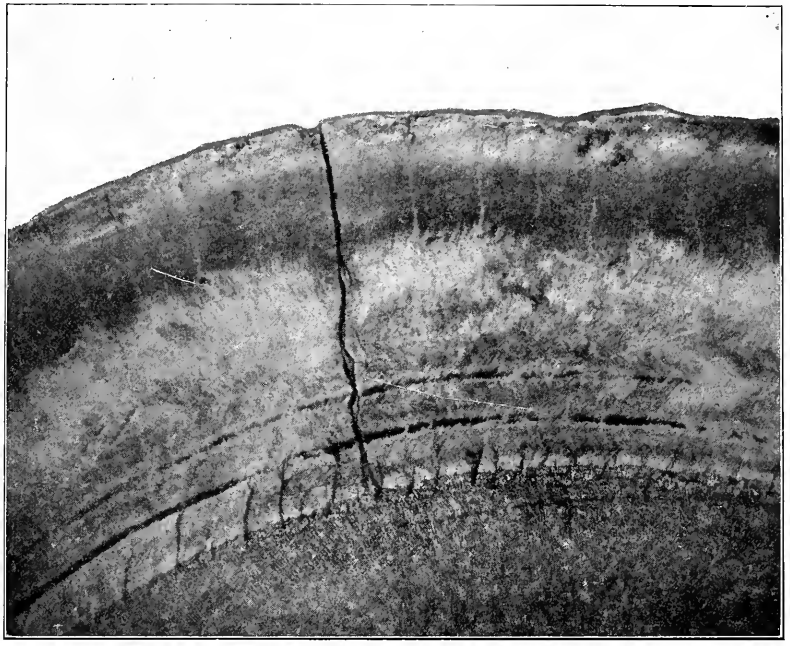

FIG. 38.—Gnarled enamel. (About 50 ×.)

From a study of the arrangement of the enamel rods in the formation of the crown it is apparent that the plan is such as to give the greatest strength to the perfect structure, and may be likened to an arch. At the gingival border the rods are short and are inclined apically 6 to 10 centigrades[1] (20° to 35°) from the horizontal plane. These short rods

[1] In the centigrade division the circle is divided into one hundred parts, each called a centigrade. One centigrade is equal to 3.6 degrees of the astronomical circle, 25 centigrades to 90 degrees, 12 centigrades to 45 degrees. The cut gives a comparison of the two systems of measuring angles.

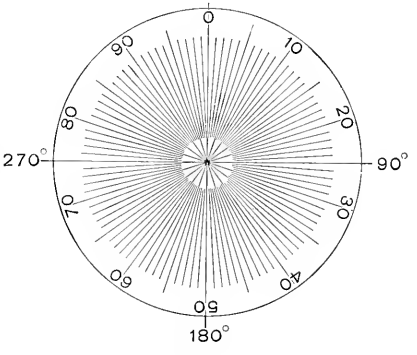

Centigrade division.

are overlapped for a short distance by the cementum. This inclination grows less and less, and at some place in the gingival half of the middle third of the surface they are in the horizontal plane. At this point they are also usually perpendicular to the surface of the dentin. Passing from this point they become inclined more and more occlusally from the horizontal plane, at the junction of the occlusal and middle thirds about 8 to 12 centigrades (28° to 40°) in bicuspids and molars, and 8 to 18 centigrades (28° to 65°) in incisors and canines. In the occlusal third the inclination increases rapidly, and often the outer

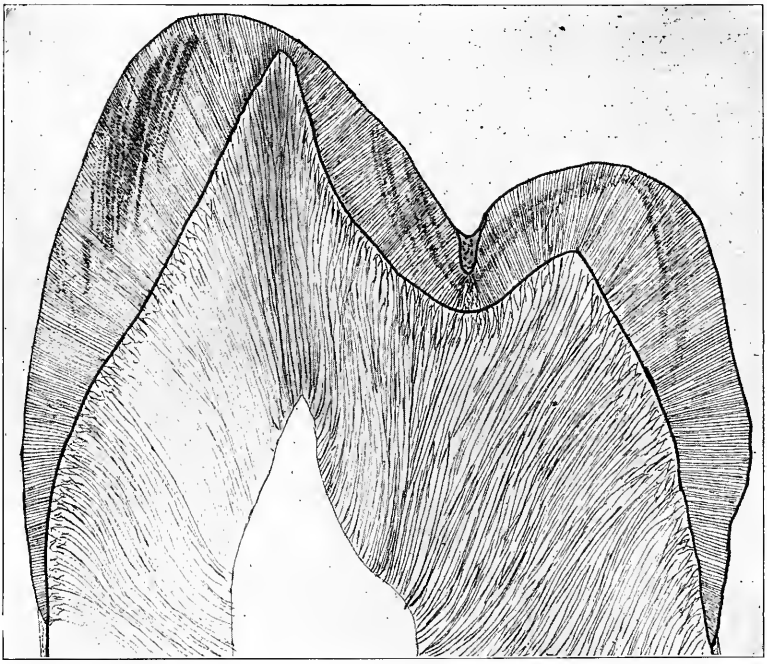

FIG. 39.—Diagram of enamel rod directions, from a photograph of a bucco-lingual section of an upper bicuspid.

ends of the rods are inclined more than the inner ends. Over the point of the cusps and the crest of the marginal ridges the rods reach the axial plane, though they are often very much twisted about each other in the inner half of their length. This position does not always correspond with the highest point of the cusp, but is inclined slightly axially from that position, and corresponds with the highest point of the dentin cusp.

Passing down the central slope of the cusp, or ridge, the rods become again inclined away from the axial plane toward the groove, or pit,

leaning toward each other where the two plates meet. The degree of inclination of the rods on the central slope of the cusps depends upon the height of the cusps; the higher the cusp the greater the inclination from the axial plane. Fig. 39, a diagram from a photograph of a bucco-lingual section of an upper bicuspid, shows the plan of arrangement and illustrates the arch principle in the construction.

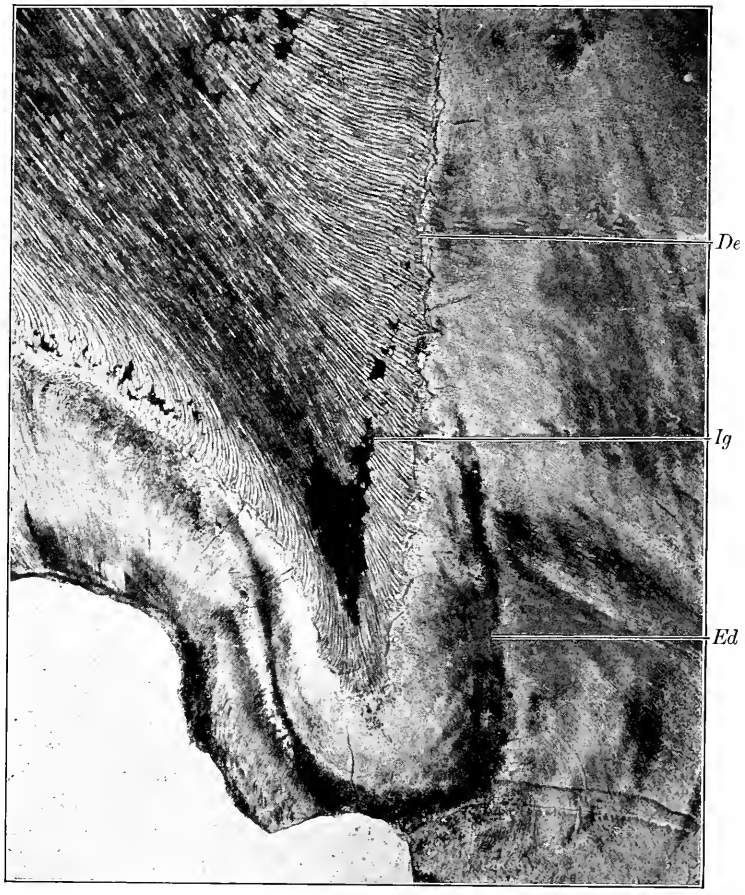

FIG. 40.—Stratification of enamel; the cusp of a bicuspid: *De*, dento-enamel junction; *Ed*, enamel defect showing in the heavy stratification band; *Ig*, interglobular spaces in the dentin. (About 40 ×.)

In the study of longitudinal sections of the teeth, one of the most conspicuous structural features is the stratification bands or brown bands of Retzius. These bands are not parallel with either the outer surface of the enamel or the dento-enamel junction. They begin at the tip of the dentin cusps and sweep around in larger and larger zones.

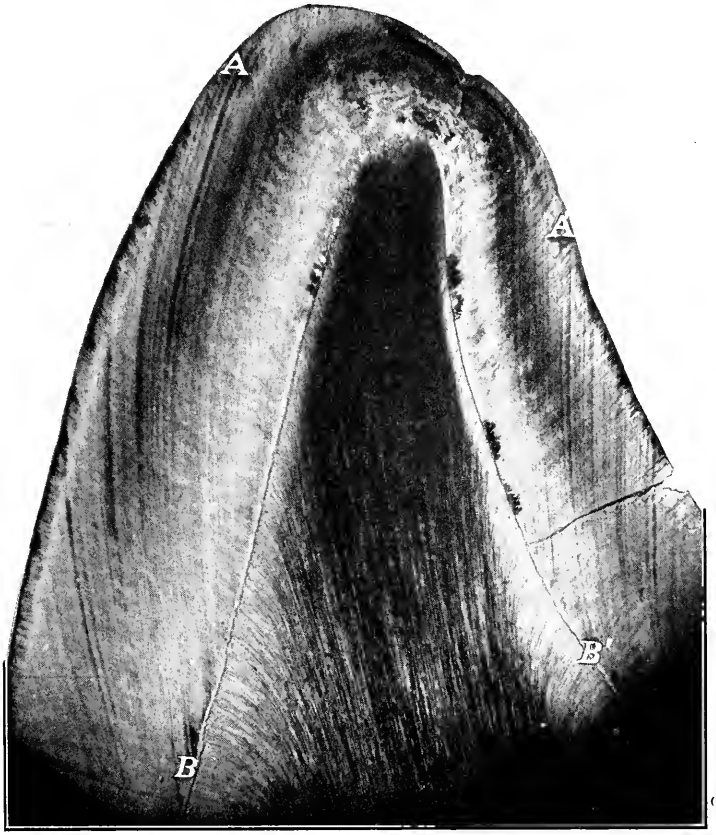

FIG. 41.—Incisor tip showing stratification or incremental lines. Rods at *A* were fully formed at the time the rods at *B* were beginning to form. (About 50 ×.)



FIG. 42.—Enamel showing both striation and stratification. (About 80 ×.)

These stratification bands are better seen in comparatively thick sections, and are caused by the varying amount of pigment deposited with the calcium salts in the development of the tissue. They record the growth of enamel of the crown as a whole, as each line was at one time the surface of the enamel cap. These stratifications, or better, incremental lines, are shown in Fig. 40.

At the time the rod at *A* (Fig. 41) was completely formed the rod at *B* was just beginning to form at its dentinal end. From this it would seem that any structural defect due to imperfect development would not follow the direction of the enamel rods from the surface to the dentin, but would follow the stratification lines; and if these structural defects influenced the penetration of caries, we should expect to have the direction of penetration modified. Fig. 42 shows a structural defect in the enamel over a cusp following the stratification band, and it will be noticed also that there is a structural defect in the dentin at a corresponding position.

HISTOLOGICAL REQUIREMENTS FOR STRENGTH IN ENAMEL WALLS.

1. The enamel must be supported upon sound dentin.
2. The rods which form the cavo-surface angle must run uninterruptedly to the dentin and be supported by short rods, with their inner ends resting on the dentin and their outer ends abutting upon the cavity wall, where they will be covered in by the filling material.
3. That the cavo-surface angle be cut in such a way as not to expose the ends of the rods to fracture in condensing and filling material against them.

In thinking of the supporting tissues it has been too much the habit to think of the bone and the fibrous tissues as separate entities or anatomically distinct things. Instead of this point of view, the supporting tissues should be thought of as a connected tissue organ of support, part of which is calcified for the purpose of rigidity. The bone of the alveolar process, the fibrous tissue of the peridental membrane, periosteum and septal tissue should be thought of as only parts of a whole which function as an organ of support to the denture, sustaining the teeth in their function and keeping the epithelium in proper relation to the teeth for the protection of the supporting tissues from injury and infection.

The first step, then, in the preparation of an enamel wall is to determine the direction of the enamel rods by cleavage with a chisel or hatchet. In Fig. 43, No. 1 shows an enamel wall after cleaving the enamel with a hatchet. It will be noticed that the split has not followed the



FIG. 43.—Preparation of enamel wall in straight enamel: 1. Enamel wall as cleaved, showing breaking across rods. 2. Wall smoothed but not extended; some rods do not reach the dentin, but their inner ends are cut off at *b*. 3. Correctly trimmed and the cavo-surface angle slightly beveled. The inclination of the enamel rods is too great to make a good enamel wall in this position. *c*, cavo-surface angle; *De*, dento-enamel junction; *D*, dentin; *b*, point at which inner ends of rods are cut off. (About 80 ×.)

direction of the rods exactly, but has broken across them, slivering the rods as wood slivers in splitting. This would cause in the cut surface a whitish, opaque appearance. The plane of the enamel wall should



FIG. 44.—Preparation of enamel wall in gnarled enamel: 1, Enamel wall as cleaved, showing breaking across rods and slivering at *a*. 2, Wall as smoothed but not extended to remove short rods whose inner ends are cut off at *b*. 3, Wall extended and trimmed to a position of strength. *D*, dentin; *De*, dento-enamel junction; *c*, cavo-surface angle; *b*, point where inner ends of rods are cut off; *a*, slivering of the tissue. (About 80 ×.)

be extended so as to form a small angle with the plane of the dental wall, by shaving the surface with a very sharp hand instrument. No. 2 shows the same wall after it has been extended somewhat; but it

will be seen that it has not been extended enough, for the rods forming the surface at *A* do not reach the dentin, but run out at *B* on the cavity wall, and that piece would chip out in packing against it or if force came upon the surface afterward. The angle should be extended so as to produce the plane shown in No. 3; then the cavo-surface angle may or may not be beveled as the position demands.

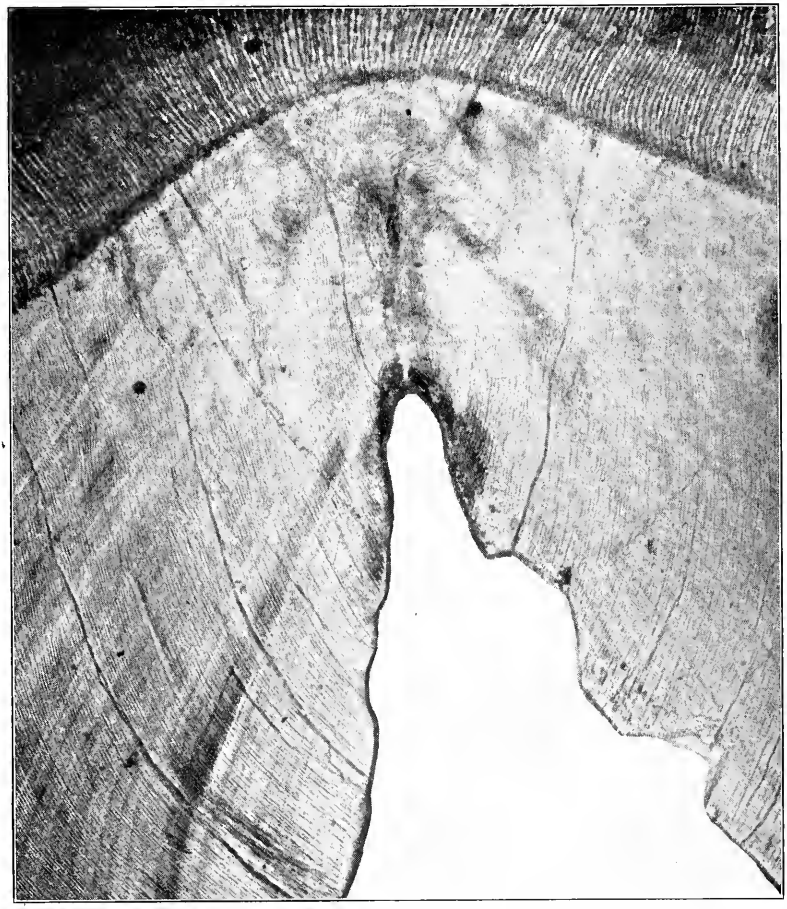

FIG. 45.—Occlusal fissure in an upper bicuspid, showing direction of rods. (About 80 ×.)

With reference to the direction of the enamel rods in relation to the cavity, enamel walls may be divided into two classes: (1) those in which the rods are inclined toward the cavity, characteristic of grooves, fissures, and pits; and (2) those in which the rods are inclined away from the cavity, characteristic of cavities beginning on smooth axial surfaces. In the first it is easy to obtain the structural requirements for

a strong wall. In the second it is comparatively difficult. It is important to remember that strength is measured by the degree to which the structural requirements are attained.

Grooves, fissures, and pits are always positions of weakness, and when a cavity approaches a groove or pit, a good margin, histologically, cannot be prepared without cutting beyond it. Fig. 45 shows an

FIG. 46.—Bucco-lingual section of upper bicuspid; enamel is broken from grinding: *A* to *B*, area of weakness for enamel margins. (About 20 ×.)

occlusal fissure in a bicuspid, which illustrates the conditions of structure characteristic of these positions. The rods are inclined toward the fissure, and between the bottom of the fissure and the dentin are very irregular. If a cavity wall were made to approach this fissure from the lingual side, so as to come to the dotted line, the wall would have to be inclined 6 to 8 centigrades (20° to 28°) from the axial plane toward the fissure, and then the cavo-surface angle beveled, when the conditions

would be similar to those in the wall of an axial surface cavity, and not as strong as the location requires. Not only is this true, but it also leaves a vulnerable point next to the margin of the filling—a point of

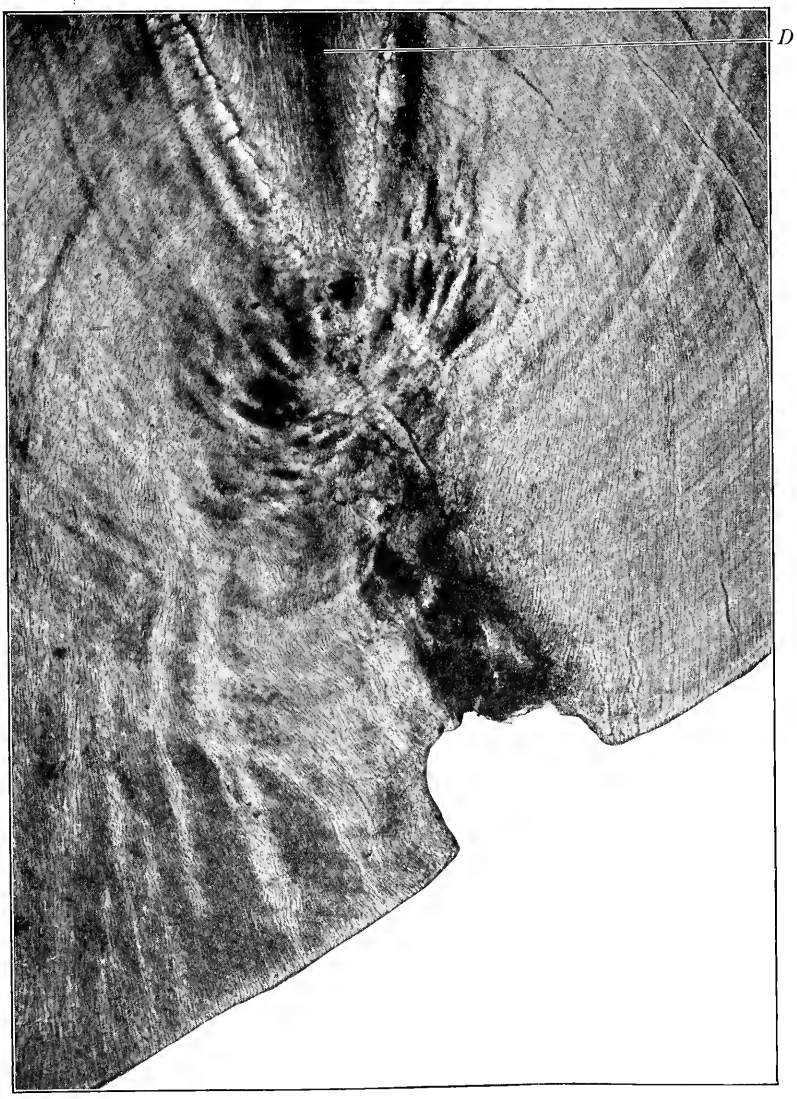

FIG. 47.—Enamel over tip of dentin cusp: *D*, dentin cusp. (About 80 ×.)

liability. Cutting just beyond the fissure, the wall may be left in the axial plane and have an ideally strong margin, and the point of liability is removed. To state the conditions in general terms, a strong margin

is more easily obtained where enamel rods are inclined toward the cavity than where they are inclined away from the cavity.

The points of cusps and the crests of marginal ridges are positions of strength in the perfect tissue; but when a cavity margin approaches them they become points of weakness, because it is impossible to support properly the rods which form the margin. Over the marginal ridges are many short rods which do not reach the dentin, and these are usually very much twisted about each other, so as to form the strongest possible keystone in the perfect structure. In preparing a margin in such a position it is impossible to have the rods which form the margin reach the dentin with their inner ends, and these short rods are sure to break in completing the operation or to break out later. The arrangement of enamel rods in such positions is to be borne in mind, especially when extending approximate cavities in incisors toward the lingual side and in large pit cavities in incisors. A similar condition is found over the points of the cusps. Fig. 46 shows a bucco-lingual section of an upper bicuspid. It will be noticed that the rods forming the point of the cusp are not in the axial plane, and do not reach the tip of the dentin cusp, but reach the dentin a little way down on the outer slope. The enamel covering the tip of the dentin contains many short rods, and they are very much twisted about each other, so that the area from *A* and *B* to the point of the cusp is an area of weakness for the cavity margins. If the margin reaches this area, the cusp must be cut away and the enamel wall carried out in the horizontal plane. Fig. 47 shows this area more highly magnified, and illustrates the structure. It will be noticed that, in grinding, some of the short twisted rods have broken out of the section.

DENTIN.

Dentin belongs to the connective-tissue group, and is made up of a solid organic matrix impregnated with about 72 per cent. of inorganic salts[1] and pierced by minute canals or tubuli, which radiate from a central cavity which contains the remains of the formative organ, or pulp. The minute canals, or *dentinal tubuli*, are occupied in life by protoplasmic processes from the odontoblastic cells which form the

[1] von Bibra gives the following analysis of dentin:

Organic matter	27.61
Fat	0.40
Calcium phosphate and fluorid	66.72
Calcium carbonate	3.36
Magnesium phosphate	1.08
Other salts	0.83

outer layer of the pulp. Dentin contains two kinds of organic matter, the contents of the tubuli and the organic basis of the matrix.

From a study of microscopic sections it appears that the total volume of the dentinal tubuli amounts to approximately one-tenth of the entire volume of the dentin. The contents of these spaces and its fate are important factors in the question of pulpless teeth. Unfortunately very little is positively known about the contents of the dentinal tubuli. And there is a very great diversity of opinion among the authorities on the subject. During the formation of dentin, it is apparent that protoplasmic projections of the odontoblasts are left in the dentinal tubuli (though this is disputed by some authors, see Hopewell-Smith); but whether this condition is permanent or not is by no means certain. Some authors (Howard Mummery) claim to have demonstrated nerve fibers in the dentinal tubuli; at present the author feels that much work must be done on this subject before the facts are clearly established. In recent study the author has been convinced that in the formation of dentin many cells are enclosed in the matrix but what their fate is and what is their relation to the matrix is not known.

The dentin matrix, after the removal of the calcium salts by acids, yields gelatin on boiling and resembles the matrix of bone, reacting in a similar, though not identical, way with staining agents. The portion of the matrix immediately surrounding the tubuli shows different chemical characteristics from the rest of the matrix, resembling elastin, and resisting the action of strong acids and alkalies after the rest of the tissue has been destroyed. This portion of the matrix surrounding the tubuli and lying next to the fibrils is known as the sheaths of Neumann.

The dentinal tubuli are from 1.1 to 2.5 microns in diameter, and are separated from each other by a thickness of about 10 microns of dentin matrix. This is fairly uniform throughout the dentin. The character of the tubuli is different in the crown and root portions.

In the crown the tubuli branch little through most of their course; but in the outer part, close to the enamel, they branch and anastomose with each other quite freely. Fig. 48 shows a field of dentin just beneath the enamel, as seen with a high power and shows the diameter of the tubuli, their branching, and the amount of matrix between one tubule and the next. The relation of one tubule to another is shown also in sections cut at right angles to their direction (Fig. 49). In the crown portion the tubuli pass from the pulp chamber to the dento-enamel junction in sweeping curves, so as to enter the pulp chamber at right angles to the surface, and end next to the enamel at right angles to that surface. This produces *S*- or *F*-shaped (ς) curves, which are known as the primary curves of the tubuli.

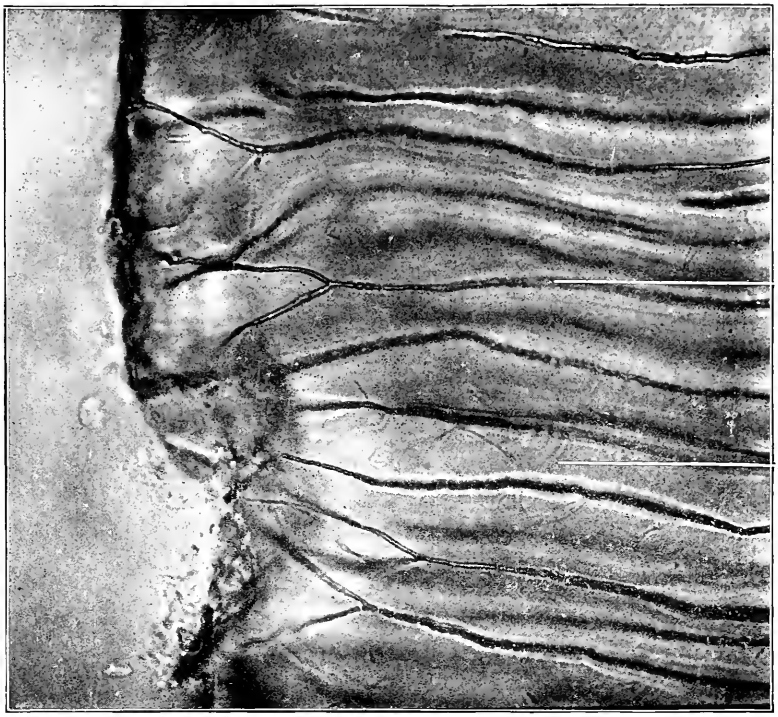

FIG. 48.—Dentin at dento-enamel junction, showing tubuli cut longitudinally: *Dt*, dentinal tubuli; *D*, dentin matrix. (About 760 ×.)

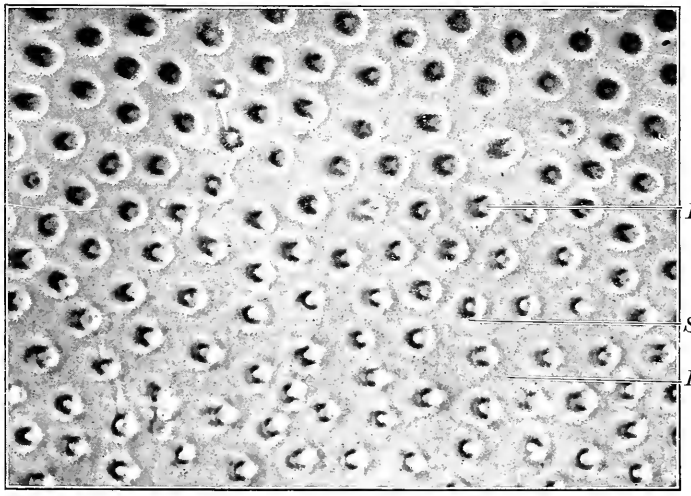

FIG. 49.—Dentin, showing tubuli in cross-section: *Dt*, dentinal tubuli; *D*, dentin matrix; *S*, shadow of sheaths of Neumann. (About 1150 ×.)

Throughout their course the tubuli are not straight, but show a great many wavy curves, known as the secondary curves. These appear as waves when seen in longitudinal sections, but are really the effect of an open spiral direction, as is seen by changing the focus of the microscope in studying sections cut at right angles to the direction of the tubuli. The branches throughout their length are few and small and are given off at an acute angle to the direction of the tubule; but just before the enamel is reached the tubuli fork and branch producing an appearance similar to the delta of a river. These branches are given



FIG. 50.—Crown of a molar, mesio-distal section, showing penetration of caries: *A*, caries penetrating dentin; *B*, line of abrasion; *P*, pulp chamber. (About 20 ×.)

off from the tubuli for some little distance back from the enamel, and they anastomose with other tubuli very freely. The branching of the tubuli in their outer portion causes the spreading of caries. Just beneath the enamel the microörganisms growing through the branches from tube to tube, spread sideways beneath the enamel plates, and penetrate the dentin in the direction of the tubuli. Fig. 50 shows the penetration of caries in the dentin. It will be noticed that in decay starting at the contact point, there has been more spreading under the enamel than in that starting at the gingival line, but in both positions the penetration has followed the direction of the tubuli.

In the root portion the tubuli pass out from the pulp canals at right angles to the long axis of the tooth and pass directly out to the cementum, showing only the secondary curves. Throughout their course they give off a great many fine branches passing through the matrix in all directions from tubule to tubule. These branches are so numerous that in sections which have been mounted in such a way as to leave air in them, or if the tubuli have been filled with coloring matter, they give the impression of looking through a hazel bush; or they may be



FIG. 51.—Dentin from the root, showing tubuli cut longitudinally. (About 700 ×.)

likened to the fine rootlets of a plant. These fine branches are shown in Fig. 51, and the character of the dentin in the root portion is to be compared with that in the crown portion as shown in Fig. 48. The outermost layer of the dentin next to the cementum contains many small irregular spaces, which connect with the dentinal tubuli and give to the tissue when seen with low powers a granular appearance. This layer was first described by John Tomes as the granular layer, and has since been usually called the granular layer of Tomes. The spaces of the granular layer are probably filled by the enlarged ends of the

FIG. 52.—Dento-enamel junction. (About 70 ×.)

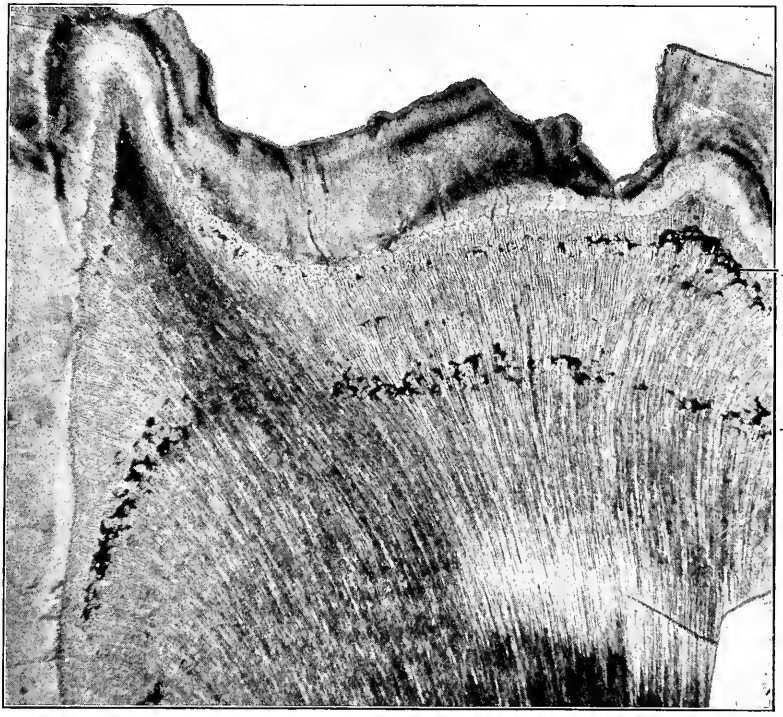

FIG. 53.—Interglobular spaces in dentin: *Ig*, first line of interglobular spaces; *Ig′*, second line of interglobular spaces. (About 30 ×.)

dentinal fibrils. The same appearance is sometimes seen beneath the enamel, but is never as well marked as next to the cementum.

In recent study of material prepared by Dr. Newton G. Thomas and Dr. William S. Skillen the author has been convinced that the spaces in the granular layer of Tomes are formed and occupied by cells enclosed in the formation of the matrix, but whether they are persistent or not seems doubtful.

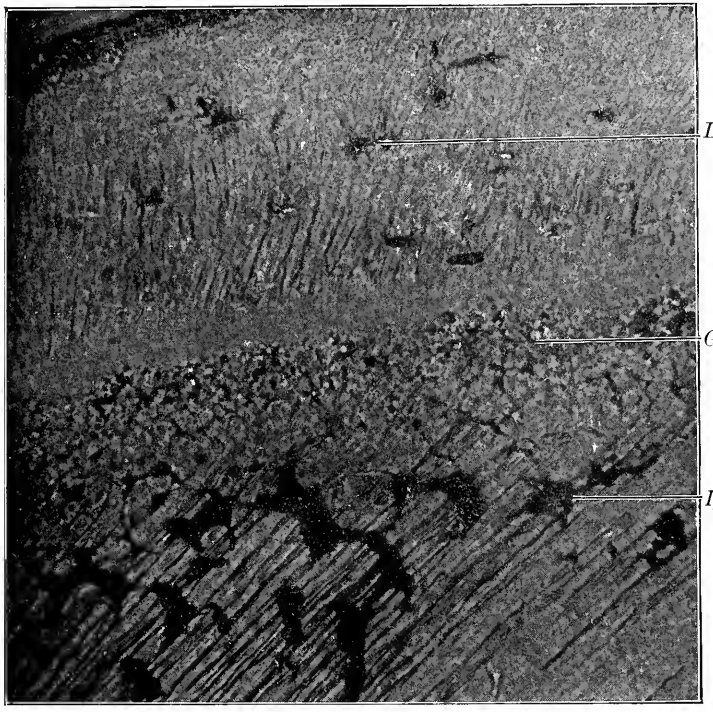

FIG. 54.—Granular layer of Tomes; *L*, lacunæ of cementum; *Gt*, granular layer of Tomes; *Ig*, interglobular spaces. (About 200 ×.)

The dentin at the dento-enamel junction seldom presents a smooth surface, but the inner surface of the enamel plate shows rounded projections, between which the dentin extends. In sections this gives to the dento-enamel junction a scalloped appearance as shown in Fig. 52; and often the deceptive appearance of the dentinal tubuli penetrating for a short distance between the enamel rods.

In many specimens made by grinding dried teeth, large irregular spaces are very conspicuous in the dentin. They usually occur in lines or zones at about uniform depth from the surface. These have

been called the interglobular spaces. They are really not spaces at all, but are areas of imperfect development in which the dentin matrix has not been classified. The dentinal tubuli pass through them without interruption. In a dried specimen the organic matrix shrinks, and the resulting space becomes filled with debris of grinding, so as to give the appearance of black spaces. Fig. 53 shows two quite distinct layers of interglobular spaces, the second much more marked than the first; and in the enamel at a position corresponding to the first is seen an

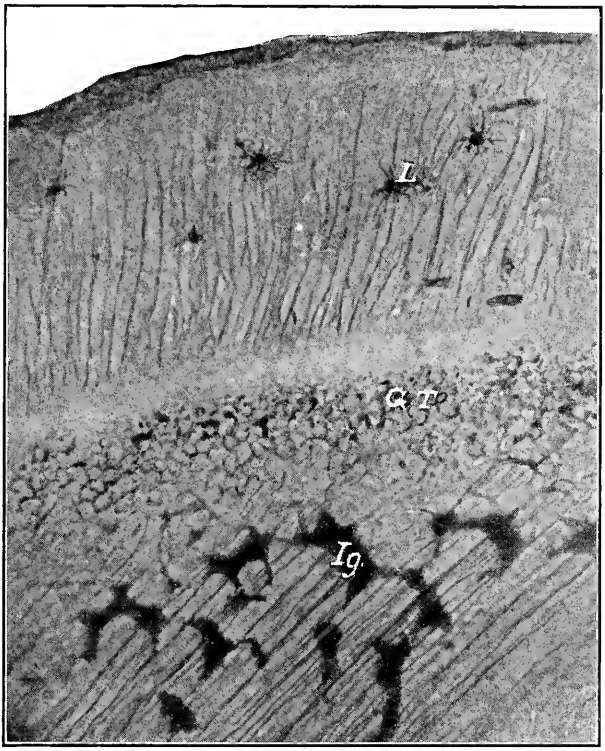

FIG. 55.—Granular layer of Tomes: *L*, lacunæ of cementum; *GT*, granular layer of Tomes; *Ig*, interglobular spaces. (About 200 ×.)

imperfection of structure marked by the very dark stratification band. This is shown best in the region of the cusp (Fig. 40) from the same section. Interglobular spaces in the root portion of the dentin are shown in Fig. 54, close to the granular layer of Tomes.

The formation of dentin is not complete at the period of eruption of a tooth, but continues for an indefinite period, thickening the layer of dentin at the expense of the pulp. When the typical amount of dentin has been formed the growth ceases, and does not begin again unless

excited by some irritation to the pulp or the pulp of some other tooth of the same side, which leads to the formation of a secondary dentin. Secondary dentin is never as perfect in structure as primary dentin; the tubuli are smaller, fewer, and much more irregular. Often in ground sections several periods of formation can be determined by differences in structure, each deposit becoming successively more and more imperfect in structure. This is shown in Fig. 55.

PULP.

The dental pulp is the soft tissue occupying the central cavity of the dentin. It is made up of embryonal connective tissue and contains a large number of bloodvessels and nerves. Like all connective tissues, the intercellular substance is large in amount and the cells are widely scattered in this soft, jelly-like tissue, which contains but few fibers. We recognize four kinds of cells in the pulp: the odontoblasts, forming the outer surface of the pulp next to the dentin; and round, spindle-shaped, and stellate connective-tissue cells.

Arrangement of Cells.—The odontoblasts are tall columnar cells, sometimes club-shaped, and in older tissues, which have ceased to be functional, sometimes become almost spherical. They form a continuous layer over the entire surface of the pulp, being everywhere in contact with the dentin. The layer has been called the membrana eboris, or the "membrane of the ivory."

The nuclei of the odontoblasts are large and oval, contain a large amount of chromatin, and are very different from the nuclei of ordinary connective-tissue cells.

Three kinds of processes have been described in connection with the odontoblasts:

1. The dentinal fibril processes or fibers of Tomes. These are long, slender protoplasmic processes projecting from the dentin end of the cell into a dentinal tubule, and running through the tubule to the outer surface of the dentin. Usually there is but one fibril extending from each odontoblast, but sometimes two can be seen, extending into two tubuli. These fibrils can be demonstrated in decalcified sections or by removing the pulp from a recently extracted tooth by cracking the tooth and carefully lifting the pulp out of the pulp chamber, and then either teasing or sectioning. Fig. 56 shows the fibrils projecting from the surface; but in this section the cut was not in the direction of the long axis of the odontoblasts, but obliquely through them. Fig. 57 (from a photograph by Röse) shows the form of the odontoblasts in a young tooth in which formation of dentin is actively progressing, with the fibrils in the dentinal tubuli.

2. Lateral processes projecting from the sides of the cells and uniting one with another in the formation of the layer.

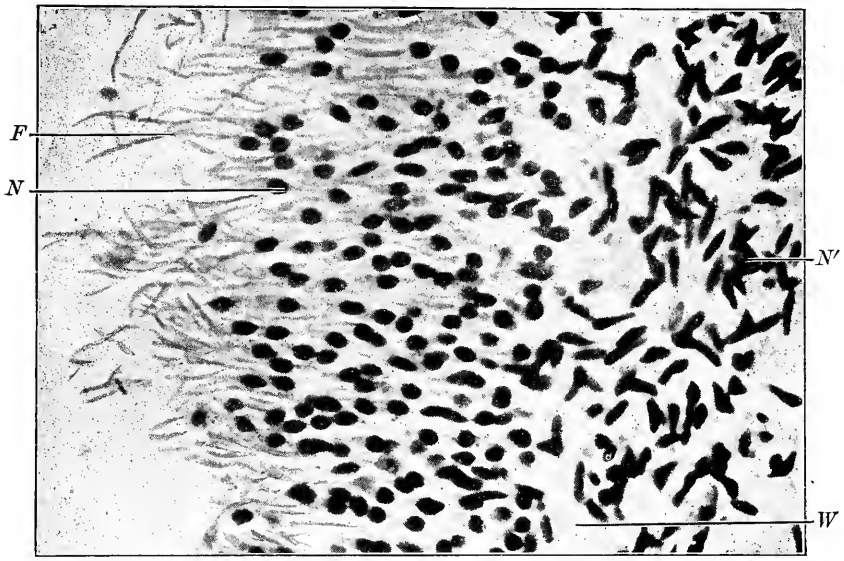

FIG. 56.—Odontoblasts. The section cuts obliquely through the odontoblasts: *F*, fibrils; *N*, nuclei of odontoblasts; *N′*, nuclei of connective-tissue cells; *W*, layer of Weil, not well shown. (About 80 ×.)

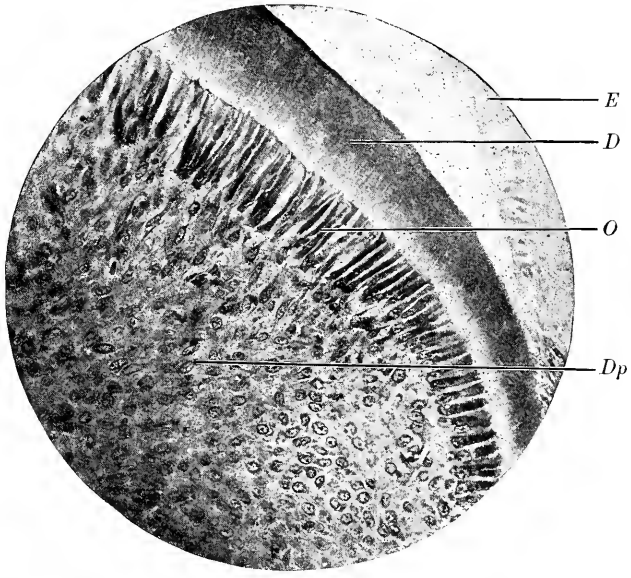

FIG. 57.—Odontoblasts and forming dentin: *E*, forming enamel; *D*, forming dentin; *O*, odontoblasts; *Dp*, body of dental papilla. (From photo-micrograph by Röse.)

3. Pulpal processes, projecting from the pulpal ends of the odontoblasts into the layer of Weil.

The odontoblasts, as the name indicates, are the dentin-forming cells. They superintend the formation and calcification of the dentin matrix, the fibril being left behind surrounded by the formed tissue. Whether the fibrils have any share in the formation and calcification of the dentin matrix has been a matter of controversy.

One author claims that the odontoblasts have no part in the formation of dentin, but it seems incredible that this view could be held by anyone who had made even a superficial examination of the tissues during dentin formation.

The relation of the fibrils to the transmission of sensation is also a matter of dispute; but at present the weight of evidence is that they in some way transmit impressions to the sensory nerves of the pulp.

The relation of the odontoblasts and the fibril to the dentin matrix is of great importance just now in the solution of the problem of the pulpless tooth. It is important to remember that the dentin matrix is a formed material of the same general class as other intercellular substances and its relation to the odontoblasts and fibril is the same as other intercellular substance and the cells which produce them. In other words, there is a chemical relation between the cell and its intercellular substance in which the cell and the normal circulation of lymph are necessary to the maintenance of the intercellular substance in its chemical and physical properties. When the cells in bone are killed, the intercellular substance or bone matrix becomes a foreign body and undergoes chemical and physical change. When the pulp is removed from the dentin the dentin matrix becomes a dead substance, a foreign body, it undergoes physical and chemical change as Black demonstrated twenty-five years ago. Dentin from a pulpless tooth is very much more easily broken than that from a vital tooth, and would be expelled from the body were it not for the fact that between it and any other vital tissue is another tissue, the cementum, which encloses the dentin and its vitality is not destroyed by the death of the dentin. The only reason that a pulpless tooth is not exfoliated is because the dead dentin is enclosed in living cementum.[1]

The question as to what becomes of the dentinal tubuli and whether they may produce decomposition products or split proteid elements which reduce the vitality of neighboring tissues and render them liable to the invasion of infection cannot be answered until a great deal of hard work has been done in the laboratory.

[1] The question as to whether the death of the dentin affects the vitality of the cementum in any degree is a matter of discussion at present.

In the opinion of the author very little is really known about the contents of the dentinal tubuli.

Just beneath the layer of odontoblasts is a zone which contains very few connective-tissue cells. In thin sections, especially in the body of the pulp, this appears as a clear layer about half as thick as the layer of odontoblasts. It is known as the layer of Weil. Just beneath the layer of Weil the connective-tissue cells are especially numerous and form a more or less distinct layer of closely placed cells. In the rest of the body of the pulp the cells are about uniformly distributed throughout the intercellular substance. These connective-tissue cells are of the characteristic forms, rather small, containing a small but deep-staining nucleus, the protoplasm stretching out into slender projections in two directions to form the spindle cells, or in more than two directions to form the stellate cells. The stellate forms are more common in the body of the pulp, the spindle form in the canal portions. The round cells are comparatively few in number, and are probably young cells which have not yet acquired the adult form.

Bloodvessels of the Pulp.—The blood-supply of the pulp is extremely rich, several arterial vessels entering in the region of the apex of the root, often through several foramina. These large vessels extend occlusally through the central portion of the tissue, giving off many branches which break up into a very close and fine capillary plexus (Fig. 58). From the capillaries the blood is collected into the veins, which pass apically through the central portion of the tissue. A very striking peculiarity of the bloodvessels of the pulp is the thinness of their walls. Even the large arteries show scarcely any condensation of fibrous tissue around them to form the usual adventitious layer, and usually contain but a single involuntary muscle fiber representing the media, while the walls of even the large veins are made up of only the single layer of endothelial cells forming the intima and are in structure like large capillaries (Fig. 59). This peculiarity of the bloodvessel walls is of great importance as it renders the tissue especially liable to such pathologic conditions as hyperemia and inflammation.

The lymphatic circulation of the dental pulp and the presence or absence of lymphatic vessels in the tissue have been matters of dispute for many years.

In 1909 Sweitzer demonstrated lymph vessels in the dental pulp by injection.[1] Since that time Sweitzer's work has been repeated in this country and the direct injection of lymph vessels in the cervical glands through the dental pulp has been accomplished.[2]

[1] "Ueber die Lymphgefässe des Zahnfleisches u. der Zähne beim Menschen u. bei Säugetieren," Arch. f. mikrosk. Anat. u. Entwickl., 1907, lxix, p. 807; 1909, lxxiv, p. 927.

[2] Kaethe Dewey, Frederick B. Noyes: Dental Cosmos, 1917.

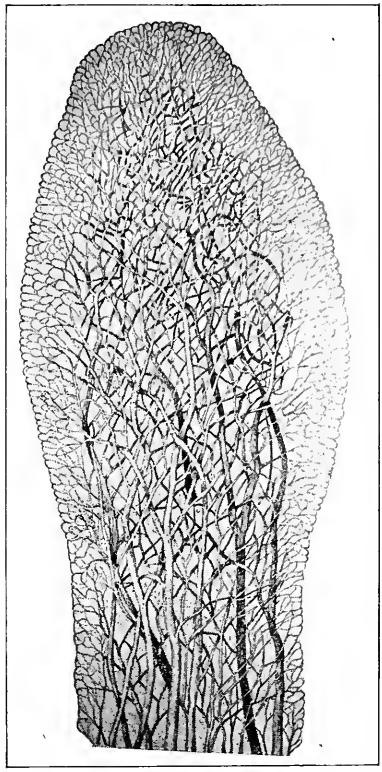

FIG. 58.—Diagram of the bloodvessels of the pulp. (Stowell.)

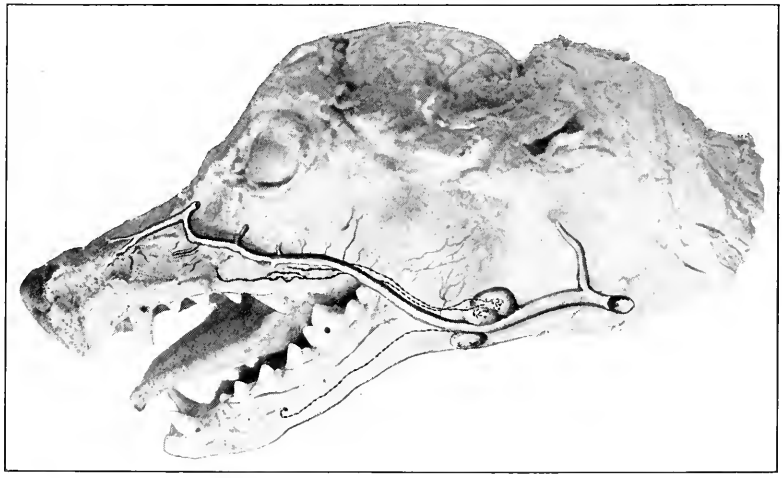

FIG. 59.—Dog's head, showing lymphatic glands injected from dental pulp.

The lymph is collected in very delicate vessels that have been followed to the region of the odontoblastic layer. The vessels pass to the apical region following the same course as the large bloodvessels. Both independent vessels and perivascular lymph sheaths have been demonstrated. The vessels leave the pulp through the apical foramina, anastomose freely with those of the peridental membrane in the apical portion, and pass through the bone to the inferior dental canal in the lower jaw and the infra-orbital canal in the upper. They have been demonstrated emerging from the mental and infra-orbital foramina and followed to the submaxillary lymph glands. It is probable that some of the incisors drain to the submental lymph nodes and that probably the second and third molars communicate with lymph vessels emerging from the posterior opening of the inferior dental and infra-orbital canals and pass to the lymph nodes of the pharynx. Much work is still to be done in this field. There is also some experimental evidence that there is a flow or circulation of lymph in the tubuli of the dentin, which is quite logical from a priori reasoning.

Nerve of the Pulp.—Several comparatively large bundles of medullated nerve fibers, containing from six or eight to fifteen or twenty fibers, enter the pulp in company with the bloodvessels and pass occlusally through the central portion of the tissue. These bundles branch and anastomose with each other very freely. Most of the fibers lose their medullary sheath before reaching the layer of Weil, in which position they form a plexus of non-medullated fibers; from these fibers free endings are given off, which penetrate between the odontoblasts. In some cases these have been followed over on to the dentinal ends of the odontoblasts, but in no instance have they been followed into the dentinal tubuli.

In the opinion of the author the work of Carl Huber [1] though done many years ago remains the most convincing of any on the enervation of the dental pulp. Several authors have claimed to demonstrate nerve fibers in the dentinal tubuli, but in the opinion of the author the evidence based upon the gold chlorid method alone must be considered as unsatisfactory, and at least capable of other interpretation.

The Functions of the Pulp.—The pulp performs two functions, a vital and a sensory.

The vital function is the formation of dentin, and is performed by the layer of odontoblasts. This is the principal function of the pulp, and it is first manifested in the development of the tooth before the dentinal papilla is converted into the dental pulp by being enclosed in the formed dentin. After the tooth is fully formed the

[1] Dental Cosmos, 1898.

FIG. 1

FIG. 2



FIG. 3



Fig. 1.—Tooth split open, showing pulp and pulp chamber and lymphatic vessels as seen with magnification of about 10 diameters.

Fig. 2.—Injected lymphatic vessels in the dental pulp.

Fig. 3.—Injected perivascular lymph sheath.

vital function is not manifested unless the pulp is stimulated by some excitation affecting trophic centers and which causes the formation of secondary dentin. There are some exceptions where the formation is entirely local.

The Sensory Function.—In regard to sensation the pulp resembles an internal organ. It has no sense of touch or localization, and responds to stimuli only by sensations of pain. The pain is usually localized correctly with reference to the median line, but, aside from that, is localized only as it is referred to some known lesion. If several pulps on the same side of the mouth and in teeth of both the upper and lower arches were exposed so that they could be irritated without impressions, reaching the peridental membrane, and the patient were blindfolded, it would be impossible for him to tell which of the pulps was touched. The pain originating from a tooth pulp may be referred to the wrong tooth or to almost any point on the same side supplied by the fifth cranial nerve.

The pulp is especially sensitive to changes of temperature, but is incapable of differentiating between heat and cold; this fact is often made use of in differential diagnoses (see Chapter XVI). The pulp is also very sensitive to traumatic and chemical irritations, even when these are conveyed to it through the agency of the dentinal fibrils. Dr. Huber[1] has suggested that this transmission may be accomplished by the traumatic or chemical action upon the fibrils setting up metabolic changes in the odontoblastic cells which act as stimuli to the sensory nerves ending between the cells of that layer.

CEMENTUM.

The cementum covers the surface of the dentin apically from the border of the enamel lapping slightly over the enamel at the gingival margin (Plate I, Fig. 1).

This is undoubtedly the normal and ideal relation, though in many extracted teeth it will be found otherwise.[2] It forms a layer, thickest in the apical region and between the roots of bicuspids and molars, and becoming thinner as the gingival line is approached. The cementum resembles subperiosteal bone in structure, but differs from it in the character and arrangement of the lacunæ and in the absence of Haversian systems; the layers or lamellæ of the cementum also are less uniform in character than those of bone.

The function of the cementum is to furnish attachment for the fibers of the peridental membrane which holds the tooth in its position.

[1] Dental Cosmos, 1898.
[2] Hopewell-Smith: Normal Histology, p. 18.

The surrounding tissues are never in physiologic connection with the outer surface of the dentin, except to form cementum over it or to remove its substance by absorption; and when absorption of the dentin has occurred on the surface of a root, it is never repaired except by the formation of cementum to fill up the cavity and reattach the membrane.

The cementum is intermittently formed during the functioning of the tooth, being added layer after layer over the entire surface of the root, the difference in thickness of the tissue in the gingival and apical portions being chiefly, though not entirely, due to the difference in thickness of each layer in the two positions (Plate I, Fig. 2). The cementum on the roots of newly erupted teeth is thin, and on the roots of teeth of old persons is thick. This continued formation of cementum is due to the necessity for change and reattachment of the fibers of the membrane.

In the gingival portions, where the cementum is thin, the tissue is clear and apparently structureless, and usually contains no lacunæ; while in the apical half and between the roots the lacunæ are numerous. In general, wherever the lamellæ are thin, the lacunæ are absent; but where the lamellæ are thick, they are found. The canaliculi which radiate from the lacunæ are not as regular as in the case of the lacunæ of the bone. Sometimes they are numerous, sometimes few; they may extend from a lacuna in all directions, or they may be confined to one side, usually the side toward the surface of the cementum (Plate I, Fig. 3).

The cementum is penetrated through all its layers by fibers of the peridental membrane which have been imbedded in the matrix of the tissue and calcified along with it. The first layer—that is, the one next to the dentin—is usually structureless and shows no fibers in it, at least in its inner half. In ground sections the imbedded fibers often appear in a number of layers, while they are not apparent in the rest of the thickness. This is because just before and just after the formation of the layers in which they appear the fibers were cut off and reattached, changing their direction, so that in the other layers the fibers are cut transversely or obliquely. This is illustrated in Fig. 60. These imbedded fibers are very numerous in some places. If properly stained, the tissue seems almost a solid mass of fibers. In ground sections they have sometimes been mistaken for minute canals from the fact that they are not always as fully calcified as the cementum matrix, and shrinkage causes the appearance of little open canals.

There has been much discussion recently of the relation of the dentin and cementum, and the nourishment of the cementum. Much of the discussion shows lack of the fundamental considerations of cytology, tissue structure, nutrition, metabolism, and other biological ideas.

The author is of the opinion that most of the root communications between the lacunæ and canaliculi of the cementum and the tubuli of the dentin are not typical of the tissue if they ever occur. From a study of the formation of cementum and dentin it is evident that the formation begins at the dento-cemental junction just as that of enamel and dentin begins at the dento-enamel junction. The formation of dentin proceeds from this line inward and that of the cementum out-

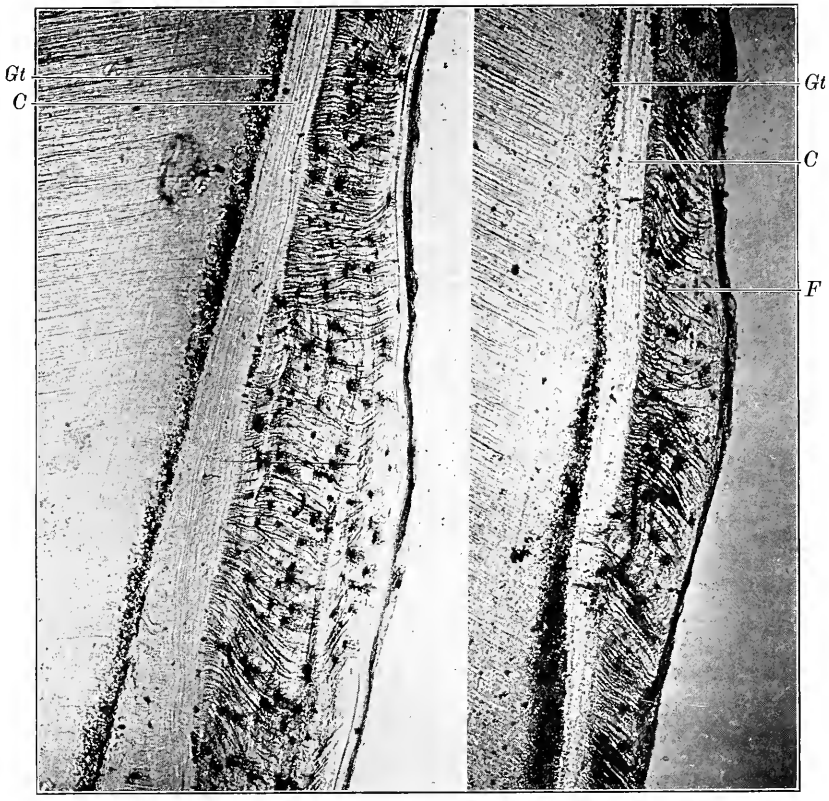

FIG. 60.—Two fields of cementum showing penetrating fibers: *Gt*, granular layer of Tomes; *C*, cementum not showing fibers; *F*, penetrating fibers. (About 54 ×.)

ward. The formative process as well as the tissue produced is supported, for the dentin by the pulp, for the cementum by the peridental membrane. While it is quite evident that there may be occasional communication between the channels in the dentin matrix and those in the cemental matrix, it seems well established that the nourishment of one tissue is not dependent upon, or even related to, the other.

The relation of dentin and cementum in the region of the apex

of the root becomes very complicated because of the way in which the formation of the root apex is accomplished, and the structure in this region becomes important in the pathology of the region.[1]

Hypertrophies of the cementum (formerly often called exostoses, or excementoses) are very common. The increased thickness may be of one lamella or of several lamellæ in the region of the hypertrophy, or all of the layers from first to last may take part in it. Small local thickenings of a single lamella are seen in connection with the peridental membranes wherever an especially strong bundle of fibers is to be attached to the root to support the tooth against some special strain.

PERIDENTAL MEMBRANE.

The peridental membrane may be defined as the tissue which fills the space between the root of the tooth and the bony wall of its alveolus, surrounds the root occlusally from the border of the alveolus, and supports the gingiva.

It is important to emphasize the three parts of the membrane and to call attention to the fact that the membrane clothes the root occlusally from the border of the alveolar process as far as the tissues are attached to the cementum and supports the epithelium of the gingiva.

There has been much discussion as to the origin of the myeloplax or giant absorbing cells. Some have claimed that they are degenerate, fused, osteoclasti.[2] It seems more probable to the author that they originate from the endotheloid cells of the connective tissue which at first act singly, but fuse as the area of absorption increases. It has been referred to under many names, as pericementum, dental periosteum, alveolo-dental periosteum, etc. While this tissue performs the functions of a periosteum for the bone of the alveolus, it differs in structure from the periosteum in any position, so that any name including the word periosteum or implying a double membrane should be avoided.

The peridental membrane belongs to the class of fibrous membranes, and is made up of the following structural elements: (1) Fibers. (2) Fibroblasts. (3) Cementoblasts. (4) Osteoblasts. (5) Osteoclasts. (6) Epithelial structures which have been called the glands of the peridental membrane. (7) Bloodvessels. (8) Nerves. (9) Lymphatics.

The peridental membrane performs three functions: a physical function, maintaining the tooth in relation to the adjacent hard and soft tissues; a vital function, the formation of bone on the alveolar

[1] Noyes: Dental Histology.

[2] Arey, L. B.: Origin, function and fate of the osteoblast. Am. Jour. of Anatomy, February, 1920.

wall and of cementum on the surface of the root; and a sensory function, the sense of touch for the tooth being exclusively in this membrane.

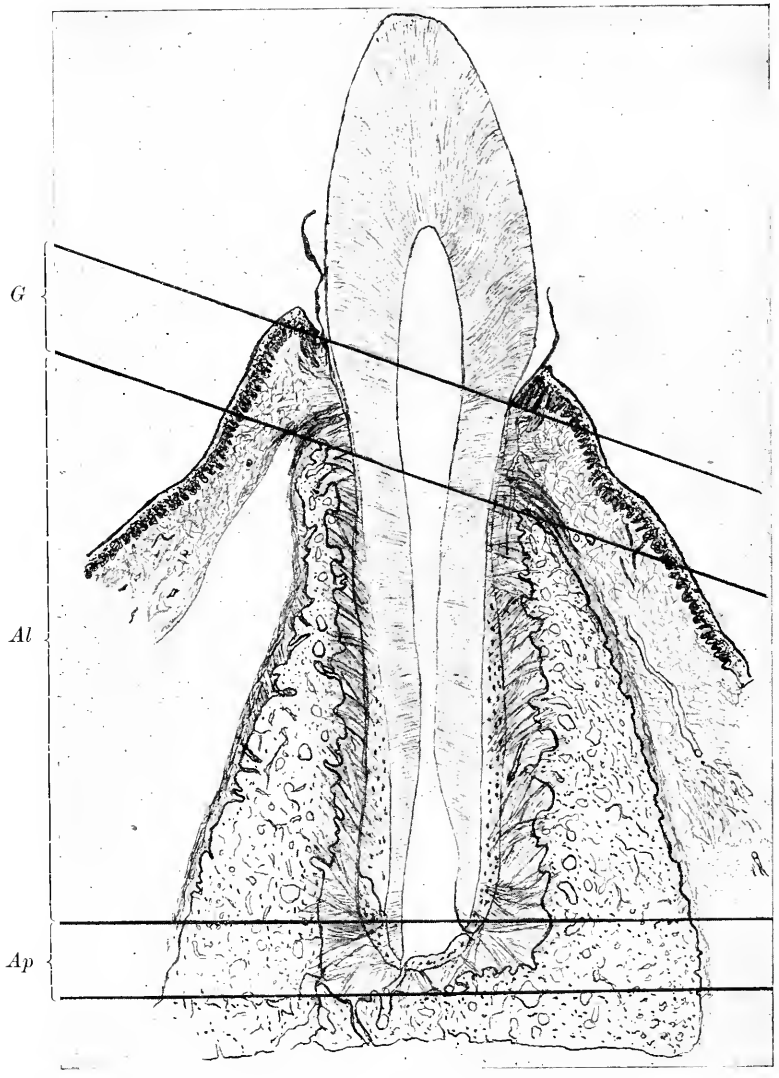

FIG. 61.—Diagram of the fibers of the peridental membrane: *G*, gingival portion; *Al*, alveolar portion; *Ap*, apical portion. (From a photograph of a section from incisor of sheep.)

The fibrous tissue of the membrane is of the white variety, and may be divided into two classes, the principal fibers and the indifferent

or interfibrous tissue. The principal fibers may be defined as those which spring from the cementum and are attached at their other end to the bone of the alveolar wall, to the outer layer of the periosteum

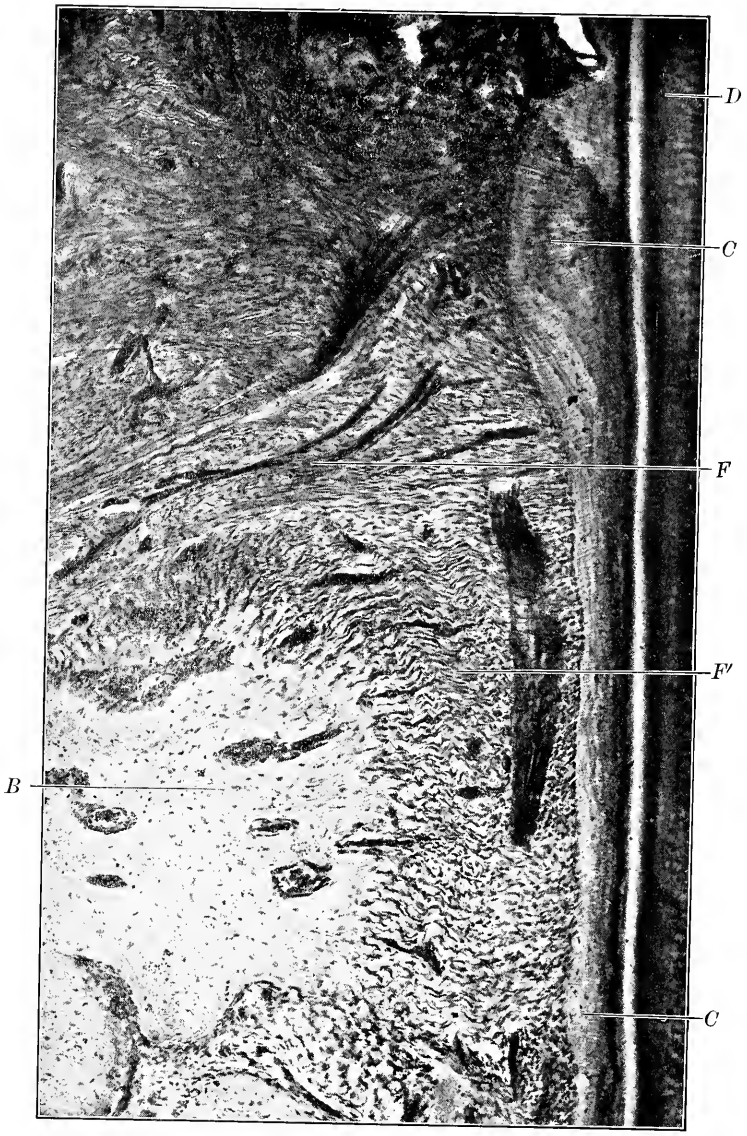

FIG. 62.—Longitudinal section of peridental membrane from young sheep, showing fibers penetrating cementum: *D*, dentin; *C*, cementum, showing embedded fibers; *F*, fibers running to outer layer of periosteum covering the alveolar process; *F′*, fibers running to the bone at the border of the process; *B*, bone. (About 80 ×.)

covering the surface of the alveolar process to the cementum of the approximating tooth, or become blended with the fibrous mat of the gum supporting the epithelium. They were so called by Dr. Black, not only because they form the principal bulk of the tissue, but they also perform the principal function of the membrane, the support of the tooth and surrounding tissues. The interfibrous tissue, also of the white variety, but made up of smaller and more delicate fibers, is found filling spaces between the principal fibers and surrounding and accompanying the bloodvessels and nerves, and contains the lymphatics.

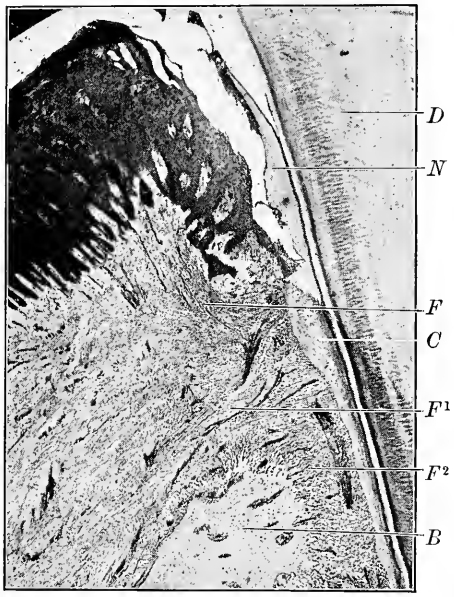

FIG. 63.—Longitudinal section of the peridental membrane in the gingival portion: *D*, dentin; *N*, Nasmyth's membrane; *C*, cementum; *F*, fibers supporting the gingiva; F^1, fibers attached to the outer layer of the periosteum over the alveolar process; F^2, fibers attached to the bone at the rim of the alveolus; *B*, bone. (About 30 ×.)

For convenience of description and study, the peridental membrane is divided into three portions: the gingival, that portion which surrounds the root occlusally from the border of the alveolar process; the alveolar, the portion from the border of the process to the apex of the root; and the apical portion, surrounding the apex of the root and filling the apical region (Fig. 61).

The principal fibers spring from the cementum, the cementoblasts building up the matrix around them and then calcifying both matrix and fibers, in this way implanting their ends into the surface of the root. In Fig. 62 the fibers are seen passing through the last-formed

layer of cementum. In most positions the fibers as they spring from the cementum appear as well-marked bundles of fine fibers. A short distance from the surface of the root they break up into smaller bundles, which interlace and are reunited into larger bundles, to be attached at their other extremity to the bone, cementum, or fibrous tissue.

To arrive at an understanding of the arrangement of the fibers of the peridental membrane, they must be studied in both longitudinal and transverse sections. In longitudinal sections of the membrane in the gingival portion (Fig. 63) the fibers springing from the cementum at the gingival line pass out for a short distance at right angles to the long axis of the tooth and then bend sharply to the occlusal[1] passing into the gingiva to support it and hold it closely against the neck of the tooth. These fibers are most numerous on the lingual side, where food is brought against the gingiva with force in mastication and tends to crush it down. In the middle of the gingival portion the fibers pass out at right angles to the axis and are blended with the fibrous mat of the gum on the labial and lingual sides, or are attached to the cementum of the adjoining teeth on the approximate sides. A little farther from the gingival line the fibers are inclined slightly apically, passing over the border of the process to be attached to the outer layer of the periosteum. These fibers are especially large and strong and form what has been called the ligamentum circulare. Just at the rim of the alveolus the fibers are inclined slightly apically and inserted into the bone, forming the edge of the process.

In transverse sections of the membrane in the gingival portion (Fig. 64) the fibers spring from the cementum in large bundles; at the center of the labial surface they extend directly outward, breaking up into smaller bundles, passing around bloodvessels and bundles of fibers, and blending with the fibrous tissue supporting the epithelium. Passing mesially and distally toward the corners of the root, the fibers swing around laterally and pass to the cementum of the next tooth. On the approximate sides the fibers suddenly divide into smaller bundles, which wind in and out around bloodvessels, and bundles of fibers which pass into the gingiva and are reunited into large bundles to be inserted into the cementum of the next tooth. On the lingual side the arrangement is like that of the labial, except that the distance to which the fibers of the membrane can be followed before they are lost in the fibrous mat of the gum is usually greater than on the labial.

In the occlusal third of the alveolar portion of the membrane the fibers pass, at right angles to the axis of the tooth, directly from the

[1] In describing the direction and inclination of peridental membrane fibers, they are always traced from the cementum to the bone, the angle with the horizontal plane being formed at the surface of the cementum.

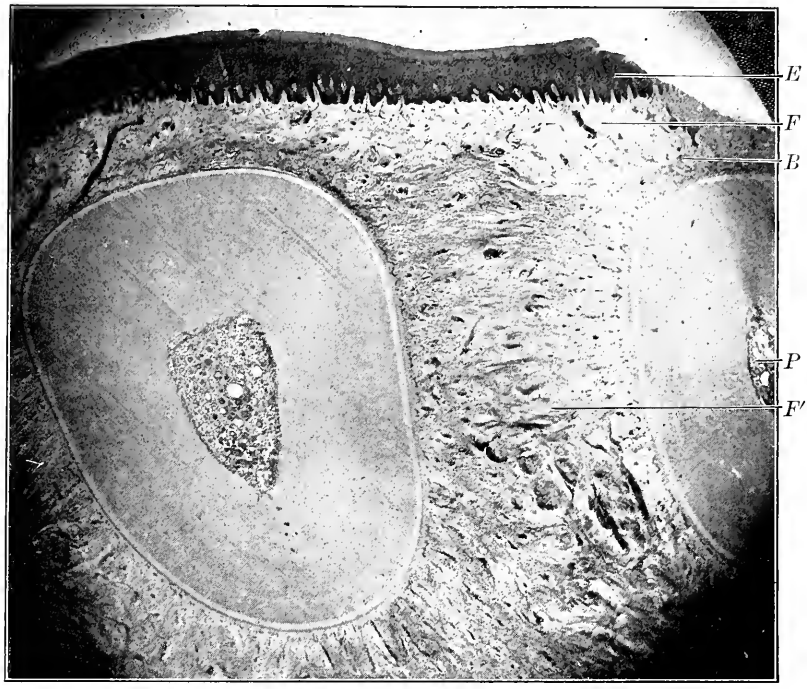

FIG. 64.—Transverse section of the peridental membrane in the gingival portion (from sheep): *E*, epithelium; *F*, fibrous tissue of gum; *B*, point where peridental membrane fibers are lost in fibrous mat of the gum; *P*, pulp; *F'*, fibers extending from tooth to tooth. (About 30 ×.)

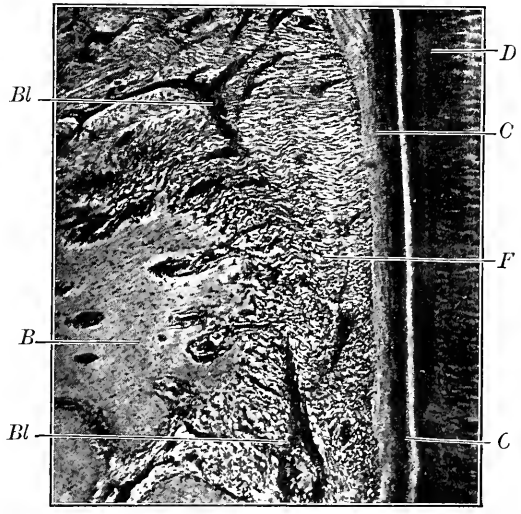

FIG. 65.—Fibers at the border of the alveolar process (from sheep): *D*, dentin; *C*, cementum; *F*, fibers extending from cementum to bone; *Bl*, bloodvessel; *B*, bone. (About 80 ×.)

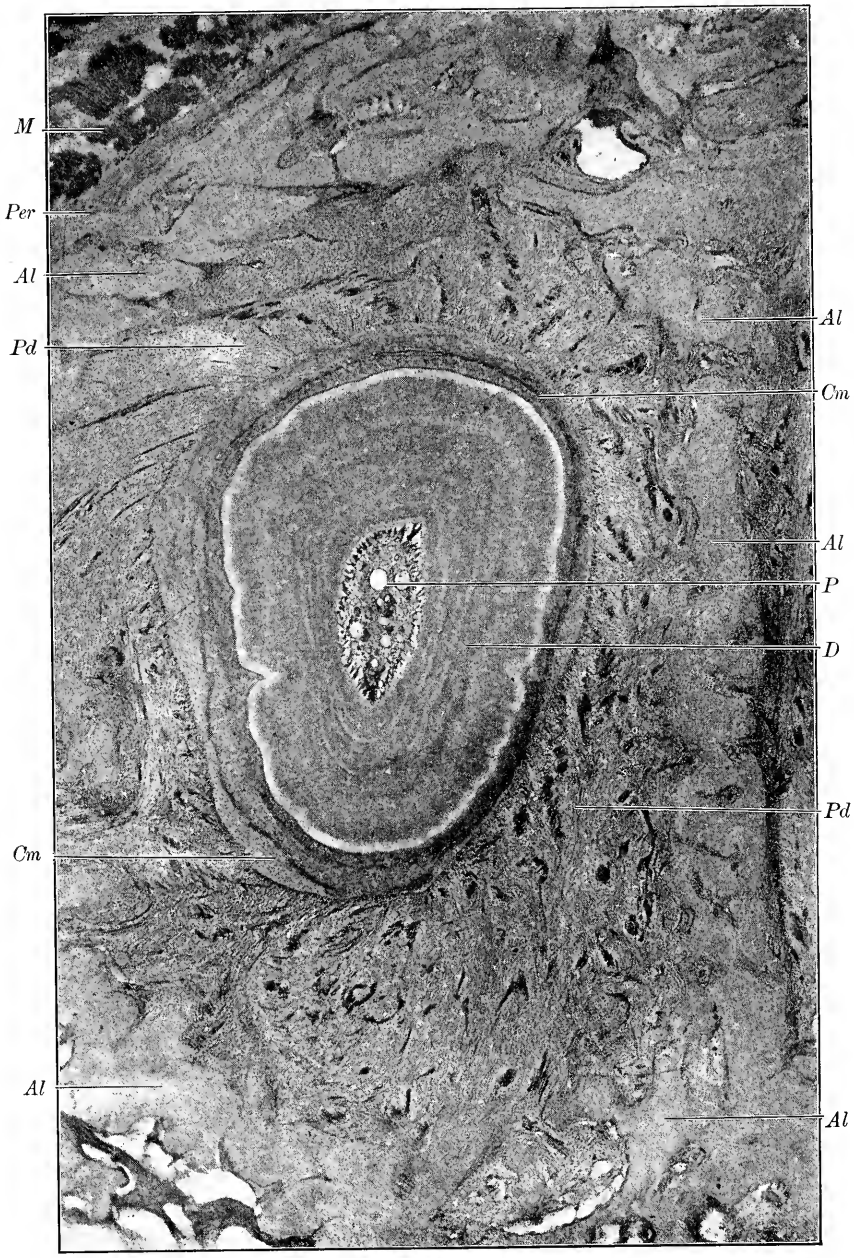

FIG. 66.—Transverse section of the peridental membrane in the occlusal third of the alveolar portion (from sheep): *M*, muscle fibers; *Per*, periosteum; *Al*, bone of the alveolar process; *Pd*, peridental membrane fibers; *P*, pulp; *D*, dentin; *Cm*, cementum.

cementum to the bone. In this position the fibers are large and do not break up into smaller bundles, but the original fibers can be followed uninterruptedly from the cementum to the bone (Fig. 65). In the middle third the fibers are inclined occlusally, and this inclination increases as the apical third is approached. In the apical third the inclination is greatest, and the fibers as they arise from the cementum are very large and break up into fan-shaped fasciculi as they pass across to the bone. In the apical portion the fibers radiate from the apex in all directions across the apical region and spread out in fan-shaped bundles like those in the apical third of the alveolar portion.

In a transverse section near the border of the alveolus (Fig. 66), at the center of the labial surface of the root, the fibers are seen to extend directly out from the surface of the root to the bone of the process, except where they are diverted to pass around bloodvessels. Passing around distally at the corner of the root, the fibers swing laterally so as to be almost at a tangent to the surface of the root, and are inserted much farther to the distal on the wall of the alveolus. A similar arrangement is noticed at the other corners of the root, though these tangential fibers are usually more marked at the distal than at the mesial corners.

Studying the arrangement of the fibers with reference to the physical function of the membrane, it is seen to be the best that could be devised to support the teeth against the force of mastication and to support the tissues about them. In the gingival portion the fibers passing from tooth to tooth form the foundation for the gingivæ between the teeth filling the interproximate spaces; so that if these fibers are cut off from the cementum, by extending a crown band too far, or by the encroachment of calculary deposits beginning in the gingival space, the gingivus drops down and no longer fills the interproximate space. In the alveolar portion the fibers at the border of the process and those at the apex of the root together support the tooth against lateral strain, while those in the rest of the alveolar portion are so arranged as to swing the tooth in its socket and support it against the force of occlusion (see Fig. 61). As seen from the transverse section, the fibers at the occlusal third of the alveolar portion are so arranged as to support the tooth against forces tending to rotate it in its socket.

Cellular Elements of the Membrane.—The fibroblasts are spindle-shaped or stellate connective-tissue cells which are found between the fibers as they are arranged in bundles. In sections stained with hematoxylin they take the stain deeply, and the fibers, which are unstained, are differentiated by the cells lying in rows between them. The number of fibroblasts in the membrane decreases with age. They are large and numerous in the membrane of a newly erupted tooth, and com-

paratively small and few in the membrane around an old tooth. This is characteristic of fibroblasts in other positions. The fibroblasts are shown as they appear in a hematoxylin-stained section with low powers in Fig. 67, which gives part of the membrane in the gingival

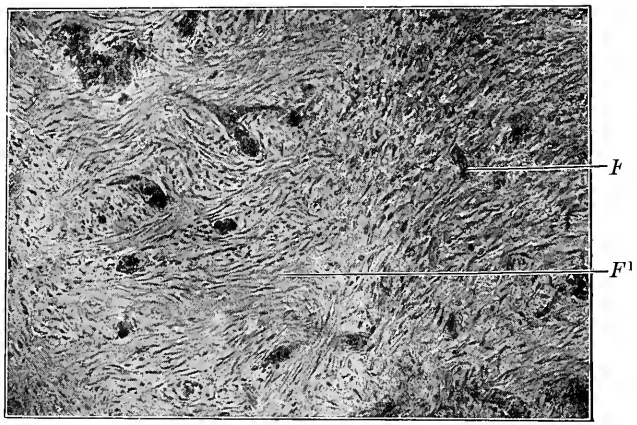

FIG. 67.—Fibers and fibroblasts from transverse section of membrane: *F*, fibers cut transversely; *F*¹, fibers cut longitudinally, showing fibroblasts. (About 80 ×.)

portion between two teeth. The cells are seen as spindle-shaped dots which mark out the fibers; at *F* they are seen in a position where the fibers are cut transversely. While these cells perform the same function for the cementum as the osteoblasts do for bone, they are in form very different from the osteoblasts. The cementoblasts are always flat-

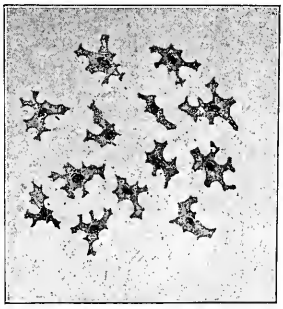

FIG. 68.—Cementoblasts. (Drawing by Dr. Black.)

tened cells, sometimes almost scale-like, and when seen from above are very irregular in outline. This irregularity of outline is caused by the cells fitting around the attached fibers of the membrane so as to cover the entire surface of the cementum between the fibers. Fig. 68 from

a drawing by Dr. Black shows several cementoblasts as seen when isolated by teasing. The cementoblasts have a central mass of protoplasm containing an oval nucleus, and short irregular processes which fit around the fibers as these spring from the surface of the cementum. Fig. 69 shows them in section perpendicularly to the surface of the root, where they are crowded between the fibers. The cementoblasts often have processes projecting into the cementum like those from the osteoblast, but processes projecting into the membrane have never been demonstrated.

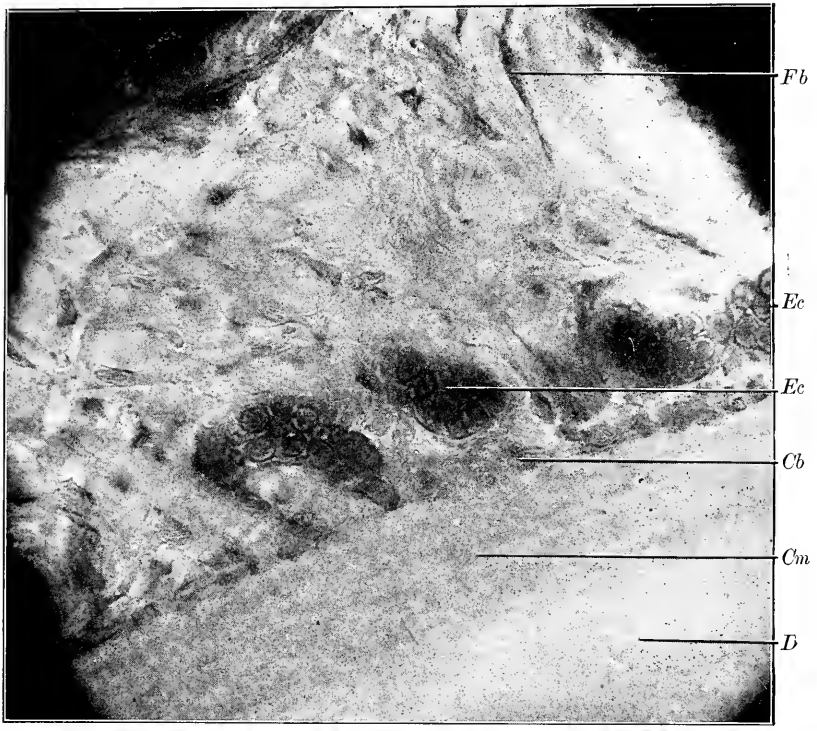

FIG. 69.—Transverse section, showing the cellular elements: *Fb*, fibroblasts; *Ec*, epithelial structures; *Cb*, cementoblasts; *Cm*, cementum; *D*, dentin. (About 900 ×.)

In the formation of the cementum occasionally a cementoblast becomes enclosed in the formed tissue filling one of the lacunæ, in which position it becomes a cement corpuscle.

The osteoblasts of the membrane cover the surface of the bone, forming the wall of the alveolus, lying between the fibers which are built into the bone. In form and function they are like the osteoblasts in attached portions of the periosteum. They form bone around the

ends of the peridental membrane fibers, building them into the substance of the bone. The bone thus formed over the wall of the alveolus

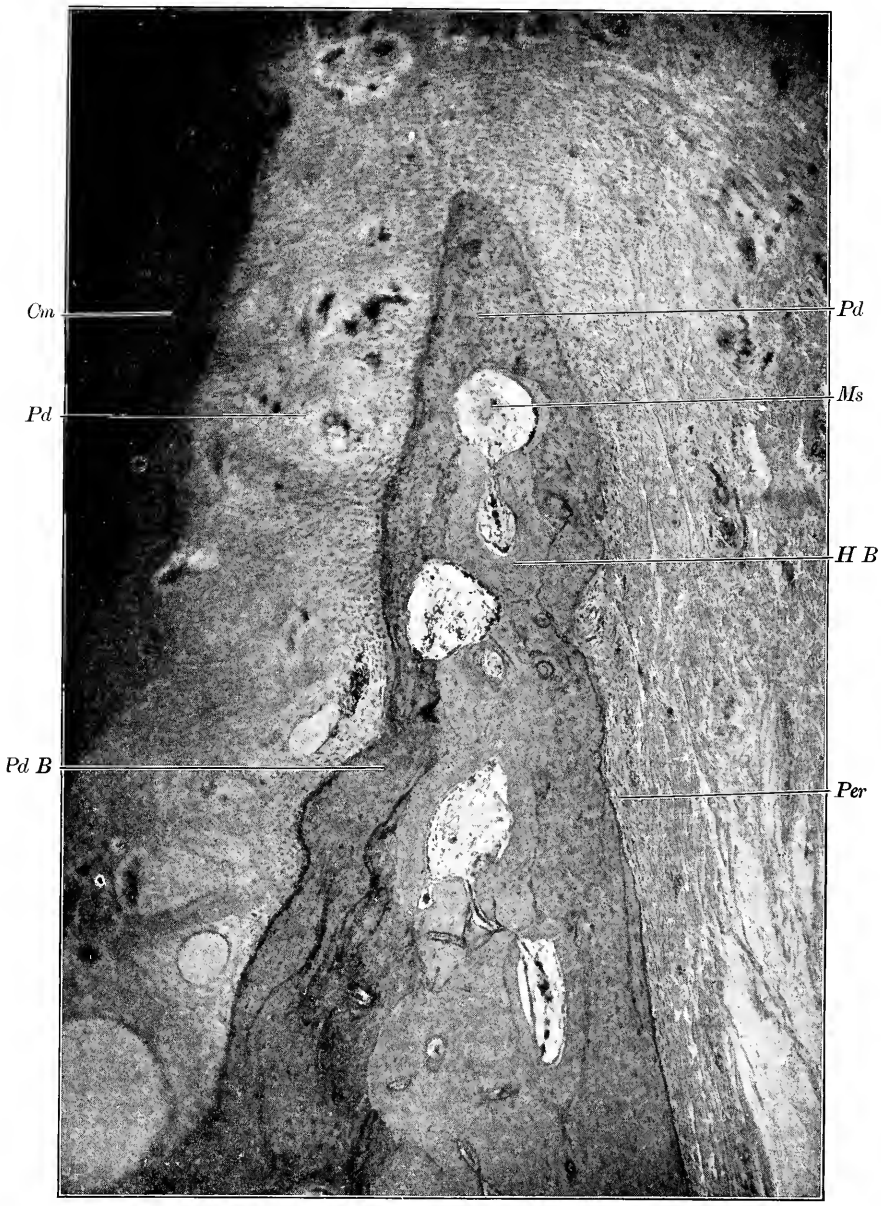

FIG. 70.—Border of growing process: *Cm*, cementum; *Pd*, peridental membrane; *Pd.B*, solid subperidental and subperiosteal bone with imbedded fibers; *Ms*, medullary space formed by absorption of the solid bone; *H.B*, Haversian-system bone without fibers; *Per*, periosteum. (About 50 ×.)

is like the solid subperiosteal bone, and is penetrated throughout its thickness by the imbedded fibers; but, as with the subperiosteal bone, it is constantly being penetrated by perforating canals, the solid bone being removed by resorption and rebuilt in bone with Haversian sys-

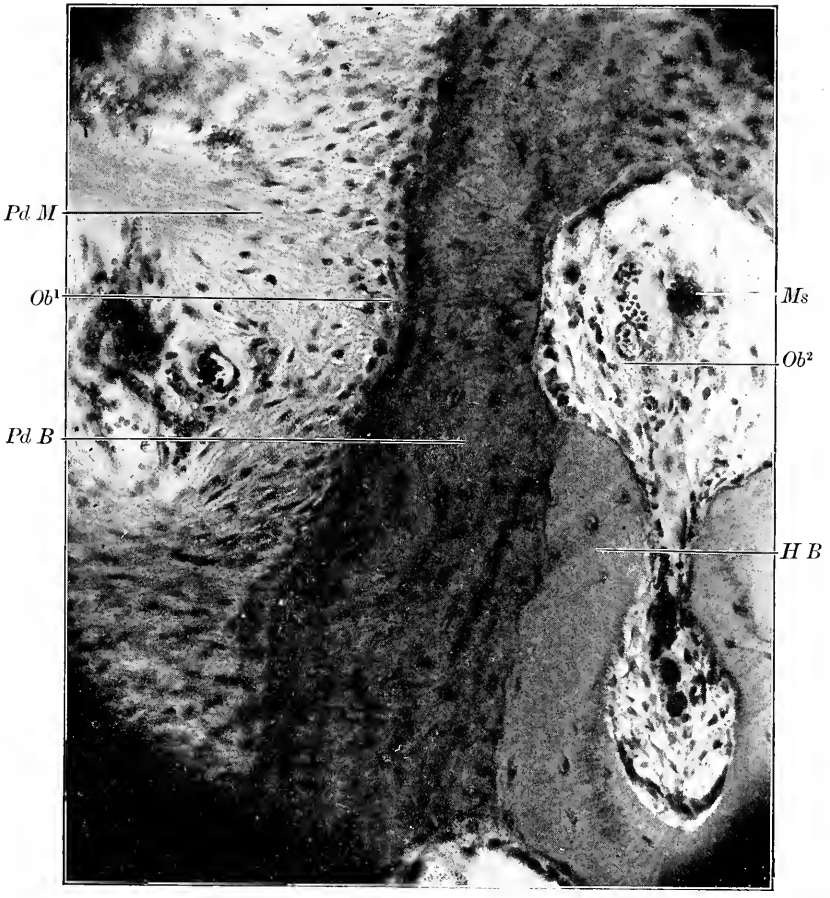

FIG. 71.—Penetrating fibers in bone: *PdM*, peridental membrane; *Ob*¹, osteoblasts of peridental membrane; *Ob*², osteoblasts of medullary space; *PdB*, solid subperidental and subperiosteal bone with embedded fibers; *Ms*, medullary space formed by absorption of the solid subperidental bone with embedded fibers; *H.B*, Haversian-system bone without fibers built around the medullary space. (About 200 ×.)

tems. This process is shown in Fig. 70, a section through a growing portion of the process around a permanent tooth. A higher power (Fig. 71) shows the penetrating fibers and the formation of Haversian-system bone without fibers, in the body of the process.

The osteoclasts, or myeloplaques, are bone-destroying cells (Fig.

72); they act not only upon bone, but also upon cementum and dentin. They are oval cells, often as much as 30 microns in diameter, and contain many nuclei—from two or three to fifteen or twenty. They are often called giant cells. The osteoclasts are not constantly found in the membrane, but make their appearance whenever calcified tissues are to be destroyed. In order that they may act upon a tissue they must lie in contact with its surface, and therefore the first step in absorption of the peridental membrane is the cutting off of the fibers imbedded

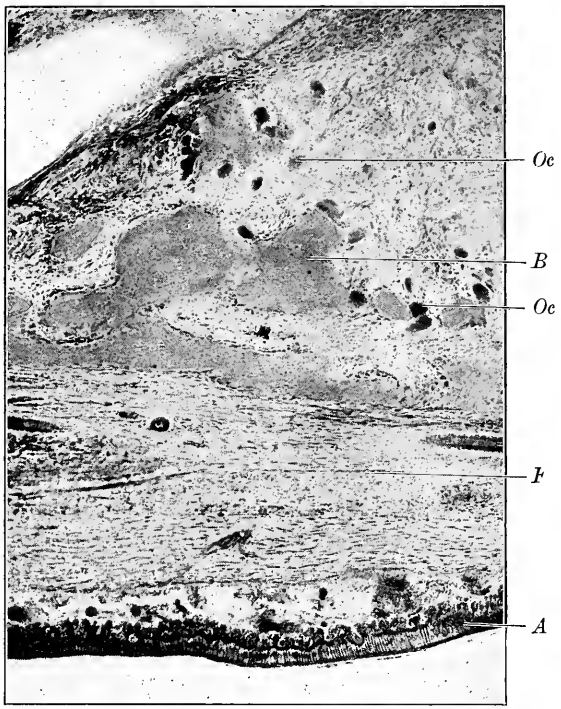

FIG. 72.—Osteoclast absorption of bone over permanent tooth: *Oc*, osteoclasts; *B*, bone of crypt wall; *F*, fibrous tissue of follicle wall; *A*, ameloblasts. (About 62 ×.)

in the bone or cementum. Where the osteoclasts act upon the surface of the tissue they produce bay-like excavations, in which they lie, and which are known as Howship's lacunæ. These excavations are shown in Fig. 73, though the osteoclasts have disappeared. In Fig. 74, from a ground section, the basin-like excavations are shown filled with newly-formed cementum, thus leaving in the tissue the record of an absorption repaired. In absorption of the roots of the temporary teeth the osteoclasts are found not only in the membrane and attacking the

surface of the root, but all through the medullary spaces in the bone, removing the temporary alveolar process.

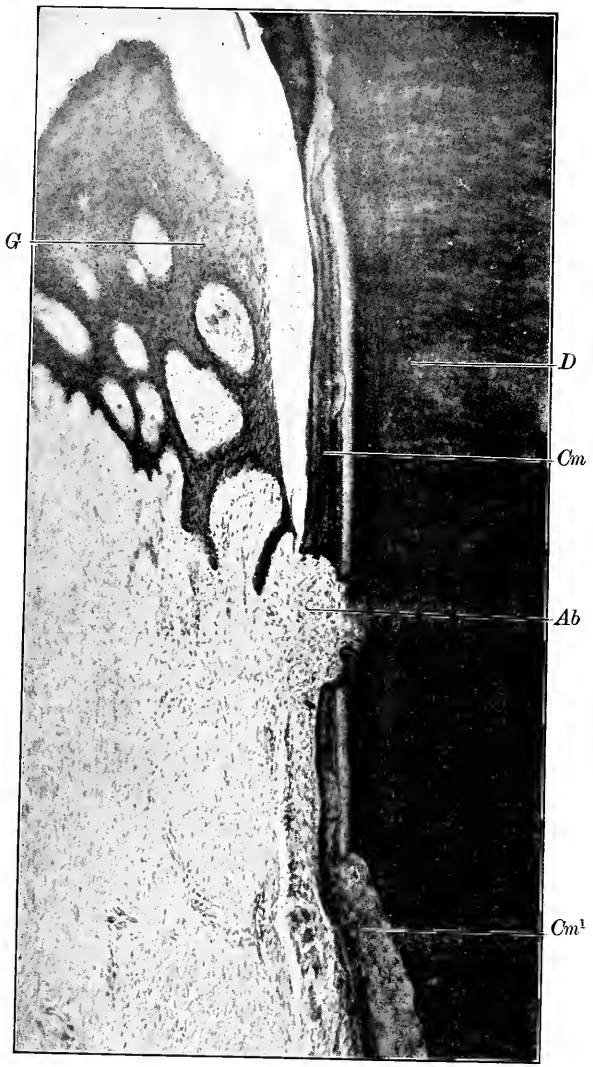

FIG. 73.—Root of a temporary incisor, showing absorption and rebuilding of cementum (from sheep): *G*, gingiva; *D*, dentin ; *Cm*, cementum; *Ab*, absorption cavity, showing Howship's lacunæ; *Cm*¹, newly-formed cementum. (About 50 ×.)

When absorption is going on at one place on the surface of a root a compensating formation of cementum is going on at another, so that

not all of the fibers of the membrane are cut off. This is illustrated by sections of temporary teeth that are ready to be shed (Fig. 75).[1]

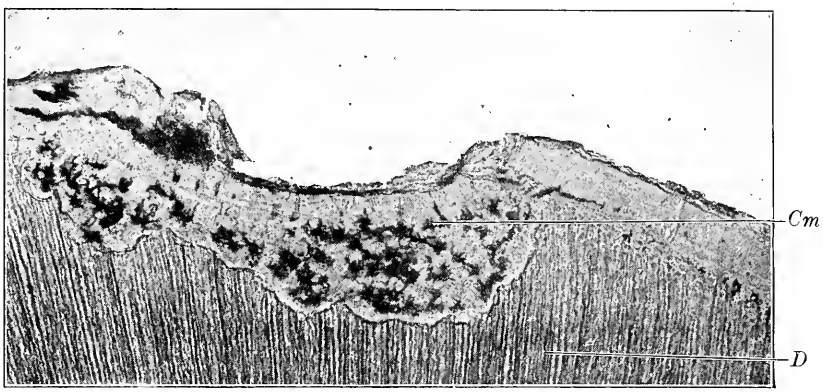

FIG. 74.—Record in the calcified tissue of an absorption repaired: *D*, dentin; *Cm*, cementum filling absorption cavity. (About 40 ×.)

Epithelial Structures of the Membrane.—The peridental membrane contains cellular structures of epithelial character which are so conspicuous that they demand consideration though their nature and origin are not as yet fully understood.



FIG. 75.—Section showing absorption of the tooth of a sheep: *a*, cementum; *b*, osteoclasts in cementum and dentin; *c*, osteoclast in the peridental membrane.

These structures were first well illustrated and described by Dr. Black, in his work on the periosteum and peridental membrane, in

[1] Absorption of the Roots of Teeth, by Newton G. Thomas, Cosmos, 1920.

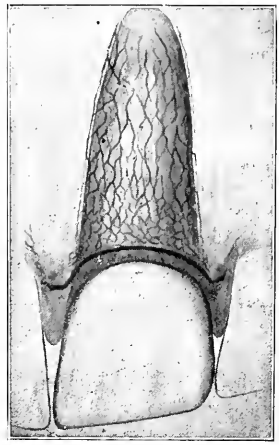

FIG. 76.—Diagram of glands of peridental membrane. (Black.)

FIG. 77.—Epithelial structures of the peridental membrane (from sheep): *Fb*, fibroblasts; *Ec*, epithelial structures; *Cb*, cementoblasts; *Cm*, cementum; *D*, dentin. (About 468 ×.)

1887, and were called by him the glands of the peridental membrane. About the same time von Brunn[1] described what are probably the same structures, and which he regarded as embryonal remains of the inner layer of the enamel organ, which he described as growing down over the surface of the root. These structures appear as cords of epithelial cells arranged in the form of a network winding between the fibers of the membrane, very close to the cementum and surrounding the root

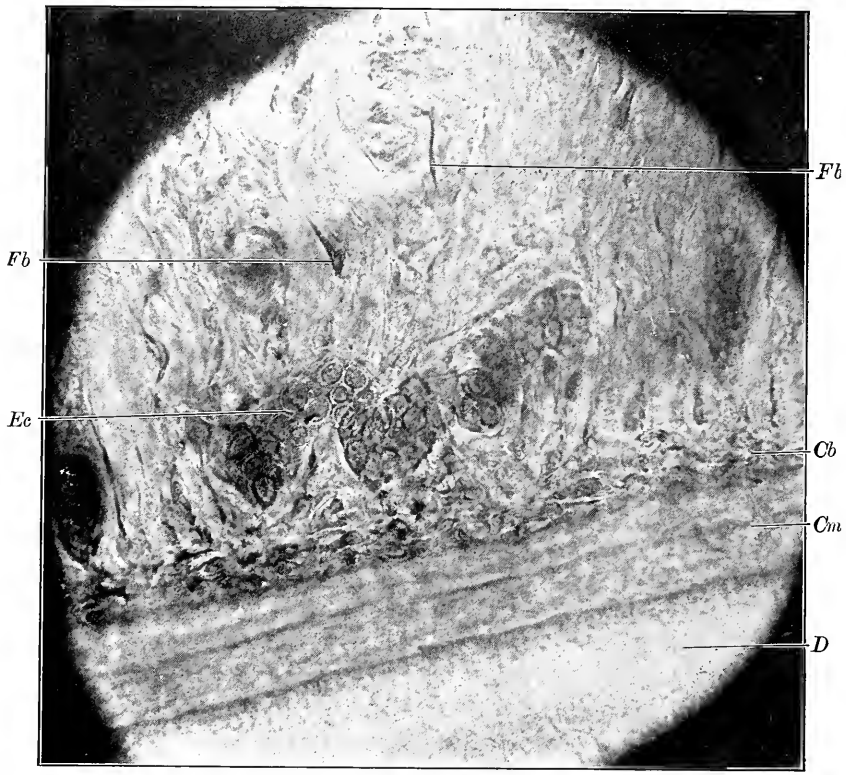

FIG. 78.—Epithelial structures (from sheep): *Fb*, fibroblasts; *Ec*, epithelial structures; *Cb*, cementoblasts; *Cm*, cementum; *D*, dentin. (About 700 ×.)

almost to the apex. This arrangement is illustrated in Fig. 76, a diagram by Dr. Black. The meshes of the net are close in the gingival portion of the membrane, but grow more and more open in the alveolar portion. They are not confined to the membranes of young teeth or the temporary dentition, as Dr. Black has shown them in the membrane of a tooth from a man seventy years old, though, like all of the

[1] Archiv. f. mikros. Anat., 1887.

cellular elements of the membrane, they become less numerous as age advances. These structures are especially well shown in the membranes of the pig and sheep. Fig 77 shows their appearance in a transverse section of the root of an incisor of a sheep; here they swing out from the surface of the cementum and back again in loops, winding in and out among the fibers. Studied with higher powers (Fig. 78), they are seen to be made up of epithelial cells with large oval nuclei which react to the characteristic epithelial stains. They are arranged

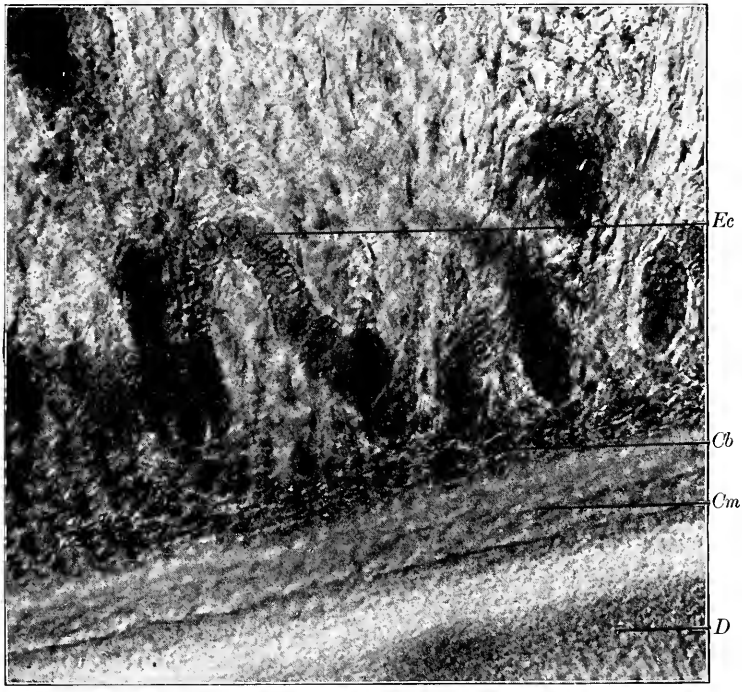

FIG. 79.—Epithelial structures: *Ec*, epithelial cord, apparently showing a lumen; *Cb*, cementoblasts; *Cm*, cementum; *D*, dentin. (About 500 ×.)

in cords, though sometimes what seems to be a lumen of a gland tubule can be found (Fig. 79). The cords are invested with a delicate basement membrane, but no special relation to bloodvessels has been demonstrated. The attempt to show their connection with the surface epithelium has thus far failed. As the gingiva is approached (Fig. 80), they seem to swing out from the surface of the root and are lost between the projections of the epithelium lining the gingival space. There is evidence that these structures are, at least in some cases, of importance as the primary seat of pathologic conditions of the membrane.

FIG. 80.—Longitudinal section: *Ep*, epithelium lining the gingival space; *Gg*, gingival gland, so called; *D*, dentin; *N*, Nasmyth's membrane; *Du*, duct-like structure stretching away toward the gingiva from the epithelial cord, seen at *Ec*; *Cm*, cementum, separated from the dentin by decalcification. (About 50 ×).

Bloodvessels and Nerves of the Membranes.—**Bloodvessels.**—The blood-supply of the peridental membrane is very abundant. Several vessels enter the membrane from the bone in the apical region. These arteries branch and divide, forming a rich network, from which the capillary vessels are given off. The arterial network is constantly receiving vessels which enter the membrane through Haversian canals

FIG. 81.—Unstained section, showing lymph capillaries of the tooth side of the gingivæ and their drainage through the ligamentum circulare to the peridental membrane.

opening on the wall of the alveolus, and in this way the size of the vessels passing occlusally is maintained. Arterial vessels also enter the membrane over the border of the process. This double or triple supply of the membrane is important, as it maintains the health of the membrane when the supply entering through the apical region is entirely cut off by alveolar abscess. While the arterial supply of the membrane is very rich, the capillaries in the membrane are comparatively few. This is, however, a characteristic of connective-tissue membranes.

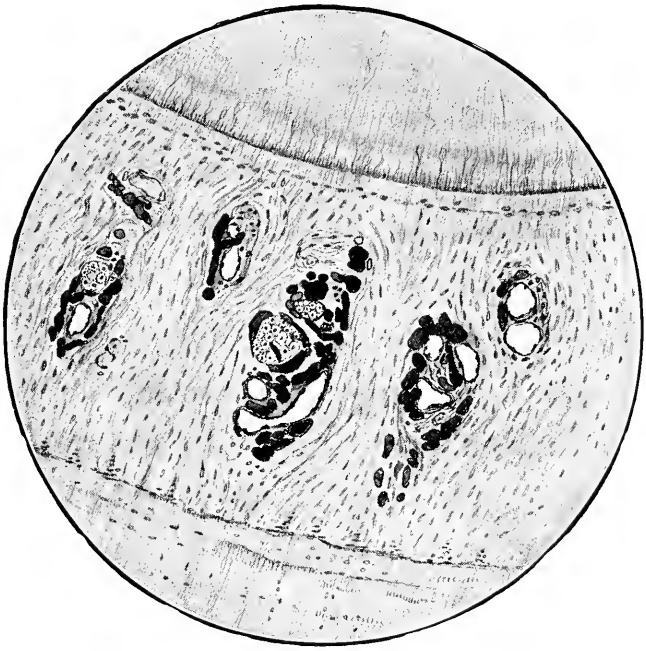

FIG. 82.—Transverse section of the peridental membrane; showing injected lymphatic vessels (oc., 3; obj., 16 mm.; reduced about one-tenth).

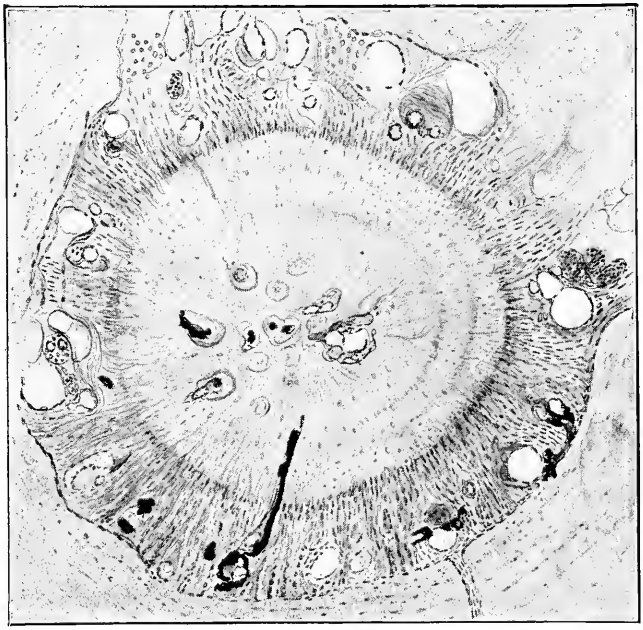

FIG. 83.—Transverse section just at the apex of the root, showing injected lymphatic vessels in the peridental membrane and in the canals passing to the pulp (oc., 2; obj., 16 mm.; reduced about one-third).

Space will not permit an extended description of the lymphatics of the dental region; for this the reader is referred to other and more extended treatises.

The mucous membrane of the mouth, lips, cheeks, alveolar process and gums gives rise to a very rich network of lymphatic capillaries which drain through a limited number of trunks to the sub-mental, the submaxillary and the upper group of deep cervical lymph glands. The capillaries of the labial and buccal slopes of the alveolar process including those from the outer slopes of the gingivæ pass to the reflection of the soft tissue from the bone to the lip or cheek. On the lingual side, in the upper arch, they pass obliquely backward and to the upper

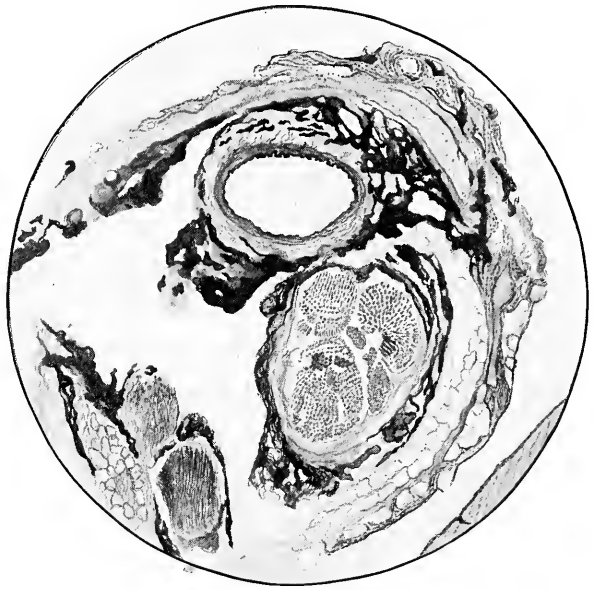

Fig. 84.—Injected lymph vessels in the inferior dental canal.

group of deep cervical nodes; in the lower, those from the incisal region probably pass to the submental nodes, while those from the molar and bicuspid region join the collecting trunks from the lateral portions of the tongue.

The course of this drainage is important in the effect of radical curetting of infected areas about the teeth.

The first injections of the lymphatics of the peridental membrane have been made in the last year or two. As a result of this work, the following statements can be made with some positiveness. The lymphatics arising in the papilla under the epithelium on the buccal and lingual slopes of the gingivæ pass outside of the periosteum over the

alveolar process to a wreath of collecting trunk at the reflection of the soft tissues from the bone to the lips or cheek. The lymphatics arising in the papillæ of the connective tissue supporting the epithelium of the gingival space pass close to the cementum, penetrate the ligamentum circulare and extend in the interfibrous tissue with the bloodvessels and nerves through the peridental membrane to the apex of the root. They anastomose with the vessel in the bone of the alveolar process. At the apex of the root they receive the vessels from the dental pulp and pass through the bone to the inferior dental or infra-orbital canal. They have been traced emerging from the anterior openings of these canals, and to the submaxillary lymph nodes, but it

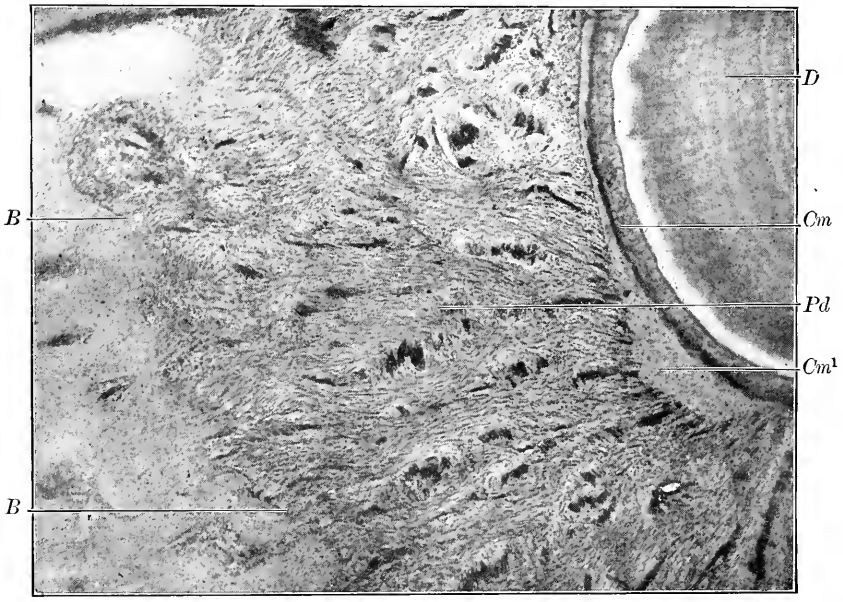

FIG. 85

is probable that from the region of the second and third molars they emerge from the posterior openings of these canals and pass to the upper groups of deep cervical nodes. The course in the incisor region is also not positively determined. It is probable that some of the vessels from the lower incisors drain through the submental nodes and those from the upper incisors probably become superficial on the outer surface of the maxilla or on the floor of the nose. In the dog's head illustration, injections were made only in the canines and first molars and the injecting fluid was followed throughout its course to the submaxillary nodes.

Nerves.—The nerves of the peridental membrane have not been sufficiently studied to be described in detail. Six to eight medullated

nerve trunks enter the apical region in company with the bloodvessels, and they receive other trunks through the wall of the alveolus and over the border of the process, but the manner of their distribution and the nature of their endings are not known.

The Changes which Occur in the Membrane with Age.—When a tooth is erupted the roof of the bony crypt in which it was enclosed in the body of the bone is removed by absorption and the crown advances through the opening. The diameter of the alveolus at that time is, therefore, greater than the greatest diameter of the crown, and

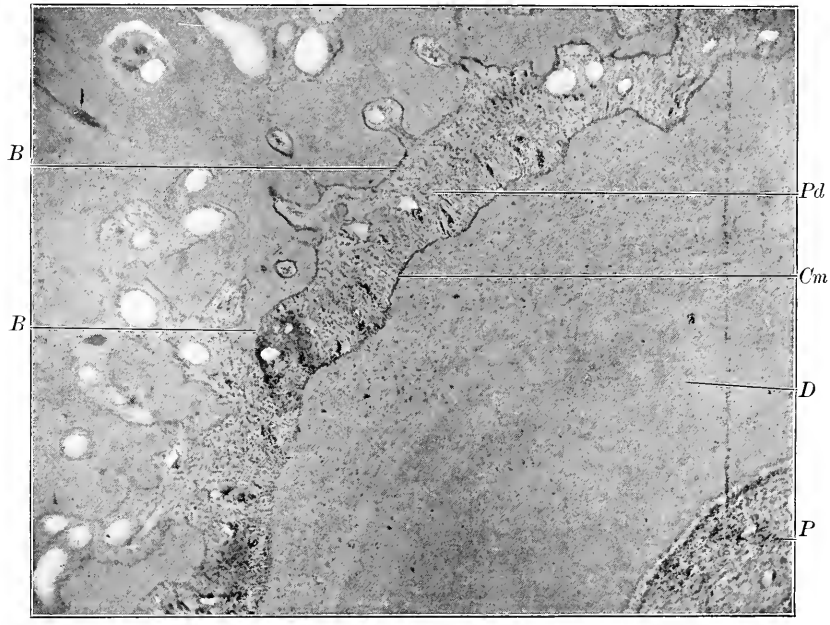

FIG. 86.—Young and old membranes (from sheep): *D*, dentin; *Cm*, cementum; *Cm*^{1}, thickening of cementum to attach fibers at the corner; *Pd*, peridental membrane; *B*, bone forming the wall of the alveolus; *P*, pulp. (About 80 ×.)

the peridental membrane which fills the space is very thick. By the formation of bone on the wall of the alveolus and the formation of cementum on the surface of the root the thickness of the membrane is reduced. In the young membrane most of the large bloodvessels are found in its outer half, forming a rather defined vascular layer near its center. In the old membrane most of the bloodvessels are found very close to the surface of the bone, often lying in grooves in its surface. Both young and old membranes are illustrated in Figs. 85 and 86, which are taken from the temporary teeth of a sheep, one just after eruption and the other shortly before the time of shedding.

CHAPTER III.

PREVENTIVE DENTISTRY.

By RUSSELL W. BUNTING, D.D.Sc.

The term preventive dentistry has been given a very flexible interpretation and has included a wide range of operative and prophylactic procedures. Not only has it been applied to the prevention of dental disease, but also to the prevention of general diseases which may result from dental or oral infection. As a result of the different viewpoints of writers who have dealt with this subject, various statements and opinions have appeared which are so contradictory and confusing that in the minds of many the exact meaning and significance of the term preventive dentistry is not clear. Strictly speaking, preventive dentistry should consist of the employment of those measures which will tend to prevent dental and oral diseases; but, as will be pointed out later, the successful accomplishment of this object will effectually prevent many general bodily diseases, so that in the realization of one the other is attained. Preventive dentistry in its broadest sense, therefore, aims not only at the prevention of dental diseases, but also at the prevention of any general disorders which might arise as a result of dental disease. These two conceptions are therefore so closely related that one may not well be considered apart from the other.

In a consideration of our present knowledge regarding the prevention of dental disease, it must be admitted at the outset that as yet no absolute methods of control have been found by which an immunity to any of the special dental affections may be attained. No panacea, specific drug, or vaccine has been discovered which will exert a definite protective action against dental diseases after the manner of typhoid and diphtheria immunization. Although dental diseases are not absolutely preventable, it may be said that they are partially or relatively preventable, for by the employment of certain measures the occurrence of dental disease may be decreased and in many cases entirely eliminated. And further, dental disease may be permanently arrested if taken early in its course, whereby the extent of the lesion is limited and serious destruction of the tissue prevented.

Preventive dentistry therefore may be said to consist of the employment of all those measures which tend to decrease the inception of oral diseases and in the early application of operative procedures to arrest the progress of lesions which have already occurred. In many

respects the practice of preventive dentistry is not unlike the present methods of preventing tuberculosis. Preventive medicine has discovered no infallible cure for this dread malady, but has found that the observance of proper life conditions and hygiene will, as a rule, successfully prevent its occurrence even in individuals who have a tendency toward phthisis. And in those cases in which the disease has already begun, if taken in the early stages, the lesion may be checked and healing effected. At the present time, the greatest success in the prevention of dental diseases and tuberculosis lies in the employment in each case of those specific measures of partial prevention which tend to inhibit these diseases. It is to the application of these measures of prevention to dental diseases and their systemic effects that this chapter is devoted.

The practice of dentistry and medicine in the past was limited to the treatment of diseases which had already manifested themselves and to the repair of tissues which had been damaged by disease or injury. But in recent years both professions have recognized their inability to maintain the health of the human race by curative measures alone and have come to see that there is great need for more effective means of disease prevention. The study of methods by which diseases may be prevented has become, therefore, an important branch of dental and medical practice.

In the field of dentistry, the greatest thought and energy have been directed in the past toward the perfection of various operative procedures by which the dental tissues, which have been damaged by disease, might be repaired, and their functions restored. To this end dental technics have been developed to such a high degree of perfection that extensive restorations and the rehabilitation of badly diseased mouths have been made possible. Today, therefore, by virtue of modern dental art, many cases which formerly would have been considered hopeless and condemned to the forceps may be rebuilt and restored to masticatory efficiency and esthetic appearance. In this manner dentistry has endeavored to play her part in the general scheme of public health.

But in the light of recent developments in medical science grave questions have arisen as to the safety of many operative procedures in dental practice. This question was most forcibly brought to our attention by Wm. Hunter,[1] of England in a series of papers in which he severely arraigned the practice of dentistry, especially the so-called "American Dentistry" as carried on in England. He stated that many dental restorations, such as gold fillings, crowns, and bridges cover and

[1] Hunter, Wm.: The Role of Sepsis and Antisepsis in Medicine, London Lancet, January 14, 1911; Dental Cosmos, July, 1918, p. 585.

conceal septic material about the roots of teeth, and that these infections constitute a grave menace to the health of the individual. He believed that these infectious organisms might enter the blood stream, be distributed throughout the body, and give rise to a wide range of disturbances, namely, affections of the digestive tract (ulcers, colitis, enteritis, etc.), of the glands (adenitis), of the blood (anemia, and septicemia), of the joints (arthritis), of the kidneys (nephritis), and of the nervous system. It was the opinion of Hunter that these septic teeth were retained in place and the areas of infection hidden for many years by reason of faulty and ill-advised dental operations when, for the good of the patient, they should have been extracted or allowed to exfoliate. He inferred that the poor people who could not afford such dental restorations were more fortunate than those who could and did have them because in their case the diseased roots would tend to be exfoliated and the peridental infections might escape to the surface rather than be confined in the tissues and enter the circulation.

These criticisms at first aroused a storm of resentment and protest on the part of the dental profession. They believed that the charges made were unwarranted and unjust and they could not conceive the possibility that skillful works of dental art by which diseased mouths had been made serviceable and comfortable could be anything but beneficial to the individual. But because of the interest which was aroused in the question, extensive and careful studies of the peridental tissues were made to determine the prevalence and extent of peridental infection. By the wide application of improved methods of dental roentgenographic technic, a great mass of data has been gathered and reported, the results of which have been so startling that they have revolutionized many of our previous concepts. For a clear understanding of these findings the reader is referred to the original reports of investigation, a partial list of which is appended.[1] The data which

[1] Rosenow E. C.: Elective Localization of Streptococci, Jour. Am. Med. Assn., November 13, 1915, p. 1687.

Rosenow, E. C.: The Relation of Dental Infection to Systemic Disease, Dental Cosmos, May, 1917, p. 485.

Rosenow, E. C.: The Pathogenesis of Focal Infections, Jour. Nat. Dent. Assn., February, 1918, p. 113.

Billings, Frank: Focal Infection, Jour. Am. Med. Assn., September 12, 1914, p. 899.

Mayo, C. H.: Constitutional Diseases Secondary to Local Infections, Dental Review, April, 1913, p. 281.

Mayo, C. H.: Mouth Infection as a Source of Disease, Dental Summary, January, 1915, p. 1.

Mayo, C. H.: The Control of Focal Infections, Dental Cosmos, November, 1918, p. 963.

Hartzell, T. B., and Henrici, A. T.: Report of Mouth Infection Research Corps of the National Dental Association, Official Bulletin, Jour. Nat. Dent. Assn., October, 1914, p. 48; 1915, p. 333; November, 1916, p. 333; May, 1917, p. 477.

Black, A. D.: Roentgenographic Studies of Tissues Involved in Chronic Mouth Infections, Jour. Am. Med. Assn., October 19, 1918, p. 1279.

Fischer, Martin: The Relation of Mouth Infection to Systemic Disease, Dental Summary, August, 1915, p. 607.

were obtained by these and other students of the subject clearly revealed the fact that peridental infection and sepsis exist about the roots of teeth far more commonly than previously had been suspected. Large and small areas of necrotic change were discovered in the bone and peridental membrane about the apices of devitalized teeth, as well as deep septic pockets about the roots of pyorrhetic[1] teeth. Upon examination these areas were found to contain pure or mixed cultures of streptococci, staphylococci, pneumococci and other organisms, among which the Streptococcus viridans appeared to be especially prominent. Many of these septic areas produced no pain and gave no outward evidence of their presence other than that shown by the roentgenogram. Clinical histories revealed that many of these infections had in all probability existed for months or years about the apices of devitalized teeth, the root-canals of which were incompletely filled, and in deep pockets about loose pyorrhetic teeth which had been held in place by ligatures or bridge work. These peridental infections have been shown to occur with astonishing frequency especially where the state of oral hygiene and the method of treating and filling root-canals of teeth have been of an indifferent character. In tabulations made in the large clinics of the great cities, it was found that over 75 per cent. of the non-vital teeth were septic. It is true that these data were taken from patients coming from the poorer classes for whom dental services had been of an inferior grade, but it was also found that even among the patients of the most skilled operators deep infections occurred with great frequency.

The question then arose as to the significance of these peridental infections and their possible relationship to general health. It was noted clinically that many patients who had considerable oral sepsis were also suffering from certain general disturbances. These disturbances seemed to be of wide range but the most prominent and frequent in occurrence were joint affections (arthritis) and heart lesions (endocarditis and myocarditis). Rosenow and others[2] isolated bacterial cultures from the infected peridental tissues and injected them into animals with the result that in many cases the animals showed bodily disturbances similar to those of the patient from whom the cultures were taken. That is, certain organisms, especially the *Streptococcus viridans,* taken from peridental infections and injected into the circulation of an animal had the ability to localize in the joints, heart, or other tissues of the animal and produce pathologic disturbance. Although the theory which Rosenow advanced as to the method by which these bacteria became localized (elective localization) has not received uni-

[1] For use of term pyorrhea, see Chapter XIII.

[2] Loc. cit.

versal corroboration, the fact remains that septic material taken from the tissues about the teeth and injected into animals will produce in them general disturbances of bodily health, which in many instances, are closely parallel to the clinical findings of the patient from whom the infectious organisms were taken. All septic areas about the teeth are therefore looked upon today as potential foci of general infection from which organisms and their products may and frequently do spread by way of the lymph and blood-stream to the various tissues and organs of the body. Clinical observation teaches us that not every infection of the peridental tissues gives rise to systemic disorders, for in many instances these tissues are seriously infected while the general health is seemingly unimpaired. In cases of this kind the local tissue reactions are so complete that they effectually confine the infectious organisms and prevent their spread in the general circulation. But there is always the possibility that such localized infections may break through the protective defenses at some future time, especially during a general decline of body reactions and tissue defense.

At the present time, therefore, there remains little room for doubt that systemic infection may, and frequently does, arise from localized areas of sepsis about teeth, many of which may give no evidence of their presence other than that shown by the roentgenogram. Consequently dental operative procedures and oral sepsis have come to be recognized by both the dental and medical professions as matters of great significance to general health. No longer may the mouth be considered as a separate and independent part of the body, but rather, it must be viewed as an important and strategic avenue by which pathogenic bacteria may gain entrance to the general circulation.

As a result of this newer conception of oral infection and the manifest relationship of dental health to the general health, dentistry is confronted with serious problems and responsibilities. Many dental operative procedures which in the past have been considered safe and well-founded are now known to be dangerous and often highly injurious to the health of the individual. The question has arisen therefore, "What dental procedures are safe and sane?" In answer to this question a very careful study of all departments of dental practice which have a bearing upon oral sepsis has been made with the view of proving the safety of each operation and discarding from dental practice all those procedures which are unsafe. Consequently, the viewpoint of practitioners of dentistry has undergone such a radical change that tooth conservation, which was formerly considered to be the matter of greatest importance, has been superseded by, and made secondary to, the question of safety in respect to oral sepsis and systemic infection. Already marked changes have occurred in dental teaching and practice and it is reason-

able to expect that as our knowledge of oral sepsis shall be increased by future study and research, further modifications will be made in operative dentistry to insure the safety of its procedures. It is today generally conceded that fillings, crowns, and bridges should not be placed on teeth which have septic areas about them and that all possible means should be utilized to discover the presence of such infection before beginning operative procedures. Severe lesions in the peridental tissues either apical or pyorrheal are no longer treated with the hope of cure, but on the contrary the affected teeth are extracted for the safety of the patient. Indeed, there are many who claim that no devitalized teeth should under any circumstance remain in the mouth, believing that they always constitute a possible source of infection. On the other hand, there are many others who believe that it is possible to fill the root canals of devitalized teeth in a manner that is above reproach and are attempting in every way to perfect the technic of this operation. Operative dentistry then is undergoing a change in its policies by which it is making an honest attempt to meet the new situation to the end that its procedures may be safe and sane as regards dental sepsis and systemic involvement. And not until all dental operations shall be so ordered that the possibility of oral infection is minimized or removed will dentistry fulfill her duty as a guardian of public health or be fully accepted as a benefit to mankind.

ORAL SEPSIS.

The term oral sepsis is used to denote a *relative state of mouth infection*. The oral cavity is never sterile but, on the contrary, continually harbors various forms of bacteria, pathogenic and non-pathogenic, in health as well as in disease. These organisms thrive among the oral secretions and retained foodstuffs, living in symbiotic relationship to each other. In health, the mucous membrane presents an efficient and continuous barrier against infectious organisms by which the mouth bacteria are prevented from entering the deeper underlying tissues. As long, therefore, as the protection is complete, the oral microorganisms are segregated in the mouth cavity and the digestive tract and are of no apparent significance to the general health. Normally the bacterial flora of the mouth leads a low-grade, saprophytic existence quite independent of the body as a whole. But when, by reason of poor mouth hygiene, quantities of food debris are retained about the teeth, fermentations take place and the bacterial flora is greatly increased. In such cases certain types of organisms may attain a high degree of virulence producing rapid and extensive fermentation thereby changing

the bacterial picture of the oral cavity from a normal low-grade flora to that of a vicious, harmful overgrowth of microörganisms capable of destroying the protective mucous barriers of the mouth and invading the deeper tissues. This latter state is known as *oral sepsis.*

The manifestations of oral sepsis present a wide range of variation dependent upon the type or types of organisms which predominate in the overgrowth, the quality of oral hygiene, and the general health of the host. Clinically, two general classes may be distinguished, namely acute and chronic. The former consists of open and manifest infections which rapidly involve the mucous surfaces of the oral cavity. They excite intense inflammatory reactions in the gums, the cheeks, and the tongue accompanied by more or less ulceration and desquamation of the superficial tissues. To these the general term *stomatitis* is applied, which includes a wide range of ulcerative conditions dependent upon the type of predominating organism and the severity of its proliferation. As a rule, these acute infections run a rapid and virulent course and the symptoms which they produce are so alarming that the attention of the patient and the operator is readily attracted to them. When prophylactic and abortive treatment is applied they are promptly controlled and the tissues usually return to normal within a few days.

Unlike the acute type, the chronic forms of oral sepsis are mild and inconspicuous in their action. They consist in an overgrowth of organisms which do not produce ulceration or active inflammatory reactions in the tissues. Thriving upon the retained foodstuffs about the teeth and in mucoid plaques in the gingival areas they set up a chronic low-grade irritation in the gum tissues, as a result of which chronic inflammation and slow degenerations of the peridental tissues ensue. By reason of the insidious manner of their growth these chronic infections may be easily overlooked and frequently may only be recognized by staining the teeth with a disclosing solution. Consequently they may exist in a mouth unobserved for months or years and slowly accomplish a progressive degeneration of the peridental tissues, thereby gaining entrance to the underlying deeper structures.

Recent investigations have been directed toward a study of the various organisms which are involved in the several types of oral sepsis. It has been found that in the acute ulcerative types of infection and in abscesses the predominating organisms are of a purulent, hemolytic type which have the ability to destroy tissue rapidly with the formation of pus. Among others Streptococcus pyogenes, Staphylococcus pyogenes albus and aureus, Bacillus pyocyaneus are commonly found. Against them intense inflammatory reactions are set up in the tissue by reason of which their course is limited and their activities confined. The active and purulent types of infection, there-

fore, being restrained by the protective powers of the tissues, as a rule, do not tend to spread far from the original seat of inoculation.

In the subacute or chronic forms of oral sepsis the predominating organisms are usually a non-purulent, non-hemolytic type among which Streptococcus viridans occurs with the greatest frequency. Various streptococcal strains, of which viridans is one form, may be demonstrated in practically every case of non-purulent gingivitis and pyorrhea and in the periapical affections known as granuloma. This type of organism does not excite active tissue reactions but rather induces in them progressive degenerations against which the tissues have little power of self protection. There is, therefore, a tendency for these chronic types of infection to infiltrate deeply into the tissues which they attack and on gaining entrance to the bloodvessels of that region they may be introduced into the general circulation.

When we view these two forms of oral sepsis in the light of their significance to the general health, it becomes evident that they are not of equal importance. In former times the purulent type of infection was looked upon with the greatest concern, and indeed, the peridental abscess, purulent forms of pyorrhea and active tissue ulcerations were the only infections that were given any serious consideration. It was recognized that these infections would in time produce marked and often extensive degeneration of the local tissues and occasionally the more severe types resulted in general septicemia. But more recently we have come to have a greater fear of the insidious forms of bacterial invasion, namely, the non-purulent streptococcal group of organisms which manifest a greater tendency to penetrate into the deeper tissues and enter the general circulation.

The true significance of these two types of infection and the manner of their action may be expressed in terms of tissue resistance. Nature has built in every oral cavity a complete lining which offers resistance to the entrance of all kinds of organisms into the underlying tissues. It is only by injury to this mucous membrane, or the teeth, that oral sepsis may gain entrance to the general circulation. And when, either by accident or by bacterial erosion, a lesion has been made in the protective covering, the infectious organisms meet in the tissues a second line of defense which consists of all the protective reactions of the bodily tissues; namely, phagocytosis, bacteriolysis, antitoxins, granulation tissue, etc. By these reactions the tissues seek either to overcome and destroy immediately the infectious organisms, or, failing in this, to form a protective wall of granulation tissue about the septic invader to limit its action and confine it to one locality. This wall at first consists of masses of lymphocytes and leukocytes which have rallied to the spot under the direction of chemotaxis, and many new

and rapidly growing bloodvessels which afford a very rich and free blood supply to the part. Later, if the tissues succeed in checking the invasion, this limiting wall is organized into a more permanent line of defense by the growth of connective-tissue fibers until the infectious material is entirely enclosed in a fibrous tissue sac. When this has been accomplished, the bacteria, as a rule, are effectually confined, although the possibility still remains that they, or their toxins, may make their escape in limited quantities by way of the capillaries which enter and leave the sac. But the tissue reactions which have just been described are not always complete. They, in the first place, are dependent upon the type of bodily health and general activity which the individual possesses. When the general health is good the local reaction to infection will be far more vigorous than when the vitality is low. In the second place, as the local tissue reactions arise in response to bacterial injury, the type of reaction which is produced will be determined largely by the type of invading organism. Against the acute purulent types of infection the tissue reactions are high and, as a rule, sufficient to check and control effectually the invader, while against the non-purulent streptococcal type of infection the protective reactions are usually weak and insufficient to check the penetration of the organisms into the tissues and the circulation. It is therefore that type of infection against which the protections are weak that is most to be feared, inasmuch as even in healthy individuals the tissues are frequently unable to combat it successfully, but are seemingly at the mercy of the invader.

In a consideration, therefore, of oral sepsis in its relation to systemic disease, we must recognize that those forms of infection which are low grade and non-purulent are most to be feared, not only on account of the inability of the tissues to combat them, but also because of the fact that since they excite no active tissue reactions, their invasion is insidious, almost imperceptible, and their presence may be overlooked easily. It is then to the control of this type of infection that the greatest attention should be given in the practice of preventive dentistry.

In a study of methods by which these infections may be controlled, we are led to consider the avenues by which the organisms break through the protective defenses of the mouth: that is, the areas of the oral cavity which are most susceptible to bacterial invasion and which, therefore, should be watched most carefully. Practically all deep infections of the oral tissues occur in one of two general localities; the one through a carious defect in a tooth involving the pulp, and the pulp-canal and thence to the periapical tissues; the other by way of the gingival crevice about the neck of a tooth into the deeper peridental tissues.

So comprehensive are these two avenues of infection that could they be successfully protected and closed, practically all danger of oral sepsis would be eliminated and systemic disease from a dental source would most effectually be prevented. It is therefore to the guarding of these two gateways of infection that preventive dentistry must be directed.

The question next arises as to the manner in which these invasions occur. In the first type we find that the initial step is a lesion in a tooth, a carious cavity, which is laden with infectious organisms characteristic of the mouth flora. As soon as the pulp is exposed, these

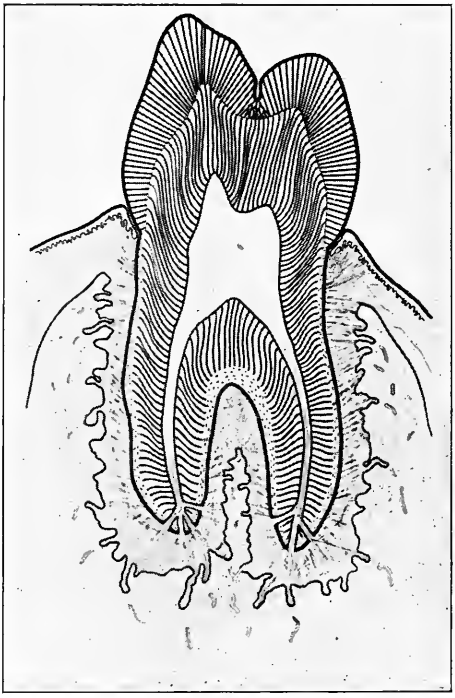

Fig. 87

organisms promptly invade the pulpal tissue, through which they pass out through the apex of the root to be implanted in the periapical tissues. If the infection be purulent in type, an acute abscess is formed, accompanied by pus and a severe inflammatory reaction. If, however, the infection be low grade and non-purulent in type, a mild tissue reaction will be set up and a gradual destruction of tissue will be effected with little or no outward signs or symptoms in evidence thereof. At the present time we do not fully understand the significance of these lesions. In many cases it seems that the tissue

is able to construct a fibrous tissue wall about the infection forming a so-called granuloma. Upon examination these granulomata are frequently found to be sterile, from which it is inferred that the organisms which caused the lesion have been overcome by the bactericidal properties of the surrounding tissues. But many of these non-purulent lesions contain pneumococci and Streptococci viridans which may act as potential foci of systemic infection. As we have at present no means at hand by which we may distinguish clinically the dangerous from the benign types, all granulomata must be viewed with suspicion.

The successful treatment and elimination of periapical infections are not easily accomplished. As a rule they have invaded far beyond the end of the root so that the treatment of these lesions through the root-canals is uncertain and of doubtful value. For the most part, surgical excision of the root and curettage of the infected bone through the gum tissues (root resection or apicoectomy) is the only efficacious manner of treating all such cases save perhaps the more incipient forms. And, indeed, there are many who hold that no tooth, the root-end of which has been seriously affected, should in any case be retained.

Every tooth therefore in which the pulp has died from bacterial invasion, by accident, or by operative procedures, must be looked upon as a possible source of infection. The difficulty of completely filling tortuous root-canals and the ease with which infectious matter may be introduced during the operation of cleansing and filling the root-canals make the coefficient of error and the probability of subsequent infection exceedingly high.

A study of roentgenograms of a large number of pulpless teeth has demonstrated clearly that the most certain root-canal filling is a living and healthy pulp. That is not to say that root-canals of such a tooth cannot be filled safely, but the fact should be emphasized that the successful filling of root-canals is an exceedingly difficult and hazardous undertaking which should be attempted only under the most favorable circumstances and performed with the most careful technic.

The handling of pulpless teeth and root-end infections is, therefore, a difficult problem in dental practice. It is conceded, however, that periapical infections seldom occur on teeth having vital pulps. If, therefore, the pulps of all teeth could be kept alive, the dangers of periapical infection as well as the difficulties of root canal operations would be eliminated. Going still further, we may say that the great majority of pulps die, either directly or indirectly, from dental caries. If then, we could either prevent caries or check its lesions before they involve the pulp, practically all teeth might remain alive. It follows, therefore, that the absolute prevention and control of dental caries would automatically result in the prevention of periapical abscesses

and granulomata with all their attending sequelæ. It is then in the prevention and control of dental caries that the greatest hope of success lies, by closing the root-end route through which oral infections may enter the general circulation.

PERIDENTAL AFFECTIONS.

Turning to the second order of dental infections, the peridental type, we find somewhat different conditions prevailing. In the first place, we observe that of all the mucous coverings of the mouth the gingivæ are most vulnerable to the attack of infectious organisms. In all other portions of the mouth the mucous membrane with its thickened epithelium offers a continuous protective barrier against the entrance of infectious organisms. But in the process of eruption of the teeth, holes are made in this membrane, one for each tooth, which apertures persist as long as the tooth remains in position. Nature attempts to protect the body at these places and to close the door against the entrance of infection through them by causing the borders of each opening to be drawn in tightly about each tooth with the formation of a purse-like flap, the gingiva, which normally hugs tightly about the neck of each tooth. On the inner side of this gingival flap there is a shallow space between it and the tooth, the gingival crevice, at the bottom of which the mucous membrane is firmly attached to the pericementum by strong connective-tissue fibers. In health these gingival tissues are thin, firm, and so closely adapted to the teeth that they offer considerable resistance to the entrance of infectious organisms. So effective is the gingival attachment that as long as the tissues remain in perfect normality they successfully protect the underlying tissues. But when masses of infectious material remain for some time in close contact with the gingivæ, as in cases of faulty oral hygiene, or when they are disturbed by the traumata of food, calculi, crowns, bridges, overhanging fillings, etc., the gingivæ are irritated and become inflamed. Because of the fact that the gingival tissues have an end-circulation, it follows that slight irritations may produce profound disturbances such as active and passive congestion, thrombosis, and other inflammatory reactions. In the event of any of these conditions, the health and normal function of the gingivæ are profoundly disturbed. No longer do these tissues cling tightly about the teeth, but rather do they swell and become puffy, their normal tone is lost and they fall away from the teeth. In this manner the gingival crevice is opened to mouth infection and an excellent opportunity is offered for the growth of infectious organisms. The surrounding tissues also, being disturbed in their circulation and

metabolism are often less able to combat these infectious invaders. The result is that deep penetration of septic organisms takes place. If the infection be of a purulent type, superficial ulcerations of the gingival tissues are produced or the deeper peridental affections characteristic of true pyorrhea are affected consisting of the formation of a pocket along the side of the root of the tooth and the production of pus. If the infection be non-purulent in type, a slow disintegration of peridental tissues may take place with the formation of pockets on the lateral surfaces of the root in which no pus will be found. In either case, the infectious organisms have passed the epithelial barrier and have become firmly entrenched in the deeper tissues where they are either confined by the local tissue reactions or spread through the circulation to remote parts of the body. The early stages of this process are known as gingivitis while all forms of deeper penetration and tissue destruction are commonly referred to under the general term pyorrhea alveolaris.

Much has been written regarding the cause, course, and effects of the so-called pyorrhetic types of infection and a wide diversity of opinion is expressed. At the present time, however, the more rational students of the subject agree that all of those conditions begin either as an inflammation of the gingival tissues, or that the presence of gingivitis is an integral part of the process. If this be true, it may be argued theoretically at least, that if the gingival tissues be kept in health, the inception of deep peridental infections would be prevented. And in actual practice this has proved to be true. Few observers today believe that pyorrhea can occur in a mouth in which all the gingivæ are normal and in perfect health. Practically all agree, therefore, that the most successful method of preventing these conditions lies in the prophylactic supervision of the gingival tissues.

In the foregoing consideration of the two most important and almost sole avenues by which oral sepsis penetrates the natural barriers set up against it, we have been led to see that the successful prevention of the one lies in the prevention and control of dental caries, and of the other in the prevention and cure of gingivitis. It may be said, therefore, that if we could keep the teeth intact, and the gingivæ in health, practically all danger of oral sepsis would be removed. In our discussion of preventive dentistry, therefore, it is toward the control of these two affections, dental caries and gingivitis, that the greatest attention will be directed.

The Prevention of Dental Caries.—The history of the development of our present knowledge of dental caries is an interesting one. Examinations of crania of earlier races show that all through the centuries every type of people has been afflicted with this dental affection. In

the early Greek and Roman writings frequent allusion is made to the pain and discomfort of decayed teeth, and various speculations were indulged in regarding the cause and nature of the process. It was in the 18th century that the first real interest was shown in the study of dental caries and through the years that followed various conflicting opinions were held concerning the etiology of caries and about each certain definite schools of thought and teaching were built until the time of Miller who gave what seems to be the true solution of the problem.

Prominent among these hypotheses, the inflammation theory received a wide acceptance from 1754 to 1835 and was championed by such men as Hunter, Fox, Bell, Jourdain and many others who believed that the hard structures of the tooth possessed a blood circulatory system, similar to bone, and that disturbances of circulation resulted in a necrosis of the tooth quite like bone necrosis. They therefore looked upon dental caries as a disease which originates in the interior of the tooth, probably the dentin, and progresses outward to the surface of the enamel, the process being alluded to by Koliker of Philadelphia as a "bony abscess."

In 1835 Robertson of England took exception to the inflammation theory and stated that it "is to chemical and not to inflammatory action that the destruction of teeth must be attributed." He believed that the acids of caries arose from the decomposition of retained foodstuffs about the teeth. This view was corroborated by Tomes who, in his histological studies of the teeth, found that the dentin contained no bloodvessels and therefore could not undergo true inflammation. He turned then to the chemical hypothesis of Robertson as also did Magitot who in 1878 published the most comprehensive treatise of his time in which he described dental caries as a disintegration of the tooth by chemical substances either developed in the mouth or introduced with the food. Watt in 1868 advanced the theory that free nitric, sulphuric, and hydrochloric acids were generated in the mouth as a result of disintegration of foods and that each acid produced a specific type of dental caries.

In 1867 Bridgeman formulated a theory in which he considered dental caries a destruction of the tooth by acids formed from electrolytic action. He believed that the crown of the tooth and the gums were of different potential and that they with the saliva as an electrolyte formed a battery in which acid substances were set free at the positive pole (the crown) which acids decalcified the enamel. So also S. B. Palmer, in 1874, claimed that recurrent caries of a tooth beneath a filling resulted from a difference in potential between the filling and the dentin and in the presence of the saliva a current would be set up with

the formation of acids which either decalcified the tooth or disintegrated the filling.

It was in 1867 that Leber and Rottenstein first called attention to bacteria as a causative factor in the carious process. They succeeded in staining with iodin and identifying several varieties of mouth organisms in carious dentin. They believed that an initial lesion of the enamel by some other means was necessary for the bacterial propagation in the dentin. At the World's Medical Congress in 1881 Miles and Underwood in an exhaustive treatise on the subject characterized dental caries as "a combined action of acids and germs." They believed that the acids which were active in the process were produced by bacterial organisms which lived upon the contents of the dentinal tubuli.

At this time, the knowledge that bacteria caused disease was largely theoretical as no one had been able to demonstrate conclusively the pathogenicity of these organisms. It was not until Koch completed his epoch-making studies in 1880 that specific bacteria could be shown to cause definite lesions and diseases. This he accomplished by the formulation of four rules or tests by which the type of organism might be determined and its responsibility as the cause of disease established. The four rules of Koch are as follows:

1. The microörganism is present and discoverable in every case of the disease.
2. It is to be cultivated in every case of the disease.
3. Inoculation from such culture must reproduce the disease in susceptible animals.
4. It must be reobtained from such animals and again grown in pure culture.

It so happened that W. D. Miller was closely associated with Koch in his laboratory at the time he was pursuing his studies, and as soon as the principle was definitely established, Miller immediately applied Koch's four rules to the problem of dental caries, in order that he might determine definitely whether or not the process was due to bacterial action. It was during the following year that he gave out the results of his studies in what is now known as the Millerian theory of dental caries. Briefly, it may be stated as follows: dental caries is primarily a decalcification of the enamel and dentin of the tooth by organic acids which have resulted from the fermentation of carbohydrates in the mouth and is usually associated with, and localized by, mucoid plaques or films. Secondarily the decalcified dentin is disintegrated by a proteolytic process. The bacteria which produce the initial lesion of enamel caries are not a specific variety but a relatively large group of

organisms which have the ability to form acids when acting on carbohydrates. The process of dental caries is therefore infective in type but certain other attending conditions are necessary for the bacterial action to be effective; namely, carbohydrate food material, and a protective covering by which the acids formed may be held against the tooth and protected from dilution and neutralization by the salivary secretions. Under this so-called mucoid plaque the process of acid production and enamel dissolution may go on unmolested with the result that a lesion in the tooth is accomplished. After the initial cavity is once formed, the bacteria advance deeper and deeper into the tooth progressively decalcifying the enamel and the dentin as long as they are undisturbed. The theory which Miller thus formulated has remained until today as the only tenable concept of the caries process which has so far been advanced.

Although the Millerian theory has given us a fairly definite picture of the manner in which dental caries operates, it did not reveal the methods by which the process may be prevented. Miller later turned his attention to this phase of the subject and spent considerable time in the study of caries prevention. He first sought for some form of antiseptic by which he might eliminate mouth infection. He found it impracticable and virtually impossible to continuously rid the mouth of acid-producing organisms, so that he was convinced that means of caries prevention did not lie in the use of antiseptics or bactericides. Then he began investigation of the methods of mechanically cleansing the mouth and of reducing the amount of carbohydrate and infective materials about the teeth by means of the tooth brush and dentifrices. This line of attack he was still pursuing at the time of his death.

Extension for Prevention.—Since the time of Miller, many valuable additions have been made to our knowledge of the subject, but among these there are few concrete suggestions as to the practical control of the process. Of these the earliest method and undoubtedly the most practical one, so far advanced, is the excavation of cavities which have already begun in the teeth and the filling of the defects with a substance which will arrest the process and preclude a subsequent infection. This procedure has received its most rational and successful application when carried out according to the principles outlined by G. V. Black, known as "Extension for Prevention."[1] Many have observed that caries has a tendency to occur on certain definite areas of the tooth such as the approximate surfaces, and in the sulci of the occlusal surfaces, while it seldom occurs on the angles of the teeth or the cusps. It is argued that if, in the preparation of a cavity, the walls

[1] Black, G. V.: The Management of Enamel Margins, Dental Cosmos, 1891, p. 85.

might be carried outside of the susceptible areas to those of relative immunity, the liability of recurrence of caries would be greatly lessened. The rationale of this method has been supported by years of clinical evidence that leaves little room to doubt its efficacy in caries limitation. It is true that many advocates of this principle have been overzealous in its application, carrying the extension of cavities to great extremes and needlessly sacrificing tooth structure; but those who have extended cavities advisedly and with due consideration of other factors involved, have been rewarded with a high degree of success. It follows therefore that the early detection of caries defects in teeth and the successful repair of these lesions in accordance with the present approved methods of operative dentistry constitute the most effective means of controlling caries when once the process has been inaugurated. The application of these principles in operative dentistry is fully considered in a succeeding chapter.

The Oral Hygiene Movement.—About ten years ago examinations of children in public schools clearly revealed that a great majority of the children were suffering from dental defects and severe oral sepsis for which they were receiving little or no remedial care. So apparent was the need of dental services that municipal dental dispensaries were instituted in the schools for the gratuitous care of the children. The work accomplished was mainly that of cleansing the mouths and teaching the children to keep them clean. On the assumption that dental caries is a filth disease, it was hoped in this manner to limit to a degree the occurrence of caries, and to reduce the oral sepsis present. In addition to cleansing the teeth, inspection was made at regular intervals and cavities were filled promptly in order that a minimum amount of damage might be done by the carious process. The results which have been attained have been so gratifying that school clinics have come into almost universal adoption and have proved to be of real economic value.

A further extension of this service has been more recently made in the establishment of similar dental clinics for the benefit of workers in various mercantile plants and factories. Regular dental examinations of the employes are made and advice given them regarding the care of their mouths. The only operations performed are brief prophylactic treatments, extractions, and emergency relief of pain, the patients being referred to the family dentist for permanent restorations and fillings. Over sixty dental clinics of this kind are now in operation in this country. Without exception they have proved to be of great benefit to the employes of the institutions in which they are operating, and have produced a marked increase in the efficiency of the whole organization.

Oral Prophylaxis.—A most exacting regimen of oral hygiene has been advocated and practiced by certain members of the profession. Acting upon the hypothesis that "a clean tooth never decays," they spend considerable time in polishing the several surfaces of each of the teeth in the mouth in order that they may be easily cleansed by the patient. They enlist the coöperation of their patients and instruct them in the performance of a vigorous and thorough daily care of the mouth. Such patients are seen regularly once a month for the purpose of cleansing those teeth which were habitually missed and encouraging the patients to perfect the personal care of their mouths. This method of practice, which is known as oral prophylaxis, has been followed more or less extensively by a large number of dental practitioners. Perhaps the periodontists have attained the highest degree of efficiency in oral prophylaxis, while other general practitioners have adopted the principles with varying degrees of thoroughness. There is also a difference of opinion as to whether prophylaxis actually prevents dental caries. Certain practitioners affirm that they are able to eliminate practically all caries from the mouths of patients so treated. In evidence they submit many cases of individuals who have been susceptible to dental caries, who cease to have cavities occur under the regimen of oral prophylaxis, and cases of women who have been carried through the susceptible period of pregnancy without dental defect. Many other practitioners having rigorously carried out this method of strict oral prophylaxis, or a modification of it, state that they have been able to stop the inception of caries in a large number of patients who previously had been susceptible to a marked degree. The more conservative, however, do not as yet believe that immunity from dental caries can, in all cases, be obtained in this manner, but that in a large majority its rate of occurrence is decreased and occasionally it may be entirely prevented by the thorough and continuous practice of oral prophylaxis. Those who have carried out this method with a less degree of thoroughness, have found little or no benefit resulting from it other than the general decrease of oral sepsis.

The diversity of opinion regarding the value of oral hygiene and prophylaxis as a caries preventive, has led to considerable uncertainty in the minds of many as to the rationale of its adoption. The familiar picture of apparently clean mouths being vigorously attacked by dental caries, and filthy mouths that are wholly immune, is to many a direct contradiction of the slogan "clean teeth do not decay." They are, therefore, unwilling to subscribe to or put into practice the principles of strict oral prophylaxis with the hope of preventing dental caries. Rather do they look and hope for the discovery of some other controllable factor in the process of caries by which more definite and tangible

results may be obtained. Let us, then, at this time consider what other methods have so far been suggested by dental research for the solution of this problem.

Sulphocyanate in the Saliva.—In 1900 Micheals of Paris reported studies which he had made of the saliva and its relation to dental caries, stating that the secretions of caries susceptibles differed from those of caries immunes. Among other constituents he noted a difference in the amount of sulphocyanates which he considered to be significant. Acting on this suggestion, a large group of men in this and other countries, began a systematic search of the salivas of carious and non-carious mouths and a wide interest was shown in the investigation. Many reported that a relationship did exist between the sulphocyanates and dental caries, and suggested that potassium sulphocyanate be fed to individuals who were susceptible to dental caries for the purpose of establishing immunity to that disease. Perhaps no other form of caries prevention has received the attention this received for a time; but later investigations discredited the premises of the theory and resulted in its abandonment by all save a few of its most ardent supporters.

Glycogen in the Saliva.—Michaels also stated that the saliva contained glycogen as a variable constituent, and that it was increased in amount by excessive carbohydrate diets and by diabetes. Following this line of thought, Kirk has written voluminously upon the effect of excessive carbohydrate diets as productive of glycogen in the salivary secretions which in turn, he believes, furnishes pabulum for lactic acid fermentation and dental caries. As a caries preventive, he suggests the limitation of carbohydrates in the diet. There is little doubt that carbohydrates are active factors in dental caries for without their presence in some form, lactic acid fermentation could not take place. But the assertion that the most important source of carbohydrates in oral fermentation and dental caries is to be found in the salivary secretions is open to serious objections. In a former contribution,[1] we have reported analyses made of the total carbohydrate content of a series of salivas, comparing the results obtained to the caries susceptibility in each case. By the most exact methods we were able to demonstrate only the most minute quantities of carbohydrate which, when compared with the sugars and starches habitually retained in the mouths, we deemed to be too insignificant to be given serious consideration in the process of caries. Moreover, we were not able to find any analogy between the slight glycogen variations of the samples tested to the caries susceptibility of the individuals from whom they were taken.

[1] Bunting and Rickert: Dental Caries, Jour. Nat. Dent. Assn., No. 4, p. 16.

In a series of articles which he is now publishing, Herman Prinz[1] states that he has made exhaustive search in salivas to determine the presence of carbohydrates and glycogen and has been unable to find them. He definitely denies the presence of sugars in the normal saliva.

On the other hand, it is a matter of common observation that millers, bakers, and confectioners are frequently attacked by rapid and extensive dental caries. Unless their mouths be vigorously cared for, rich, sticky carbohydrate pabulum is adherent to the teeth and fermentations are high. These are the extreme cases of carbohydrate retention to which many other caries susceptibles who ingest considerable quantities of sugars and starches approximate to a less degree, especially if the mouth hygiene is poor. In all of these the quantity of food retained in the mouth furnishes ample material for lactic acid fermentations and greatly exceeds any possible sugar content which the saliva might possess. These retained carbohydrates, therefore, seem to constitute a direct and primary factor in the production of dental caries, for they by their presence, may act as the determining cause of that process. It follows that all the measures of diet selection and mouth hygiene which tend to reduce the sugar pabulum habitually sticking about the teeth will have a direct influence upon the inception and progress of dental caries.

Diets.—Sim Wallace[2] has written extensively on the subject of diets and their relation to dental caries. He believes that the soft and pappy foods which constitute the bulk of diets for younger children are responsible for the prevalence of dental caries during the early years of life. Such foods require little mastication and tend to form a sticky carbohydrate pabulum about the teeth favorable to lactic acid fermentation. Rather, he suggests that children be fed hard and tough foods which afford the necessary exercise for proper development of the jaws, stimulate a copious flow of saliva and salivary ferments to act upon the food in the mouth, scour the teeth and cleanse them from food debris. He also urges that the amount of easily fermentable carbohydrates be limited and followed by fresh fruits, preferably apple, or an acid food or drink which should always constitute the ending of every meal. The results which he has obtained by practical application of these principles in the diets of children in orphanages and in boarding schools have convinced him of their efficacy and their superiority over any methods of artificial prophylaxis. In view of the data which he presents he claims[3] "that dental caries is one of the most

[1] Dental Cosmos, February, 1918, *et seq.*
[2] Prevention of Common Diseases of Childhood, 1912.
[3] Wallace, Sim: Prevention of Dental Caries, Dental Record, 1912.

easily and certainly preventable of diseases and there would seem now no valid excuse for the bringing up of children with decayed teeth."

In his monumental contribution to the subject, H. P. Pickerill[1] also treats dental caries as a problem of dietetics. In many respects his conception of the cause and control of dental caries is similar to that of Wallace, but it differs in that he accentuates the importance of acid foods and fruits in the diet over that of hard and tough substances. Like Wallace, he believes that the occurrence of caries is dependent upon the ability of the mouth to cleanse itself after meals, and that caries may be prevented by the selection of a diet which will promote the normal cleansing factors of the mouth. By extensive analyses of the saliva, he shows a variation in that secretion in response to the stimulation of foods. Dry bread increases the amount of saliva 2 to 1, and apple or orange increases it 6 to 1. He finds that all acid and highly flavored foods increase the saliva in amount, in alkalinity, and in ptyaline content, all three of which are, in his opinion, important in the cleansing of the mouth and the prevention of dental caries. On the other hand, bread and butter, meat, biscuits, sugars, tea, milk and other sapid foods are either neutral or depressant in salivary stimulation. He suggests for caries control that all diets should begin and end with some form of acid, preferably the organic or fruit acids; that sugars should not be eaten to excess and should always be incorporated with some form of acid; and that, so far as possible, the diet should consist of foods having a high flavor and acid taste. He also claims that alkaline dentifrices have a depressant effect upon the secretions, tending to mouth acidity, and suggests the use of acid mouth washes, preferably potassium acid tartrate, 0.50 per cent. The author reviews the prevalence of dental caries among the various nations and peoples of the world and states that among civilized races the susceptibility to caries is high, while in many uncivilized tribes caries susceptibility is low; that the diets of the civilized people are largely unnatural, sapid, and low in acids, while those of the uncivilized people are composed of natural foods, highly flavored and acid; and that caries susceptibility is not due to civilization *per se*, but rather to the adoption of a civilized diet.

The views of Pickerill have been concurred in by Wm. Gies of Columbia University and his co-workers[2] in their voluminous contributions to this subject. They strongly object to the use of alkaline dentifrices and urge the adoption of acid mouth washes as a means of caries prevention. They suggest that organic acids be used for this purpose, and prefer vinegar, either full strength or diluted claiming that it dis-

[1] The Prevention of Dental Caries, H. P. Pickerill, 1912.
[2] Jour. All. Dental Soc., 1912, p. 400; 1913, p. 283 *et al.*

organizes the mucoid plaques adherent to the teeth and stimulates a copious flow of saliva, thereby decreasing oral fermentations and the tendency to dental caries.

It is not practicable to discuss fully in this chapter the significance of these views of caries prevention. It is evident, however, even from a superficial examination that most authors consider the prompt elimination of food debris from the mouth and the attainment of oral cleanliness as matters of the highest importance in the control of dental caries. The possibility of attaining this object by diet alone may be determined only by a wholesale application of these principles to a large number of subjects under direct observation. That hard and coarse foods mechanically cleanse the teeth and stimulate an active flow of saliva to wash the food particles from the mouth is a well-known fact. Consequently, they lessen the amount of carbohydrate material about the teeth and reduce lactic acid fermentation. It is also true that acids stimulate the salivary secretions in amount and in alkalinity and have a tendency to leave the mouth clean. But the universal adoption of acid diets and acid mouth washes is open to question. In a former communication[1] we have reported certain untoward effects arising from the use of acid diets. Patients under our observation gave evidence of pronounced gastric and digestive disturbances while following a prescribed acid diet, and several developed a severe urticaria which could be attributed only to hyperacidity. Others were found who could not tolerate acid mouth washes as their teeth became exceedingly sensitive to slight changes in temperature during their adoption. Prinz also states[2] as his opinion that the correctness of the use of acid mouth washes is not substantiated by clinical experience, that the pharmacologic principle involved in the selection of such solutions is erroneously applied, that constant forcible stimulation of the salivary glands by acids is followed by an impairment of glandular function, and that the acidity of the solution kills the important salivary ferments. It seems wise, therefore, to withhold opinion in regard to this particular procedure until further scientific data have been gathered. It is possible that in certain selected cases where the saliva is thick and mucinous the judicious use of acids in the diet and acid mouth washes may have a beneficial effect; but in cases of thin, watery salivas with a tendency toward erosion of the teeth, it seems to us that acids are contra-indicated.

Carl Röse looks upon dental caries as a form of physical decadence and degeneration due to civilization. The uncivilized man, he believes,[3]

[1] Dental Review, 1916, p. 423.
[2] The Therapeutic Efficiency of Oral Preparations, Jour. All. Dental Soc., June, 1916.
[3] Dental Cosmos, 1912, p. 1214.

has better teeth and less dental caries as a result of the laws of survival of the fittest and sexual selection. Only those having good dental organs are able to subsist on the hard and tough foods which compose their diet. The primitive male chooses a mate that is strong physically and has sound teeth, and the children which result from such union inherit the strong physique and well developed dental organs of both parents, thus continuing the race of caries immunes. Civilized man, on the other hand, is so protected by law that physical strength is not necessary to his existence and the character of his food does not require that his teeth be sound or in a high state of efficiency. Natural selection or survival of the fittest, as regards physical development and dental health has therefore been supplanted among civilized races by panmixia and survival of the physically unfit resulting in a general physical deterioration, one phase of which is dental defect and a tendency to dental caries. Röse, accordingly, looks upon the prevalence of dental caries among civilized peoples as a problem in eugenics and believes that the remedy may be found only in the intermarriage of those who are strong in body and perfect as to dental apparatus. He naïvely accuses the dental profession of aiding in the process of evolutionary decadence of the teeth by so repairing and replacing decayed teeth with crowns and bridges that it is difficult for the casual observer to determine who has good teeth and who has not. The views of the author thus expressed are interesting and worthy of consideration; but the means of control of dental caries which he suggests, namely, the regulation of intermarriage, involves weighty problems in social economics which as yet are unsolved, and their application on a large scale at the present time is impracticable.

Röse also reports[1] that in an examination of a large number of school children in Germany, it was very evident that those who came from sections of the country in which the calcium salts of the water and soils were high had better formed teeth and better dental health than did those who came from localities in which the calcium salts were low. He states that the enamel of the hard and resistant varieties of teeth has a better organization and contains a higher percentage of calcium salts than does that of the softer forms. It is this degree of organization and calcium salt content that, in his opinion, renders them immune to dental caries. In view of this, he suggests that a high calcium diet be maintained and that the calcium be taken in the form of natural mineral waters containing calcium.

The latter views of Röse coincide with those of Pickerill[2] who demonstrated that the enamels of soft and more poorly formed teeth were

[1] Monatschrift f. Zahnheilkunde (abstract in Dental Cosmos, 1909, p. 135).
[2] Loc. cit.

porous and contained canals which ran from the surfaces of the enamel to the interior. Enamels of hard teeth he found to be compact and free from canals. Also, that the enamels of all teeth are porous at the time of their eruption, and that in time the enamel surface undergoes a process of condensation. In some mouths the enamel becomes hard, dense and sclerotic, the hard tooth, and in others the process is less complete, the tooth enamel is soft and is more or less porous. Pickerill states as his opinion, for which he has no definite proof, that the condensation of the enamel after eruption is produced by infiltration of calcium salts from the saliva, and that the degree of condensation is dependent upon the degree of calcium salt concentration in the saliva.

In former contributions[1] we have given the results of determinations made of the calcium in a large number of salivas. We found that the saliva of every individual contained a definite percentage of calcium which remained fairly constant in amount from day to day. Also, that in those mouths in which the teeth are well formed, sound, and free from dental caries, the calcium content of the saliva is uniformly high; while in those cases in which the teeth are soft and carious, the percentage of calcium in the saliva is low. So definite and invariable were the findings which we obtained at that time and which are constantly being corroborated by cases selected from the college clinic, that we present them as definite proofs of the view that the quality of the enamel and tendency of the teeth to caries are dependent upon the calcium salt content of the salivas which bathe them. Of all the other salivary constituents and factors which have been suggested as caries controllers, we have found none which bear so close and definite a relationship to clinical conditions.

We have further shown[2] that the tooth is not an impermeable substance, but that salts and fluids may readily pass from the exterior of the enamel through its substance to the dentin and pulp; and, conversely, from the pulp through the dentin and enamel according to the laws of osmotic pressure. This being true, the tooth can no longer be viewed as a stable, unchangeable substance, but rather as one that is capable of being built up and condensed by salts from the blood and saliva through osmotic interchange of these fluids through the tooth. It is obvious, therefore, that in accordance with the laws of osmotic pressure through permeable membranes, the degree of such condensation will be in direct relationship to the salt concentrations in the blood and the saliva.

In our attempt to make practical application of these theories for the prevention of dental caries, we were met with certain difficulties.

[1] Bunting and Rickert: Jour. Nat. Dent. Assn., 1912, p. 287; 1917, p. 81.
[2] The Tooth, a Permeable Membrane, Jour. Nat. Dent. Assn., 1918, p. 519.

Experimental medicine has for a long time sought means by which it might permanently increase the calcium salt content of the blood, but as yet no satisfactory method has been found. We, therefore, in our endeavor to raise the calcium salts of the saliva by forced calcium feeding and stomachic medication were confronted with the same difficulties. At some future time, when the process of calcium metabolism shall be more clearly understood and methods found by which it may be raised, we may be able to increase permanently the calcium salt content in salivas which are low in that constituent to the betterment of the teeth and the reduction of dental caries. At present we are limited to two methods of procedure in such cases, namely, the selection of diet to the full calcium requirements for metabolism, and the use of mouth washes containing calcium. These methods we have employed on selected cases for some time with seemingly beneficial results, but sufficient time has not yet elapsed to present proofs of their efficacy further than the reasonableness of their adoption.

Viewing thus briefly the various methods of caries control we may ask which of these methods are worthy of adoption to meet present-day needs and in what manner they may be applied by the general practitioner. It is evident that in dealing with caries susceptibility, two distinct classes of causative factors present themselves, either of which may act singly or in conjunction with the other: First, those general and constitutional disorders which favor the carious process. For example: cases of nutritional disturbance resulting in poor tooth formation and deficient calcium in the salivary secretions; cases of increased susceptibility as the result of general disease, bodily weakness, nervous disorders or pregnancy; and those cases in which caries has become acute following a change in habitat or climatic conditions. The second class of factors includes those which are local and oral, namely, the retention of food in certain localities of the mouth by irregularity of the teeth, overhanging fillings, etc.; a general excessive accumulation of carbohydrates in the mouths of children, millers, candy makers, and those having habitually unclean mouths; and finally, the presence in the mouth of virulent acid-forming organisms. It will be seen that these two classes of causative factors may occur in an almost endless number of combinations, making the analysis of every case an extremely complicated matter. Also, that in those cases in which the first, or constitutional group of factors predominates, we have at the present time little means of control. But in those cases in which the second, or local factors are the determining ones, definite and tangible methods are at hand by which we may reduce the virulence of attack or entirely prevent it. These methods are all those which make for continuous mouth cleanliness and oral hygiene.

The field of oral hygiene is a broad one. In its practical application the greatest benefits as regards caries control are to be obtained during the age of childhood. As the deciduous teeth, one by one are lost and are replaced by their permanent successors, the food has a tendency to become packed and retained about the teeth due to the irregularities of the dental arch, oral fermentations are high, and dental caries common. The enamels of newly erupted teeth, not having been condensed by contact with the saliva, are imperfect and at this time are least resistant to the inception of caries. Cavities, when once begun, grow rapidly and early involve the pulp, resulting in its death and many times in severe periapical infection. It is during this particularly susceptible period of childhood that effective measures of caries control are most necessary; for could we conserve the teeth of children and bring them to manhood and womanhood with perfect dentures, we would greatly enhance their chances for maintaining dental health throughout the remainder of their lives. To this end there are certain definite and obviously effective methods of procedure by which the teeth of children may be preserved. These methods are of assured value and quite apart from any theories or speculations regarding caries control. Although these measures are well known to the dental profession, it is regrettable that a great many practitioners fail to put them into effect because of the fact that they are reluctant to operate on children. They prefer to wait until their little patients are older, then to build bridges and to make large restorations to repair as best they can the damage that has been done. This is not a pleasant or comforting admission, but, unfortunately, it is true.

A rational method of oral hygiene for children might be outlined somewhat as follows: children should be seen regularly by the family dentist for the purpose of assisting and encouraging them to keep their mouths clean; cavities should be discovered early and filled in their incipiency; imperfect sulci on bicuspids and molars should be protected; orthodontic interference should be given whenever indicated to promote normal development of the dental arch; children should be encouraged to include in their diet hard foods and a limited amount of sweets combined with tart and acid fruits; special emphasis should be given to the foods which are high in calcium, as milk, butter-milk, and cheese, celery, spinach, turnips, radishes, string beans and kidney beans, cabbage, cauliflower, and chard, in order that calcium metabolism may be amply provided; and, finally, the frequent use of lime water as a mouth wash should be urged. A one-half of a saturated solution of lime water seems to be beneficial as it increases the intra-oral calcium content, softens the plaques about the teeth, and neutralizes acids which may be present.

This, or a similarly efficient regimen of mouth hygiene, for children is being carried out most completely by certain dentists who have limited their practice to the treatment of children. In this manner they are bringing their patients through the susceptible age of childhood to maturity with a complete and often perfect dental apparatus. The number of children so treated is comparatively small, but it is an ever-increasing one. The great majority, however, must be cared for by the general practitioner and the community dental clinic. For these the task is colossal and may be accomplished only by the hearty coöperation of every practitioner in the attempt to do his part in caring for the children under his supervision. Could this work be performed completely, there would result a generation of people who would require far less dental attention than the present one and for whom the problem of dental infection and its attendant systemic involvement would be largely solved.

Passing from the age of childhood to that of maturity, we find a somewhat different set of conditions presented in regard to caries control. Usually all the teeth have erupted and their enamels have become more or less condensed. They have become established in a certain fixed and permanent state of caries susceptibility, or immunity, as the case may be, dependent upon the balance of forces which exist in the oral environment. It is true that individual cases may change from time to time in their susceptibility to dental caries as the result of changes in general health or life conditions, but it is well known that the majority may be classified as belonging to certain definite types of virulence. For the relief of those cases which have a tendency toward dental caries, we are limited for the present to those measures which will most effectually eliminate or reduce the carbohydrates and fermentations which are essential to the carious process. Could we but keep the teeth continuously free from these, dental caries could not exist. But mouth cleanliness is at best but a relative matter for lactic-acid fermentations undoubtedly do exist in all mouths to a greater or less degree. Our only hope, therefore, in oral prophylaxis is to reduce these fermentations to the point where the other protective forces of the mouth will establish caries immunity. It must be admitted that the complete elimination of caries in every case by oral prophylaxis is impossible; for, in certain mouths the forces of caries susceptibility are very strong and the protective powers correspondingly weak. Fortunately, it is also true that a very large percentage of susceptible cases may be made practically immune and the severe types reduced in virulence by the rational application of prophylactic measures. After viewing the work of many operators who are practicing preventive dentistry most intensively, the author personally applied the principles

of prophylaxis to a group of patients to substantiate or disprove the claims which were made as to the efficacy of such measures. These patients had been under personal observation for some time and many of them had been strongly susceptible to dental caries for years. In several cases so treated, dental caries has not occurred during the past four years, although previous to that time cavities appeared with frequent regularity. Others showed a marked decrease, having but two or three cavities during that time. One particularly susceptible case was immune for three years and then suddenly became susceptible coincident with a protracted illness and general debility. The results obtained from this limited number of cases have clearly demonstrated that a regimen of strict oral prophylaxis does limit, and in many cases, controls the occurrence of dental caries.

THE PREVENTION OF PYORRHEA ALVEOLARIS.

In a succeeding chapter which will be devoted to that subject, the history of our present knowledge of the disease commonly known as pyorrhea alveolaris and the various causative factors which are connected with the process will be set forth in detail. By a careful perusal of the matter there presented it will be seen that the author, after having reviewed all the important theories and speculations thereto, concludes that pyorrhea is a distinctly infectious process acting in conjunction with a lowering of local tissue resistance. That is, the process consists in a progressive destruction of the tissues about the teeth by infectious organisms resulting in the formation of characteristic pyorrhetic pockets. But these infectious organisms do not produce their characteristic results upon the tissues unless the natural resistance of these tissues against infections has been destroyed by some form of injury or disturbance of circulation and metabolism. It follows, that although the disease is essentially an active infective process the determining factor in every case consists in one or more predisposing causes which lower the resistance of the local tissues and make the infective invasion possible. Further, it may logically be inferred that if the peridental tissues could be protected from injury and kept in health and normal resistance, pyorrhea would most effectually be prevented. At the present time of all the methods which have been suggested for the prevention of peridental diseases those measures which have been directed toward the maintenance of health and normal resistance in the gums and gingival tissues have yielded the most beneficial results.

It has been pointed out previously that the mucous membrane of the oral cavity normally possesses a high degree of resistance

against infections. But, when the gingival tissues are disturbed either by local irritations or by systemic fault of metabolism, gingivitis is set up, the gingival tissues lose their normal tone and fall away from the necks of the teeth. In this manner the gingival crevice is opened and an opportunity is offered for the entrance and growth of oral microorganisms, which process constitutes the first step in the great majority of cases of incipient pyorrhea. In general, the local causes of gingivitis consist of various traumatic injuries, as the impaction of food, encroachment of calculus, overhanging fillings, crowns and bridges, and excessive stresses upon the teeth due to malocclusions; chemical injuries as persistent localized growths of bacteria about the necks of the teeth which continually irritate the gingival tissues; and certain other special local irritants. The general or constitutional causes of gingivitis consist of circulatory poisons such as lead, mercury, etc., or of general disturbances of circulation and nutrition by which the metabolism of the local tissues is altered. Of these two types of injury the local causes are in the majority. Indeed, it may be seen in clinical practice that when all local irritations are removed and the circulation of the peridental tissues is stimulated by proper massage, the gingival tissues, as a rule, may be restored to health and maintained in that state even in the presence of evident general and systemic disturbances.

The practice of preventive dentistry as regards the control of peridental disease, therefore should consist of the thorough prophylactic removal of all local irritants and other injurious influences from the teeth and the peridental tissues. This should be accompanied by the correction, so far as possible, of all systemic faults and the stimulation of the circulation in the peridental tissues. By a rational application of these measures it will be discovered that gingivitis is the most easily and certainly preventable of all dental diseases. And it also follows that in preventing gingival disturbance and by maintaining the health and normal resistive powers of these tissues, the great majority, if not all of the more serious peridental diseases are effectually prevented.

In all of the foregoing it will be seen that as we survey the whole field of preventive dentistry, and the methods of procedure which thus far have been suggested for the control of the two most important diseases, namely, dental caries and pyorrhea alveolaris, oral prophylaxis in its broadest application offers the greatest hope of success. Not that these measures are presented as an infallible panacea for dental ills, but that the faithful performance of those local procedures which make for oral and dental health constitutes the most reasonable and practical method of at least partial prevention with which we at this time may combat dental disease. The efficacy of this form of practice has been demonstrated clearly by a large group of operators who have

intensively applied the principles of oral prophylaxis to a large number of patients with the result that for them dental and oral diseases have been largely eliminated. These same procedures as outlined in the following section may well be adopted in a modified form by every dental practitioner.

ORAL PROPHYLAXIS.

The term prophylaxis has been widely applied in dentistry to the operation of cleaning the teeth; so much so that in the minds of many it has come to be synonymous with that procedure. In its broadest sense, however, oral prophylaxis consists of not only cleaning the teeth, but also includes all measures which tend to protect the mouth tissues from disease, and make for dental and oral health. Oral prophylaxis therefore embraces all methods by which the various harmful influences may be removed from the dental and peridental tissues, and the tissues left in such condition that a continual maintenance of oral cleanliness and oral health is possible.

In general, the practice of oral prophylaxis in a broad sense consists of the following procedures:

1. Removal of all calcareous deposits, stains and other extraneous substances from the teeth.
2. Smoothing and polishing of all exposed tooth surfaces and rough fillings.
3. Detection and filling of all cavities.
4. Restoration of faulty proximate contacts and tooth contours.
5. Removal of overhanging portions of fillings, crowns, bridges, etc.
6. Relief of undue stresses on the teeth.
7. Protection or filling of defective sulci.
8. Instruction of the patient as to daily personal care.
9. Sustained periodic supervision and assistance.

It will be seen that all of the above procedures are directed toward the removal of irritating and harmful influences from the teeth and surrounding tissues and the establishment of oral conditions in which the mouth will be practically self-cleansing, or capable of being cleansed by the personal efforts of the patient. The question has often been raised as to the need of such prophylactic measures and the possibility that in their performance actual harm may be done. Objection has been made to polishing the tooth surfaces on the ground that the enamel would thereby be thinned and weakened and that this operation could not be accomplished without doing irreparable damage to the peridental tissues. It is undoubtedly true that as the result of many overzealous and radical exponents of this form of practice, an excessive amount of enamel substance has been removed

from the teeth and extensive injury to the peridental tissues produced. But these distressing and unwarranted procedures which have been done in the name of oral prophylaxis cannot be construed as a real objection to that process when safely and sanely performed. Upon careful examination it will be seen that in a large percentage of mouths the teeth are more or less incrusted with salivary calculi which act as irritants to the peridental tissues and by virtue of the rough surfaces which they present tend to mechanically hold food in contact with the teeth and gums. On those tooth surfaces which are not so incrusted it will be seen that the enamel is frequently dull and rough, lacking the natural luster which it normally should possess. Tooth surfaces of both classes offer considerable retention for food and bacterial plaques; and cannot be cleansed by natural forces or the personal efforts of the patient. The great prevalence of the roughened enamel surfaces to be found in the mouths of the great majority of people is evidently due in part to the soft and pappy diets which are almost universally adopted today by the civilized world. In the primitive and uncivilized races we find teeth with highly polished enamel surfaces and a marked freedom from dental disease. Among these people the diet contains more gritty and hard foods which in the act of mastication produce considerable mechanical cleansing and polishing of the enamel surfaces. Moreover, many races that are noted for the brilliance and lustre of their teeth are known to spend considerable time each day rubbing the surfaces of their teeth with various roots and herbs which cleanse and polish them. It follows therefore that those who live upon foods that tend to stick to the teeth rather than scour and cleanse them, must substitute some artificial mechanical measures for the natural action of the food if they would have clean and healthy mouths.

As a rule, the indifferent and irregular habits of personal dental care on the part of the patient are not sufficient to compensate for the lack of friction which the hard and gritty foods would give. Consequently, in the great majority of mouths concretions form on those portions of the teeth which receive the least friction and the enamel surfaces which are continuously covered by bacterial films and plaques become etched and roughened by acids which are formed on the spot. For these it is evident that the first step in oral prophylaxis should be the removal of concretions and the subsequent polishing of all tooth surfaces to the end that the patient may cleanse the teeth properly by his personal efforts. It is true that in some mouths the teeth are naturally polished and clean. In such cases it will be found that the salivary secretions are thin and low in mucin, while the teeth are frequently abraded giving evidence of heavy and thorough mastication. From this we see that in them the tendency for lodgement of food and calculi

upon the teeth is slight and the natural friction of mastication is marked. As a result, the mouth is naturally self-cleansing and as a rule free from disease. This type is, however, in the great minority while the roughened and incrusted denture is much more common.

It follows, therefore, that the great majority of our patients need assistance in the care of their mouths. They need careful and thorough operative procedures to remove all forms of irritation from the dental and peridental tissues, and to eliminate all mechanical hindrances to oral cleanliness. Unless this be done, oral cleanliness is impossible in the mouth of the average patient.

1. **Removal of Concretions from the Teeth.**—Calcareous deposits on the exposed surfaces of the teeth form masses which are more or less evident and may be recognized easily (Fig. 88). For their removal

FIG. 88.—Salivary calculi.

a large variety of instruments have been suggested, scalers, cleaners, files, planes, chisels, etc., among which considerable latitude for the personal preference of the operator may be exercised. The chief requisite of each is that by their use the deposits may be effectually and completely removed and that the enamel surface will not be scratched or injured in the operation. Calculi which are formed on the roots of the teeth beneath the free margin of the gum are much more difficult to remove. As a rule, they are entirely covered by the gum tissues, are hidden from view, and may be detected only by an instrumental exploration of the subgingival crevice. Certain forms are fine and granular while others consist of thin and plate-like scales firmly adherent to the surfaces of the root (Fig. 89) both of which may be overlooked and are difficult of removal when discovered.

In the removal of dental calculi, especially the subgingival varieties, too much stress cannot be placed upon the means of discovering and locating these deposits. Since they are frequently hidden from view, the mouth mirror as a means of diagnosis cannot be relied upon. Therefore, the operator must cultivate a keen sense of touch by which he may read the character of the enamel and cementum surfaces by passing the point of an explorer or other instrument over them. In this manner he may judge as to the roughness or smoothness of these surfaces and may detect all deposits and concretions which may be attached to them. To this end it is desirable that the operator cultivate the habit of grasping and using the instrument after the manner

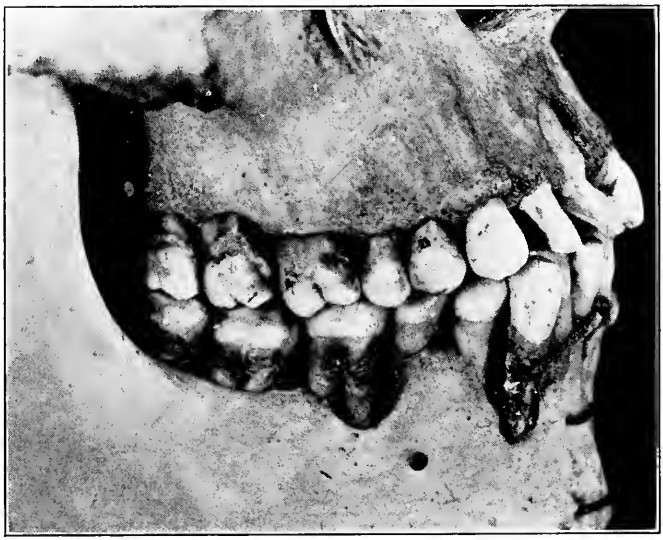

FIG. 89.—Subginival calculi.

of holding the pen in the old Spencerian style of writing (Figs 90 and 91).

If the instrument be held lightly with the muscles of the hand at ease and uncramped, the vibrations which are set up as the point is passed over various rough and smooth surfaces will be transmitted to the hand and will accurately portray the character of these surfaces. For instance, one may try the experiment of passing an instrument held in this manner over the surfaces of etched and smooth glass and may easily distinguish one from the other by the feel or vibrations of the instrument. If, on the contrary, the instrument be held tightly and considerable force continually exerted upon it, the muscles of the hand soon become cramped and the keen sense of touch is lost.

It is equally important that in all forms of prophylactic instrumentation the same Spencerian type of hand grasp should be maintained and



FIG. 90.—Method of holding instrument.

the fingers should remain as nearly passive as is possible. If they are continually flexed and extended for the purpose of moving the instru-



FIG. 91.—Method of holding instrument.

ment over the surface of the tooth, the sense of relationship is lost, and as a result of continued muscular effort the fingers become cramped

and the tactile sense is dulled. Rather should the instrument be actuated by a rocking motion of the whole hand describing the arc of a circle about the tip of the second or third finger which rests upon some fixed point in the mouth as shown in Fig. 91. This is accomplished by flexion of the wrist or elbow by which the instrument may be made to traverse the surface of the tooth in any desired direction without any effort of the fingers other than to lightly hold the instrument in position. If this method be adopted the operator may feel the surfaces of the tooth above and below the gum margins searching for extraneous deposits and when he has found them he may, by the momentary exertion of pressure, pry off the foreign body and continue to smooth the tooth surfaces until by the sense of touch through the instrument he knows that the deposit is entirely removed. In this manner he may operate for hours still maintaining his keen sense of touch and the free use of his hand.

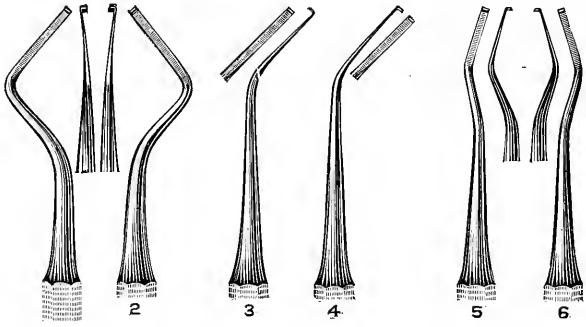

FIG. 92.—Tompkins' scalers.

In the selection of instruments adapted to the practice of oral prophylaxis the average practitioner may be easily confused by the wide range of types which are offered by the dental supply houses and private individuals. Leaving out of account the many clumsy and crude forms which have no place in preventive dentistry, there are in common use today four basic types of prophylactic instruments, namely, Tompkins' scalers and Younger's scalers, files, and planes.

The Tompkins' scalers (Fig. 92) consist of variously shaped instruments, having a right angle turn at their extreme end. They are intended to be used with a pull motion by which they may be hooked over a calcareous deposit and remove it. This type of instrument has been widely accepted and has been adopted in a modified form in the Buckley, Logan and Adair sets. The chief objections to them are that they are not adapted to smoothing the enamel or cementum after the removal of the calculi, and in the hands of the inexperienced operator

considerable damage may be done to the tooth surfaces by the sharp corners of the blade.

The Younger type of scalers (Fig. 93) is made in the form of slender elongated spoons, the shanks of which are bent at various angles to reach the several surfaces of the teeth. These are also intended to be used with a pull motion, the instrument being so tipped that the

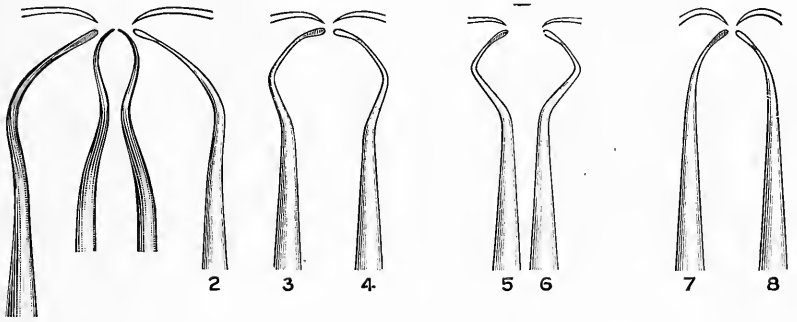

FIG. 93.—Younger's scalers.

lateral edge of the blade is presented to the surfaces of the tooth at an acute angle. In this manner the blade may be slipped down beneath the gum margin at a right angle to the long axis of the tooth and by a drawing motion the surfaces of the tooth may be cleansed and smoothed without injury to the soft tissues (Fig. 94). This type of instrument has

FIG. 94.—Younger's scaler, enlarged.

a wide range of usefulness and probably is the safest and most efficient type in the hands of inexperienced operators.

Files of various shapes, sizes and fineness of cut have been extensively used in prophylaxis. D. D. Smith made use of a selection of fine and coarse files (Fig. 95), the shanks of which were bent at various angles. A somewhat different set of coarse files has been suggested by Towner

(Fig. 96), which are very effective in removing calculi and smoothing roughened enamel and cementum. When sharp, the file is rapid in its action and covers a greater surface with each stroke than other forms of instruments. In many respects it is the most universal in its application and the easiest to master. The chief objection to this form of instrument is that its broad surface does not give the delicate sense of touch that is obtained by a smaller blade and as a result the operator

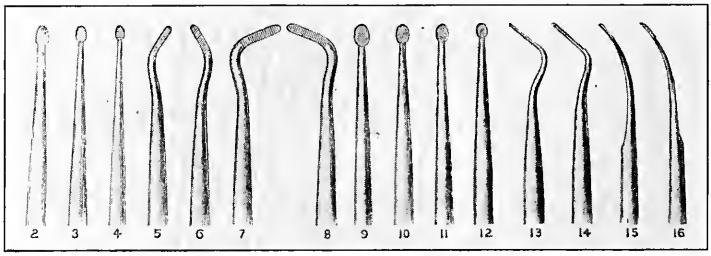

FIG. 95.—D. D. Smith's files.

may easily be deceived regarding the character of the tooth surfaces, either leaving upon them thin plates of calculi or cutting too deeply into the enamel or cementum.

The planing form of instrument (Fig. 98), as designed by Carr, James and Hartzell, constitutes a special and distinct type. These sets are composed of 150 different instruments nearly all of which have a right angle turn at their extreme tip. The blade is much heavier than

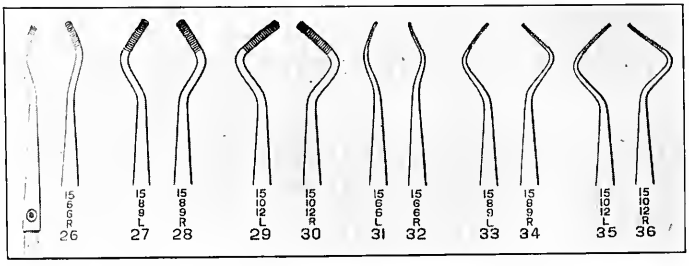

FIG. 96.—Towner's files.

that of the Tompkins type and is so made that it has a relatively broad and flat surface on the extreme end of the right angle tip which is intended to ride upon the surface of the tooth when in use. The shanks are so shaped that when the flat end is laid upon the tooth and the shank rests upon some other surface of the tooth, the inner edge of the blade acts after the manner of a draw plane or scraper when pulled over the surface of the tooth (Fig. 98). When used in this

manner these instruments will remove all foreign and extraneous substances from the enamel and cementum and by continued application will shave or plane down these surfaces until they are smooth. The large number of instruments in the set are arranged in groups of

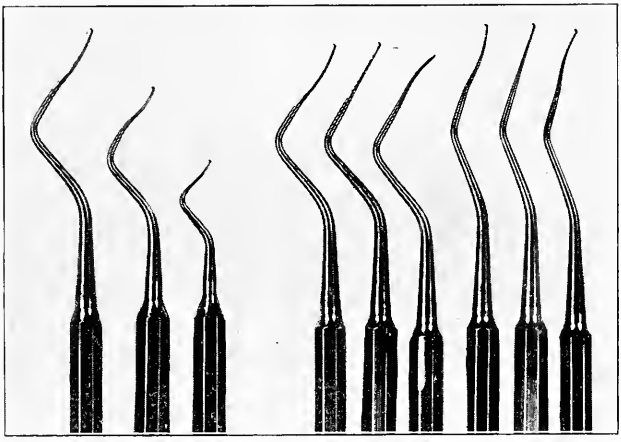

FIG. 97.—Planing instruments.

eight which are so shaped that they readily adapt themselves to eight positions on the tooth. The various sets of eight instruments are then grouped according to curvature of shanks, straight, convex and concave; according to size, small, medium and large; and according to angle of inclination of shank to handle, namely narrow and wide angle. The principle upon which these planes are built and their wide adapta-

FIG. 98.—Plane in position in tooth, enlarged.

bility to reach all tooth and root surfaces make them in the hands of the skilled operator the most efficient of the available prophylactic instruments. On the other hand, it is true that the technic of using these complicated sets of planes is not easily or quickly mastered and may be

successfully accomplished by only those operators who give considerable attention to this method of practice. They therefore are not to be recommended to the general practitioner who gives but a small part of his time and attention to dental prophylaxis. Rather should he adopt some of the simpler forms of instruments, to begin with at least, and master their use to the best of his ability. With the Younger type of instrument combined with files and small delicate sickles valuable and gratifying results may be obtained.

As has been said, the selection of instruments is more or less a personal matter. It is not so important that one particular type be selected, as that some suitable set be adopted and mastered by the operator so that he may completely remove all extraneous deposits from the teeth. This may be successfully accomplished in a large percentage of cases by any of the above types of instruments.

Stains.—The great majority of stains on the teeth are extraneous to the enamel, being glued to the surface by mucoid films. It follows therefore that when all such films and deposits are removed from the teeth, the stains will also be eliminated. This may be accomplished by instrumentation alone or by the subsequent polishing of the tooth surfaces. Many of the nostrums which are recommended for the quick and ready removal of stains are dangerous and should be avoided. They are frequently highly acid in reaction and depend upon a superficial decalcification of the enamel surface to release the stain. These highly acid preparations, therefore, etch and destroy the natural enamel surface and frequently accomplish considerable damage as a result of their use.

For a discussion of the handling of stains which have penetrated the substance of the tooth or have diffused outward from the pulp, the reader is referred to Chapter XI.

Plaques and Films.—The various forms of mucinous and bacterial plaques which cover all neglected and unclean surfaces of the teeth are of as great importance as, if not greater than, the dental calculi. It is in these films that the salivary calculi and stains first become impregnated and are attached to the surface of the tooth. So also do they afford an excellent medium for the propagation of oral microorganisms, many of which when growing in this manner, exert a harmful influence upon the teeth and surrounding tissues. For instance, acid-producing bacteria beneath a plaque may produce sufficient acid to decalcify the enamel and form an initial lesion of caries. Other types of organisms when growing in a plaque contiguous to the gums at the neck of the tooth frequently exert a toxic and irritative effect upon these tissues, producing chronic gingivitis and a tendency toward pyorrhea. It is therefore highly essential that all plaques and films

be removed from the teeth by prophylactic measures and the patient taught to prevent their recurrence by daily personal care.

When these films are infiltrated with stains or calcareous deposits they may be recognized easily, but when they do not contain these products they are colorless and invisible to the eye. In many instances they may be detected by the particular injury which they produce or by the employment of a stain which will reveal their location and distribution. For this purpose a disclosing solution which has been suggested by Skinner is very valuable. The formula is as follows:

Iodin (crystals)	50 grains
Potassium iodid	15 "
Zinc iodid	15 "
Glycerin	4 drams
Aqua	4 "

If this stain be applied to the surfaces of the teeth and washed off with a stream of water, all films and plaques will be highly colored by the iodin and will stand out in bold relief to the clean portions of the teeth which will be clear. This, or some other, efficient disclosing solution should be used in the diagnosis of every case and in the beginning and the close of all prophylactic treatments. In this manner the plaques may be located to the end that in the subsequent polishing of the tooth special attention may be given to their removal.

2. **Smoothing and Polishing Tooth Surfaces and Fillings.**—When all deposits have been removed from the teeth, the surfaces of the enamel and cementum should be smoothed and polished. Much of this may be done with the same instrument with which the calculi are removed by simply continuing to plane the tooth surfaces after they are cleaned until they feel smooth and free from irregularities. Occasionally the enamel surfaces are so rough and corrugated that the ordinary scalers and files are not sufficient to smooth them. Especially is this true of the enamel in the region of the gingival line which is frequently pitted and roughened by the action of acids produced by cervical fermentations. These may be smoothed by planing instruments or by the judicious use of stones and discs. When the enamel has been made smooth in this manner, it should be polished with XXX Silex[1] or with combinations of these two substances followed by tin oxid. This may be done with orange wood sticks and porte polishers (Fig. 100), vigorously rubbing all accessible enamel surfaces until a high polish has been obtained. The interproximate surfaces are reached by thin tapes and the wide floss carrying the polishing powder, care being taken to prevent injury of the interproximate gum tissues. This process

[1] XXX Silex may be obtained from the Bridgeport Wood Finishing Company, Bridgeport, Conn.

may be expedited by substituting an engine polisher for the hand rubbing. For this purpose the common bell-shaped rubber cup should



FIG. 99.—Orange-wood stick and porte polishers.

never be used as it invariably injures the gingival tissues. There are however, two types of rubber cups, namely, the Young B. S. polisher

FIG. 100.—B. S. polishers.

(Fig. 101), and the Davis Polishing cup (Fig. 102), which are so shaped that they may be adapted to the labial and lingual surfaces of practically

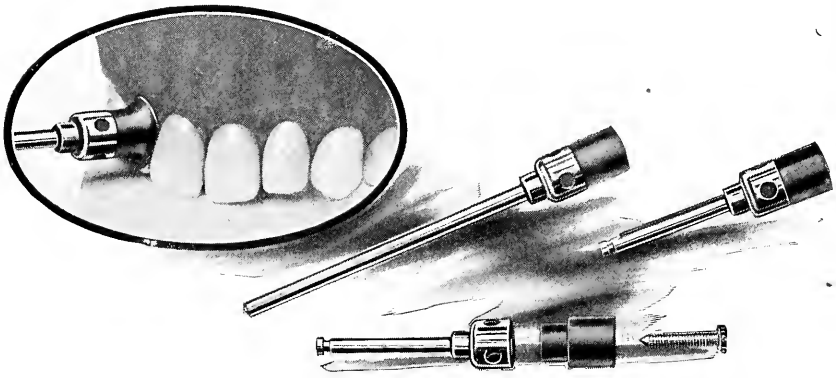

FIG. 101.—Davis polishing cup.

all teeth and if used with care will do no injury to the gingival tissues. By the use of this form of polisher together with soft felt wheels, a

smooth and highly lustrous polish may be given to the labial and lingual enamel surfaces in a comparatively short time.

In the process of polishing enamel surfaces it should be borne in mind that the enamel covering of the teeth is a highly important structure and should not be sacrificed ruthlessly. We have shown elsewhere[1] that the outer surface of well formed enamel is more dense and impervious to fluids than a cut enamel surface can be made by any form of polishing (Fig. 102). It is undesirable, therefore, to reduce the surfaces of those enamels which are naturally lustrous and polished. And those that are dull and rough should be smoothed and polished with the *least possible* loss of enamel surface. This may be accomplished

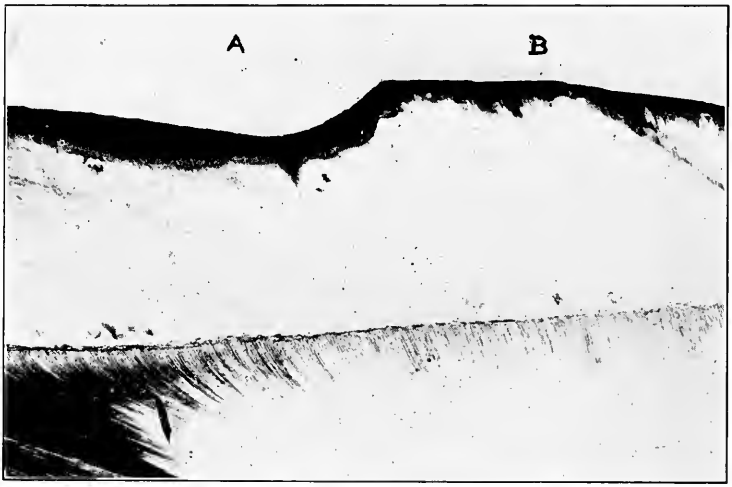

FIG. 102.—Section of tooth showing portion of enamel at (*A*) which had been ground and polished, the normal enamel surface being shown at (*B*). The tooth was immersed in silver nitrate after polishing and by a comparison of the depth to which the stain has penetrated the enamel it will be seen that the ground and polished portion (*A*) is more porous than the natural surface (*B*).

usually by the removal of a layer of enamel not greater than the thickness of writing paper. When the teeth are polished in this manner with due regard for the conservation of enamel substance, no harm will result to the dental tissues and an inestimable benefit to oral hygiene may be accomplished (Figs. 103 and 104).

Care should be exercised to prevent the injury of the peridental tissues in the process of tooth polishing. The heroic measures which are practiced by over-enthusiastic exponents of preventive dentistry, such as the ruthless cutting of the gingival and interproximate gum tissues and the vigorous sawing between the teeth in the act of polishing

[1] Bunting and Rickert: Jour. Nat. Dent. Assn., January, 1917, p. 90.

the enamel surfaces, are unwarranted and unnecessary. The teeth may be made sufficiently smooth to be self-cleansing and oral hygiene may be established by much more conservative measures than these without any attendant injury to the peridental tissues.

FIG. 103.—Upper cuspid before and after polishing for five minutes in the manner described in the text.

All fillings should be polished and made absolutely flush with the tooth surfaces. A rough cervical filling may often act as a nidus for the attachment of a bacterial plaque which may promptly reappear after a prophylactic treatment. When the filling is made perfectly smooth and polished, these surfaces may be kept clean and free from localized fermentation.

FIG. 104.—Upper molar before and after polishing for five minutes in the manner described in the text.

3. **Detection and Filling of All Cavities.**—At this stage of the process careful search should be made for carious lesions in the teeth and all necessary operative procedures should be performed. Indeed, the early detection and treatment of these defects should always be a matter of prime importance in preventive dentistry. It is the small cavity which is most successfully handled and, if taken early, the treatment is not complicated by pulp disturbances and devitalization.

4. **Restoration of Faulty Proximate Contacts and Contours.**—Faults in form and contour of teeth are very prolific causes of peridental irritation and disease. When proximate cavities are repaired by fillings which are not sufficiently contoured to afford a normal contact with the adjacent tooth, food is crowded between the teeth in mastication and as a result the interproximate gum tissue (Fig. 105),[1] is severely injured. Normally these tissues are protected by tight contacts which in mastication tend to deflect the food labially and lingually and all proximate fillings should be made to reproduce these normal interproximate relationships. The importance of this procedure cannot be too strongly emphasized since those who have studied these conditions have recognized that open and faulty contacts constitute the point

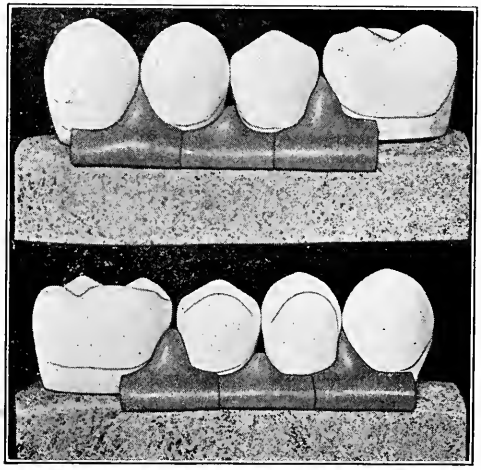

FIG. 105.—Models showing the injury to gum tissues arising from the lack of proper interproximate contact.

of inception of a very large percentage of peridental infection. Operative dentistry, therefore, to be consistent with the principles of oral hygiene, must be so constructed that all proximate contours will be restored and the normal relationships of the teeth to each other reëstablished.

It is equally important that the buccal and lingual contours be restored to the full normal curvature. A comparison of the normal contours of teeth will reveal the fact that certain types possess far more buccal and lingual contour than others (Fig. 106). It is also evident that when these contours are pronounced, the buccal and lingual gum tissues are protected from the injury from excursions of

[1] Friesell, H. E.: The Dental Items of Interest, 1918, p. 977.

food against them during mastication. But in case the contours are flat, considerable damage may be done to the gingival tissues by the impaction of food during mastication. Instance of this may be seen in Fig. 107 in which it will be noted that the gingival margin about the

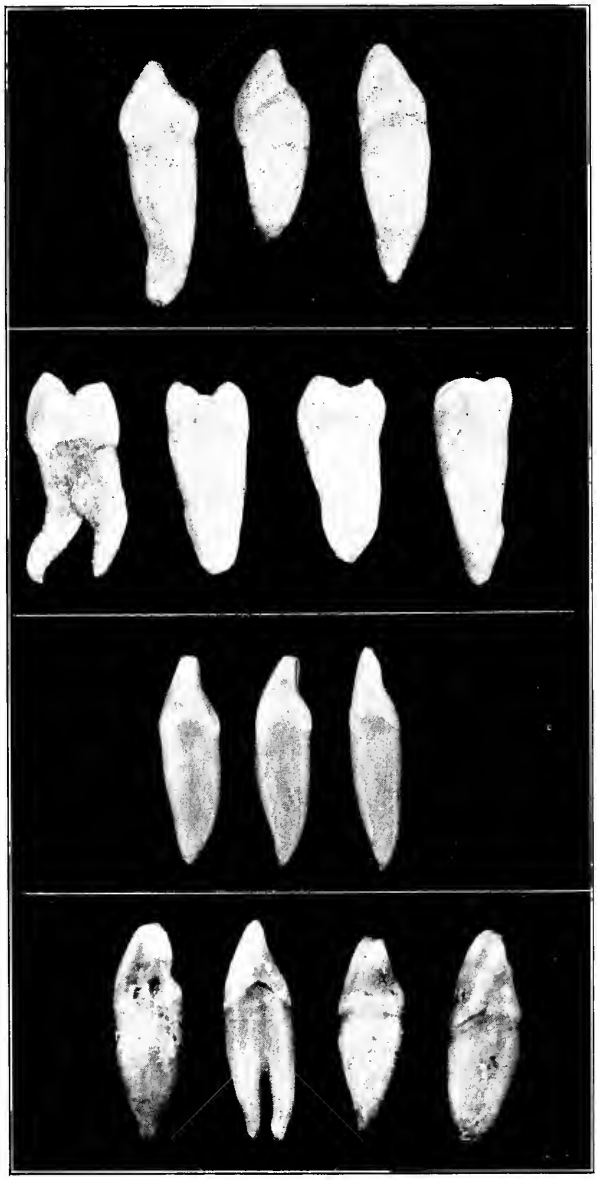

FIG. 106.—Types of teeth showing natural variance in buccal and labial contours.

lower central incisor has been torn and caused to recede, by virtue of the fact that the tooth in question was flat on its labial surface and did not protect the gingivæ. A correction of this natural fault may be made by the introduction of bulging cervical inlays which will afford

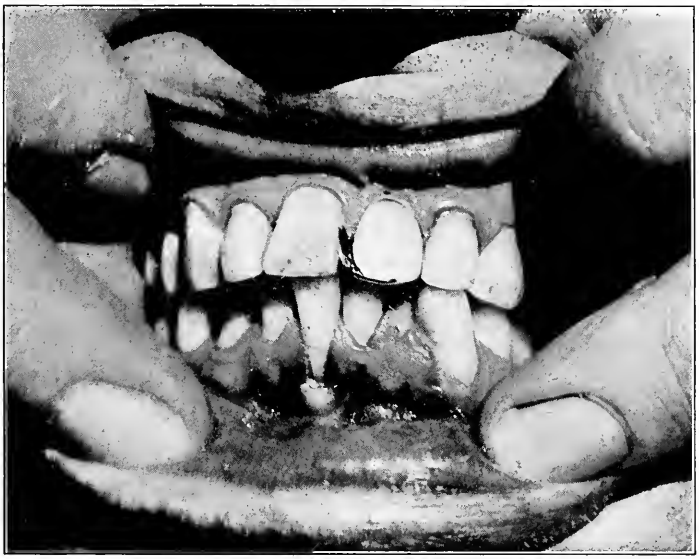

FIG. 107.—Retraction of labial gum tissues about lower central incisor resulting from excursions of food over flat labial surface of the incisor.

artificial food deflectors. Perhaps the worst offender in this respect is the straight sided type of crown about which the gingival tissues are constantly in a state of irritation. In contrast to these, we find that properly shaped and adapted crowns as in Fig. 109 protect the labial and lingual tissues and cause a minimum amount of irritation.

FIG. 108.

5. **Removal of All Overhanging Portions of Fillings, Crowns, Bridges, etc.**—Fillings which are not flush with the tooth surfaces, and crowns which are not closely adapted to the teeth at the cervical region offer considerable retention for food and infectious materials and constitute

potent predisposing factors in both caries and peridental disease. So frequent are these operative faults that scarcely a case is presented which does not have one or more of them. In the practice of preventive dentistry it is necessary, therefore, not only to conform all new restorations to these principles, but also to correct the faults of all operative procedures which have previously been made, even if it involves their removal and replacement. It frequently happens, however, that by the judicious use of files and chisels a faulty filling may be reshaped and made to conform very closely to the normal contours of the tooth. So, also, overhanging edges of porcelain crowns may often be reduced by small pointed stones and made flush with the end of the root. By these procedures such faulty restorations may cease to be a menace and may be retained for many years of service.

FIG. 109.—Traumatic occlusion, upper right cuspid being forced outward and distally by undue stresses arising from the loss of molar occlusion.

6. **Relief of Undue Stresses.**—It has been noted by operators who have studied peridental diseases that many cases of pyorrhea begin about teeth upon which there has been excessive and unusual stress. In such cases it will be seen that when the jaws are brought into occlusion, these teeth are moved laterally in their sockets by the gliding of the inclined planes of opposing teeth, one upon the other. This is noted frequently in the upper anterior teeth when because of the loss of a large proportion of the molars and bicuspids, the bite has closed and the lower incisors strike against the lingual surfaces of the upper incisors to produce a pronounced traumatic injury. As a result, the peridental attachments on the lingual surfaces of the roots of these teeth are broken down, the teeth become loosened and drift labially until they elevate the upper lip and in extreme cases assume a position practically perpendicular to their original inclination (Fig. 109). It is of the greatest importance that all such cases of excessive incisal

occlusion be discovered early before serious damage and protrusion of the teeth have been accomplished, as the correction of these faults and restoration of the teeth to their normal position are extremely difficult and as a rule impracticable. The treatment of such cases consists of either raising the bite by the insertion of mechanical appliances to restore missing posterior teeth or the shortening of the lower incisors by grinding until they no longer strike the opposing teeth.

Traumatic occlusion may produce injury in the peridental tissues about teeth other than the incisors. Fig. 111 is taken from a mouth which had slight indications of pyorrhea save that of a deep pocket on the mesial of the upper right first molar and the distal of the adjacent second bicuspid. It will be noted that the lower first molar had been

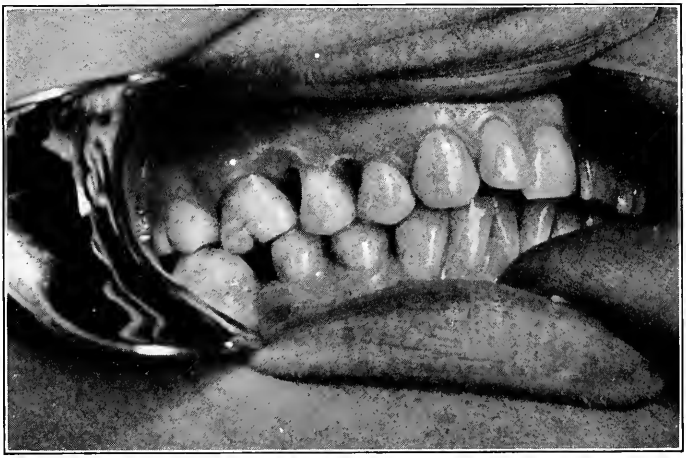

FIG. 110.—Deep pyorrhetic pockets on mesial of first molar and second bicuspid upper due to traumatic occlusion of lower second molar.

extracted some time previously and the lower second molar was striking the upper first molar at an unusual angle. The traumatism thus occasioned, associated with a general lowering of tissue resistance, of which there was evidence in this patient, resulted in a serious pyorrhetic involvement of the teeth under stress. Numerous examples of injury from occlusal stress are to be found in susceptible individuals when the cusps of the molars and bicuspids are high and closely interlock in occlusion. In them it is found that the teeth stand in such a position that as they are brought together in rest the cuspal planes do not immediately fit, but that two inclined surfaces first strike together and then slide into position producing a lateral shearing strain upon both teeth. Unless the resistance of the peridental tissues is exceedingly

high peridental injury and degeneration result which are very frequent causes of pyorrhetic affections.

In oral prophylaxis, therefore, the mouth should be examined for all undue stresses, especially when the cusps of the teeth are high and closely interlocked. And in all operative procedures which involve the reproduction of tooth form, such as fillings, crowns, bridges, etc., it is highly important that they be so shaped that no unnatural or unusual stresses be exerted by them upon the opposing teeth. Many teeth have been loosened by an over-full filling and many a bridge which was otherwise technically perfect has failed because of faults of occlusion, which have resulted in traumatic injury and loss of attachment of the peridental tissues about the abutments. So also, may prosthetic appliances produce injury to the peridental tissues by excessive pressure upon the soft tissues and lateral stress upon the teeth. It is only by a full appreciation of these factors and a close study of the stresses in each individual case that preventive dentistry may successfully be accomplished.

7. **Protection of Sulci.**—It is a matter of common observation that the sulci of many teeth are attacked by caries very early. Especially is this true in the case of those teeth which have high cusps and correspondingly deep and more or less patent sulci. In these occlusal crevices food and acid-producing bacteria are retained under very favorable conditions for the inception of dental caries. Prophylactic measures directed toward the protection of these extremely vulnerable areas in the tooth consist of the cleansing of the sulci with picks and explorers, dessication and flooding with copper cement, or other suitable substance. In this manner the defect in the tooth will be filled by a material that will exert a continued antiseptic and germicidal action in its immediate vicinity and will effectually protect the tissues against caries invasion for a considerable length of time. This form of treatment is especially beneficial in cases of children's teeth, if performed immediately after the eruption of the tooth before the carious process has set in.

8. **Instructions to the Patient.**—As we read the various opinions upon the subject we find that a wide range of procedures is suggested by dental practitioners to their patients as to the personal care of the mouth. All agree that the daily personal attention to the cleansing of the mouth and teeth is a matter of highest importance in preventive dentistry. The most that may be done by the operator is to so organize the mouth that dental cleanliness is made possible and then the future course of the case is determined largely by the manner in which the patient coöperates in maintaining oral cleanliness. Obviously patients should first be given definite instructions as to the method by which

they should cleanse their mouths, but as yet no uniform technic of personal care has been agreed upon. Differences of opinion have been expressed as to the armamentarium to be used, some preferring one style of brush and others another style, while a few have objected to the use of any kind of a brush on the ground that they believe them all to be harmful to the oral tissues and suggest in their place the use of cotton rolls and swabs. The majority, however, agree that some form of brush and flat floss should be employed although the manner of their use is not generally agreed upon. So also is there variance of opinion regarding the form of dentifrice that should be adopted, individual preference ranging through the whole gamut of powders, pastes, and dental lotions. The most comprehensive statement of the views of leading workers in preventive dentistry was obtained by the Editor of the *Items of Interest* and was published in the May issue of that journal for 1915. In answer to a letter relative to the instruction which should be given to patients, a variety of opinions and statements were received which were compiled into a symposium upon that subject. To this the reader is referred for a general view of what are perhaps the most sane and conservative lines of thought on this subject. It is not possible to discuss in this place all these various views, but rather a particular course of procedure will be outlined which is selected from various sources and which seems to the author to be well founded. These views are suggested, not as measures *par excellence,* nor as views possessing any special virtue, for it is true that each of the various operators is daily accomplishing excellent results in the mouths of patients by the use of the particular method of oral prophylaxis which he advocates, but rather are these measures stated as a simple workable basis which may be taught easily to the patient and which has yielded very beneficial results under the personal supervision of the author.

It must be recognized at the outset that the purpose of brushing the mouth and teeth is two-fold; first, the cleansing of the oral cavity of all food and bacterial plaques; second, the production of mechanical friction upon the peridental gum tissues which will stimulate the circulation and harden and toughen the epithelium to the point that it becomes highly resistant to mechanical injury. To accomplish these ends not only the teeth but the gums as well should be brushed vigorously with a hard stiff-bristled brush used in the proper manner.

Brushes.—During recent years the matter of obtaining suitable brushes has been a difficult one, due to the fact that the war has interfered with the importation of the best brushes and materials for making them. As a result, at the present time, there are on the market two forms which are acceptable, one the Rolling Brush (Fig. 112) and the other a brush designed by Dr. Card, of Philadelphia (Fig. 114). These

brushes are said to be made from the bristles of the Russian boar, and, as a rule, wear very well. They are made of three grades of bristles, soft, medium and hard, of which the hard is usually to be preferred.



FIG. 111.—The Rolling brushes.

In the selection of a brush, the largest size that can comfortably be adapted to the mouth of the patient should be chosen. The largest size of these two forms may be used in the average adult mouth, while the smaller forms are well suited to small mouths and those of children.



FIG. 112.—Dr. Card's brushes.

The method of using the brush should consist of two general types of motion. The first is a sweeping stroke beginning on the gums and continuing over the teeth in a direction parallel with the long axis of the teeth, down on the uppers, and up on the lowers. The brush is placed on the buccal surface of the upper jaws with the bristles pointing up and the side of the brush lying against the teeth. By a rotary motion of the hand the bristles are made to sweep down over the gums

and the teeth, in a vigorous manner, thereby stimulating the gingival circulation and cleansing the buccal and a portion of the proximate surfaces of the teeth (Fig. 113). On the lingual a similar motion is used while on the lower a reverse motion is employed, namely, a sweeping upstroke on the gums and the teeth.

To reach the cervical portion of the tooth and embrasures a special stroke is used. This is accomplished in case of the upper teeth, by placing the brush with its side against the upper jaw with the bristles

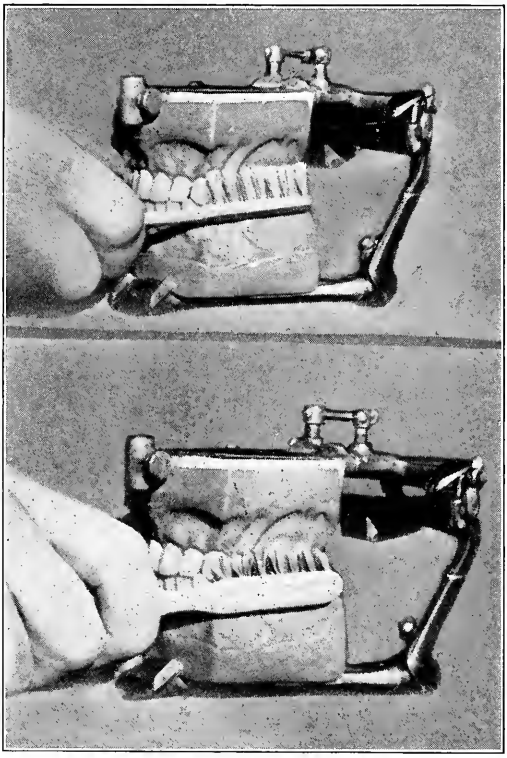

FIG. 113.—Two views of downward stroke.

pointing *down* in a position exactly the reverse of the first described method (Fig. 114). The brush is then carried *lightly* down over the teeth in a lengthwise, shaving stroke so that the inner row of bristles will be forced gently into the interproximate spaces and against the cervical portion of the buccal surfaces. By repeated motions of this order those portions of the teeth which receive the least friction by the first method are rubbed and cleansed. This may be accomplished by the use of the single row Rolling brush and by the larger multi-row

brushes used in the same manner, one row of bristles only being made operative. On the lower jaw the same motion is used in a reverse manner. For the lingual surfaces a peculiarly shaped brush has been

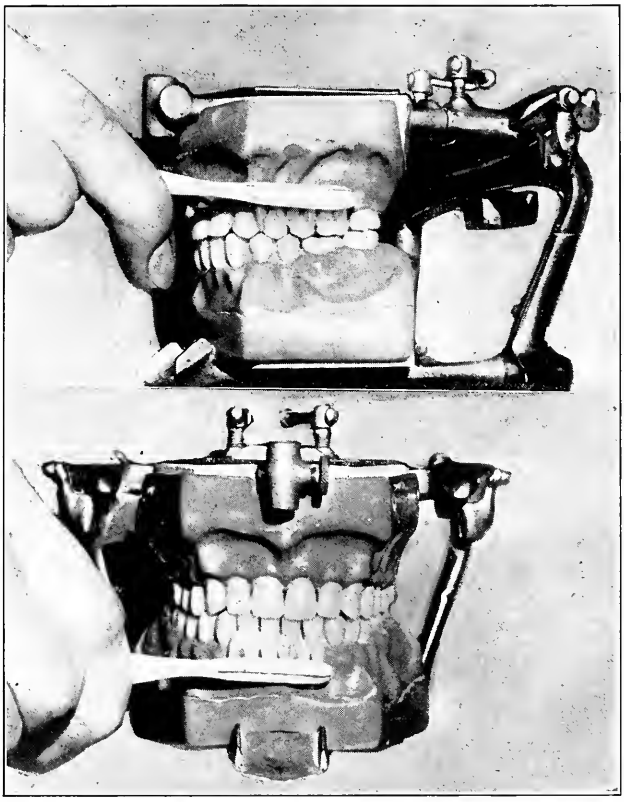

FIG. 114.—Two views of interdental stroke.



FIG. 115.—The single row Rolling brush (above) and the Barnes lingual brush (below).

suggested,[1] which may be made from any celluloid-handled brush. The head of the brush is cut off removing all but two rows of bristles together with that portion of the celluloid handle which holds them. The celluloid handle is then softened in boiling water and bent to the shape shown in Fig. 116. With this brush the patient may effectually cleanse a large portion of the lingual surfaces and the lingual embrasures, by a gentle shaving stroke.

Dental Floss.—It should be obvious that by no method of brushing may the entire mesial and distal surfaces of teeth in close contact be reached. For cleansing these surfaces of the teeth which are so frequently attacked by dental caries, it is necessary that the patient be taught to pass the flat floss into each interproximate space to wipe off the two proximate surfaces. For this purpose the flat dental floss is much to be preferred over the round cord as it covers more surface and is more effective as a cleanser of the teeth (Fig. 116). In this operation



FIG. 116.—Flat dental floss.

great care should be exercised to prevent the snapping of the cord against the interproximate gum septa for in this manner an over-zealous or careless patient may do serious harm to the soft tissues. The floss, therefore, should be held with the fingers of the two hands, exposing but a short segment of the cord and by a gentle sawing motion it should be carried beyond the point of contact (Fig. 117). Then the mesial and distal surfaces should be gently and carefully wiped to rid them of food and bacterial plaques, but in no case should the floss be sawed or manipulated in a rough or vigorous manner. If ordinary care is used in the instruction of the patient this procedure will do no harm to the gum tissues but, on the contrary, will serve as an active and effective means of combating interproximate caries and gingivitis.

Dentifrices.—The question of dentifrices is one about which there has been considerable discussion. At the present time, however, there is little accurate information on this subject. For the most part, the

[1] Dr. Henry Barnes, Cleveland

dental profession has depended upon, and recommended, the various dental preparations which have been placed on the market and widely advertised without any definite knowledge of the ingredients of which

FIG. 117.—Carrying dental floss between the teeth.

FIG. 118.—Passing floss over mesial surface of bicuspid.

they are composed or the action which they exert when used. In a former communication[1] we published microphotographs showing the shape and character of the grits contained in a number of the popular dentifrices. At that time we called attention to the fact that certain

[1] Bunting and Rickert: Jour. Nat. Dent. Assn., August, 1915, p. 247.

of these preparations are highly abrasive and rapidly cut the enamel especially when a crosswise stroke of the brush is used. On the other hand, many contained almost no abrasive materials and were exceedingly bland in their action.

It is the opinion of the author that no one dentifrice should be invariably adopted. Rather should a type of preparation be selected which is best adapted to each individual case. In the preparation of a mouth for preventive dentistry, a strongly abrasive dentifrice may be prescribed which will assist materially in smoothing the tooth surfaces and in ridding the mouth of fermentation. When the mouth is under control, it will be found that oral cleanliness may be accomplished by less harsh measures. Then the patient may be given a smoother preparation by which he can maintain the tooth surfaces in a highly polished and clean state. Occasionally cases are presented in which the viscosity of the oral fluids tends to make the cleansing of the mouth so difficult that the bland dentifrices are inadequate. For them a coarser preparation should be prescribed to be used either alone or alternately with the finer form. In all such cases special supervision should be given to see that damage to the tooth and peridental tissues does not occur as a result of the abrasive action of the dentifrice.

As to the various dental lotions and mouth washes which are on the market, it is the opinion of the author that none of them possess very essential therapeutic action and all of them are of doubtful value. Occasionally, when considerable hypertrophy of the soft tissue has taken place, the zinc chlorid preparations, as Astringosol and Lavoris, may be used for a short time to assist in reducing the inflammation, but as soon as this has been accomplished they should be discontinued. It must be remembered also that these preparations are impotent when used alone and act only as simple adjuvants to the necessary operative and surgical measures by which the local irritants must be removed before the swelling and inflammation may be reduced. If a dental lotion is desired, a 5 per cent. salt solution or a one-half saturation of lime water may be used to good advantage. The salt solution seems to act as a tonic to the gum tissues as well as a detergent to cleanse the teeth. The lime water, although not so palatable, is useful in that it softens the mucinous plaques and by its alkalinity tends to neutralize any acids which may be present.

9. **Sustaining Supervision.**—When a mouth has been reorganized as has been outlined and the patient has learned how to care for it properly, a complete change in the oral picture will be noted. Instead of the fermentations and general uncleanliness which previously had existed, the teeth appear clean and polished and the gums are hard and firmly resistant. If the patient continues to perform the duty of daily cleansing, the mouth will remain in this improved state of oral hygiene. But,

as a rule, even the most careful coöperation on the part of the patient is not sufficient to reach all the surfaces of the teeth and gums and in time there will be fresh collections of food, bacterial plaques and other concretions in those localities which have received the least care. For the permanent maintenance of oral hygiene and preventive dentistry, it is necessary that the patient be seen occasionally for the purpose of assisting him in the care of those most difficult places, to note and correct any beginning gingivitis and to discover any new cavities which may have appeared. To this end simple measures of prophylaxis are necessary which may be accomplished in from twenty to thirty minutes. They should consist of the exploration of the cervical areas and gingival crevices with a small Younger type instrument searching for and removing all accretions. The surfaces of the teeth may then be lightly gone over with the engine cup and one of the abrasive dental pastes followed by the use of the dental floss upon the proximate surfaces. This, with a direction of the attention of the patient to certain places in the mouth which need special care is all that usually is necessary. The frequency of these sustaining treatments should be determined by the nature of the case. Some will need to be seen once each month while others may safely be allowed to go two and three months without attention by the operator.

From the necessarily lengthy detailed description of this programme of preventive dentistry, the reader may be led to think that the performance of these measures is a long and tedious process. In cases which require considerable reorganization of fillings, crowns, bridges, etc., it is true that considerable time may be consumed in preparing the mouth so that it may be kept in a hygienic condition. But all the necessary cleansing and polishing of the teeth usually may be accomplished in a relatively short time by the method suggested, not more than two to four hours all told. To many, this may seem inadequate, but by actual experience covering a large number of cases the author has been convinced that very beneficial results may be obtained by the expenditure of time which is not beyond the reach of the average practitioner. Indeed, for a given number of cases in a busy practice the institution of these measures should result in an actual saving of time as mouths which are so reorganized will have far less dental and peridental disease to be treated as time goes on.

The working details of the procedures which we have just described or the benefits which are to be derived from them can never be fully appreciated by an operator until he has faithfully applied them to a variety of patients, has carefully worked out his own method of obtaining the result and has watched the resultant changes which occur in the mouths so treated. Then and only then will he fully understand the principles of preventive dentistry and oral hygiene.

CHAPTER IV.

INSTRUMENTATION, CAVITY PREPARATION AND THE FILLING OF TEETH WITH GOLD FOIL, GOLD INLAYS, AMALGAM, CEMENTS AND GUTTA-PERCHA.

By JOHN V. CONZETT, D.D.Sc.,

AND

ROSCOE H. VOLLAND, M.D., D.D.S.

Operative dentistry consists of all operations that are performed upon the natural teeth and the tissues directly connected with them, but the modern use of the term confines it to the operations that are performed upon the teeth themselves, to correct the damage done by caries, accident; and unusual wear of the surfaces of the teeth in mastication. Crowns, regulations, and all restorations of teeth that have been lost, are allotted to other departments of the profession. In this paper operative dentistry will mean all operations that are made upon the natural teeth that have for their purpose the restoration of lost tooth tissue by means of fillings or inlays. The terminology and presentation of the subject given to the profession by Dr. Black will be very largely followed.

Cavity preparation is fundamental to all operations on the teeth, and as the basic principles are the same for all materials and methods, first the science of cavity preparation and the principles governing the same will be taken up; then, the various materials with which to fill the cavity will be considered with such exceptions in the preparation as the physical characteristics of the material may demand.

Fundamentally, all cavities are the same no matter what may be the material with which they are to be filled or what method may be used to make the filling whether it be a filling of gold or one of the plastics or whether it be an inlay of metal or porcelain. The only deviation from the principles that will be laid down is that which may be made imperative by the method used in the filling. For instance, in the inlay, it will be impossible to use any retention that would make an undercut of any description, for to do so would prevent the making of a model or pattern that would fit the cavity; in the making of a porcelain inlay or a silicate filling, it will not be advisable to bevel the cavo-surface angle, for the lack of edge strength of those materials would

militate against the use of the bevel, as that would leave a thin edge of the filling material at the margin of the cavity that would soon break away and leave a vulnerable spot for the beginning of a recurrence of decay. In nearly every respect, the principles may be applied to all materials and methods, and in whatever case it is thought advisable to depart from the principles here laid down, it will be emphasized in the consideration of that particular method or material.

The first thing that the student should do in attempting to fill a cavity is to study the conditions that surround the making of such an operation. He should have a clear idea of the cause of the decay, whether it was due to a defect in the tooth, as in a pit or fissure cavity, whether it was a lack of cleanliness on the part of the patient, as in all smooth surface cavities, and particularly cavities occurring in the gingival surface of the teeth, or whether it was due to some mal-occlusion that prevented the proper cleansing of the portion of the tooth in which the initial penetration occurred. It is known that if it were possible to keep the teeth surgically clean they would not decay, and it is known that there are areas of susceptibility and areas of comparative immunity upon the surfaces of the teeth. It is also recognized that the areas that are most susceptible are those that are the hardest to keep clean by the natural use of the teeth in eating. Therefore, if it were possible to keep all of the surfaces of the teeth in the condition of the immune areas there would be no decay. In our study of the conditions surrounding the cavity in a tooth we should consider its position in relation to the area of susceptibility or of immunity; whether the patient is negligent in the care of his teeth or whether the cavity occurred, notwithstanding that the most careful attention had been given to them. The operator should carefully study the occlusion of the teeth, for he will not be able to lay out intelligently his retentive and resistance cavity forms unless he is familiar with the stress that will fall upon the filling that he is going to place in that particular cavity. All men do not exert the same degree of stress in mastication. One patient will bite with a force of from 250 to 300 pounds as measured by the gnathodynamometer, while another one will only exert a pressure of from 75 to 100 pounds. It would be inadvisable to cut as deeply for retention in the case of the man with the weak bite as in the case of the man with the strong one, and if, on the contrary, the same retention were made for the man with the strong bite that you would think sufficient for the weak one, you would invite failure by reason of a lack of enough resistance on the part of the filling. It will be seen, then, how necessary it is to study the conditions that caused the initial decay that we may try to so make the filling that there will be no recurrence of decay, and that the strength of mastication will not destroy the filling. If the

student will make it a habit to study carefully the conditions surrounding the teeth upon which he is to operate, and will then apply the principles of scientific cavity preparation to those conditions, he will have the pleasure of seeing his operations maintain themselves against all of the natural usages of the teeth for long years to come, but neglecting to do so will be disastrous and in the end will make him a failure in his chosen profession.

After a thorough examination of the teeth they should be well cleaned. If possible a thorough prophylactic treatment should be instituted before any operations are attempted, for the reason that most patients who present for the treatment of carious teeth have mouths that are ill cared for, and the attempt to place the rubber dam upon such teeth will drive many pathogenic organisms under the gingival margin, with a very probable gingival irritation, if not a serious infection. If by reason of an aching tooth such procedure is not possible, and it is found necessary to make immediate attempts at relief, the teeth to be treated should be cleaned as well as possible. The debris should be removed by forcing an antiseptic spray about the gingival margin, painting the gums with the tincture of iodin and then applying the rubber dam. But the dam should never be forced upon a tooth that is unclean for fear of infecting the gum tissue. During the cleansing of the teeth an examination pad should be at hand to mark all of the defects that will reveal themselves during the cleansing operation, and this tablet should then be filed away for reference as the work progresses.

An artist must have good instruments to accomplish good work and a dentist is no exception to that rule. The authors are not of those who believe in multiplying instruments; indeed, they believe that the least number of instruments that will perfectly accomplish the desired result is the ideal. In the multiplication of instruments beyond that necessary for the accomplishment of the desired operation is the multiplication of confusion. The student should thoroughly acquaint himself with every instrument in his cabinet and know just where, when and how best to use that instrument and make every instrument accomplish as much of the operation as possible. The reason that so many operators are slow and sloven in their work is that they are slaves to their instruments and can only accomplish a very little with any instrument, and when that little is done, must, perforce, find another slightly different in design, in order to finish the operation. The real artist will accomplish more with a piece of chalk and a shingle than will a bungler with the finest outfit possible; therefore, every student should be the master of a few instruments and add to that list those that experience demonstrates are necessary and then master those.

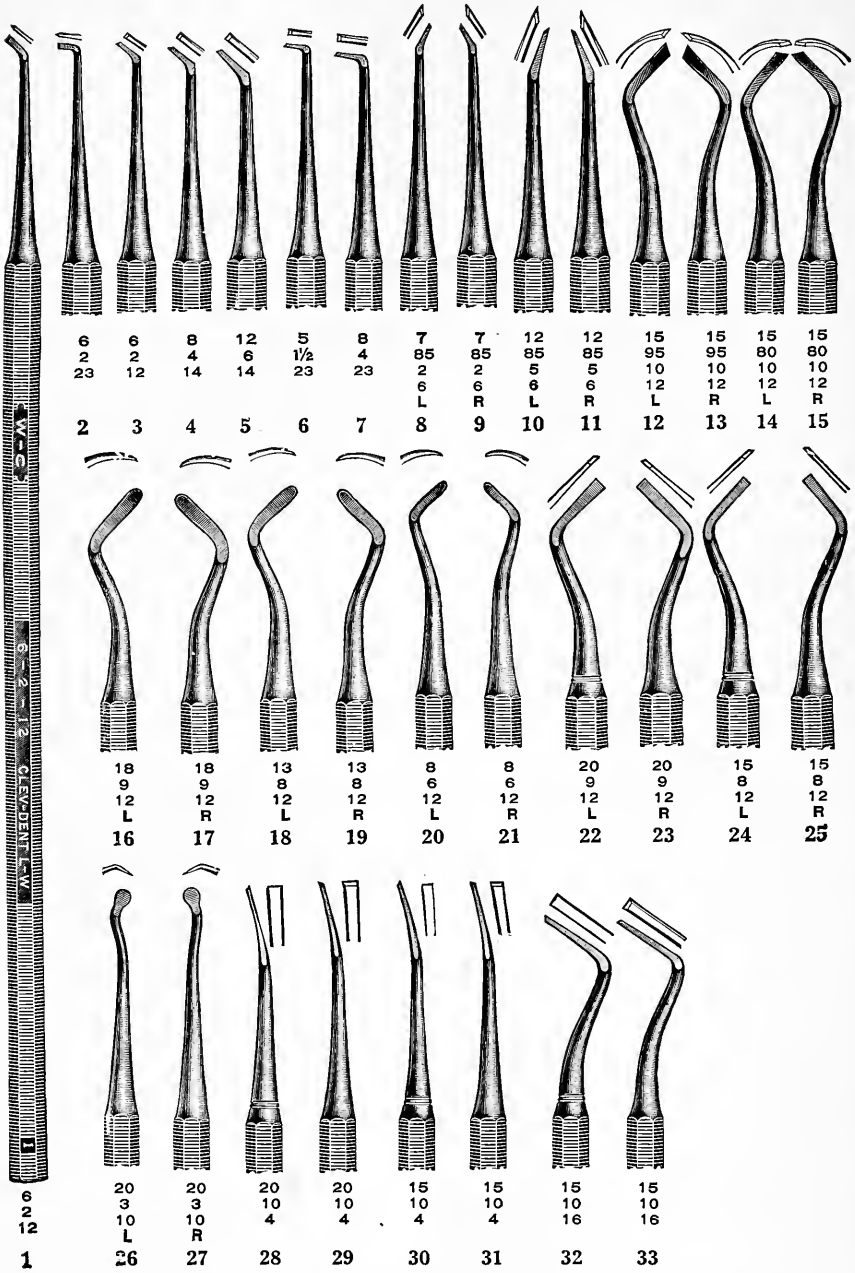

FIG. 119.—Woodbury-Crandall instruments for cavity preparation. Nos. 1 and 2 are hatchets for forming angles in the anterior teeth. Nos. 3, 4 and 5 are obtuse angle hoes. Nos. 6 and 7, right angle hoes, instruments of the widest application in cavity formation. Nos. 8, 9, 10 and 11, are right and left angle forming instruments, designed especially for carrying out the sharp line angles in cavities, particularly in the anterior teeth. Nos. 12,

A good mirror, several pairs of pliers, and five or six explorers must be at hand to begin any operation.

The set of cutting instruments that were designed and selected by Drs. Woodbury and Crandall are admirably adapted to the use of student and dentist as well. These cutting instruments have been selected with a view of obtaining the greatest service with the least number of instruments. We append the description given by the makers of the selection.

The engine instruments that will be necessary are round burs Nos. 2, 4 and 6, inverted cone burs Nos. $33\frac{1}{2}$, 35, 37 and 39, fissure burs Nos. 57, 58 and 59, and cross-cut fissure burs Nos. 701, 704 and 705. These should be for both the straight and contra-angle hand pieces. In addition to the burs, there should be a sandpaper disk mandrel for straight and right angle and a good assortment of carborundum and gem stones.

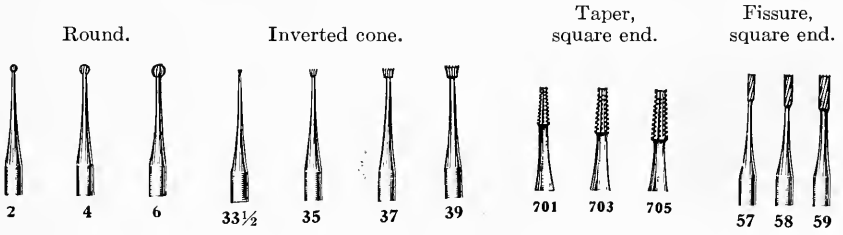

FIG. 120

Every student should know how to care for his instruments, for a good workman is known by the condition of his tools. Duplicate sets should be in the case of every operator as soon as he begins active practice, so that an instrument once used may be discarded and not placed in the operating case again until it has been sharpened and sterilized.

13, 14 and 15 are right and left, mesial and distal, gingival margin trimmers. Nos. 16, 17, 18, 19, 20, 21, 26 and 27 are right and left spoon excavators. Nos. 22 and 23, 24 and 25 are right and left enamel hatchets for breaking down enamel and shaping cavity walls in bicuspids and molars; one of each pair is marked with a ring to distinguish the direction of cut without examination of the cutting edge. Nos. 28 and 29, 30 and 31 are front and back cutting enamel chisels; one of each pair is marked with a ring so that those which cut on the back may be distinguished from those which cut on the face without examination of the cutting edge. Nos. 32 and 33 are special instruments for cutting mesially and distally in molar cavities that are difficult of access. Nos. 34 and 35 are finishing knives, designed for finding and removing overlaps along the gingival margin of fillings on the proximate surfaces. Nos. 1 to 11, 22 to 25, and 32 and 33 have five cutting edges. The sides of the blade, as well as the end, are sharpened. These additional surfaces are used for push and pull cutting in the final smoothing of axial walls. After the end of the instrument has been used in the preparation of the wall, the same instrument, with only a slight change of the hand to bring the side of the blade into position, is used to remove the slight irregularities left by the overlapping cuts of the end of the instrument. The enamel instruments, Nos. 22 to 25, and 28 to 31, have a special temper differing from that of the other instruments of the set. On account of their special hardness, they are not only better suited for removing enamel, but will hold their edge longer.

All burs should be thrown away as soon as they begin to lose their edge. Nothing is more discouraging to an operator or more painful to the patient than an attempt to operate with a dull bur. The best possible obtundent to sensitive dentin is sharp instruments and their proper use.

In sharpening the hand instruments, a large flat carborundum stone of the finest texture is the best that the authors have found. The stone should be five or six inches long and two or three inches in width.

The instrument to be sharpened should be held in the hand at the proper angle, with a pen grasp; guiding the hand with the last knuckle of the little finger, the instrument should be drawn the whole length of

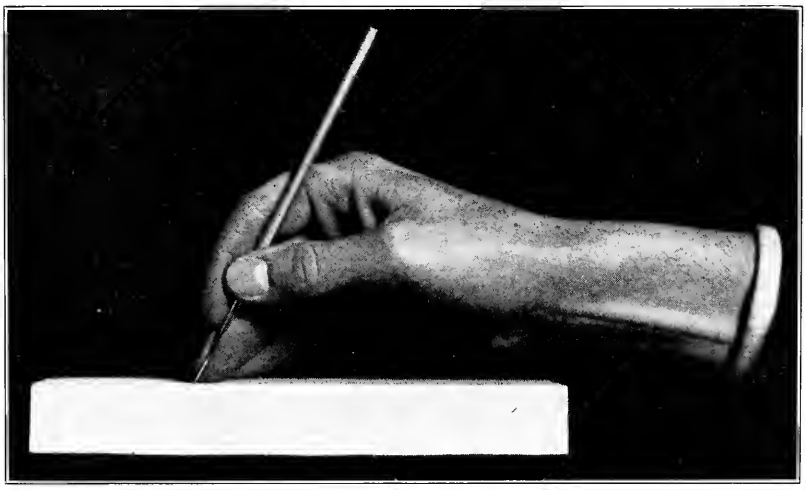

FIG. 121.—Showing proper method of sharpening instruments, using a large stone, the right method of holding the instrument, and the finger guide on the stone as the instrument is drawn across it.

the stone with a firm pressure. If the instrument is not too dull, one or two passes over the stone will sharpen it; but if it has completely lost its edge, the drawing over the stone will have to be repeated until a perfect plane is reproduced. Care should be exercised that every pass of the instrument is at the same angle or there will be a different facet upon the edge of the tool for every passage over the stone that the instrument has made. The edge on a dental instrument should be as good as that on a carpenter's plane, and fully as sharp, and the student should never rest content until he is able to reproduce such an edge upon his instruments and keep it there, for unless he does he will not be able to do good work.

All instruments should be scrupulously clean and should never be

used upon a patient until they have been carefully sterilized and sharpened.

In the preparation of the cavity and the making of a filling of any kind it is best to apply the rubber dam for the following reasons:

(*a*) It provides a dry field of operation.

(*b*) It holds lips, cheeks and tongue away so that a free view of the field of operation may be secured.

(*c*) The cuttings and debris produced in excavating the cavity are easily and quickly removed by a blast of warm air.

(*d*) The extreme limits of superficial decay can be made out only on a practically dry tooth surface. This decay will appear as a dull white chalky area on the enamel margin.

(*e*) The partial drying of the cavity reduces the sensitivity of the dentin to cutting instruments.

(*f*) Since the cavity is mechanically cleansed and cut into sound dentin in excavation the minimum of any infective material is left. Saliva is continually charged with microörganisms, and it is not desirable to permit it to enter a cavity after the excavation is complete.

The dam should be medium heavy; a light dam is very undesirable. A dark-colored, medium weight dam is preferred for the reason that the dark-colored one will better reveal the holes punched in it for the reception of the teeth. This is a great convenience, for if a light dam is used the holes in it are difficult to find and a great deal of time is wasted in attempting to do so.

The hole in the dam should be punched in a manner to correspond with the position of the necks of the teeth in the curve of the arch, so that the fit of the dam may be obtained without any wrinkles or stretching of the rubber. It is good policy to start always at the median line no matter how far back in the mouth the tooth that is to be operated upon may be, for the reason that the method of having many teeth through the dam assists in holding it away from the field of operation, makes the work of the operator easier and gives him better vision.

Before placing the dam, spray the mouth and teeth with an antiseptic solution to remove any debris from around and between the teeth. Then go between all of the teeth to be isolated with a piece of floss silk, to see that the dam will be able to pass between them. If any obstruction in the shape of food debris is there it will be dislodged, and any sharp cavity margins that would cut the dam will be revealed and can then be removed with a thin saw blade or sandpaper strip. If this is not done, difficulty will be experienced in getting the dam in place and the possibility of cutting the rubber is very great.

With the teeth prepared for the reception of the dam and the proper

number and arrangement of holes punched in it, it is ready to be placed in position. In order to facilitate its passage between the teeth, coat the holes with soap or vaselin. Some operators have a piece of hard soap whittled into an elongated cone, and just before placing the dam, moisten the soap and insert the cone into each hole in the rubber, thus coating the sides of the hole with a film of soap and lubricating the rubber so that it slides over the teeth more easily. Perfumed vaselin or oil may be used for the same purpose and will be as effective and more pleasant to the patient.

The dam should be grasped with both hands and the first hole in the rubber placed over the central incisor. When that is perfectly in place, pass on to the lateral and so on until all of the teeth to be isolated are in position; then place a properly selected rubber dam clamp over the tooth farthest back and the fastening of the rubber dam retainer will complete the operation. It is very convenient to have two dam holders, the first, the usual double grasp holder for use against the cheek, and the second, a single grasp one that will be placed on the dam below the usual double grasp holder and passing back of the neck be attached to the same position on the other side, thus firmly holding the dam down on the chin and preventing the lower portion of the dam from coming up, getting into the way and within the range of vision of the operator.

If the incisors are the teeth to be operated upon it will be advisable to include all of the incisors in the dam, and if the cavities are in the distal surface of the central or in the laterals or cuspids, it will be well to carry the dam as far as the bicuspids, using a clamp on the bicuspid to hold it in place. If the dam has been properly placed it will not be necessary to ligate the teeth, but the edges may be turned in under the gum by slipping a piece of floss silk between the teeth and insinuating it under the dam and turning the edges under, which will help to retain the dam in position. The teeth and dam should be thoroughly washed with alcohol and dried with a blast of warm air. This will remove any oily or muciferous material, will cause the dam to cling tightly to the teeth and will do much to prevent dislodgment. It may sometimes be necessary to ligate the teeth that are to be operated upon. In doing so it will be found very convenient to use the Wedelstaedt tie.

This is made by throwing a double loop of silk around the tooth and then uniting the ends with a surgeon's knot. This tie has the advantage that it will not slip as you make the knot, because the double thread will hold the silk firmly in place while the tie is being made. Instead of pushing the silk under the gum with an instrument, it will be found advantageous to place the ends of curved pliers between the silk loop and the gum and then place the ends of the pliers under the

gum, making traction on the ends of the silk, which will cause the loop to follow over the curved ends of the pliers and slide off them under the gum margin, where it will be held in place while the silk is drawn tight by making firm traction on the ends.

A number of rubber-dam clamps should always be on hand and one suitable to the case selected before attempting to place the rubber. If an assistant is at hand it will facilitate the placing of the dam to have her set her finger on the lingual surface of the last tooth to be included in the isolated field and hold the dam in place while you fit the clamp, or she may be trained to use the rubber-dam forceps and place the clamp on the tooth after you have adjusted the dam. If an assistant is not available the finger and thumb of the left hand may be used to hold the dam in position while the forceps are used in the right hand.



FIG. 122.—Surgeons' knot, also Wedelstaedt tie.

Another method of adjusting the dam in difficult posterior positions is to cut the holes in it as usual, select the proper clamp and then insert it into the last hole in the dam, grasp the clamp with the forceps and place it over the tooth indicated in the isolation scheme. The rubber will have to be somewhat rolled up and kept in the hand so that the tooth to be clamped will not be obscured. When the clamp is in place draw the rubber over it and over the tooth and then come forward and include the other teeth to be isolated in sequence until all have been included, when the retainers may be applied and the operation continued.

A well defined plan should always precede any operation and the student will find that if he will adopt and follow a system that is rational he will make more progress and become more efficient than he possibly could by the hit-and-miss fashion of operating. The system given to the profession by Dr. Black will be followed in this treatise:

First, obtain the required outline form.

Second, obtain the required resistance form.

Third, obtain the required retention form.
Fourth, obtain the required convenience form.
Fifth, remove any remaining carious dentin.
Sixth, finish the enamel wall.
Seventh, make the toilet of the cavity.

The outline form is the first portion of the operation to engage the attention of the student, and he should learn to visualize the finished filling before he makes the first move in the preparation of his cavity. If he will learn to do this and have a well-defined plan to carry out his vision he will soon become very adept in his operations; but if he has no plan in mind and simply cuts away until his cavity bears some semblance of a proper shape he will waste time and effort, and will, in the end, obtain a very inferior result. The outline form comprehends the doctrine of extension for prevention and the esthetic form.

Extension for prevention is the method of making the outline of the cavity in such a manner that all of the margins thereof will be in an area that is relatively immune to decay.

We stated in our preliminary remarks that there were areas of susceptibility and areas of relative immunity to decay. The areas that are susceptible are all of the defective portions of the teeth, as open pits and fissures, and those portions of the smooth surfaces that are not kept clean. Decay begins by the invasion of the dental tissues by microorganisms attaching themselves to a surface of the tooth that is not disturbed covering themselves with a gelatinous membrane technically called the bacterial plaque. Under the protection of this plaque they live upon the carbohydrates that are derived from the food debris left around the teeth, and from which they elaborate lactic acid, which attacks the cementing substance of the enamel. When the enamel rods are broken and fall out the organisms have direct access to the dentin, the destruction of the tooth is then rapid, and, if not stopped, complete. The susceptible areas are those that are not reached by the food in its excursions over the teeth in mastication or by the movement of the tongue and lips, or not kept clean by the patient in his toilet of the mouth. The proximate surface of a tooth, especially that portion lying immediately gingivally to the contact point, is the area of greatest susceptibility, and there will be found the large majority of the cavities occurring in the smooth surfaces of the teeth. As the point of greatest susceptibility is left and progress toward the buccal and lingual angles is made, a lessening degree of susceptibility is found until, when the angles are approached, we will find a territory that is practically immune. The same may be said of the march toward the occlusal and gingival margins until upon the occlusal surface there is immune territory. Decay is never found upon

the occlusal or incisal surfaces unless there is a defect in the enamel. Also, toward the gingival margin susceptible territory is in evidence until the cavity is carried under the free margin of the gum. On the buccal and labial surfaces we will find an area of susceptibility at the gingival margin and as far toward the occlusal surface as the curve of the tooth will make difficult the scouring action of the bolus as it passes over the tooth in chewing. The tooth with a large bell-shaped crown will have a larger area of susceptibility at the gingival margin than a tooth of more flat outline, occluso-gingivally, for in the case of the tooth with a bell-shaped outline the belling of the tooth will cause the bolus to miss the gingival portion, while if this surface were more flat the food would have a scouring action over the entire buccal surface. Also, in the bell-shaped tooth the curve of the bell will have a tendency to prevent the frictional action of the muscles of the cheek upon the gingival portion of the tooth, while in a tooth with a more nearly flat surface the cheeks would move upon the entire buccal surface, with a tendency to keep bacteria from making a lodgment upon them. As we have said, the occlusal surfaces of the teeth are naturally in immune territory, for the mastication of food would effectually prevent any organism from attaching itself to this surface; but, unfortunately, we will frequently find here defects in the closure of the enamel plates making pits and fissures into which the organisms of decay may penetrate and find themselves immune from the frictional action of mastication.

Finding that decay begins in certain territory and that it is rarely if ever found in other areas, it is evident that if a recurrence of decay is to be prevented around a filling that is made to correct the ravages of decay the conditions that were responsible for the initial penetration must be corrected. In order to do that the susceptible area will have to be restored with a material that will be immune to the action of the organism that caused decay and that material will have to be carried far enough out of the susceptible area to prevent a recurrence of decay. If this is not done it will make no difference how well the filling is made nor how perfectly it may be adapted to the walls of the cavity. There will be a recurrence of decay around it, not because the organism can penetrate between filling and tooth, but because the original fault was not wholly corrected. The organisms may find a hospitable territory immediately next to the filling upon the surface of the tooth, and a bacterial plaque being established in that position there will be a new decay started, which will in time undermine the filling, and the whole work will be destroyed.

In obtaining the outline form it will be seen then that it is necessary to carry all of the margins of the cavity into areas of relative immunity

to decay. The fact is that in large cavities the decay has practically solved the outline form for the operator, for the penetration of the carious process has been so great that the cutting necessary to lay the cavity in sound tissue will usually find the margins in the area of immunity. It means that the margins must be carried buccally and lingually far enough out of the embrasures so that the margins of the filling will not be in contact either with the proximating tooth or with a filling in the tooth, and will therefore be kept clean by the progress of the food over the tooth in mastication. In cavities in the incisors it will be necessary to carry the margin far enough lingually and labially so that the margins of the filling will be free of proximate contact. In all cavities in the proximate surfaces it will mean the carrying of the lines of the cavity margins below the free margin of the gum. In the case of cavities in the occlusal surfaces of the teeth it will mean that all of the pits and fissures will be cut out to their entire extent and that the margins of the cavity will lie in smooth, sound territory. In short, extension for prevention means the carrying of all margins of the cavity into territory that can be kept clean by the natural functions of the teeth, tongue and lips and under the free margin of the gum.

The esthetic form is that form which we give to the outline of the cavity that will, to the greatest extent, preserve the beauty of the tooth. A dentist should be an artist as well as an artisan, and it is his duty, and should be his pleasure, to make all of his operations as beautiful as possible. The highest art is to hide the art and make it appear natural, therefore in the making of a filling it is of the utmost importance to hide the restorative art as much as may be possible without the sacrifice of utility or the ultimate preservation of the tooth. When utility and esthetics come into direct antagonism, as they frequently do in the making of restorations with gold, the usefulness of the masticatory organ is paramount to the looks of the same and the tooth must be preserved in spite of the lack of perfect color harmony. In short, when the health and strength of the tooth demand the showing of gold, do not hesitate to show it. Whenever possible make all of the operations with as little show of the filling material as practicable. Make the outline form in such a way that the greatest mass of gold will be out of the line of vision and preserve all of the enamel possible, thus preventing the disfiguring display of gold. But lest it be misunderstood, let it be repeated, never under any circumstances hesitate to display the gold when the preservation of the tooth demands it.

All of the external lines of the cavity should be slightly curved. Nature abhors an angle, and a sharp angle on a filling is inharmonious and very objectionable; therefore always round all angles that come within the range of vision. Internal angles should be sharp in order

to make for a greater degree of retention, but outline angles should be rounded.

The natural outline of the tooth should always be restored to as perfect a degree as the skill of the operator will permit. A tooth may be restored with a filling that will be inharmonious in color, as with gold, but if the form and size are correctly reproduced it will be much more esthetic than if the color were to be perfectly restored while the size and shape were to be distorted. In order to properly reproduce the contour of a tooth it will frequently be necessary to separate the teeth in order to obtain sufficient space to make a perfect form restoration, for the reason that in the process of decay the teeth have fallen together to such a degree that a large part of the mesio-distal diameter of the tooth has been lost. If the loss is not great, sufficient separation may be obtained by the use of the immediate separator of the Perry or Ivory type; but if much of the mesio-distal diameter has been lost it will be necessary to separate for some time in order to obtain sufficient space. This may be accomplished in several ways:

(1) The operator may place an immediate separator upon the tooth, and when as much separation has been obtained as is deemed wise, gutta-percha may be packed into the cavity and left for several days, the patient being instructed to call again, when the same process may be repeated until a sufficient amount of space has been obtained to make the proper restoration. (2) The cavity may be cleaned out and a gutta-percha filling made, which will be a little more full than normal, so that the patient will bite upon the filling. After wearing this for a week a larger amount of the material may be placed in the cavity and this repeated as often as necessary until the required space is secured. This last method is the least painful and the best.

The resistance form is that form given to a cavity which will enable the filling placed therein to withstand the stress that falls upon it in mastication. When it is remembered that a filling will have to stand the masticatory stress of from 100 to 300 pounds at each closure of the jaw in the act of chewing the food, some idea is obtained of the necessity of studying closely the best form to give the cavity, so that a filling placed in it will be able to bear this tremendous strain. The best foundation known is the flat base, and the best form that can be given a cavity is a flat base with parallel walls. A box with flat seats and walls at a right angle would be the ideal cavity, and as nearly as possible this should be the cavity that the student should strive to obtain. In cavities occurring in the proximo-occlusal surfaces of molars and bicuspids the double step is used, one in the occlusal surface, called the occlusal step, and one in the gingival portion of the proximate surface, called the gingival step. These fillings have to bear the

greatest amount of stress, and this preparation best confers the ability to withstand the force brought to bear upon them.

The retention form is that form given to a cavity which prevents the displacement of the filling from any cause and consists very largely of the same methods used in the resistance form, that is, the flat seats and parallel walls. If the gold or filling material is thoroughly condensed no other preparation is necessary, for the force of condensation will displace the elastic dentin slightly and the resultant spring of the dentin will cause it to so hug the filling material that it will be impossible to dislodge it. However, it is permissible to shape the cavity so that it will be self-retentive; that is, the internal portion thereof will be larger than the orifice, making a dovetail arrangement of the whole cavity, which will prevent the displacement of the filling short of breaking the tooth. This dovetailing should be very slight, for it is not necessary to make much retention, and more than is necessary is obtained at the sacrifice of useful dentin and the consequent weakening of the tooth.

The convenience form is that form which we give a cavity which will enable the operator to fill it more conveniently. After all, the filling of the cavity is of the greatest importance, for no matter how perfectly it has been prepared, if the filling material is not inserted so that it hermetically seals the cavity the operation will be a failure. For this reason it is of the greatest importance to make the cavity of such shape that the operator can fill it perfectly. It is not possible to lay down any hard and fast law on this subject, for here more than any other place the personal equation of the operator comes into play. One operator will be able to fill perfectly a cavity that will be impossible to another; therefore the only rule that can be made is that every cavity should be shaped so that the operator can fill it perfectly. One rule that is universally true is that in the making of a gold-foil filling all portions of the cavity should be so accessible that the plugger point can perfectly reach them, for gold cannot be condensed around a corner.

Pits and pothooks are no longer permissible, for they are not only useless as a means of retention but are positively harmful. A convenience pit may be used as a help in starting the gold, but not as a means of retention. This sort of a pit should not be deep, only deep enough to enable the operator to start his pellet of gold and have it retained until he is able to fill that portion of the cavity and have the general retentive form hold the gold firmly from that on. Many operators do not use a convenience pit at all, simply depending upon the point in one of the gingival angles for a starting place.

The removal of any remaining carious dentin should always be insisted upon. Usually when the preparation of the cavity has pro-

gressed thus far all of the infected dentin has been cut out, but in deep-seated cavities there may be some decayed dentin left, and this should be carefully sought out and removed, for any carious dentin is a menace to the filling and a greater one to the life of the pulp. This should be removed with a spoon excavator of as large a dimension as the size of the cavity will permit.

The preparation of the enamel walls contemplates the beveling and smoothing of the enamel margins. It may be remembered that the outline form was obtained as the first part of the cavity preparation, but the beveling and smoothing of the enamel margins was left as the last part of the operation, for in the progress of the work the enamel margins might be injured and roughened; therefore, the final finishing of this important portion of the cavity is left until the last. The enamel margins should be beveled all around the cavity for the protection of the enamel margins themselves. In the study of the structure of the enamel it will be remembered that it is composed of rods standing upon end, resting upon the dentin, and in their general arrangement agreeing to the form of the dentin. In studying the splendid reproduction of Dr. Frederick B. Noyes' diagram upon the subject it will be noticed that while there is a general agreement of the enamel rods in their direction to that of the dentin, in some very important places there is a discrepancy in their following the form of the dentin.

At the extreme gingival portion the enamel rods have a root-wise inclination, and as they approach the middle third of the tooth they straighten up, so that at that portion of the tooth they are practically perpendicular to the dentin. As they approach the cusp of the tooth the rods incline in the opposite direction, until at the apex of the dentin cusp they are again perpendicular to the dentin. Passing over the cusps they are found inclining toward the sulcus or fissure, if there is one, and in the immediate vicinity of the fissure they join their fellows on the opposite side in falling together to such an extent that a cut through this territory will find no short rods upon the surface. A study of this diagram will do more to teach the student the wisdom and necessity of beveling the enamel walls than anything known. By studying this it will be seen that a margin made in the gingival region, if cut straight across the horizontal axis of the tooth, would leave a large number of short enamel rods; that is, rods that were so cut that the dentin portion did not rest upon the dentin. They were cut off from their dentin base, and, as a consequence, are in a very weak condition, so that the slightest stress will cause them to fall out and leave a vulnerable spot in the filling. All modern operators are convinced that more failures are due to this fault in cavity preparations than any other, with the exception of a failure to carry out the lines of extension.

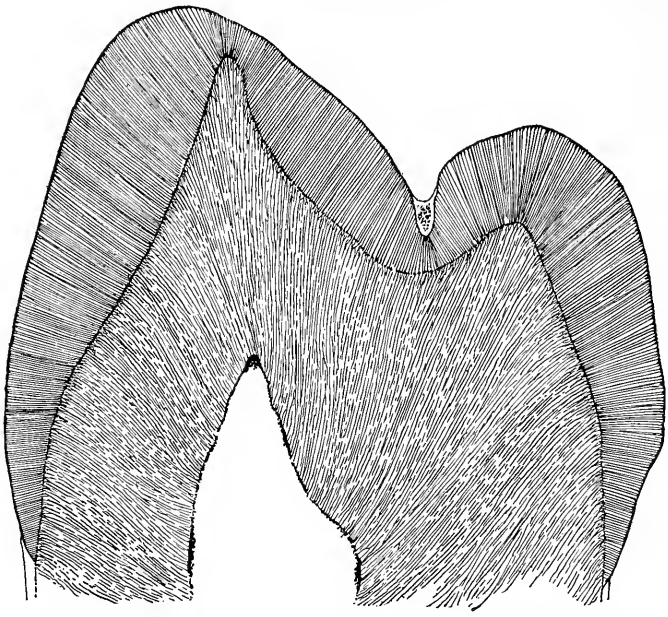

FIG. 123.—Diagram of enamel rod directions, from a photograph of a bucco-lingual section of an upper bicuspid. (Noyes.)

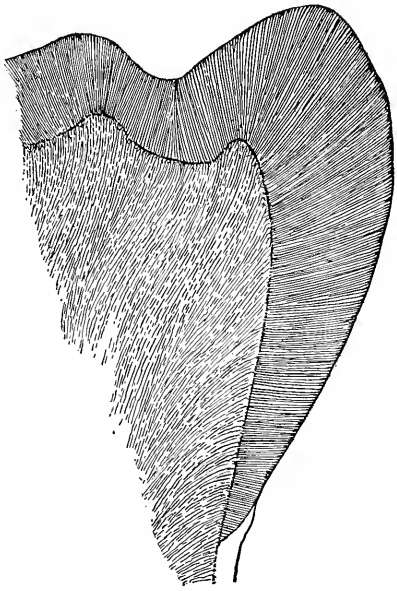

FIG. 124.—Diagram of enamel rod directions, drawn from a mesio-distal section of a bicuspud. (Noyes.)

On the contrary, when a pit or fissure is approached it will be found that their arrangement is of such a nature that, as they are inclined toward each other and into the cavity, a straight cut through them will leave no short rods upon the surface. In the immediate vicinity of a pit or fissure, therefore, it is not absolutely necessary to bevel the margin, and we do so only to be sure that we have removed any rods that have been injured in the operative procedures. At all developmental lines the rods are weak, and it is always a rule in the management of the enamel margin, when a developmental line is approached, to go beyond it and lay the margin in the strong enamel beyond the line of fusion.

It will be noticed that as the enamel rods approach the cusps of any of the teeth they incline toward the cusp. This will necessitate making a very decided bevel as the cusp is approached, until arriving at the crest of the cusps it is the part of wisdom to go beyond and cut off the enamel and reproduce it in gold. A failure to do so will endanger the filling by causing a breaking down of the enamel rods with an ultimate destruction of the entire filling.

The beveling of the enamel margins, or the making of the cavo-surface angle, as it is technically called, should be done with sharp chisels and marginal trimmers. The occlusal and proximate portions may be made with a chisel, but the gingival margins will be best obtained with the marginal trimmers. Some operators prefer to make the required enamel bevel with sand-paper disks and strips, but this is an error in technic, for the reason that a definite bevel cannot be as readily obtained in this way, and for the further reason that the gold cannot be adapted as easily to a polished surface as to a planed one. Furthermore, the chisel in the hands of an observant operator is the best indicator of the direction of the enamel rods. While in the main the diagram of Dr. Noyes is correct, yet there are so many exceptions to the rule that the operator is never sure of the lay of the rods in any position on the surface of the tooth, except as it has been tested by the cleavage under the chisel. Therefore the chisel in his hands becomes the best possible guide as to where and how the enamel bevel should be made in any particular case.

The toilet of the cavity comprehends the thorough cleansing of the cavity of all chips and debris. As all of the operation has been conducted under the rubber dam the tooth is in the best possible condition for the reception of the gold, without any further treatment. If the chip blower does not remove all of the cavity debris a piece of cotton or spunk in the pliers will be all that is necessary. The freshly cut dentin is in the best condition against which to pack the gold, so no medicament of any description should be placed therein. If any

moisture has penetrated to the tooth it should be dried thoroughly and the dentin freshened by slightly cutting the surface with a sharp hoe.

There are five classes of cavities which are named according to the tooth and their position on the surface thereof:

Class I. Cavities having their beginning in the defects of tooth structure, as fissure and pit cavities.

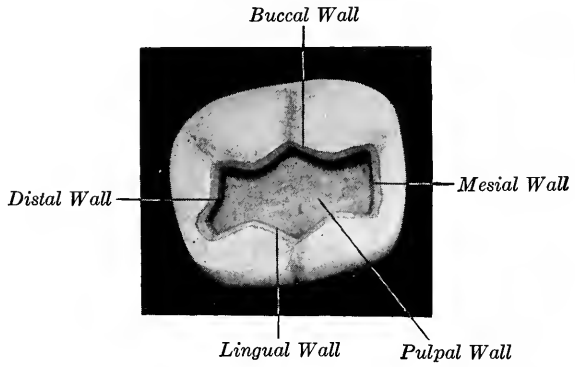

FIG. 125.—Occlusal cavity in the lower first molar, illustrating Class I cavities and names of their walls.

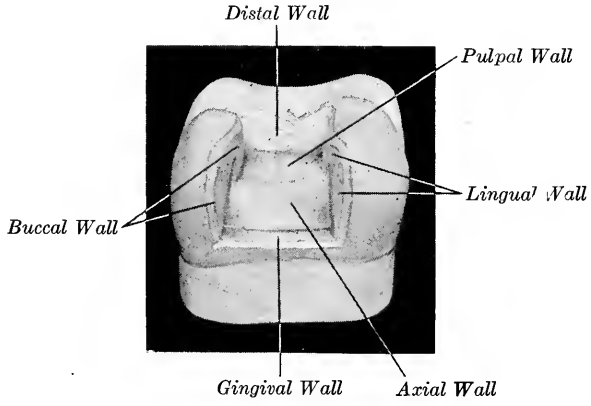

FIG. 126.—Mesio-occlusal cavity in the upper first molar, illustrating Class II cavities and names of their walls.

Class II. Cavities having their beginning in the proximate surfaces of bicuspids and molars.

Class III. Cavities having their beginning in the proximate surfaces of incisors and cuspids not involving the angle.

Class IV. Cavities having their beginning in the proximate surfaces of incisors and cuspids involving the angle.

Class V. Cavities having their beginning in the gingival surfaces of any of the teeth.

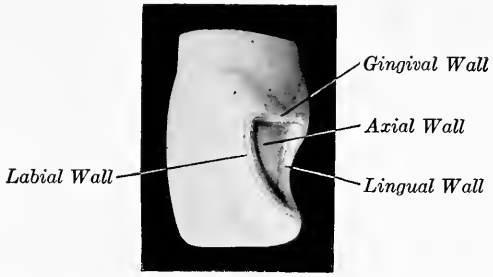

FIG. 127.—Mesial cavity in the upper central incisor, illustrating Class III cavities and names of their walls.

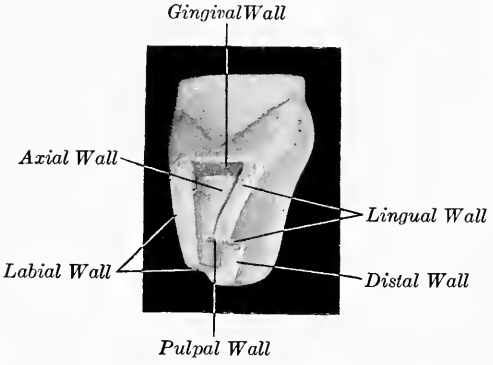

FIG. 128.—Mesio-incisal cavity in the upper central incisor, illustrating Class IV cavities and names of their walls.

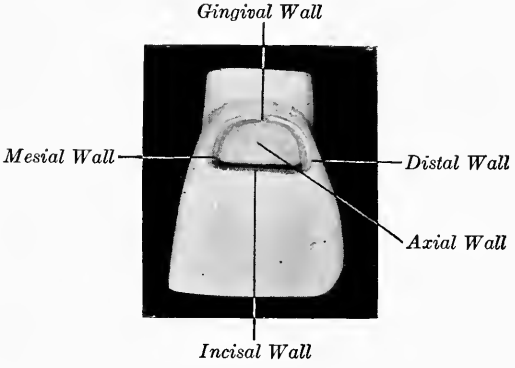

FIG. 129.—Labial cavity in the upper central incisor, illustrating Class V cavities and names of their walls.

In the preliminary considerations we presented a plan of operation that should be carried out in the preparation of any cavity, and in

following the system it is advisable to adopt the sequence there given, though it is possible to combine some of them in actual operation; for instance, the resistance and retentive forms are so nearly alike in practice that it is nearly always possible to make them at the same time. After one has been accustomed to this system of operation it will become involuntary and will be followed without conscious thought or effort. It is at this condition that the student should try to arrive, for the best work is that which has been done so many times that the eyes and hands have been so trained that they coördinate every step of the operation without conscious effort, just as the organist plays the most difficult compositions without giving thought to the technic, but devotes his entire attention to the interpretation of the composer's thought, the hands and feet involuntarily carrying out the designs of the composer. Thus the dental operator, by repeatedly following the system here given, finally arrives at the point where the system and its rules and sequences are followed involuntarily, while the whole effort of the operator is given to idealizing his work.

By reason of the failure of nature to close the enamel plates by fusion with one another there will be a pit or fissure left at the point of failure which will make an ideal place for the organisms of decay to penetrate and begin the work of tooth destruction. Such places are the fissures in the occlusal surfaces of bicuspids and molars, the pits in the buccal surfaces of the lower and lingual surfaces of upper molars and in the lingual surfaces of the upper incisors, particularly the laterals.

Class I Cavities.—If the carious process is just beginning there will be only a fissure with very little decay, and that at a slight depth. This is the ideal time to fill the tooth and prevent further destruction of tissue, or any possible pulp complications by the incursion of the pathogenic organisms, thereby causing irritation which might possibly lead to inflammation and death.

Since the decay is very slight it will be necessary to open up the cavity with an engine instrument. A cross-cut fissure bur No. 702 is the best instrument with which to do this the most rapidly and efficaciously. The bur should be placed in the point of entrance of the decay, and, when it has penetrated through the enamel, rapidly follow the fissures to their entire extent. With chisel No. 28 or No. 29 and mallet the enamel may now be broken down to some extent, when, with an inverted cone No. 37 or No. 39 the enamel may be undermined by cutting the dentin from underneath the same. At the same time the depth of the cavity may be obtained and the floor somewhat flattened. In this way the required outline form is secured and at the same time some progress is made in obtaining the resistance and retentive forms. When the enamel has been undermined sufficiently for the chisel to break it the

chisel should again be used and the entire outline form obtained. This will mean that all of the fissures are eliminated and the margins of the cavity are laid in smooth sound tissue.

In a cavity of this class there will be very little need of a resistance form, for the force of masticatory stress will have a tendency to pound the filling into the cavity, so the resistance and the retentive forms will be identical. This form will consist of a flat pulpal wall, with the lateral walls perpendicular to it, making the whole cavity as nearly like a box as possible. The depth of the cavity will depend upon the force of mastication, for a heavy masticatory stress would cause the gold in a shallow cavity to flow and the filling would fail as a result. The cavity should always penetrate the enamel and have the seat made in dentin. It is rarely possible to make a filling that will stand the stress of years of mastication with a depth of less than $1\frac{1}{2}$ mm., and it would be as rare to have one deeper than $2\frac{1}{2}$ mm. If the penetration of decay calls for a greater depth than that, it will be wise to fill the cavity with a cement first, allowing the patient to wear this filling for a week or more, and then, if all is well, make the cavity of the proper depth, with the cement as a base. If there is only one point of deep penetration, which is often the case, make the depth of the cavity without considering the depth of penetration of this one point: do not attempt to cut the floor of the cavity to the depth of the deepest part. Make the rest of the floor flat at the required depth and then, when finished, remove the decay from the part of deepest penetration and proceed to fill in this way.

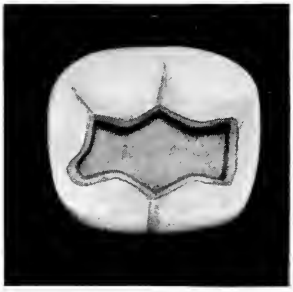

FIG. 130.—Occlusal cavity in the lower first molar.

In a cavity in this situation the convenience form is negligible, for all parts of the cavity are accessible. However, if the filling is to be of cohesive gold, do not make an undercut or even a perfectly perpendicular wall on the mesial, for to do so would make the adaptation of gold at this point rather difficult (Fig. 130).

Slightly incline this wall mesially so that the plugger may reach the

bottom of the cavity and perfectly adapt the gold to the walls. The slight loss of retention, because of this preparation, will be more than compensated by the ease of access and perfection of condensation of the gold. If the filling is to be one of non-cohesive gold this convenience form should be discarded and a sharp, square angle made at the mesial portion of the cavity, for it will not be hard to adapt the non-cohesive gold to an angle even though the line of force is not perfectly obtainable. The paralleling of the walls of the cavity can best be made by the use of a fissure bur in the contra-angle hand-piece and the angles made sharp with a hatchet.

All of the remaining carious dentin should now be removed. There will usually be none left except in those cases in which there is a deeper penetration of decay than it is thought advisable to make the cavity, in which case, remove the remaining carious dentin until sound tissue is found. The decay can best be removed with a spoon excavator of as large size as the cavity will permit. The instrument should be placed under the decay and the whole mass lifted out of the cavity. When all of the decay has been removed it is well to thoroughly plane the underlying dentin to remove any infection and provide good, healthy tissue against which to condense the gold.

The finishing of the enamel margins is the last act in the preparation of the cavity and consists of smoothing all the lines of the cavity margin and obtaining the cavo-surface angle. This should be made with a very sharp chisel, carefully ascertaining the direction of the enamel rods and then making a bevel about one-quarter of the thickness of the enamel all around the cavity. It is best to make the cavo-surface angle with a planing instrument rather than a stone or disk, because it has been demonstrated that gold can be more easily adapted to a planed surface than to a polished one.

The toilet of the cavity is made by the removal of any chips or debris of any kind that may be left as a result of the preparation of the cavity. The debris may usually be removed with a blast of warm air, but if not the cavity should be wiped out with a piece of cotton or spunk. No liquid of any sort should be used in the cavity, and if it becomes moist through the leaking of the saliva through the rubber dam, or from any other cause the cavity should be thoroughly dried and the dentin freshened by going over it with a chisel or hoe. In case of close proximity to the pulp and the danger of thermal shock some non-conducting substance may be placed between the gold and dentin. Dr. Black advises a piece of quill, and this is very good. A good substitute may be made of a piece of thin celluloid, cut so that it accurately fits the bottom of the cavity. Or a little cavitin may be placed in the cavity, care being used that none of it comes in contact with the walls or

margins thereof. On the evaporation of the menstruum a thin layer of celluloid will be adherent to the dentin and will make a very good non-conductor of thermal changes.

Cavities occurring in the pits of upper molars are also Class I cavities and are treated in the same manner as those in the occlusal surfaces of the lower molars. The floors of the cavity are made flat, the walls perpendicular to the floors and parallel to each other as much as the nature of the case will admit and the enamel margins beveled all around

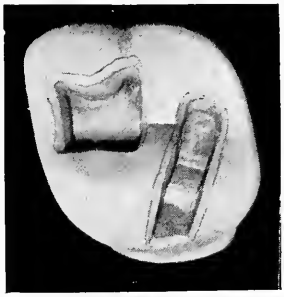

FIG. 131

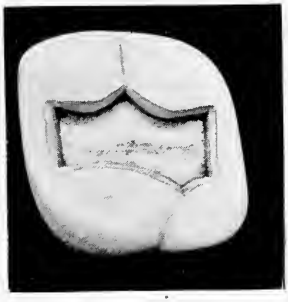

FIG. 132

FIG. 133

FIGS. 131, 132 and 133.—Occlusal cavities in the upper first molar. Fig. 131 showing cavities in central pit and distal fissure filled separately. Fig. 132 showing transverse ridge cut across and pit and fissure cavities made as one. Fig. 133, same as Fig. 132, but disto-lingual fissure involved.

the cavity. If the oblique ridge has not been undermined and the cavities are confined to the pits in the occlusal surface of the upper molar it will not be wise to cut across the ridge and make the cavity as one, but allow the ridge to remain intact, prepare a cavity in each pit and treat them separately. In case the decay has progressed to such an extent that the oblique ridge has been appreciably undermined, it will be well to cut through the ridge, unite the cavities having their beginnings in the central and distal pits and make them as one. In this case the treatment will be practically identical with that of a cavity

in the occlusal surface of the lower molar, except for such slight changes as the anatomic form of the tooth will demand. If the lingual marginal ridge remains intact the lingual margin of the cavity may be established just before reaching the crest of the marginal ridge. But if, as frequently happens the disto-lingual fissure is defective throughout its length it is necessary to carry the cavity over the marginal ridge onto the lingual surface of the tooth. Then the fissure should be cut out the entire length until the margin will be laid in the smooth territory to the gingival of the fissure. The fissure should be followed with a No. 702 cross-cut fissure bur and the enamel broken down to the outline form with a chisel. The gingival wall should be made flat with a No. 35 or No. 37 inverted cone bur followed by the use of an obtuse angle hoe of proper size to fit the situation. The mesial and distal walls may be paralleled by the use of the inverted cone or the fissure bur. A fissure bur is preferable in this situation. The making of the cavo-surface angle offers but one point of emphasis, and that is the lingual marginal ridge. The cavity as it passes over this marginal ridge finds the enamel rods bent toward the fissure and consequently in a favorable condition to withstand the force of masticatory stress, for no short rods are likely to be left upon the surface as a result of the preparation of the cavo-surface angle even though a straight cut were made through the fissure. Owing to the unusual stress that will inevitably come upon this portion of the filling it will be well to make a rather long bevel so that the margins may be strengthened and at the same time the filling so made that it will be able to withstand the stress of occlusal force without flowing. Convenience angles may be made in the disto-axial and mesio-axial angles, but the one in the mesio-axial angle should not be very pronounced, for if it were it would be difficult to reach it with the point of the plugger and an imperfect condensation of the gold at that point would result. In preparing a cavity for the reception of a gold filling it should be in the operator's mind never to prepare any angle or position of the cavity in such a way that it will not be perfectly accessible to the plugger, for gold cannot be well condensed around a corner. The attempt to seal hermetically a place in a cavity that is inaccessible to the plugger point will invite infiltration decay by reason of a failure to perfectly adapt the filling material to the dentin at that point.

Cavities occurring in the pits and fissures of the bicuspids, both upper and lower, are Class I cavities, and their treatment calls for no further amplification. The seats should be made flat and only as deep as the carious condition will demand, for here there will be no unusual stress and the carrying of the depth of the cavity through the enamel will be sufficient to maintain the integrity of the filling. In case there is a

deeper penetration of the decay it will be necessary to make the cavity deeper, of course, but the resistance and retentive forms are amply provided for if the filling is well anchored in the dentin.

Cavities in the buccal surfaces of the lower molars and lingual surfaces of the upper incisors are pit cavities and therefore in Class I. Their preparation will be with the flat seat, parallel walls and the bevel-

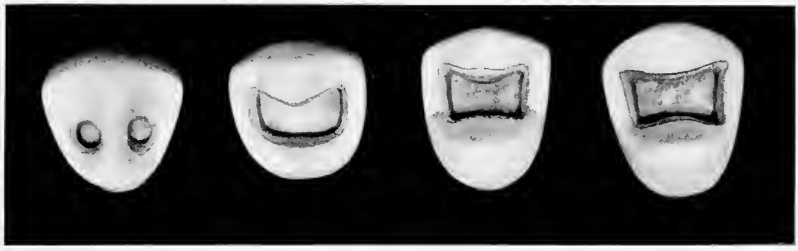

a *b* *c* *d*

FIG. 134.—Occlusal cavities in the bicuspids. *a*, lower first bicuspid; *b*, lower second bicuspid; *c*, upper second bicuspid; *d*, upper first bicuspid.

ing of the cavo-surface angle. No special mention need be made of the preparation of these cavities, except to warn the student against the exposure of the pulp in the case of the cavities in the lingual surfaces of the upper incisors. If a very deep preparation should be attempted there would be a great danger of pulp complications. These cavities should be sought out at the very first opportunity and filled before there

FIG. 135.—Buccal cavity in the lower first molar.

FIG. 136.—Lingual cavity in the upper lateral incisor.

is any great penetration of decay. The depth of the cavity need not be great for there will be little stress in this situation and a deep resistance form is not necessary. The convenience angles should be made in the disto and mesio-gingivo-axial angles for a point in the inciso-axial angle would be so out of the line of force that it would be difficult to fill perfectly. Therefore, the retention should be made by the box-

like form of the cavity assisted by the angles in the gingival portions of the cavity, making the angle in the incisal portion as acute as possible to reach with the plugger point, but no more. Fortunately, no great degree of stress falls upon a filling made in this situation so that a great deal of retention is not necessary, and a perfect adaptation of the gold to the cavity is of more importance than the resistance or retentive forms.

There are a number of weak spots in the enamel in this surface, being at the developmental lines, and care should be taken to seek them out, remove any frail portions, and so bevel the margins that the enamel will be perfectly protected.

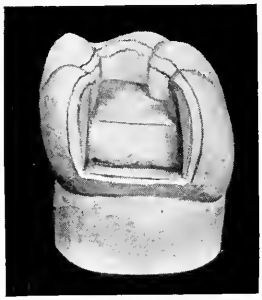

FIG. 137.—Mesio-occlusal cavity in lower first molar.

FIG. 138.—Mesio-occlusal cavity in lower second molar.

Class II Cavities.—Class II cavities are those having their beginnings in the proximate surfaces of bicuspids and molars. The decay has its inception on the proximate surface of the tooth just gingivally to the contact point, and is not apparent to the patient until it has made considerable progress; perhaps not until the carious process has gone so far that a sudden force upon the occlusal portion of the tooth in mastication breaks the marginal ridge and the cavity is opened up, when the patient presents with the statement that the cavity came all at once. It is sometimes difficult for the dentist to find these cavities in their inception, and yet that is the time they should be located and filled; therefore, it is the duty of the dentist to make a careful search for this class of cavities, using small curved explorers for the purpose, being assisted by the use of the electric mouth lamp and compressed air. The lamp will frequently assist in locating cavities that defy the ordinary methods of search, and the compressed air is valuable in clearing away the saliva and debris and giving a clear field for inspection.

When a cavity of this class is to be filled it is the invariable practice to fill it from the occlusal surface, making it a proximo-occlusal cavity.

This is for the double purpose of making the extension and resistance forms more perfect and making the cavity of such convenient form that the gold can be well adapted to the walls of the same. Fillings made by the old method of attempting to fill the cavity by making a simple proximate cavity failed, because there was a recurrence of decay around the margins that were not brought out into immune territory. The cavities so made were very difficult of access and the gold was imperfectly adapted to the walls thereof, so that the fillings leaked and there was a recurrence of decay by infiltration.

Frequently cavities occurring in the proximate surface of a bicuspid or molar are complicated by the presence of decay starting in a fissure in the occlusal surface. Whether that be true or not the entrance to the cavity is through the occlusal surface. By the use of a cross-cut or dentate fissure bur No. 702 an entrance is made through the enamel into the dentin and the bur is made to travel toward the margin cutting



FIG. 139.—Two views of mesio-occlusal cavity in upper first bicuspid.

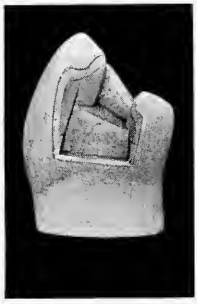

FIG. 140.—Mesio-occlusal cavity in the lower first bicuspid.

into the dentin and drawing it up through the enamel. In this way the enamel is undermined and its organization broken up to such a degree that the breaking down of the same is a very easy matter. If the decay has penetrated into the dentin from the proximate surface to any great extent it will be a very short time until the bur will fall into the cavity, when the marginal ridge should be undermined with the bur cutting upward at the same time, making a sweeping motion sideways to widen the cavity. When sufficiently undermined the marginal ridge should be broken down by the use of chisel No. 38 or No. 39. With the same bur the cavity may now be deepened toward the gingival by cutting close to the dento-enamel junction and sweeping the bur from lingual to buccal. Cut the cavity until a sufficient gingival depth has been obtained. The enamel, being undermined by this operation, can be cut away easily with the chisel and the buccal and lingual extensions obtained in the same way. The easiest and most expeditious method

of removing the enamel is to place the edge of the chisel at the enamel margin where the break is desired, and then tap the end of the chisel with the mallet. If the enamel has been properly undermined it will be very easy to break it away until the proper outline form has been obtained. The occlusal step should be made by the use of the inverted cone bur No. 37 or No. 39 as the width of the step may demand. The outline form has been obtained by the breaking down of the enamel under the chisel and mallet, so it will be comparatively easy to cut the dentin to the proper depth and form. The depth will have to be gauged by the amount of resistance that the filling will have to withstand, and will comprehend one of the points of the resistance form, which we should now have in mind. If it has been ascertained that there is a strong occlusal force that will probably be exerted upon the finished filling, it will be necessary to make the cavity correspondingly deep and broad. If it is to be a deep and broad preparation, a No. 39 inverted cone bur should be the choice and the floor of the occlusal step made as deep as necessary. If the force to be withstood is moderately great a depth of $1\frac{1}{2}$ mm. will usually be sufficient; but if the occlusion is particularly strong, 2 mm., and in rare cases, $2\frac{1}{2}$ mm. will be permissible. In making the resistance form in the occlusal step the lines of the recession of the pulp should be in mind and care should be observed not to cut through these lines for fear of cutting into a prolongation of a horn of the pulp, in which case the destruction thereof would be an inevitable consequence. It will not be possible to give a study of the recessional lines of the pulp in this treatise, but the student is urged to familiarize himself with the subject so that he may avoid the distressing accidents that an ignorance thereof will inevitably lead him into, namely, exposure of the pulp.

When the cavity depth has been obtained the walls should be made perpendicular to the floor and should be as nearly parallel to each other as the form of the tooth will permit. The ideal that should be always before the operator is to make his cavities as nearly like a box as possible and only depart from that as the anatomic form of the cavity and the exigencies of the carious process may demand. Decay does not follow any hard and fast lines, and while the ideal should always be sought it must be borne in mind it may not always be attained. However, with an ideal in mind and an effort for its attainment one may become a more perfect operator.

The squaring out of the cavity, paralleling of the walls, etc., will be most easily obtained by the use of the fissure bur, either plain or dentate. After the walls and floor have been roughly squared out by the use of the burs they should be smoothed by the use of the hoe No. 4 or No. 5 or the chisel No. 29 or No. 31.

The gingival wall should be made flat by the use of the inverted cone bur No. 37 or No. 39 as the case may be, the choice of the smaller or larger bur being determined by the resistance form that has been chosen. If the resistance is to be great the larger bur should be the choice, but if the seat is not to be as broad as that contemplated by the use of the larger bur then the No. 37 should be used. The idea that is to be in the mind of the operator all the time is to make the cavity of proper proportions and adequate strength. The buccal and lingual walls are to be made perpendicular to the step and parallel. In the linguo-gingivo-axial and bucco-gingivo-axial angles, convenience points should be made for the retention of the first pieces of gold, whether the cohesive or non-cohesive methods are contemplated. These points are made by allowing the shank of the bur to follow close to the bucco or linguo-axial lines and then letting the head of the bur sink into the gingival point angle. The angle may be made sharper by the use of the $33\frac{1}{3}$ inverted cone bur or the hand instrument No. 8 or No. 9. These instruments are primarily intended for the beveling of the cavo-surface angle, but are admirably adapted for the making of point angles in the dentin.

The general outline of the resistance form and retention form being made by the use of the bur, it is well to smooth up the cavity by the use of the obtuse angle hoes, going all over the dentin with a planing motion thus making a smooth and beautiful finish.

In making a proximo-occlusal cavity in a molar or bicuspid we have obtained the required convenience form, for no angle of the cavity so made is placed so that the plugger point cannot directly reach it and the condensation of the gold against all of the walls of the cavity is assured if the operator uses the right technic in condensing the same.

If there is any remaining carious dentin it must be removed, after which the enamel margins should be finished. This means that all of the marginal lines should be squared up. The lines from the occlusal to the gingival margins should be made as straight as possible. Particular care should be given to the linguo and bucco-gingival outline angles to see that they are well out of the embrasures. These are the points of the greatest vulnerability and are the points of the most frequent failure by reason of a recurrence of decay around the margins. Because of the fact that the angles have been rounded off or allowed to fall so far within the embrasures that the margin of the filling was within the area of susceptibility, and the bacterial plaques were therefore enabled to fasten themselves upon the enamel in proximity to the filling, a new point of decay was started that undermined the filling and the destruction of the same was the outcome. To prevent such an occurrence, square out the angles of the cavity to such an extent that

they will be in immune territory and no fear need be felt of a failure by reason of a recurrence of decay if the gold has been properly adapted.

The cavo-surface angle must now be made, and at the gingival margin in an upper tooth can best be made with right and left instruments designed for this purpose, Nos. 8, 9, 10 and 11. These margins on the proximate surfaces of the lower molars and bicuspids are best made with the Nos. 12 and 13 for margins on the distal surfaces and Nos. 14 and 15 for margins upon the mesio-gingival surfaces. The buccal and lingual margins can be made with the chisels Nos. 28, 29, 30 and 31.

The cavo-surface angle upon the occlusal surface is also made with the chisel. All of the cavo-surface bevel for the gold filling is made at an angle of from 10 to 15 centigrades and from one-fourth to one-half of the thickness of the enamel.



FIG. 141.—Proximo-occlusal cavity in upper molar, showing method of protecting a weak cusp, by cutting off a portion and restoring with gold (*a*) mesio-buccal cusp cut off.



FIG. 142.—Mesio-occluso-distal cavity in bicuspids, showing method of strengthening weak cusps.

The toilet of the cavity finishes the preparation and the rubber dam having been in position and the excavation having been made in a dry cavity, there is usually little that need be done. A blast of warm air is usually sufficient, but if not, this may be supplemented by going over the cavity with a piece of cotton or spunk in the pliers.

If the carious process has progressed so far that the cusps of the tooth are undermined or weakened by the near approach of the decay, it will be necessary to protect them by cutting off a portion of the cusps and building the gold over them. If this is not done there will be danger of breaking off one or more of the cusps. This is particularly true in the case of a tooth from which the pulp has been removed. In the event that it is thought advisable to protect them, grind off a portion of the cusp or cusps as may be thought expedient. The amount of the tooth to be removed must be determined by the amount of decay that

has undermined the cusp and the amount of stress that will be brought to bear upon the finished filling. It should always be enough to make room for a sufficient bulk of gold to stand the stress of mastication without flowing. A sufficient amount of the enamel should be removed to bring the cavity to sound tissue supported by a good body of dentin. In the finishing of the cavo-surface angle in this class of cases the bevel should be decided and of sufficient depth to make for a goodly flange of gold that will go over the enamel margin and effectually bind the walls together. If the cavity is so made and the amount of gold that overlays the walls of the tooth is sufficient, there will be little danger of a fracture of the tooth. This rule is one that should be followed in all cases whether the cavity occurs in a bicuspid or a molar. It is also of equal importance to protect the incisal angles of incisors and cuspids in case of a like weakness.

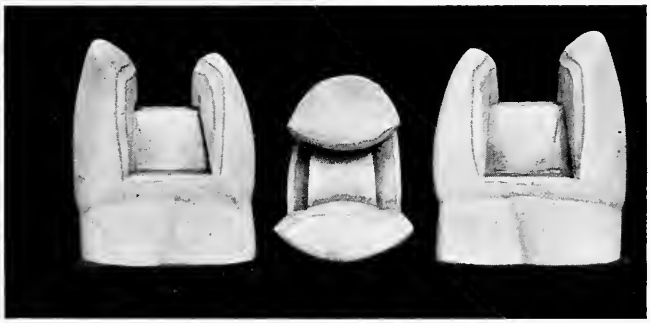

a *b* *c*

FIG. 143.—Three views of mesio-occluso-distal cavity in upper first bicuspid. *a*, mesia view; *b*, occlusal view; *c*, distal view.

Cavities involving the distal and mesial surfaces of the same tooth are restored by the making of a mesio-disto-occlusal filling. In these cases the method of procedure is the same as in the case of a cavity occurring in either the mesio-occlusal or disto-occlusal surface of a tooth. The outline form is made so that all of the lines of the cavity are in relatively safe territory, while the resistance and retentive forms follow the laws of flat seats and parallel walls. The only difference in the cavity is that the cavities in the two surfaces of the tooth are treated as one and filled at the same time.

There is no difference in the principles governing the preparation of the cavity, whether the carious process occurs in a lower or an upper tooth. There is a difference in technic due to the location of the tooth in the mouth and the dissimilarity of approach. In the making of a cavity in the lower molars and bicuspids it will be expedient to use the

contra-angle hand piece. This will bring the bur into proper relation to the tooth to make the advised preparation. The walls of the cavity and the internal angles can best be cut by the use of enamel hatchets Nos. 22, 23, 24 and 25, assisted in some instances by the very useful angle chisels Nos. 32 and 33.

As indicated above, the cavo-surface angle of the gingival margin in the lower teeth is made with the special marginal trimmers Nos. 12, 13, 14 and 15, Nos. 12 and 13 being for the angles on the disto-gingival margins and Nos. 14 and 15 being adapted for the making of the angle on the mesio-gingival margins. In all other respects the cavities are the same and the technic identical except in the processes enumerated.

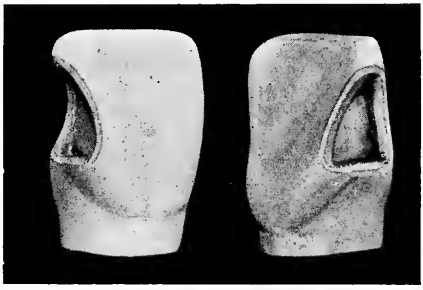

a *b*

FIG. 144.—Mesial cavity in upper central incisor. *a*, labial view; *b*, lingual view.

Class III Cavities.—Class III cavities are those occurring in the proximate surfaces of the incisors and cuspids not involving the angle. The beginnings of the decay are to be found immediately gingivally to the contact point and should be discovered at the earliest possible moment. There is very little excuse for these cavities attaining any appreciable size in the teeth of patients that present for regular examinations. Indeed, there is little excuse for a cavity in any surface of the tooth making much headway if the patient is conscientious in presenting for examination at frequent intervals. But while there might be some excuse for overlooking an incipient cavity in the proximate surface of the second or third molars there is no excuse for the failure to discover a cavity beginning in the proximate surface of an incisor or cuspid.

In the treatment of Class III cavities, the rubber dam being in place, separation must be made, if it has not already been obtained. A separator of the Perry or Ivory type should be carefully placed. Too much pressure must not be used on the single rooted teeth for fear of making the movement so great and sudden that permanent injury may be done to the peridental membrane or pulp. The pressure should be applied gradually and the separator tightened as the tooth moves in the

arch. When sufficient separation has been obtained the point of decay may be entered with a No. 2 round bur. The dentin should be undermined by cutting under the enamel, after which with chisel No. 30 the enamel wall may be broken down to the extent of the undermining thereof. This undermining of the enamel with the bur and breaking down with the chisel should be continued until the desired outline form has been obtained. This form contemplates carrying all of the margins of the filling out of the areas of susceptibility and will mean that the labial margin will be carried labially far enough out of the embrasure to prevent the enamel coming into contact with the enamel or filling in the approximating tooth. In making this extension it is not necessary to bring the gold into such open view that it makes a glaring defect. The cutting of the labial portion of the tooth to such an extent that it disfigures the patient is not good practice, and except in case of extensive decay should not be tolerated. If sufficient separation has been obtained, enough room to perfectly adapt the gold to the walls of the cavity can be obtained without a disfiguring restoration. At the same time the extension must always be sufficient to cause the gold to clear contact with the approximating tooth or the margin will lie in unclean and therefore susceptible territory.

The gingival margin should be cut far enough to allow the gum to cover the margin of the finished filling. The incisal portion should be cut far enough to make the contact on the gold and not on the enamel. Lingually the margin should be carried out far enough to bring it clear of the approximating tooth. This margin should be rather generously cut for the reason that it is not within the range of vision, and the further reason that it is a more difficult portion of the filling to make and by more extensive cutting a greater convenience form is obtained.

The points of greatest vulnerability, and therefore the areas of the greatest number of recurrences of decay, are the labio and linguo-gingival angles. The reason that there is so great a proportion of recurrences of decay in this territory is that in the preparation of the cavities these angles have not been properly squared-out. It is natural, in making a cavity in this surface, to prepare a rounded angle at the labio and linguo-gingival angles which leaves these margins so far within the embrasures that they are not kept clean. The student should emphasize these angles to such an extent that they are seemingly overprepared, for in the large majority of cases an angle that looks to him as though it was too far out of the embrasure will, when filled, be just about right, with the probabilities in favor of the fact that he has not cut far enough. In the outline form of a cavity in the incisal or mesial surface of the cuspid we look for the esthetic form more than in any other class of cavities, for here more than any other place does

the filling obtrude itself upon the consciousness of the observer. Therefore the angles that are within the range of vision should be rounded. In attempting to make rounded angles the student is led into the greater error of not bringing them out far enough, and it will take much time and patient observation to obtain the necessary perfect balance. The angle should first be brought out sufficiently far for purposes of safety, and when that is accomplished the squared angles should be gently curved and made to take on the esthetic form of outline. This is not necessary at the linguo-gingival angle but must be made a matter of routine in making the labial angles both at the gingival and incisal.

The resistance form takes the form of the squared cavity. The gingival wall should be made flat from the axial wall to the surface of the enamel, but labio-lingually it may be curved to harmonize with the outline of the cemento-enamel juncture. The round bur should be discarded as soon as the outline form has been obtained and should never be used in making the resistance or retentive forms. In the class under discussion the best bur to use is the No. 35 or No. 37 inverted cone.

The end of the bur should be used in making the flat seat at the gingival and the sides of the bur may be used in making the labial or lingual walls. These walls should be as nearly at right angles with the gingival seat as the form of the tooth will permit. The incisors being of a wedge form a cavity in the proximate surface that attempts to conform in some degree to the shape of the tooth will of necessity take the form of a triangle. The walls of the cavity will therefore converge as they approach the incisal angle and the finished cavity will be triangular in shape. The axial wall should be made to conform to the shape of the pulp; the labial and lingual portions of the same being made deeper than the center, that the pulp may have all the protection of dentin that is possible. The angles should be slightly accentuated, and this may be accomplished with a $33\frac{1}{3}$ inverted cone bur and the point angles then sharpened with the hand instruments Nos. 8 and 9. In making the emphasized angles at the labio and linguo-gingivo-axial angles, there is usually sufficient convenience point to start the filling, but if not, it is permissible to make a convenience point for the starting of the gold in either of the gingival angles.

The labial and lingual walls may be cut out with the right angle hoes Nos. 6 and 7. The point angle at the incisal may be best made with the $33\frac{1}{3}$ inverted cone bur. In making the cavity of the shape suggested we have satisfied both the retentive and resistance forms. The convenience form is very important in this class of cavities, for if the operator is not able to reach all parts of the cavity with the plugger point he will be unable to perfectly adapt the gold to the walls of the

same, and in this situation some of the parts of the cavity may be very inaccessible if the cavity is not sufficiently opened up. It is important, then, at this stage of the operation to determine whether all parts of the cavity are accessible to the plugger point, and if not, to cut away enough of the outline to make the cavity convenient.

The enamel margins should be beveled all around the cavity. The labial and lingual margins may be planed with a chisel and the bevel at the incisal may be made with the same instrument. The gingival cavo-surface angle should be made with the right and left instruments Nos. 10 and 11. The toilet of the cavity is made by removing all debris, carefully searching out any remaining carious dentin and the cavity is ready to fill.

Class IV Cavities.—Cavities of the fourth class are those occurring in the incisors and cuspids involving the angle.

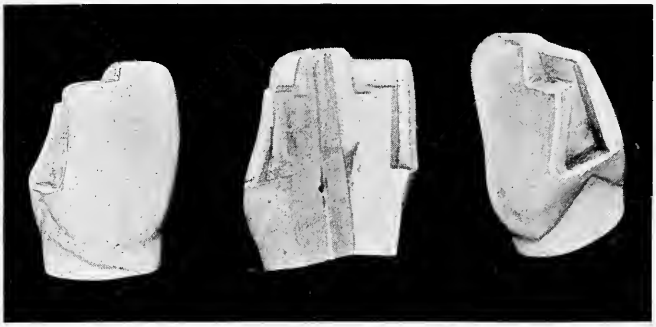

a *b* *c*

FIG. 145.—Mesio-incisal cavity in upper central incisor. *a*, labial view; *b*, mesio-distal longitudinal section; *c*, lingual view.

This class of cavities is more difficult to fill by reason of the fact that in the loss of the angle so much of the tooth has been destroyed that the problem of retention is considerably intensified. There have been several ways suggested for its solution, but the step cavity has been the best in practice and will be adhered to in this treatise. The outline form will be obtained by breaking down all overhanging enamel walls and bringing the margins of the cavity into sound territory. The problem of extension for prevention is usually solved by the progress of the decay, for if the angle has been involved it is more than probable that the tooth has decayed so far that the finished filling will have its margins in safe territory. After the enamel walls have been trimmed down the incisal portion of the tooth should be ground with a flat carborundum stone, the depth and extent of this cutting to be governed by the study of the conditions obtaining in the special case. If the

occlusion is great there will be the necessity for a considerable trimming of the incisal portion of the tooth in order to allow for a sufficient amount of gold over the incisal angle to withstand the stress of occlusion without flowing. It is obvious that the least cutting that can be done with safety should be the ideal, for here, more than in any other place, will the gold be within the range of vision. In order to obviate this difficulty, operators have made the incisal step entirely to the lingual, leaving the enamel at the labial surface practically intact; but the fallacy of this preparation has been proved by the breaking down of the unsupported enamel at the labial or the infiltration of the filling by the flowing of the insufficient mass of gold over the incisal portion of the filling. In this place we will have to sacrifice esthetics for utility and make as deep and broad a preparation as the case demands or failure will result. In case there is no occlusion the hiding of the gold by making nearly all of the step to the lingual is permissible, but if the opposing incisors are able to come into contact with the incisal portion of the tooth in question it will be imperative to cut away enough of the labial plate to allow for a sufficient mass of gold to stand up under stress. The amount of the incisal edge involved, mesio-distally, will also be determined by conditions. Usually it will be necessary to cut past the opposite developmental groove, for in making the incisal step it will nearly always be necessary to carry it past the middle of the incisal portion of the tooth, and in doing so will carry the margin so near the developmental groove that the margin of the cavity will be in weak territory. In order to prevent this it will be found advisable to carry the margin past the groove and finish it in the strong enamel beyond. The labial portion of the step will, in ordinary cases, be cut to a depth of 1mm. or $1\frac{1}{2}$ mm., while the lingual portion will be made considerably deeper. The lingual portion is made deeper for several reasons: (1) because it is out of the line of vision, it may be cut as deep as desired without the violation of any esthetic ideal, and (2) because in the stress of mastication the lower teeth strike against the lingual surface of the upper, and, as a consequence, the greater mass of gold is required at that point. The incisal third of incisors and cuspids is almost entirely composed of enamel, due to the convergence and union of the labial and lingual enamel plates. Therefore, in order to provide sufficient width of dentin labio-lingually, to properly prepare a step, it is necessary to sacrifice one or both plates of enamel. Since the preservation of the labial plate is desirable for esthetic reasons, the lingual plate is cut far enough to provide sufficient dentin in which to anchor the filling. The outline form being completed, the resistance and retentive forms should be made. The gingival wall is made as flat as the nature of the case will allow. In incisors and

cuspids, as has been said, it is permissible to follow the cemento-enamel curve, which will cause the filling to seat upon the convex side of an arch, which in mechanics is unobjectionable, especially when there is not the tremendous stress that will be brought to bear upon a filling in a molar or bicuspid. On the other hand, if we insisted on making the gingival seat flat in the incisors and cuspids we would often find that we would run into the cementum and perhaps the peridental membrane in the central portion of the cavity when we were trying to bring the labio and linguo-gingival angles into safe territory, for there is frequently so great a curve of the cemento-enamel line that it is carried down into the embrasure so far that a flat seat for the filling that would not endanger this line would tend to make a very shallow linguo and labio-gingival angle. Therefore it is the part of wisdom to curve the gingival wall labio-lingually in incisors and cuspids, so that it will in some degree conform to the curve of the cemento-enamel line.

This step is best obtained by the use of inverted cone burs Nos. 35 and 37, according to the size of the tooth being operated upon. The proximate walls will be made triangular with the base to the gingival and the apex toward the incisal. These walls should be as nearly at right angles to the gingival step as the form of the tooth will permit, having them converge as they approach the incisal. At the inciso-proximate angle the cavity will pass into the incisal portion in a groove cut into the dentin between the labial and lingual enamel plates. This groove should not be very deep and should not cut into the enamel. It should be confined entirely to the dentin and some dentin should be left on either side to protect the enamel. After passing the site of the recessional line of the pulp a pit is sunk into the dentin for a slight distance to help resistance to lateral displacement. The groove in the incisal portion of the cavity should be made with a small inverted cone bur, usually a No. 35 in an upper incisor or cuspid. The pit may be made with the same instrument and rendered slightly retentive by undercutting to some extent. The linguo and labio-gingivo-axial point angles should be definitely emphasized, for upon them, to a great extent, depends the retentive form of the cavity. These angles should be made in the same way as those in the corresponding angles in Class II cavities in bicuspids and molars. The angles are made with a No. 35 inverted cone bur and accentuated with the instruments Nos. 8 and 9. If desired a convenience point may be made in the linguo-gingivo-axial angle, but the making of the retentive angles is usually sufficient for the purpose of starting the filling. The shape of the incisal step cavity is such that no more convenience form is needed, so it will not be necessary to elaborate upon that. Any remaining decay should be carefully removed, the cavo-surface angle beveled all around the margins with

the usual hand instruments, the toilet of the cavity made and the cavity is ready for the filling.

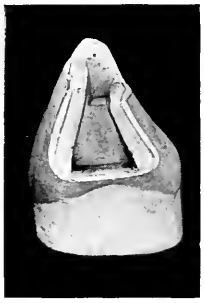

FIG. 146.—Mesio-incisal cavity, upper cuspid.

FIG. 147.—Disto-incisal cavity, upper cuspid.

In proximate cavities occurring in the distal surfaces of cuspids it is very difficult to perfectly adapt the gold to the walls of a cavity made,

a *b* *c*

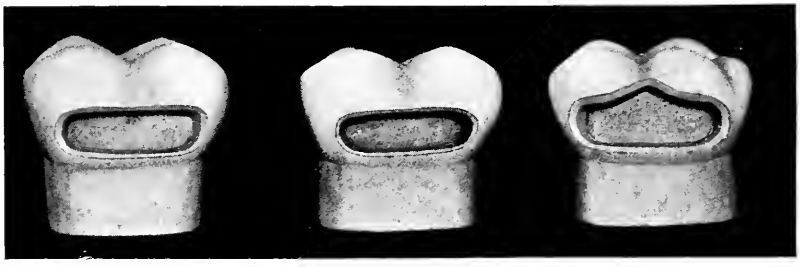

d *e* *f*

FIG. 148.—Gingival cavities. *a*, upper cuspid; *b*, upper central; *c*, lower cuspid; *d*, lower first molar; *e*, lower second molar; *f*, lower third molar.

as is usual in Class II. Therefore, some of our best operators have suggested making all such cavities into Class IV, intentionally involving

the angle and making a step in the incisal surface. They do this for the purpose of making the cavity of sufficient convenience that the gold may be perfectly adapted to it, rightly believing that it is wise to cut away sound tooth structure that the rest of the tooth may be saved with a filling rather than attempt to save a portion of the remaining healthy tooth structure, and by so doing lose the whole tooth by a recurrence of decay, because a perfect filling was not made by reason of the difficulty of adapting the gold to a surface that was not within the reach of the plugger point.

In making this cavity the same rules and technic are followed as outlined for a step cavity in an incisor.

Class V Cavities.—Cavities occurring in the gingival third of any of the teeth are Class V cavities. The placing of the dam in this class is sometimes very difficult. Especially is this true if the decay has penetrated very far beneath the surface of the gum, as is frequently the case in advanced cases. In order to place the dam properly it will be necessary to have a special clamp to push the gum back and to hold the rubber in place. There are several good clamps on the market. If the decay has not penetrated very far an ordinary gingival clamp of the Ivory type may be used effectively. The Hatch and Woodward clamps are well adapted for cavities in which it is necessary to retract the gum in order to gain access. The Ivory clamp is a very superior clamp for this purpose. It is adjustable and is provided with a movable gum retractor that is actuated by a screw with which the gum may be pushed back at will as far as the operator desires. It is advisable to use an anesthetic in cases where there is any considerable retraction of the gum for the pain of the operation is intense. A local anesthetic used upon the gum prior to the operation will obviate all this and make a very trying operation, one that will be bearable.

When the dam has been placed and the field of operation cleansed, the cavity may be opened with a spoon excavator and all of the decay removed. In case it is a cavity in its incipiency it will be necessary to open it up with a bur, when it is wise to use a No. 3 or No. 4 round bur. With this instrument excavate under the enamel until the walls may be chiseled to the desired outline form. The axial wall of the cavity may now be flattened with an inverted cone bur of the proper size, and with the same instrument the walls may be made parallel. The general shape of the cavity should harmonize with the festoon of the gum, carrying the mesial and distal portions to the angles of the tooth. The gingival margin should be placed well under the free margin of the gum, and the portion of the cavity looking toward the occlusal surface of the tooth brought as far occlusally as will be necessary to obtain the scouring action of the bolus as it passes over the teeth in mastication.

As has been said, this will differ in teeth of varying shapes, the bell-shaped tooth requiring a greater extension occlusally than a flat tooth occluso-gingivally, for the reason that in the bell-shaped tooth the bell will cause the bolus to leave the tooth a little beyond the middle third and the gingival third will not receive any of the scouring action. It will be wise to study the shape of the tooth in order to see how far occlusally it will be necessary to carry the extension. In cases of any considerable decay there will usually be a well-defined line of demarcation showing where the frictional action of the food in mastication ceases. Cut a little beyond this white line and the cavity will usually be in safe territory.

The general shape of the cavity will be of a half-moon with blunt edges, and the internal shape will be a flat seat and box-like walls. A convenience point may be made in the disto-gingivo-axial angle for an aid in starting the gold. The cavo-surface angle bevel should be made all around the cavity, not so much for the protection of the enamel rods, for in this class of cavities there will be very little stress upon them, as to be sure that the enamel margins are sound and that there are no loose rods lying upon the surface of the cavity. The toilet of the cavity should now be made, assuring one's self at the same time that all remaining decay has been removed.

FILLING TEETH WITH GOLD.

There are two kinds of gold used in filling cavities in teeth—gold foil and the various makes of crystal gold.

The foil comes in the cohesive and non-cohesive forms and is used in pellets, ribbons, cylinders and ropes.

The cohesive gold is pure gold with an uncontaminated surface. Gold is a metal that does not oxidize when pure, and, consequently, its portions being in the pure and uncontaminated state will cohere. If any contamination adheres to the surface of the gold it becomes non-cohesive; therefore, the operator heats it before using to drive off any moisture or volatile substance that may have adhered to its surface, or may have been placed upon it by the manufacturer.

There are two kinds of non-cohesive gold: that which is made temporarily non-cohesive by the deposition upon its surface of some volatile substance and the permanently non-cohesive gold, that is so made by the deposition upon its surface of a substance that is not driven off by heat, and, as a consequence, retains its non-cohesive properties despite any heating that may be given it. We prefer that which is made non-cohesive by the deposition of some volatile substance for the reason that we may use the same gold for non-

cohesive and cohesive fillings as it suits our purpose, depending upon whether or not we heat it. When this gold has not been heated it is in the non-cohesive form, and when desired in the cohesive form it is only necessary to heat it.

This form of non-cohesive foil is usually made by subjecting the gold to the fumes of ammonia gas, which, being deposited upon the surface of the gold, prevent the particles of gold from coming into perfect contact and thereby prevent cohesion.

There are certain substances that, when condensed upon the surface of gold, defy the power of heat to dispel them, and thus make the gold permanently non-cohesive, a quality that is sometimes taken advantage of by the manufacturers of the permanently non-cohesive types. Some of these substances may be deposited upon the gold as it lies in the cabinet or upon the operating tray. The fact that this does occur is attested by the occasions when we find that it is impossible to make a certain pellet of gold cohere to that placed upon the filling, or when we find that the filling becomes flaky and the pellets fail to properly cohere. That is the reason that an experienced operator uses nothing but freshly prepared gold in his cohesive fillings, knowing from experience that if he does not he will invite failure by having the gold fail to properly weld. Therefore we advise the use of the non-cohesive or so-called soft gold. The name soft gold is a misnomer, as all pure gold that is annealed is soft. Gold becomes soft by annealing and hard by beating or rolling; therefore, the cohesive gold is just as soft as the non-cohesive when it is annealed. The reason that the non-cohesive gold is called soft is because the old operators used the gold in the non-cohesive forms, and when it became cohesive it was hard to use in the way in which they were accustomed to use it. The non-cohesive form, by reason of its non-cohesive qualities, worked more easily and seemed soft under the instruments in contradiction to the harsh properties of the cohesive gold sticking to the gold in the cavity and preventing the newly placed gold from going easily to position. The names soft and cohesive came from that source, but should now be discarded for the better terms, heated and unheated or, if preferred, cohesive and non-cohesive. We find, therefore, that we have two kinds of soft foil: (1) non-cohesive foil, that which cannot be made cohesive by heating; (2) non-cohesive foil, that which can be made cohesive by heating. Both of these foils are called soft, but the first remains soft after heating, while the second becomes cohesive or hard after heating. For this reason we divide the non-cohesive foils into two divisions as follows: unheated—soft foil—non-cohesive, and heated—soft foil—cohesive.

The non-cohesive is advised, because it has its surface protected by a film of volatile gas—usually ammonia—which prevents the deposition

upon its surface of any contaminating substance that would make it permanently non-cohesive and would make a fault in the filling of which it became a part. The ammonia remains upon the gold until it is ready for the filling, when, upon being heated, it is driven off and a perfectly pure fresh surface of the gold is presented for cohesion with that in the cavity and that which is to follow it in the filling, making for perfect cohesion and the possibility of a dense filling.

In preparing the pellets for use in making a cohesive filling we use the No. 4 non-cohesive or soft foil. This comes in books of foil. The pellets are prepared in eighths, sixteenths, thirty-seconds and sixty-fourths. By this we mean that a sheet of gold is taken and divided into eight parts and rolled into pellets, each pellet containing an eighth of a sheet of gold. Likewise a sixteenth pellet is one containing one-sixteenth of a sheet of gold, a thirty-second is a pellet containing one-thirty-second of a sheet of gold, etc. This is done in order that we may definitely know the amount of gold under our plugger point at any particular time. Definite methods produce definite results, therefore we choose to know the amount of gold that we are using at any given time, so that we may know the amount of force that will be required to condense the gold to a required specific gravity. If we did not know the amount of gold we were condensing we would not be sure of the method we were using and could not be sure that we were producing the desired result.

The various forms of crystal gold in the market are cohesive and have no particular advantage over the foil. In the opinion of the authors they are not so good, but excellent fillings may be made with them if the same care is taken in condensing as that given to the foils. The reason that so many failures of condensation and pitted fillings are made with the crystal foil is not the fault of the gold primarily but of manipulation. It requires as much force to condense the crystal golds as it does the foils; indeed, in Dr. Black's laboratory it was found that it really required more force to obtain the same specific gravity with a crystal gold than it did with a foil. If, however, the operator is not misled by the belief that a perfect filling can be made without the expenditure of much condensing force, and uses the same mallet pressure upon a filling made with crystal gold that he uses in making a foil filling, he will be able to make a good filling.

The foil, for use as a non-cohesive gold, must have an entirely different treatment, for here we will have to depend upon the mechanical retention of the gold without any assistance of the coherence of the gold itself. In making a non-cohesive filling, in whole or in part, this fact must be ever in mind, that we must not depend upon the coherence of the gold to help in the retention of the filling.

Non-cohesive foil is used in cylinders, ribbons and ropes, but in this treatise only the cylinders will be considered, because the other forms are unnecessary and will only confuse the student if elaborated upon.

The cylinders are used in whole sheets, half sheets, quarter sheets and eighth sheets. They are made by taking a sheet of non-cohesive gold and dividing it into the number of parts required for the size of cylinder wanted. If it is to be a half sheet cylinder the sheet of gold is divided into two parts. One-half of the sheet is taken and made into a ribbon by folding the gold upon itself a sufficient number of times to make a ribbon of the width we want the length of the finished cylinder to be. In our operations we will want a number of different length cylinders according to the depth of the cavity upon which we are operating. Knowing the length of the cylinder we will want, the ribbon will be made to conform to that width. The ribbon of gold is now taken and rolled upon the end of a Swiss broach or long pin of some kind. A Swiss broach is more useful because the instrument is not round but triangular in shape and the gold will roll better upon it because the angles of the broach will engage with the gold and hold it from slipping while the rolling process is going on. If a smooth instrument be used the gold will have a tendency to slip and it will be difficult to make a cylinder. The cylinder should not be too tightly rolled, nor so loosely rolled that it will not maintain itself as a cylinder and unroll. The ends of the cylinder should be smoothed by holding the cylinder in the hands and slightly pressing in the ends between pliers. In this way a smooth symmetrical cylinder may be made. If much operative work is done it is well to have an assortment of soft gold cylinders of various sizes and pellets of cohesive gold made up ready for use. In case an assistant is available it is wise to make the preparation of the gold a part of her duties.

In the use of the non-cohesive foil for fillings we may use it alone or in combination with the cohesive foil. If it is used alone the cavity should be of box form with four sides. The ideal cavity for the use of non-cohesive gold is one in the occlusal surface of one of the molars. The preparation of the cavity is no different from that in which the cohesive gold is used.

For example, let us fill a cavity of the occlusal surface of a lower molar. A half sheet cylinder is placed on end in the distal portion of the cavity and pressed to place with a large foot plugger. In this position the cylinder is placed on end, one end resting on the dentin of the pulpal wall of the cavity and the other extending out of the cavity. The cylinder should be long enough to extend out of the cavity 1 mm. or $1\frac{1}{2}$ mm. The cylinder is made to rest on end because the leaves of gold have no cohesion and will therefore not cohere to each other. If

we placed the cylinder on its sides, with one of the sides extending out of the cavity, the leaves of the cylinder would peel off and the filling would in that way disintegrate; but if placed on end the sides of the cylinder will be held in place by the other cylinders that are wedged in place against it.

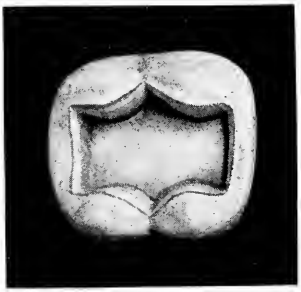

FIG. 149.—Cavity in lower molar prepared for non-cohesive gold filling.

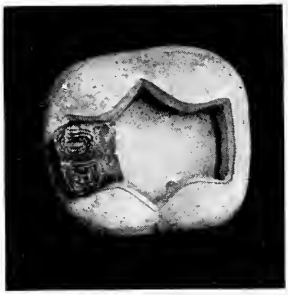

FIG. 150.—Same cavity with cylinder in place in distal portion of same. Cylinder standing on end.

The first cylinder is followed by other cylinders placed on end coming forward to the center of the cavity when a cylinder is placed in the buccal and lingual angles. It will now be advisable to place a cylinder in the mesial angle of the cavity and thereby have the walls of the cavity entirely filled, leaving an opening in the center. The cylinders should be condensed toward the walls of the cavity all around, using

FIG. 151.—Cavity half filled.



FIG. 152.—Cavity filled with the exception of the key cylinder which is illustrated beside the tooth.

hand-pressure and a strong wedge-shaped plugger. Keep on filling around the sides of the cavity until it is impossible to introduce any more of the half cylinders into the center. By the wedging process a small opening will be left in the center that should be as deep as possible and into this opening a tightly rolled half or eighth cylinder is forced

to place, and the entire occlusal surface is now malleted with strong mallet-pressure. In this way the whole mass of gold is thoroughly condensed and the cylinders wedged together, keying the whole mass to place, and, though there is no cohesion of the gold, by wedging the cylinders tightly into a box-like cavity they are so thoroughly locked into it that it is impossible for them to become dislodged. This form

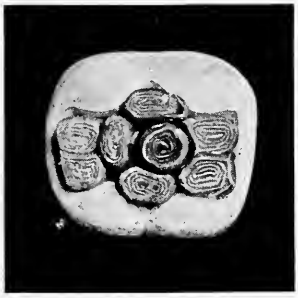

FIG. 153.—Cavity full of cylinders but not condensed.

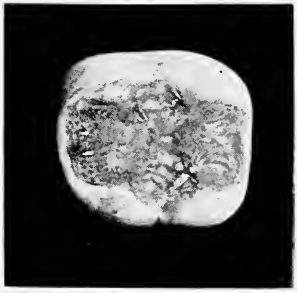

FIG. 154.—Gold condensed by hand mallet.

of a filling makes one of the best fillings that can possibly be made, and many of those made by the great operators of the past are still doing splendid service. The only difficult part of this operation is the making of the central key, and this difficulty is obviated by the use of cohesive gold to make the center wedge. Into the opening that is left in the center of the cavity, introduce a pellet of heated gold, which

FIG. 155.—Finished filling.

makes it cohesive, mallet this to place and fill the central opening full of the cohesive gold, and then mallet the entire surface of the gold as though it were all non-cohesive foil. A filling that would require a long and tedious operation may be made in a very short time and accomplished much more effectively than could be done by the use of cohesive foil alone.

Another place where the non-cohesive foil is of great advantage is in the gingival thirds of cavities in the proximate surfaces of bicuspids and molars. Three cylinders are usually used and should be of the proper size to fit the cavity. In a fairly large cavity in a molar we would use two cylinders of half-sheet each in the angles and one of quarter-

FIG. 156.—Cavity in proximate surface of bicuspid ready for gold filling.

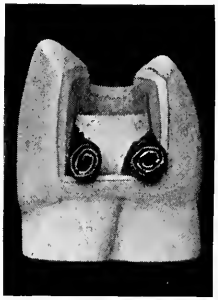

FIG. 157.—Non-cohesive cylinders in bucco and linguo-gingival angles.

sheet in the center. The cylinders having been selected, one of the halves is taken in the pliers, slightly compressed and firmly tucked into the linguo-gingivo-axial angle; then the other half is in like manner placed into the angle on the buccal surface and between these two cylinders is firmly wedged the quarter sheet cylinder of the non-cohesive gold. The three cylinders should now be condensed with

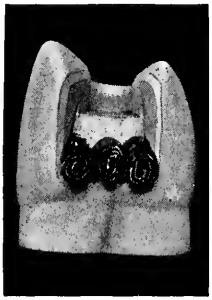

FIG. 158. — Central cylinder keyed in between the two cylinders.

FIG. 159.—Cohesive foil beginning to be built over the cylinders, note foil built in step.

hand pressure, being careful not to push them out of the cavity. They will be held in place by the approximating tooth, but can be dislodged easily by pressure exerted in the wrong direction. The gingival portion of the cavity is now filled and the operation has been accomplished in a quarter of the time that would have been necessary to condense cohesive

gold into the same place and the adaptation of the gold to the walls of the cavity is as nearly perfect as it is possible to make it.

The filling should be completed with cohesive foil. Begin the filling by starting a pellet of heated foil in one of the angles at the distal of the occlusal step. The foil may be heated in several ways: it is possible to heat over the open flame, using for that purpose a flame

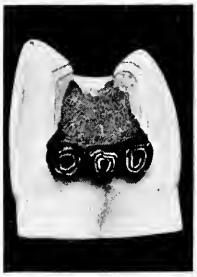

FIG. 160.—Foil in step built over the edge of the step and uniting with gold built over non-cohesive cylinders.

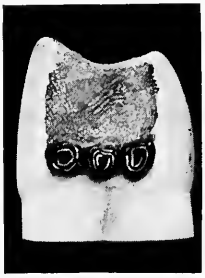

FIG. 161.—Building of cohesive foil finished but non-cohesive cylinders not condensed.

in which the combustion is perfect and in which the gas burns with a perfectly blue flame. The slightest evidence of imperfect combustion is cause to reject the flame, for the products of the imperfect combustion will be deposited upon the gold and will prevent a perfect cohesion, and a flaky filling, or one that will break, will be the result. It is better not to use the open flame for heating at all. Use either a mica or por-

FIG. 162.—Non-cohesive cylinders condensed.

FIG. 163.—Finished filling.

celain plate over the flame, upon which the gold may be placed and heated as the operator proceeds with the filling. The best heater is the electric, for with this there is plenty of heat to perfectly dissipate the gaseous deposit placed there for the protection of the gold and prepare it for perfect cohesion, and there is no danger of the contamination of the gold by the products of imperfect combustion.

The first pellet having been placed is malleted to adaptation and the next built upon it.

There are several methods of condensing gold: the hand mallet in the hands of a trained assistant, the hand mallet used by the operator himself, the automatic plugger, the pneumatic engine and the electric mallets. Each one of these has its advocates, and operators trained in the use of the different mallets obtain splendid results with any of them; but the hand mallet in the hands of a trained assistant holds first place in the opinion of the authors. With it the amount and direction of force may be more easily and certainly adapted to the purpose of condensation than with any other. In case the student does not have an assistant he may choose the automatic plugger or use the hand mallet himself, if he trains himself thoroughly in the use of the mallet, which involves the use of the left hand in such an expert manner that he will, with it, perfectly obtain his line of force and the proper amount of hand-pressure.

The making of a gold filling means more than the mere adaptation of the gold to the walls of the cavity. That may be perfectly accomplished and still the filling may be a failure. If the gold has not been condensed to a degree that gives it a specific gravity of at least 14 it will contain so great a percentage of air spaces that it will be little more than a sponge and will not make an impermeable filling. It requires considerable force to obtain a high degree of specific gravity in malleted gold in a tooth. The specific gravity of gold is about 19.3 and a filling with a specific gravity of 18 will make a filling that is about as nearly perfect as the hand of man can make it, so far as density is concerned; but a filling with a specific gravity of 16 will make a very good filling and few operators attain that. The reason that so many gold fillings in the posterior teeth begin to pit and break down in a short time is because of the low density of the filling, caused by the failure to obtain sufficient mallet force in making the filling. Most of this is caused by a failure to use the proper methods of condensation or by improper use of those at hand. The reason we prefer to use the pellets that we make ourselves is because we desire to know just the amount of gold that is under our plugger point at a given time, for we know the amount of force that a given quantity of gold must receive in order to obtain a certain density. In order to obtain this definite density, definite methods should be used. With the hand mallet used with a force of ten pounds to the blow, augmented with a five-pound hand-pressure on a plugger point that has a diameter of 0.5 mm. x 0.75 mm., give 20 blows of the mallet to a sixty-fourth pellet, 40 to a thirty-second, 80 to a sixteenth and 160 to an eighth. This method will give the student and operator a definite method of obtaining a specific

gravity that is as nearly perfect as he will be able to obtain. There are always sources of error, of course. The thickness of the cushion of the peridental membrane will cause quite a serious error in density if it is great. For this reason it is very difficult to make a good hard gold filling for children. The force of the condensing blow is so greatly dissipated by the elastic cushion made by the thick peridental membrane that it is inadvisable to attempt large gold restorations for children.

Another source of error is the shape of the plugger. A long, thin curved shank on a plugger will take up a very large amount of the condensing force of the blow in the elastic spring of the curved shank. The plugger should be as nearly straight as it is possible to have it and yet not have the point out of the range of vision. The shank should not be long but as short as may be conveniently made. The pluggers adopted by Drs. Woodbury and Crandall are as nearly perfect as it is possible to obtain, and are the ones advised in this treatise. The size of the plugger point is also of great importance for the amount of force delivered at the plugger point is directly proportional to the force of the blow and inversely proportional to the square of the plugger point. It will thus be seen that an increase in the size of the plugger point rapidly decreases the condensing power of the mallet. Use as small a point as is consistent with good results. Too small a point chops the gold instead of condensing it and too large a point fails in power of condensation. The ideal point is one that is about 0.5 mm. x 0.75 mm.

Cohesion and condensation are important, but unless the gold is perfectly adapted to the walls of the cavity it will make no difference how dense or compact the filling may be; it will fail because it will leak. Perfect adaptation of the gold to the walls of the cavity is the first desideratum. The other things must follow in the making of a perfect filling.

The adaptation of the gold to the walls of the cavity is obtained by the right use of the plugger in flowing the gold toward the walls of the cavity. The first piece or two of gold having been started in the convenience point or angle the other pellets follow in sequence, and as they are placed the condensing force should be applied, beginning toward the center of the cavity and stepping the plugger in an orderly sequence toward the wall against which the gold is to be condensed. Each step of the plugger should be about the distance of 75 per cent. of the diameter of the plugger point so that the operator is shingling the gold, each blow partly overlapping the preceding one until the wall of the cavity is reached, and then the plugger should be lifted up, retraced toward the center of the cavity and again stepped toward the wall. In this way the gold is being continually forced toward the wall of the

cavity and the last blow upon the gold is that which wedges it tightly against the wall of the cavity. If the plugger started back from the wall toward the center of the cavity it would be found that the gold would be drawn away from the wall and a leaky place would be the result. In this way pellet should be added to pellet, laminating the gold back and forth, building up and forward until we come to the step of the cavity leading toward the gingival surface. It will be remembered that three cylinders of non-cohesive gold were placed in the gingival surface and then no more attention was paid to them; but the building of the cohesive gold in the distal portion of the occlusal step was commenced. The cohesive foil is built forward over the non-cohesive cylinders in the gingival seat, effectually locking them to place. The gold is built up to occlusal and proximate form, correctly contoured and the size and shape of the tooth restored as perfectly as possible.

When inserting the non-cohesive cylinders it must always be remembered to so place them, in any form of cavity, that the ends will be extending out of the cavity and not the sides. This rule having been adhered to in this case, we will find the ends of the cylinders tightly resting against the approximating tooth. With a long, fairly wide foot plugger the cylinders are malleted into the cavity by inserting the foot plugger between the approximating tooth and the gold and making strong condensation with the hand mallet. This drives the non-cohesive cylinders tightly into the cavity and firmly against all margins, and maintains a perfect adaptation at the gingival.

The use of the combination of non-cohesive and cohesive gold is only possible in that class of cavities that will enable the cohesive gold to be perfectly anchored in the tooth without the aid of the non-cohesive gold, for there will be no cohesion between the two kinds of gold. For instance, we use the non-cohesive foil in the gingival third of bicuspids and molars because the non-cohesive cylinders may be keyed into the cavity by condensing the cohesive foil over them and anchoring the cohesive foil in the step in the occlusal surface. That retention will be sufficient to retain the filling without the aid of the retention in the gingival third. Also, in the occlusal surfaces of the molars, when the non-cohesive foil is adapted to the walls of the cavity, the center may be wedged with the cohesive and it will maintain itself, even though there is no cohesion between the two kinds of gold.

In the case of a proximate cavity in an incisor it will be necessary to use the cohesive foil entirely, because the cavity will need all of the retention of the cohesive gold to maintain the filling. This is also true of all fourth-class cavities, for in these there will not be sufficient incisal anchorage to retain the filling if non-cohesive foil be used in

the gingival third. The rule is to use the non-cohesive foil in only those cavities in which sufficient anchorage may be obtained for the filling after the non-cohesive foil is in place.

Class III cavities are filled with cohesive foil, beginning the filling by placing a pellet, No. 32, in the linguo-gingival angle and slightly condensing it. At this point in the operation an assistant plugger is invalu-

FIG. 164.—Cavity ready for filllng.

able. This may simply be any other plugger that is used to hold the pellet of gold steadily in place, while the condensing force is being applied, or, better still, it may be in the form of a gold carrier that is used to pick up the pellet of gold, place it in the proper position and then hold it steadily during condensation. The use of the combined carrier and assistant plugger is a time-saver, in that the operation of picking up

FIG. 165.—Filling started in linguo-gingival angle and built over the gingival wall to the bucco-gingival angle.

FIG. 166.—Same process carried farther.

the gold, placing it in the cavity and holding it in place is accomplished with one instrument instead of two if pliers were used to carry the gold. A very useful assistant plugger may be made by shaping a piece of 16-gauge iridio-platinum wire, sharpening it to a point and using it in a good-sized broach carrier. The iridio-platinum will have the advantage over steel in that it will not contaminate the gold with any dele-

terious material. Other pellets are adapted to the first one, building the mass of gold into the angle and gradually condensing the gold across the gingival wall of the cavity. In placing each pellet the condensing force should be begun at the point nearest the center of the cavity and stepping the plugger toward the wall against which the gold is being condensed at that particular time. Never step the plugger

FIG. 167.—Build up the filling, being careful to keep the lingual portion in advance.

FIG. 168.—Mesial angle built in.

away from the walls toward the center. The last blow of the plugger should be at the extreme point of adaptation between the filling and the wall of the cavity, thus calking the filling by wedging the gold between that already condensed and the wall of the cavity. The assistant plugger should hold the gold firmly to place during this part of the condensation, for until the filling is built across the gingival seat and

FIG. 169.—Labial wall protected.

FIG. 170.—Finished filling.

firmly anchored in the labio-gingival angle, locking the gold in the gingival to place there is danger of displacing the filling and causing it to rock. If such an accident does occur, immediately remove the gold already placed and begin over, for it will be almost impossible to make an impervious filling after a portion has loosened from its anchorage.

When the filling is built up along the gingival wall and thoroughly locked to place the lingual wall of the cavity should be built up. The lingual wall should be perfectly protected before much gold is added to the body of the filling, for if this is not done there will be an insufficient mass of gold along the lingual margin and it will be very difficult to adapt it after the body of the filling is built up. Access to it from the labial aspect will have been destroyed and the method of condensing from the lingual surface will be found very difficult, if the filling is started from the labial. After the lingual wall is well built the body of the filling may be filled in, being very careful not to trap the labial wall of the cavity without a sufficient quantity of gold to fill it, for there again difficulty will be met in adapting the gold if there is no room to do so. When the filling approaches the cavo-surface angle of the cavity the gold should be lapped over the margin with a burnishing motion of the plugger. No condensing force should be applied until a sufficient mass of gold is in place to protect the enamel margin from the impact of the plugger. If this were not done and the sharp serrations of the plugger were driven through the thin mass of gold against the enamel margin there would be grave danger of checking the enamel. When the first pellet is burnished over the margin, condense up to the cavity wall and then place another pellet and burnish it over the first, repeating this operation several times, when a sufficient mass of gold will protect the margin to allow condensation. The walls of the cavity having been cared for, the filling should be contoured to form, the surface thoroughly condensed and it is ready for the finishing.

The pluggers used in the condensation of both the non-cohesive and the cohesive foils are the Woodbury-Crandall set of 26. This selection of pluggers is most admirable and the student will find all of the points necessary for any filling that he will be called upon to make. We can do no better in giving a description of the pluggers and their use than to use the words of the designers: Woodbury-Crandall gold pluggers are designed for use in conjunction with a hand mallet in the hands of an assistant. The forms are sufficient for any gold-foil operation, though special forms may be added as conveniences rather than necessities.

The set is made up of fourteen pluggers for cohesive gold numbered from 1 C to 14 C; nine pluggers for non-cohesive gold, numbered from 15 NC to 23 NC. Nos. 1 C and 2 C are for general work. No. 1 C is used for starting fillings, filling very small cavities, convenience points, etc.; No. 2 C for general open work in building up a filling after it has been started.

Nos. 3 C and 4 C are for building along parallel walls, driving the gold into sharp line angles and for general building. Their convex face

causes the gold to spread more freely than a flat face does, thus obtaining more fully the effect of the wedging principle. These instruments

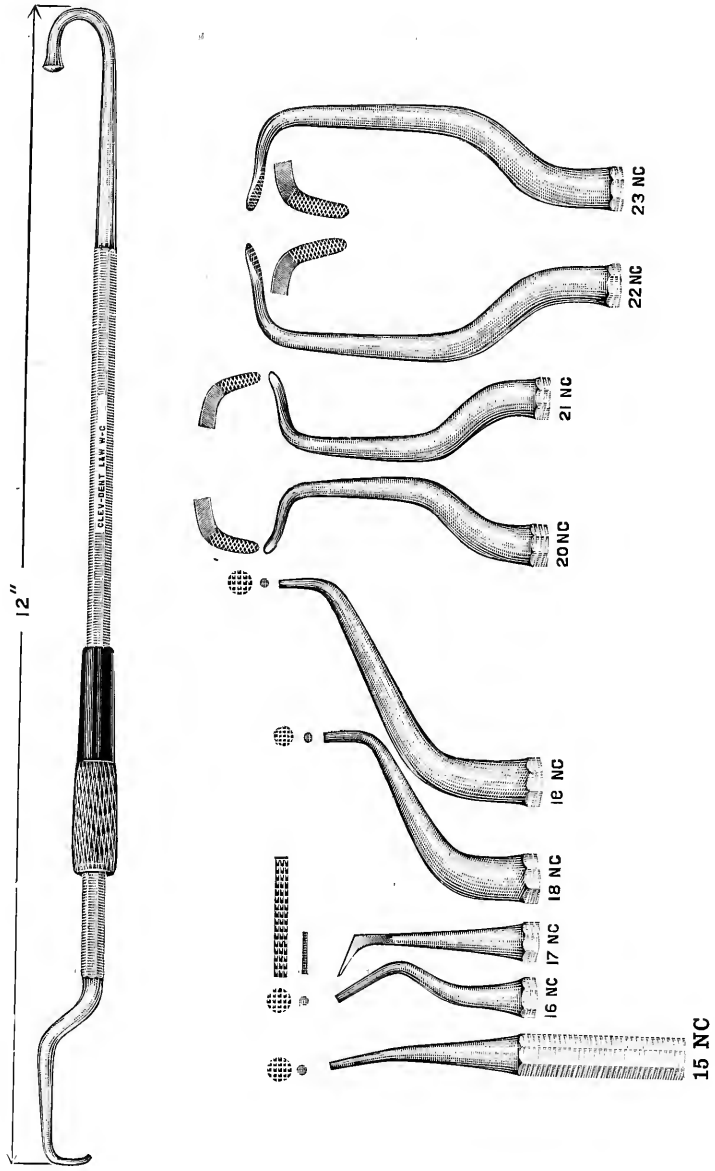

are also useful when approaching a margin, as their round face is not so likely to chip the enamel as a flat face.

Nos. 5 C and 6 C are for use in those locations that are not conven-

iently reached by Nos. 3 C and 4 C; their bends make them more convenient, but also more springy. They are best used as auxiliaries to Nos. 3 C and 4 C.

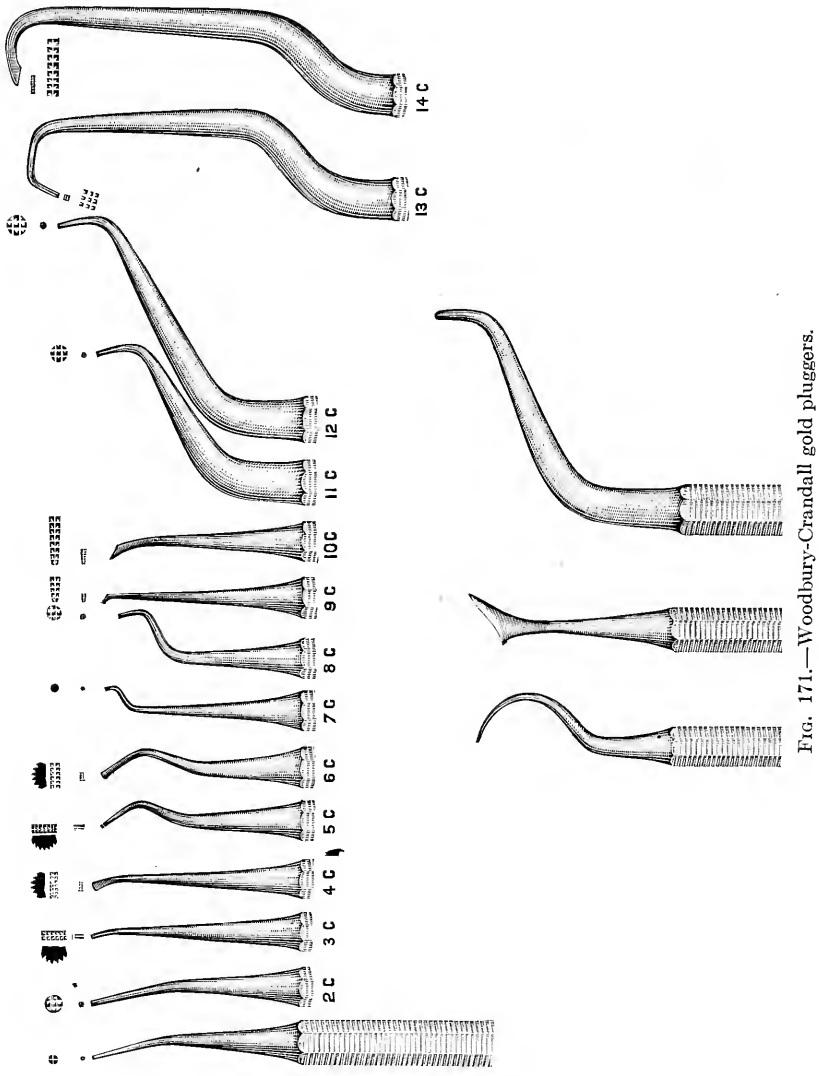

FIG. 171.—Woodbury-Crandall gold pluggers.

No. 7 C is especially designed for filling the retention form in the incisal angle and the labio-gingival angle of cavities in the proximate surfaces of anterior teeth.

No. 8 C is convenient for use in the distal and occlusal surfaces of bicuspids and molars.

The form of No. 9 C allows the flat end of the plugger to bear upon those places where it is necessary to incline the plugger to quite a degree to reach different parts of the cavity.

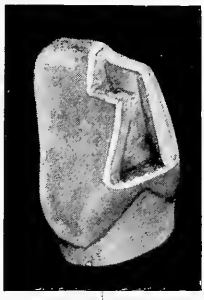

FIG. 172.—Fourth class cavity ready for filling.

FIG. 173.—Starting in gingival angles and building across gingival walls.

FIG. 174.—Continuing the building.

FIG. 175.—Progress.

FIG. 176.—Gold built up to incisal step. Now starting in pit in mesial surface.

No. 10 C is used to reach inaccessible places, condense over angles, smooth the surface of the gold, etc.

Nos. 11 C and 12 C are for use on the distal and occlusal surfaces of

bicuspids and molars, the long angles allowing almost any part of these surfaces to be reached with a correct line of force.

FIG. 177.—Built over incisal surface and anchored to body of filling.

FIG. 178.—Gold all built in.

FIG. 179.—Finished filling.

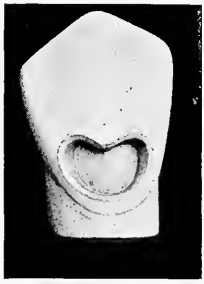

FIG. 180.—Class V cavity ready for filling.

FIG. 181.—Gold started in disto-gingival angles and built up to disto-mesial angle.

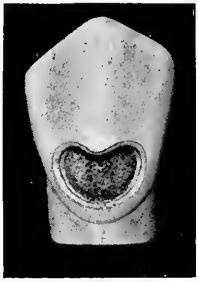

FIG. 182.—Gold built over floor of cavity.

Nos. 13 C and 14 C are back-action pluggers, intended for use only in locations that cannot be reached with a correct line of force with direct-action pluggers. These two instruments have twelve-inch handles, with hard-rubber grips.

Nos. 15 NC to 23 NC, for non-cohesive gold, should never be used for cohesive gold, as they have faces so large that cohesive gold cannot be condensed with them.

FIG. 183.—Process continued.

FIG. 184.—Building gold over cavo-surface angle, burnishing it over to obtain mass before malleting.

FIG. 185.—All cavo-surface angles protected.

FIG. 186.—Gold all built in.

FIG. 187.—Finished filling.

Nos. 15 NC and 16 NC are used to drive the non-cohesive cylinders against the gingival wall and into the axio-gingival line angle in cavities in the proximo-occlusal surfaces of bicuspids and molars.

No. 17 NC is used for driving the cylinder against the axial walls in cavities in occlusal surfaces.

Nos. 18 NC and 19NC are used for driving the cylinders farther into the cavity from the occlusal surface after the filling has otherwise been made.

Nos. 20 NC and 21 NC are for use in cavities in the proximo-occlusal surfaces, mesial aspect, for driving the cylinders in the interproximate space against the axial wall, after the filling has been otherwise completed.

Nos. 22 NC and 23 NC are back-action pluggers for use on distal surfaces in the same way that 20 NC and 21 NC are used on mesial surfaces. They have twelve-inch handles with hard-rubber grips.

FINISHING THE FILLING.

The filling should be finished with as perfect a polish as that which nature gives to the enamel of the tooth for the reason that food debris will not cling to a polished surface as well as to a rough or uneven one. All margins of the filling should be flush with the tooth surface so that an explorer will not catch between the tooth and filling when lightly passed over the surface. This is particularly true of the finish at the gingival margin, for here a rough or overhanging margin will be the cause of a considerable irritation to the gingival tissue with a resulting inflammation and a not infrequent pyorrhea. Many teeth have been lost by the careless placing of a filling with rough overhanging margins. Dr. Arthur Black and others have demonstrated that many cases of pyorrhea have had their inception in such faulty operations. It is therefore essential that the filling should be finished as perfectly as possible. The first point in the operation of finishing the filling is trimming to form. The contour of the tooth and the true anatomic form of the occlusal surface should be accurately reproduced. In order to do this, the student must possess the knowledge of tooth form, for without an accurate conception of the form of the tooth, he will not be able to reproduce it.

In finishing fillings placed in the occlusal surfaces of molars and bicuspids, the filling should be ground down to approximate occlusion with a suitable carborundum stone of the proper size. It should not be too large to be of service in bringing the surface of the filling to a relatively close approximation of the form desired, nor should it be so small that it will be likely to cut the surface of the filling and make it irregular. After the stone has brought about an approximation of the result desired, a round finishing bur is used to carve the surface of the tooth making therewith the sulcus and grooves thus making the surface of the filling correspond with the surface of the natural tooth. The skill and artistic ability of the operator can be given full play at

this point and results beautiful, as well as useful, will follow in the train of a well-executed finish. After the filling is trimmed to form and occlusion, as well as to anatomic correspondence, it should be well polished. This can be accomplished by the use of the rubber cups

FIG. 188.—G. V. Black's adjustable saw frame.

charged with wet pumice and rapidly revolved in the engine hand piece. If a high polish is desired the wet pumice may be followed by dry pumice, used with the same instrument to be followed by any of the tooth powders, also used dry. This will give a very high polish, but in

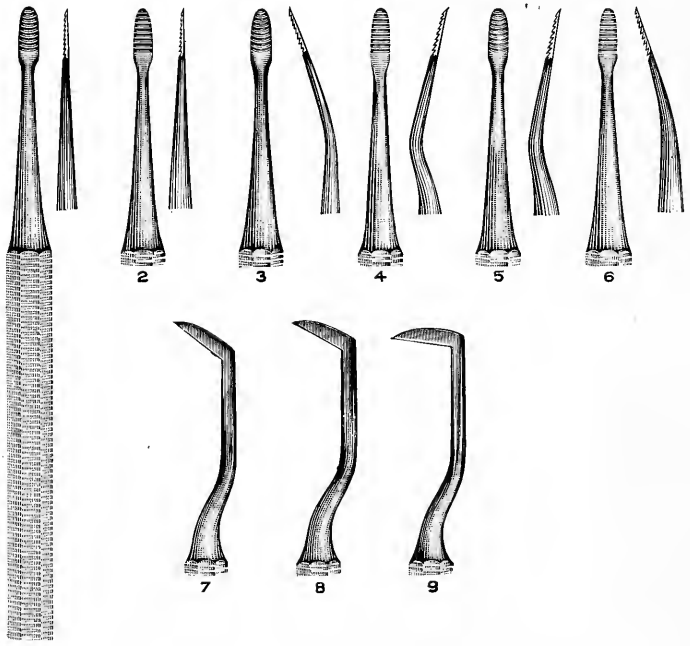

FIG. 189.—G. V. Black's finishing files and knives.

the opinion of the authors is contra-indicated in all fillings that come within the range of vision for a highly polished gold filling will so absorb the rays of light that it will look almost black. The best way to leave the filling is with the well smoothed surface that is obtained by the use

of the wet pumice, or a very fine sandpaper disk. This leaves a surface that does not look dark but on reflection of light shows in its true color.

In finishing a filling in the proximate surface of a molar or bicuspid the approximate form is reproduced by the use of a Black saw, knives and files. The Black saw is one of the most useful instruments ever devised for the finishing of the proximate surface of gold fillings. It is a heavy saw frame into which is inserted a Kaeber saw, which has been ground down upon its smooth edge until the saw is of thread form. The grinding of the saw is accomplished by inserting it in the saw frame and holding the back of the saw against a carborundum stone in the engine or lathe until the desired width has been secured. The entire back of the saw is ground down with the exception of the portions that engage with the saw frame, for if these were ground down the saw would not maintain itself in the frame when it was in use; therefore, the ends of the blade should be left as they come from the manufacturer.

In use the saw blade is inserted into the interproximate space, above the filling, with the teeth toward the occlusal surface. If there is not room to insert the saw, space can be made by cutting out a portion of the gold with a Black knife. These knives are illustrated in the Woodbury-Crandall set as Nos. 34 and 35. The saw is inserted and the frame attached to it as it is in its position between the teeth. This is necessary for the reason that we wish to cut the gold out of the interproximate space, but do not want to cut away any of the contact. Therefore, the saw must be inserted above the filling and the gold removed from the interproximate space by sawing from the gingival margin toward the occlusal surface. In this way the surplus gold can be easily and most expeditiously removed from the interproximate space with ease to the operator and comfort to the patient. The cutting with the saw must stop short of the contact, for to cut through that would be to ruin the form of the filling. When the gold is removed to the contact point the saw should be disengaged from the frame and drawn out of the interproximate space by pulling it out of the buccal embrasure. The contour form is finished by the use of the Black files, or those designed by Dr. J. M. Prime. With these files the form of the filling may be made to conform perfectly to the shape of the tooth, being careful to make all the lines of the filling slope toward the contact point, which should not be finished until the last. With the Black knives, careful search should be made for any overhang, and if any is discovered it should be removed and the gingival margin made perfectly flush and smooth. The occlusal form should be reproduced with stones and burs as in an ordinary occlusal surface filling, being

very careful to see that the marginal ridge is maintained. If the marginal ridge is not reproduced and the sulcus made so that the bolus in its excursion over the tooth in mastication is driven toward the middle of the tooth and out of the sides of the embrasure instead of toward the contact, there will be a very great probability of the food finding its way between the contacts and into the interproximate space, to the great detriment of the septal tissue and the inconvenience and pain of the patient. For this reason, the occlusal surface of the tooth should never be ground flat as has been the custom of many good operators in the past. Nature made the form of the tooth not only for the purpose of the mastication of the food, but also so shaped it that in the process of mastication that function could be normally accomplished without harm to the investing tissues.

If the separator is in position it should now be tightened a little, in order to obtain a little more space to finish the contact point. If it is not on, it should be placed and the desired space obtained. Very little finishing of the contact point is needed, for if the work thus far has been properly done the whole of the filling is finished to form, and as all of the lines of the filling slope toward the contact, that point will be but a point indeed, and all that will be required to finish it will be to obtain the requisite space and pass a polishing strip between the points and a few moments of the same will finish the operation. In the use of sandpaper disks for finishing the fillings in the posterior teeth the right angle mandrel is indispensable, for the proper angle of approach cannot be obtained by the use of the straight hand-piece. In the use of the right angle the operator will immediately see many of its advantages and will soon add places in which he will find the instrument of the greatest assistance. The interproximate portions of the filling may be polished with a fine strip, the rest of the filling disked and the whole polished with the rubber cup and wet pumice. When the separator has been removed and the teeth have resumed their normal relation the contacts should be so tight that a piece of floss silk will pass between them with a decided snap.

Fillings in the proximate surface of incisors are finished to form with files and knives, the gingival space polished with a sandpaper strip, and the labial and lingual portions disked with the aid of the right-angle mandrel, after which separation should be made and the contact polished with a fine strip.

In the use of the sandpaper strip it should be cut on one end to a narrow point, that it may be threaded in between the teeth into the interproximate space. Then, in the posterior teeth especially, it is caught in the end of a split instrument that engages the end of the strip, which when wound around the instrument is held fast and the operator

using the instrument in the mouth to hold the strip and managing the other end with his hand is enabled to use the strip with more ease and certainty.

The instrument may be made by taking an old excavator and cutting a slot in the end of it about 4 or 5 mm. deep and wide enough to accommodate a strip easily.

At no place in performing an operation does the finished product display the skill of the operator so much as in the form and finish of the filling. It therefore behooves every dentist to survey more critically his own handiwork in the light of the finished product, and strive more earnestly to make the finish of a gold filling perfect.

AMALGAM.

Amalgam is an alloy of any metal with mercury. In dentistry it may be an alloy of copper and mercury making the copper amalgam, or it may be an alloy of two or more metals with mercury, as in the silver tin alloys, which are in general use by the profession today. Copper amalgam has many points of superiority in that it will neither shrink nor expand, and, by reason of its great plasticity, is easily adapted to the walls of a cavity. It is used very sparingly in dentistry today because of the fact that it rapidly wears out of the cavity and also because of its black color. In the filling of deciduous teeth, however, it has a place that is entitled to respect, for here it usually maintains its integrity as long as it is wanted; also the antiseptic action of the copper salts makes it a very valuable aid in saving children's teeth when utility for a short space of time is paramount to appearance.

The silver tin alloys are the ones in general use, and the reader is referred to Chapter VII for a study of the physical characteristics, formulæ and methods of manufacture. This article will attempt to illustrate only the technic of the filling of teeth with amalgam, leaving all discussion concerning its properties to the author of the chapter on that subject.

The preparation of the cavity for the reception of a filling of amalgam is identical with that for a gold filling, except that the cavo-surface angle is made wider to allow a greater mass of amalgam at the edge of the filling, thus giving the filling greater edge strength. The reader is therefore referred to the article on the preparation of cavities for gold fillings by the authors of this treatise.

By reason of the color of amalgam, its use is not indicated in the anterior teeth and should be used rarely, if ever, anterior to the first molar. If the filling preserved its color at all times it would not be so objectionable, but old amalgam fillings invariably become much discolored,

making their use anywhere within the range of vision, a very doubtful practice. If the filling is well made and there is no infiltration of moisture between the filling and dentin there will be no discoloration of the tooth, but if there is a leakage, no matter how slight, there will be a discoloration of the dentin, owing to the formation of sulphids, and the penetration of the dentin by the resulting sulphids. This coloration may vary from a slight grayness near the margin of the filling to a dense blue-black of the entire tooth. A result of this kind is indicative of faulty manipulation of the amalgam under the plugger, hence the necessity for a care ul technic in condensing the filling.

In order to successfully fill a cavity with amalgam it is necessary to have four walls, for it cannot be perfectly condensed unless confined to the cavity while pressure is being made. All simple occlusal cavities have four walls and can therefore be filled without any complications, but cavities in the proximate surfaces of molars and bicuspids should



FIG. 190.—Copper matrix and cavity.

be supplied with the lost wall. This is accomplished by the use of a matrix of some sort. The matrix that is made for the particular case under consideration is advised.

Such a matrix is made by taking a piece of thin sheet copper, of 36 gauge, and cutting an oblong piece that will conform to the length of the tooth and be long enough to encircle the tooth to about two-thirds of its diameter. A small wing is turned up at each of the corners that are to be at the gingival portion of the tooth to be the recipient of the matrix, for the purpose of holding the ligature and preventing it from slipping off the matrix into the gum. The matrix is now adapted to the tooth and a piece of floss silk thrown around it, making a double turn of the silk. This is drawn tight, carefully watching to see that the matrix is being properly adapted to the tooth. Too much stress should not be applied to the silk or it will cause the matrix to be pushed into the cavity on the proximate aspect of the tooth. After the matrix is

ascertained to be in proper relation to the tooth and cavity, and it is seen that it properly restores the lost wall of the tooth, the ligature should be tied and the matrix held perfectly in place. If the matrix does not fit at the gingival margin it is advisable sometimes to adapt a small orange-wood wedge at the gingival margin to hold the matrix

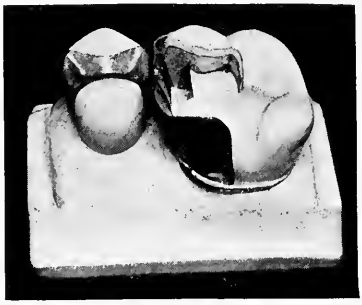

FIG. 191.—Matrix tied on.

firmly to place and prevent the amalgam being forced between the matrix and the tooth into the gum. If this happens, and it is not discovered and removed, it will cause a very sore tooth and the possible loss of the same by the severe inflammation which such an irritant may cause. The matrix should now be contoured from within the cavity with a small ball burnisher and the contact made by cutting a hole in the copper matrix with a No. 4 round bur. This will leave a hole at the con-



FIG. 192.—Matrix wedged at gingival.

tact point which will enable the operator to condense the amalgam at that point directly against the approximating tooth, preventing the displacement of the amalgam and making it possible to obtain a very tight contact. The cavity should be prepared, dam in place, matrix adapted and all things in readiness before the amalgam is mixed.

When making an amalgam filling the point of greatest interest is the choice of the alloy, for failure to use a good alloy will cause a failure of the filling. The operator may do some things perfectly, but no man can operate a faulty alloy in such a way that he can make a filling that will stand the stress of time and mastication. At the present time, happily, there is little need of making a faulty selection. Expansion and shrinkage of the filling is out of the hands of the operator and in the hands of the manufacturer, but the strength or weakness of the filling is largely an operative procedure. Too much mercury in the mix, so that a sloppy mass is the result, will make a weak filling, while too little mercury will also make a weak filling and one that has a tendency to be very brittle. Therefore, to make a strong filling it will be safer to have the proper amounts of alloy and mercury at each mix. This is accomplished by weighing the separate parts of the mix on a balance, first ascertaining the proportion of alloy and mercury to take for the particular alloy that is to be used. This can be done by experiment, finding the amount of mercury that will give the proper consistency to a definite amount of alloy. The amalgam that gives the best results is a mix that, when well kneaded, will leave the print of the fingers well outlined on the mass. When the proper amounts to produce this consistency have been obtained it is advisable to weigh out a number of such units of alloy and place them in ordinary gelatin capsules and set them aside until wanted. The same may be done with the mercury. The proper amount of mercury is weighed and placed in capsules; when a filling is to be made a capsule of alloy and one of mercury are taken and the mix made from them. If the proper amounts have been ascertained and carefully weighed out there will be approximately the right mixes every time without the care and thought whenever a filling is to be made.

The alloy and mercury are placed in a good-sized Wedgewood mortar and thoroughly triturated until a good amalgamation has been secured, when the mass is turned into the hand and kneaded thoroughly for some time until a perfectly homogeneous mix is obtained, which, as has been said, is evidenced by the fact that the resultant mass will reproduce the marks of the fingers upon its surface. There is one school of amalgam operators that teaches that the filling should be made from a mix that is so soft that it is sloppy in order to obtain a more perfect adaptation, while another school insists upon the use of a mix that is so stiff that it is almost impossible to get it into the cavity before it has set. Neither school is correct, for the sloppy mix, while seemingly easier to adapt to the walls of the cavity, in reality is not so, and the fact that such a mix is bound to make a filling that will be too weak to stand the stress of continued use would be enough to discredit it.

The too stiff mix is so difficult to manipulate that the majority of fillings made with it will be found of faulty adaptation. The better way is to choose the medium mix which will make possible a good adaptation and a strong permanent filling, if properly condensed. This mass should be broken into several fragments and is ready for the filling.[1]

The instruments that are used in condensing the amalgam are those selected by Dr. Crandall. We reproduce the illustrations and explanation of their use by their designer:

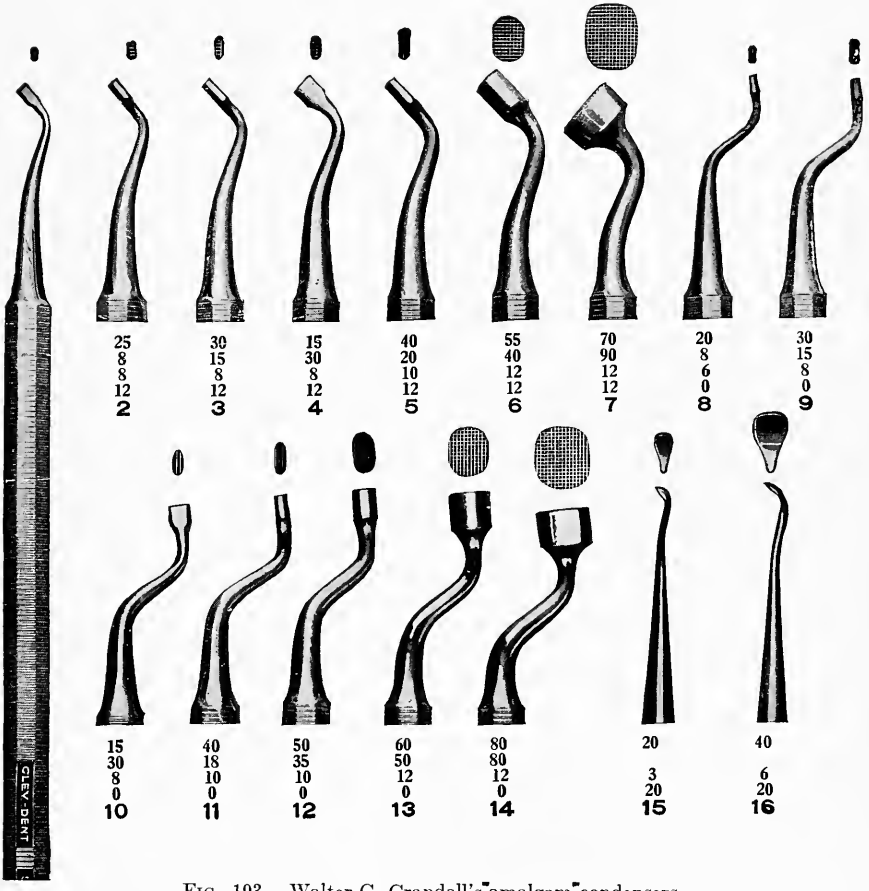

FIG. 193.—Walter G. Crandall's amalgam condensers.

These instruments have been designed to fit into the proximate and occlusal portions of such cavities as are usually made in bicuspids and molars for amalgam fillings. They have shortened shanks, bringing the working point of the instrument closer to the grasp that controls

[1] The reader is referred to the section on Amalgam, in Chapter VIII, for a further discussion of this subject.

it and affording great leverage and very accurate control. When used as pluggers to carry a mass of amalgam and to condense it under heavy hand pressure supplemented by mallet force, they will produce the greatest possible density and strength in the completed restoration.

Nos. 1 to 7 are for cavities in the lower teeth which are inaccessible with the bayonet-shaped instruments, Nos. 8 to 14.

Nos. 7 and 14 are especially valuable, as their size allows them to condense a mass of amalgam over all of the margins of the cavity simultaneously, thus avoiding the movement away from some portion of the margins which is always produced by the use of small pluggers.

Nos. 15 and 16 are amalgam formers, used for reducing the excess of amalgam to the cavity margins and for preliminary carving in the restoration of the natural tooth form.

A piece of amalgam about the diameter of the cavity is taken in the pliers and carried to the cavity, where it is pressed into place with the finger, and pressed firmly to the floor of the cavity by a plugger as large as the entrance will permit. Then a slightly smaller plugger is used to condense the amalgam against the walls, carrying the material from the center of the cavity toward the walls thereof, as is done in condensing a gold filling; then wedge the next piece in between the amalgam condensed against the walls, thus taking advantage of the wedging principle in forcing the material more tightly in its adaptation to the walls of the cavity. This should be continued until the cavity is full, when a piece of amalgam slightly larger than the orifice is placed on the filling and heavy pressure made with a large plugger, which may in some cases be advantageously augmented by the mallet. The filling is made more dense and strong in proportion to the pressure made upon the amalgam during the packing of the filling. Dr. Southwell, many years ago, demonstrated the fact that very few amalgam fillings were able to withstand a pound of air-pressure without leaking, because their adaptation to the walls of the cavity was so poor, and Dr. Crandall admits that the packing of an amalgam filling in order to make it impervious to moisture is a very difficult operation. It therefore behooves the student to study the technic of the packing and condensation of amalgam with the greatest care if he expects to make a success of its manipulation.

The amalgam should be allowed to set for several minutes until it has become fairly hard before the matrix is removed, and then care must be exercised not to break the filling in removing it. If a hole has been made in the copper at the point of contact, and the portion of the matrix extending gingivally above the surface of the filling has been cut before the matrix is applied, the matrix can usually be torn asunder after the amalgam has hardened, parting at the point where the hole

was made for the contact, when the two ends can be withdrawn easily from the buccal and lingual surfaces and the filling left undisturbed. If there is any danger of breaking the filling it is better to allow it to set until it has become perfectly hard, when it may be manipulated as desired.

The reason that it is desirable to remove the matrix before the amalgam has become perfectly hard is that it may be carved to form much more easily before it attains its hardness.

After the removal of the matrix the filling should be carved to contour with the Black knives and polished with a fine sand-paper strip, inserting the strip between the teeth gingivally to the contact point. This can be done more expeditiously if the strip is cut to a point and then threaded into the interproximate space, as advised in the finishing of a gold filling.

The occlusal surface of the filling should be made to resemble the natural tooth as closely as possible, and in this work the art of the operator can be beautifully demonstrated in the carving of the cusps and sulci. The carving of an amalgam filling is so easly done that the making of a flat occlusal surface on an amalgam filling is little short of malpractice. It is certainly indicative of gross carelessness.

When the filling is carved to form it is advisable to dismiss the patient and polish at a future sitting, when the filling should be disked to smoothness and polished to a mirror surface by the use of rubber cups and pumice, first used wet and then dry for the final polish. An amalgam filling so made will give the patient years of useful service and will, in a high degree, resist the deposits of food debris upon its surface due to the high polish which it will take and retain.

In many badly broken-down teeth that would usually require crowns the amalgam filling can be used to restore the tooth to usefulness better than a crown. In these cases the cavity is prepared with all the retention that is possible, cutting down the cusps and reinforcing them by carrying the metal over their surfaces and restoring them with the amalgam. Frequently in those cases where the pulp has been involved and the canals filled the pulp chamber can be utilized for retention and the foundation of the filling made in it. When the cavity is prepared a copper band is made to fit the case or a ready-made band is chosen and adapted to the tooth, carefully festooning the metal where it would otherwise impinge upon the gum. The band is contoured as well as the skill of the operator will permit, which can be done more easily if the band is slit gingivally from the contact, thus enabling the ligature to adapt it more closely to the tooth. The band will be allowed to remain upon the tooth for a day after the filling has been made.

The contact points should be made possible by cutting a hole in the

band at the proper point with a round bur and the cavity is ready for the filling. Sometimes it is difficult to adjust the dam before the band has been placed. If so it will be an easy matter to place it after the band is on the tooth, for it will take the form of the tooth and the rubber can be slipped over it.

FIG. 194.—Copper tube festooned, trimmed and prepared for mesio-occluso-distal cavity.

The amalgam can now be packed into the band using all the care that we would use in the packing of an ordinary filling. The occlusal surface should be carved to form while the amalgam is still plastic, but the remainder of the finishing would better be left until the following day. The band should be left in place until that time, for the attempt to

FIG. 195.—Matrix adjusted and tied.

remove it would be likely to break the filling and spoil the entire operation. When the case is seen the next day the band should be split with a sharp knife and removed and the filling dressed to shape with stones, disks and strips and polished to a mirror surface. This operation when completed will be of better service than that given

by a crown, for the gingival margin is smoother and less liable to irritation. In all operations, whether with amalgam or any other material, one of the objects of the greatest importance is to obtain a smooth and polished surface at the gingival margin, for the delicate septal tissue will not tolerate the slightest roughness. The beginnings of pyorrhea, as Drs. G. V. and Arthur Black and others have pointed out, lie in the rough gingival margins, due either to faulty dental operations or to the deposition of calcareous substances thereupon. If the cause is a faulty dental operation it is a stigma upon the operator and one that the student should teach himself to abhor.

In summing up, making an acceptable amalgam filling consists of a proper cavity preparation, choice of a good alloy, the proper manipulation of the alloy and mercury, adaptation of a well-made matrix, the condensation of the filling, the removal of the matrix and shaping of the filling and the polishing of the filling.

GUTTA-PERCHA AND THE CEMENTS.

Gutta-percha is a very valuable temporary filling, but is not used with any idea of permanency. It is used principally as a sealing for the various medicaments used in the treatment of teeth and as a stopping in cavities after the wax pattern is made for an inlay, and the patient has been dismissed for a future sitting. It is also very useful in making separations where the teeth have fallen together by reason of extensive decay, and it is necessary to separate them for a time in order to produce sufficient space to restore properly the mesio-distal diameter of the tooth. It may also be used as a temporary filling in any case that may be desirable, but not with any thought of permanency.

The cavity preparation for gutta-percha is the same as for any of the plastics; therefore it will not be necessary to go into that subject in this treatise.

In filling the cavity with gutta-percha it is necessary to have the cavity dry, for the material will not adhere to a wet surface. It is well to moisten the cavity with the oil of eucalyptus or oil of cajuput prior to the introduction of the filling, for these oils have the power of dissolving gutta-percha and making it adhere to the surface of the tooth. The gutta-percha should never be softened in the flame, for to do so will endanger its structure by overheating and consequent disintegration. If too high a degree of heat is used it will catch fire and burn. The best way to soften it is to place small pieces of the material on a heating tray for gold, such as the mica that is used over an alcohol lamp to heat gold or if the Custer gold annealer is at hand it may be

used conveniently by placing a piece of porcelain or glass upon it and allowing the electricity to heat the porcelain to a moderate degree, when



FIG. 196.—Rivet plastic instruments.

the heat is turned off and the gutta-percha placed on the porcelain. It will remain warm sufficiently long to make the filling, keeping the gutta-percha plastic, the very best possible condition for use.

A suitable set of instruments for the introduction of the gutta-percha and cements is one here illustrated. The set should consist of smooth end pluggers of slightly curved and bent angle shape in order to make convenient the placing of the material in any cavity no matter where situated; also, an assortment of smooth blades of slightly curved form for the trimming of the material in the proximate surfaces.

Gutta-percha should be inserted in the cavity in small pieces and adapted to the walls in the same way as an amalgam filling, that is, the material should be forced from the center of the cavity toward the walls thereof and the following pieces inserted in the space in the center made by condensing the material toward the walls of the cavity, this procedure to be followed until the cavity is full. The filling may be trimmed to form with the warm instrument, for to attempt to cut the gutta-percha with a cold instrument will pull the material away from the walls of the cavity and make a very ragged surface. After the filling is trimmed to form it may be further smoothed by taking a firm piece of cotton pellet and washing the surface of the gutta-percha with eucalyptus or cajuput.

In placing gutta-percha over dressings in the tooth it is necessary to use a great deal of care not to make pressure upon the medicament that is used, for if over a pulp, pressure will cause a great deal of pain, and if over a dressing placed in the pulp cavity in the treatment of root canals the pressure may cause a portion of the medicine to be forced through the apical foramen, causing intense irritation and pain. This may be obviated by the careful manipulation of the material. A small piece should first be used and placed over the medicine saturated cotton and lightly packed to place with a warm instrument that has been moistened with eucalyptus. After this piece has been allowed to harden more of the material may be introduced, but care should be used all through the operation not to use too much pressure.

Gutta-percha is invaluable for making a temporary filling in a cavity that has been prepared for an inlay until a convenient time may be obtained for the setting of the same. In such cases the filling should be made with as much care as if it were to endure for a longer period for if the gutta-percha is carelessly jammed into the tooth and up into the interproximate space it will crowd out the septal tissue and may cause considerable pain as well as a great deal of damage.

Gutta-percha is of great value in those cases in which the gum tissue has crowded into a cavity in a tooth that has had the decay progress below the gum and has caused such a gingival irritation that the

gum has hypertrophied to such an extent that it partly or entirely fills the cavity. In many cases it is possible to cut out the tissue; but some cases do not call for that treatment, when a gutta-percha plug may be inserted and the patient instructed to call again the next day. If the tissue has been displaced to the extent desired a temporary filling of the gutta-percha may be inserted, care being used not to impinge upon the septal tissue and the patient dismissed until a time desirable for finishing the operation. If the tissue is not sufficiently displaced crowd in a little more gutta-percha until the gum is entirely clear of the cavity and then it may be filled as usual.

In the separation of teeth which have fallen together by reason of decay the material may be crowded into the cavity between the teeth, leaving it a little overfull, so that the patient will bite upon the filling. In doing this a constant pressure will be made against the two teeth and will crowd them apart. This plug may be worn for a few days and then replaced with a new one that is again a little more than full; this treatment should be repeated until the proper amount of space has been obtained.

CEMENTS.

The cements used in dentistry are the oxyphosphates of zinc and copper and the silicates. The student is referred to Chapter VII for a description of the chemical and physical characteristics. The present article will only comprehend the use of cements in dentistry.

Practically the only use of cements for the filling of teeth is of a temporary nature, for the permanent cement is still to be found. The silicates are more nearly permanent, but the silicate that will stand the test of permanency is yet to be brought to the attention of the profession. It is a great mistake that will undoubtedly reflect upon the reputation of the practitioner to tell a patient that any cement is permanent.

It may be good practice to use the silicates, for their esthetic effect is good and many patients prefer it to the unsightly effect of gold; but it is always advisable to warn the patient that the filling may have to be remade from time to time, depending upon the condition of the fluids of the mouth of the patient under consideration. If the patient, with this understanding, chooses to have the silicate used, well and good, but a patient should never be told that any cement filling is as nearly permanent as some other materials.

The preparation of the cavity for a cement filling is the same as for any other filling except that the cavo-surface angle demands a different treatment, owing to the slight edge strength possessed by the cements.

The cavo-surface angle should be without bevel and should always follow the long axis of the enamel rods, so that there will be no short rods upon the surface of the cavity, and there will be no sharp angle to make a thin portion of cement at the edge of the filling, for to do so will be to cause the edge to break away and leave a vulnerable point for the beginning of a recurrent decay.

For a filling of any kind, the silicates are usually to be preferred, as they are less soluble, are harder, decidedly more harmonious in color and will make a more lasting filling than one made of any of the zinc cements; therefore, in the description of the filling of teeth with cement the silicates are understood.

The filling must be made under the most exacting conditions of dryness, for the slightest amount of moisture before the cement has set is inimical to good work and the lasting quality of the material. The rubber dam should therefore always be placed upon the tooth before the operation and the cavity dried thoroughly. It is nearly always advisable to use a matrix of some kind. A matrix made of celluloid is preferred, as it imparts a smooth, polished surface to the filling and does not endanger the color by imparting any deleterious product to the cement during its manipulation as a metal matrix might. The slightest foreign substance incorporated with the cement will endanger its integrity and will be likely to cause a discoloration of the filling.

If the filling is to be made in the proximate surface of an incisor a strip of thin celluloid is inserted between the surfaces of the teeth on the side opposite the one that is to be filled, and then one end brought around the lingual surface of the tooth and carried over the cavity. To illustrate: if a cavity presents in the distal surface of an upper left central incisor one end of the celluloid strip should be inserted between the two central incisors and the other end carried over the lingual surface of the left central up between the central and lateral, thus making the strip act as a matrix for the cavity in the distal surface of the left central. The matrix can be manipulated with the fingers to suit the operator and form the cement under the celluloid matrix.

If the filling is to be in a proximate surface of any of the posterior teeth the celluloid can be used just as with the copper matrix for an amalgam filling, only using the celluloid instead of the copper.

The cement should be mixed upon a slab made by using the surface of a large flat bottle. This bottle is to be filled with water at a temperature of about 60° F., for a cement mixed at that temperature will give the best results. In case the day is too hot and humid such a procedure may not be best, as the cool bottle in such an atmosphere will have moisture condense upon its surface and the result be worse than using a slab at room temperature. Therefore, the temperature

and humidity of the atmosphere must be taken into consideration.[1] The silicates are so sensitive that weather conditions may either make or mar an operation. A portion of the powder should be placed on one end of the slab and a portion of the liquid at the other. A small portion of the powder should be incorporated in the liquid and mixed thoroughly with an agate spatula. One made of any of the metals will be likely to discolor the filling by the abrasion of its surface and the incorporation of the abraded particles into the mass of the filling. A spatula of tantalum, however, may be used, for it is of such hard consistency that it will suffer little abrasion and will not discolor the cement.

The mix should be of a soft putty consistency and should be thoroughly spatulated until the mass of powder is perfectly incorporated in the liquid.

The instruments that are used for the insertion of the silicate should be not of steel but of ivory, tortoise shell or tantalum. The tantalum instruments are preferred as they are stiffer and can be made of more convenient shapes and can be used with more force than the others. The cement should be placed in the cavity as quickly as possible and shaped to form before crystallization begins, and should not be disturbed after it begins to set, for if it is the forming crystals will be broken up and the best results not obtained.

After the cement has hardened it may be trimmed to form after which it should be allowed to set under the protection of the rubber dam for at least fifteen minutes, when it may be coated with the varnish furnished by the manufacturers or by a varnish made by the solution of white rosin in ether. The rubber dam may then be removed and the patient dismissed.

The silicates may be used in the form of a crown for the restoration of badly broken-down teeth by the use of the Caulk's tooth forms. These are hollow celluloid forms of the teeth, and are so made that when the proper form is selected it may be filled with the enamel in the proper shades to suit the case, making the gingival portion a little yellow, the central portion of the color of the approximating teeth and, if called for, shading the incisal with a little blue to simulate the enamel that is without a dentin background, as is the case in long thin incisors. In making these mixes at the same time it will be necessary to have an assistant make one mix while the operator makes the other.

The form filled with the suitable silicate is pressed down upon the prepared tooth and allowed to harden. It should be kept dry for fifteen or twenty minutes and then the patient dismissed with the celluloid form in position, with instructions to call the following day to have it

[1] The reader is referred to Chapter VII for a further discussion of this subject.

removed and the crown polished, if necessary. If the work has been done carefully there will be very little polishing necessary, for the polished surface of the celluloid form will give a high polish to the enamel crown.

In the same manner, broken bridge facings may be repaired with the same material. In this case the forms are not entire crowns, but merely the facings, which may be selected for the case and filled with the suitable material and pressed to place over the pins in the backing of the broken facing. When the cement has hardened the form is removed, the facing coated with varnish and the patient dismissed. In these and many other ways that will suggest themselves to the ingenious dentist the silicates fill a large place in the practice of a busy man and serve the patient very well indeed. But to reiterate, a restoration of any kind made with a cement is not permanent if the cement is exposed to the fluids of the mouth and the friction of mastication.

The oxyphosphates are valuable for all kinds of temporary work, the sealing in of medicaments in root treatment, the treatment of children's teeth and the setting of inlays, crowns and bridges.

The inlay regime has brought the cements into use more than ever before, and protected by a perfectly fitting inlay, this makes about as near the ideal restoration of broken-down tooth tissues as modern science has yet attained.

For an inlay it is necessary to mix the cement a little thinner than for a filling, for if the mix is made too stiff the inlay will not go to place. The mix should be of a heavy cream consistency about as stiff as will drop from the spatula when held up from the slab. It should be placed in a dry cavity, but the modern hydraulic cements of the oxyphosphate type do not need to be kept dry after the inlay is seated. The fact is the makers say that it is necessary to have the addition of moisture to perfect the setting. (See Chapter VII.)

For the setting of crowns and bridges the oxyphosphates are also used and are found the best medium for that purpose, for their tenacity is such that they add somewhat to the retention of the crown. It will be found necessary to make the mix for crowns and bridges thinner than for fillings, but a little stiffer than that used for the setting of the inlay.

THE MANAGEMENT OF CHILDREN'S TEETH.

The first point in the management of the teeth of children should be the instruction of the parents in the importance of the temporary or deciduous teeth, for very few of them realize, in any degree, the necessity for maintaining the deciduous teeth in any sort of health. The frequent expression, "Oh! they are only first teeth and he will

soon lose them," is indicative of the carelessness with which the average parent views the ravages of decay in relation to the first, deciduous teeth. Therefore it should be the business of the dentist to institute a campaign of education among the parents of children to instruct them in the importance of the deciduous teeth in relation to the comfort, health and development of the child. From the manner in which many dentists dismiss the subject, it is evident that they also need a little enlightenment upon the subject, or at least should have their conscience awakened by being taught the baneful effects upon the growing child of a mouth full of diseased teeth.

In this day, when we are taught that many of the ills of the human family are directly traceable to foci of infection in and about the teeth, we should not overlook the fact that an abscess at the root of a deciduous tooth harbors the same organisms that make the one on a permanent tooth dangerous. If these organisms are dangerous to the adult they are in even a larger degree dangerous to the child. Not only so, but the fact that the teeth in decaying cause irritated pulps with consequent pulpitis and all forms of toothache, which are as painful to the child as to the adult, should make every lover of children do all in his power to avert the needless suffering that is thus caused. That suffering by reason of toothache is the cause of much of the ill-health of childhood is an undoubted fact, for the nervous system of children is easily upset and the reflex action caused by a severe and long-continued attack of toothache will frequently so disturb the nerve balance of the child that a severe illness and possible fatal result may ensue.

The decay of the teeth causes an inability to eat properly, and the child, with a mouth full of decayed teeth, either refuses food or bolts it whole or very imperfectly masticates it. Food thus entering the stomach of the child is not fit for digestion and the child suffers from all of the ills that follow in the train of digestive disturbances. Not only so, but the constant swallowing of the millions upon millions of bacteria and their toxins, that are holding high carnival upon the substance of the teeth, is not conducive to the health and development of the child. Many an adult today is suffering from digestive disturbances and faulty food habits that are the result of neglected conditions in the deciduous teeth.

Cavities in the teeth are ideal culture mediums for all sorts of pathogenic organisms, and the child who has overcome an attack of diphtheria, scarlet fever or any other infectious disease becomes a carrier of that disease by harboring the organism in the cavities of the teeth, and then expelling them in the saliva, in expectorating, coughing or sneezing, to the detriment of all of the other children in the vicinity.

One of the strongest arguments for the compulsory examination and care of the teeth of children is this fact. The child with decayed and diseased teeth is not only a menace to himself, but also to every child with whom he comes in contact. It may not make very much difference to us how much the children of the poor may suffer, but when we realize the truth that they will not and do not suffer alone, but pass on the germs of their misery to your child and mine, it makes us think.

The future generation will never be what it could be until the teeth of the children of this generation are kept from the ravages of decay, and the sooner the public realizes this truth the sooner will the world enter upon a real foundation of the prevention of disease.

The first thing, then, in the treatment of children's teeth is prophylaxis, the prevention of disease. The child should be under the care of the dentist as soon as the first teeth erupt, and sometimes it is necessary to see them before the emergence of the teeth from the gums, for if the teeth do not erupt easily the disturbances to the nervous system of the child may be very serious, even to the point of bringing on convulsions. If the gums are inflamed and tender and the child irritable and cross, with every indication of painful dentition, it will be good practice to lance the dense gum tissue over the erupting tooth or teeth and assist nature in bringing the tooth to the surface. In doing this a very sharp lancet should be used and the cut made in accordance with the needs of the case. If it is an incisor a straight cut following the incisal edge of the tooth will be all that is necessary. If a molar it will be wise to make a cross-cut, one from the disto-lingual angle and one from the disto-buccal angle, diagonally across the gum where the tooth is to emerge. These two incisions will cross each other at about the point of the center of the tooth and continue to the opposite angle from whence they started.

It is usually only necessary to lance one or two teeth at a time, for there are not more than four erupting at any one time, and there are not many cases in which all are gum-bound. The relief given to the child is usually almost immediate and the reflex symptoms rapidly abate.

When the teeth have been erupted they should be kept clean and the mother and nurse should be instructed in the importance of so doing. The cleansing of the teeth with a soft cloth will do for the first few months, but as soon as possible the child should be accustomed to the proper use of the brush. Simply sweeping the brush over the labial and buccal surfaces of the teeth will do little good and may do much harm, for it gives a false sense of security to the patient. A small brush should be obtained, and following the system of Dr. Charters, of Des Moines, Iowa, the bristles at the heel of the brush should be cut off

with a sharp knife, leaving a tuft of bristles at the end. In use the brush should be placed at right angles to the teeth and the bristles inserted between them, so that they enter the interproximate spaces, and then the brush should be rotated in such a manner that the bristles may scrub the approximating surfaces of the teeth, just the places where the bacterial plaques first attach themselves. If these surfaces are kept clean there will be no possibility of the bacteria forming the destructive plaque, and the teeth will not decay. After the teeth have been thus treated from the labial surface the brush should be inserted in the embrasures from the lingual surface and the method of cleansing the proximate surfaces of the teeth followed from within the arch. This method cleanses the portions of the teeth that need it, and in addition to that the friction of the brush upon the septal tissue makes it firm, resistant and healthy. Tooth pastes and mouth washes are not essential, but a bland paste of pleasant taste and a normal salt mouth wash are all that are necessary.[1] The child should be encouraged to rinse the mouth forcibly after each meal, this to be done by holding the lips together with the fingers and then forcing the wash between the teeth with so much force that it would be sprayed out of the mouth were not the lips held tightly together with the fingers. A pleasant and efficient mouth wash may be made at home by taking one teaspoonful of salt, one of bicarbonate of soda and ten drops of the oil of cassia to the pint of water; this to be brought to a boil and then bottled for future use. This wash is pleasant to the taste and the children usually like to use it. Also, it makes them think they are using something more than water, so the psychology of its use is good.

The children should be brought to the dentist at least every six months after the eruption of the teeth for a cleansing and any reparative work that may be necessary. If this is faithfully carried out there will be little danger of dental complications in childhood. In cleaning the teeth a soft piece of wood should be shaped to a point and charged with the flour of pumice. With this every surface of the teeth should be thoroughly polished, all the time making play of it. Life to a child is one big game and the dentist who can enter into the spirit of play with them and make the operation a game will have little difficulty in the management of children.

Incipient decay in the pits and fissures of the teeth may be treated with nitrate of silver. The Howe ammonium solution is of splendid service. The silver solution should be infiltrated into the defective places in the teeth after having dried the tooth and protected the mouth with a cotton roll or napkin.

[1] The reader is referred to Chapter III for a further discussion of this subject.

After the silver solution has had a chance to soak into the fissure, reduce the silver with eugenol. This will cause a deposit of metallic silver within the defect and will not only sterilize the cavity but will infiltrate the decayed process with metallic silver and protect it from a recurrence of decay for some time at least. The process of using the silver solution and reducing with eugenol should be repeated several times to make the deposit as heavy as possible. In case the decay has progressed so far that an appreciable cavity is in evidence the enamel margins should be cut away as much as necessary and as much of the decay removed as can be without pain to the patient. It is desirable to cause as little pain to the patient as consistent with the preservation of the teeth. This is particularly true of the first few times they are operated upon. After the confidence of the child is won he will bear a great deal if he is told honestly that it will hurt some. Never deceive a child, for if his confidence is once destroyed it will be impossible to do much with him. After removing as much decay as possible, sterilize that remaining with the silver solution and fill with one of the cements, gutta-percha or copper amalgam.

Cement in children's teeth is very valuable, in that the operator is enabled to introduce it into a cavity which would not retain a metal filling. By reason of its adhesiveness it will maintain itself in a shallow cavity for a considerable time, and is a very valuable material with which to temporize in the treatment of children. It is much better to make a cement filling that will have to be made over in a few months, and not hurt the child, than to make a permanent filling and destroy the confidence of the child in dentists forever.

The engine should be used very sparingly indeed in the treatment of children's teeth for several reasons: (1) because of the dread children have for the instrument, and (2) because the use of a bur in the deciduous teeth is dangerous in that the pulp is very close to the surface, and a little injudicious cutting with a bur is likely to penetrate the pulp chamber causing intense pain to the child and the loss of the pulp. The cavity preparation should be nearly all made with hand instruments, and inasmuch as we are not expecting the fillings to endure for a long time, sufficient retention can be obtained for all practicable purposes.

Gutta-percha is also a valuable material to use in children's teeth, but should not be used in proximo-occlusal cavities, for the nature of the material is such that it will jam into the interproximate space under mastication and cause annoyance and pain. In occlusal cavities or proximate cavities which do not involve the occlusal surface its use is good practice.

One of the best materials for use in children's teeth is copper amalgam. It is black in color, but in the posterior teeth of children that is

of little importance. Its antiseptic qualities and the fact that it does not shrink make it most valuable in filling such teeth. The fact that it wears out in time is an objection to its use in the permanent teeth, but it lasts long enough to be of great service in the deciduous teeth. Its physical characteristics are also in its favor, for its plasticity enables the operator to place it in the child's tooth quickly and efficiently.

In making a proximate filling the contact point should be maintained as well as in a filling for an adult, for the same reason. The packing of fibrous food into the interproximate space is as much of an irritant to the child as it is to an adult, and the same measures should be instituted to prevent it.

Unfortunately the dentist does not have control of all, nor indeed of many of his little patients, and the first time that he sees most of them is when they are brought to the office suffering with a toothache, and in many cases frightened almost to convulsions with fear of the dentist. In such cases it requires the greatest tact and patience to accomplish anything for the little sufferers. The only thing that should be done is to attempt to relieve the pain. In case it is a pulpitis this may be done by washing out the debris as gently as possible and avoiding the use of instruments except those absolutely required. The food debris may be washed out with a warm solution, flavored with a little oil of cassia, which will attract the attention of the child if he is told that it is candy water, and he will usually learn to like it and even to ask for it. If it is necessary to remove some of the decay, do it carefully so as not to cause the slightest pain, and then flow into the cavity a thin solution of zinc oxid in eugenol. Over this drop a thin portion of an oxyphosphate cement, tamp it gently to place with a moist piece of cotton and dismiss the patient. The next time be as gentle as possible, all the time gaining the confidence of the little man or woman and in a short time he will allow the dentist to work at will with him. In cases of pulpitis that respond to treatment it may not be necessary to extirpate the pulp. If the hyperemia subsides, remove as much of the decay as possible without exposing the pulp, then thoroughly infiltrate with the silver eugenol solution and make a cement filling, carefully watching the patient for symptoms of a dying pulp. It is much better to preserve the pulp if possible, but on the first symptom of its death the tooth should be opened and the pulp removed.

The extirpation of the pulp in the teeth of children is a difficult and trying operation. Arsenic should not be used at all in deciduous teeth. If the pulp must be devitalized, it can be accomplished by the repeated application of phenol, ammonia or formocresol in cases of a putrescent odor. In the removal of the pulp and the filling of the canal the same

asepsis should be observed as in the treatment of the adult teeth, for the child is susceptible to the same organisms and may suffer the same general diseases due to focal infections. If possible to place the dam it should be done. But the difficulty of doing so with a child in the treatment of deciduous teeth is realized. If not possible, much can be accomplished with cotton rolls and the saliva ejector, the assistant helping with both.

Howe's silver solution is invaluable in the treatment of the root canals. The solution should be introduced into the pulp chamber and allowed to penetrate the canals by capillary attraction. Much instrumentation should be avoided, for if the solution is forced past the apical foramen it will cause an irritation that will be difficult to relieve. If not forced through by instrumentation there is little danger, however. In the teeth of children it is advisable to reduce the silver with eugenol rather than use the formic acid method, because of its non-irritating property. This method seals the tubuli and sterilizes them at the same time, after which the canals can be filled. The filling is accomplished with Buckley's euca-percha, followed by a cone that has had the end clipped off so that it will not penetrate the foramen; the pulp chamber is filled with gutta-percha and the cavity finished with a cement. Later on the cavity may be filled with amalgam if desirable. All deciduous teeth that have had the pulp removed and the root canals filled should be watched from time to time to see that no marked destruction has taken place and that the coming tooth in the permanent set is erupting properly, for in many cases the roots of the deciduous teeth will not be absorbed and the permanent teeth will not come into their proper places in the arch as a consequence. If either happens extract the deciduous tooth. It is advisable for the development of the arch to retain the deciduous teeth as long as nature intended, but if infection or irregularity is likely to occur as a consequence of the retention of a pulpless tooth it is the part of wisdom to choose the lesser of the evils and extract the offending tooth. Abscesses on deciduous teeth are an indication that such teeth should invariably be removed. It is not wise to take the chance of a possible systemic infection with a child.

GOLD INLAY.

The preparation of a cavity for the reception of a gold inlay does not differ materially from that for a gold filling. The only difference is that a cavity for a gold filling may be made so that it offers some internal retention in the way of undercuts, which are obviously contra-indicated in making a cavity for a gold inlay, for if an undercut were made, the wax pattern would not draw and, if it did, the inlay would

not go to place when completed. Fundamentally, however, the principles of making a cavity for a gold inlay are the same as for a gold filling. Therefore, it will not be necessary to discuss the preliminary observations on cavity preparation, as they have been given in the article on gold fillings, to which the reader is referred. The same sequence of operation and cavity classification will be followed in this article.

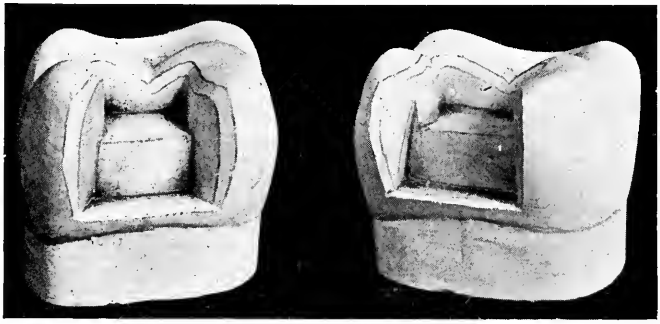

a *b*

FIG. 197.—Mesio-occlusal cavity in the upper first molar: *a*, for gold inlay; *b*, for gold foil.

The principles governing the construction of a gold inlay are comprehended in the preparation of the cavity; making the model or pattern; investing and burning out the pattern; casting; and cementing and finishing.

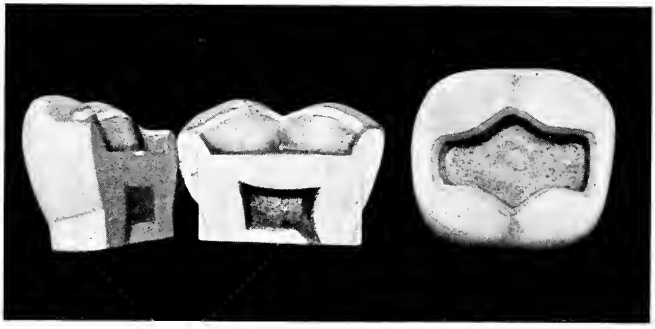

FIG. 198.—Preparation of a cavity in the occlusal surface of a lower molar, and cross-section thereof, showing the flat pulpal wall, the parallel axial walls and the bevel of the cavo-surface angle.

Cavity Preparation.—Class I cavities are prepared with flat seats and parallel walls. These cavities are those occurring in the occlusal surfaces of molars and bicuspids and the buccal pits of molars and lingual pits of the incisors. The buccal and lingual walls are cut out

with a cross-cut fissure bur, No. 702, and the pulpal wall made flat with the same instrument.

The preparation of the cavo-surface angle is a little different from that of a cavity for a gold filling, for the bevel is a little longer. This is done for the reason that it makes a longer flange upon the inlay and for

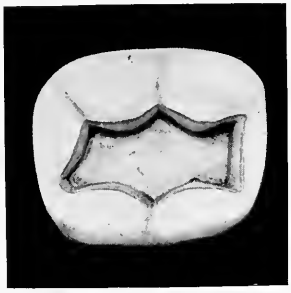

FIG. 199.—Occlusal cavity in lower first molar.

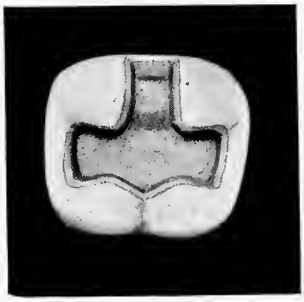

FIG. 200.—Occlusal cavity with extension in buccal groove in lower second molar.

the additional reason that a short bevel on the inlay would not have as great edge strength as a malleted filling, as the gold in the filling is harder than the gold in an inlay. The bevel for the inlay should be nearly, if not quite, the depth of the enamel and should make an angle with the wall of the cavity of about 90 degrees.

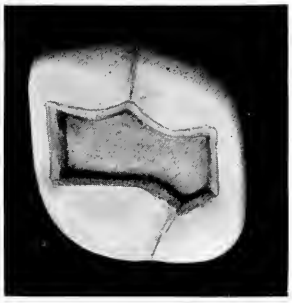

FIG. 201.—Occlusal cavity in upper first molar.

FIG. 202.—Occlusal cavity with extension in disto-lingual groove in upper second molar.

There is practically no difference in the preparation of Class II cavities from that for the gold filling. The steps are made flat, the walls parallel and the cavo-surface angle is beveled all around. The emphasis should be placed upon making the walls parallel, for the retention of an inlay depends a great deal upon frictional resistance. Dependence cannot be placed upon any internal retention, for that

would militate against the making of an inlay, and in proportion as we depart from the paralleling of the walls and make the cavity cone-shaped, with the base at the occlusal and the walls converging pulpally, we lose the frictional resistance of the walls of the cavity, and the

FIG. 203.—Mesio-occlusal upper first bicuspid.

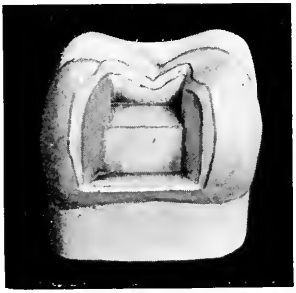

FIG. 204.—Mesio-occlusal upper first molar extending to oblique ridge.

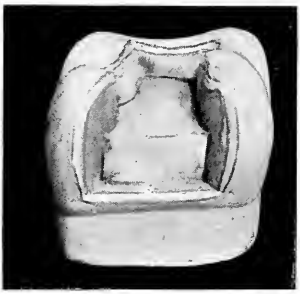

FIG. 205.—Mesio-occlusal upper first molar involving distal pit.

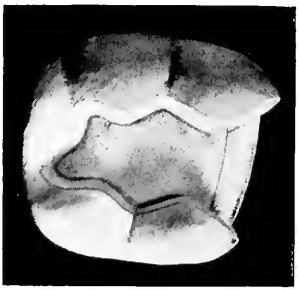

FIG. 206.—Mesio-occlusal lower first molar.

retentive form thereof. Retention is secured by the paralleling of the walls plus depth of cavity. If the cavity is not of sufficient depth, there will not be enough wall to make resistance even though it be made parallel. The cavity should never be less than the thickness of the enamel, and usually considerably more, depending entirely upon

the amount of stress the finished inlay will have to resist. All inlays and fillings should be anchored in the dentin and never in the enamel. If there is little or no occlusion it will be necessary only to clear the enamel and anchor in the dentin, but if the stress is great, the cavity should be cut proportionately deeper.



a *b* *c*

FIG. 207.—Mesio-occluso-distal cavity in upper first bicuspid: *a*, mesial view; *b*, occlusal view; *c*, distal view.

Mesio-occluso-distal cavities in molars and bicuspids, while following the general principles outlined, may have the mesial and distal walls converge slightly, as in this class of cavities there is sufficient frictional resistance offered by the great amount of wall space to afford plenty of retention and the converging walls make the obtaining of the pattern and the placing of the inlay a much easier matter.

FIG. 208.—Mesio-occluso-distal cavity in upper first bicuspid with buccal cusp cut away for protection.

FIG. 209.—Mesio-occluso-distal cavity in upper first bicuspid, both cusps cut away for protection.

If there is a weakness of the buccal or lingual walls it is advisable to cut off a portion of the cusps and build the inlay over them in order to prevent the fracture of either wall under stress. The inlay lends itself beautifully to this class of operative procedures and many teeth that

formerly would have been crowned are now restored by the inlay. In some instances, where much of the dentin is gone and the pulp has been removed, the inlay is anchored in the pulp chamber and a subpulpal seat made for retention.

FIG. 210.—Mesio-occluso-distal cavity in lower second molar with buccal cusp cut away for protection.



FIG. 211.—Mesio-occluso-distal cavity in lower first molar with lingual cusps cut away for protection.

Class III cavities are approached from the lingual surface and the preparation differs considerably from that for the gold filling. With a fissure bur, No. 702, entrance is gained into the cavity from the lingual surface and the axial wall made flat, cutting to a depth that will leave a small amount of dentin between the cavity and the labial wall of enamel.

FIG. 212.—Mesio-occluso-distal cavity in upper first molar with disto-lingual cusp cut away.

The labial cavity outline need not be very great if the decay does not demand it. The enamel on the labial surface should be cut only far enough to cause the inlay to clear the approximating tooth, thus making for a clean margin and satisfying the law of extension for prevention. This is done for the purpose of hiding the gold as much as possible and also allowing a seat for the inlay, which in this class of cases is against the labial wall. The gingival and incisal walls

should be made to slope slightly away from each other, the gingival one sloping apically and the incisal one incisally, thus causing them to diverge as they approach the axial wall. This will make a dovetail in the preparation that will prevent any lateral displacement and will allow the inlay to be inserted from the lingual and from no other direction. The cavo-surface angle should be beveled all around, but it is obvious that there can be no real bevel made upon the labial margin or the wax would not draw. Fortunately, we find that the lay of the enamel rods in this position is such that a straight cut through the tooth from labial to lingual will leave no short rods upon the surface, for the natural curve of the tooth is such that as the rods bend over in conformity to the shape of the tooth they are cut in such a way that all rods reaching the surface are those that have their base in contact

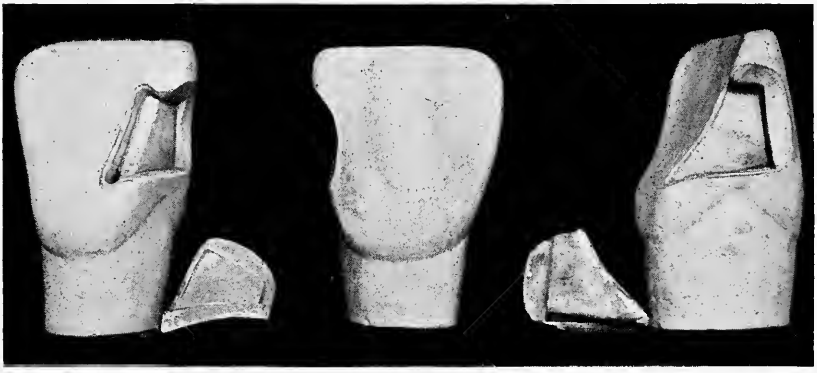

a *b* *c*

FIG. 213.—*a*. cavity for inlay in upper central incisor, lingual aspect; *b*, same cavity, labial view; *c*, same cavity, proximate view.

with the dentin. Therefore a straight cut through from lingual to labial is to all intents and purposes a bevel and a flange will be cast upon the inlay to perfect contact with the enamel. The approaching of the cavity from the lingual surface in the upper incisors affords additional security in that the stress of occlusion comes from the lingual surface as the lower teeth impinge upon the upper from that direction, which serves to pound the inlay into the cavity, and there is little danger of its displacement. In the lower incisors this is not true. Nevertheless, we approach the cavity from the lingual, for the labial approach is of such bad esthetic form that it is absolutely contra-indicated. If the incisal angle is not involved there is little danger of the incisal stress displacing an inlay in a lower incisor that is made from the lingual, for there is really no stress that reaches the inlay; but if the incisal angle is involved it will be necessary to obtain additional

retention by making an incisal step cavity and a sufficiently deep incisal anchorage.

In Class IV cavities we again depart considerably from the conventional gold-foil preparation on account of the difference in retentive problems.

There are two methods of obtaining retention in this class of cavities: one, the incisal step and the other the lingual dovetail cavity.

In making the incisal step cavity a portion of the incisal surface of the tooth is ground down with a carborundum stone, as for a gold foil operation, and the outline form obtained on the labial surface in the same manner; but the outline form on the lingual surface is different from that used in the foil preparation by reason of the fact that the

FIG. 214

FIG. 215

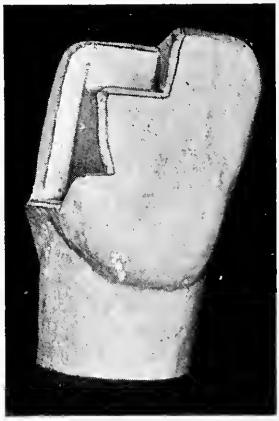

FIG. 216

FIGS. 214, 215 and 216.—Mesio-incisal cavity in upper central: Fig. 214, labial view; Fig. 215, incisal view; Fig. 216, lingual view.

internal preparation demands a treatment that makes the outline form on the lingual surface of different shape. The form of an incisor or cuspid is wedge-shaped or conical; therefore, the treatment of the lingual and labial walls takes on the laws governing conic sections. We know that parallel lines must leave the cone at some point and the farther apart are the lines the sooner will they leave the cone in their progress toward the apex thereof. We cannot make the internal preparation of the cavity in such a way that there will be any undercuts or retention that will not permit the wax to draw, therefore the walls are made para'lel, as far as the shape of the tooth will permit. But as the lines must leave the tooth at some place we choose to make the walls parallel at the labial contour of the tooth, as then the labial line does not leave the tooth at all but travels along

the long axis of the tooth until it reaches the incisal angle. Therefore, the wall along the lingual aspect will of necessity leave the tooth sooner than it otherwise would, and it does so at about the beginning of the middle third of the tooth. This method of preparation is chosen for esthetic reasons, for if the line at the labial were allowed to leave the tooth at any portion thereof it would make a very unsightly appearance in the labial outline form. Inasmuch as the wall at the lingual leaves the tooth at the middle third there is very little retention due to the parallel walls, and it is necessary to obtain some additional retention. This is done by cutting a pit in the pulpal wall of the preparation after the cavity passes the lines of pulpal recession, for to cut a pit at the line of recession would endanger the pulp. The cavo-surface angle is beveled all around as in any other cavity.

FIG. 217

FIG. 218

FIGS. 217 and 218.—Mesio-incisal cavity in upper central incision. Fig. 217, lingual view. Fig. 218, labial view.

The lingual dovetail preparation is made by approaching the cavity from the lingual surface as in a simple Class III cavity, but as the incisal angle has been destroyed by the progress of decay, additional retention is necessary. This is obtained in the lingual dovetail preparation by making the cavity as nearly retentive as possible, following the method of the simple Class III preparation and then cutting an additional dovetail in the lingual surface of the tooth. The stress of mastication on an upper incisor tends to drive the inlay farther into the cavity rather than out of it, and this makes this preparation of particular value. It is necessary to be very careful not to expose the pulp in the preparation of the lingual dovetail, as there is danger of doing if the cavity at this point is made too deep. It is only necessary to cut the dovetail through

the enamel and anchor well into the dentin. If this is done there is no danger of pulpal complications. If it is thought necessary to make a deeper preparation for the lingual dovetail by reason of extreme stress

Fig. 219

Fig. 220

Figs. 219 and 220.—Disto-incisal cavity in upper cuspid. Fig. 219, labial view. Fig. 220, lingual view showing lingual dovetail.

or abnormal occlusion in the region opposite the proximate surface in which the cavity is located, sink the dovetail deeper into the dentin. This will give a preparation that will make a thinner mass of gold as

Fig. 221

Fig. 222

Figs. 221 and 222.—Mesio-inciso-distal cavity in upper central incisor.

it passes over the pulpal area, but will be deeper and heavier and sink farther into the dentin when in safe territory. The cavo-surface angle is beveled all around this cavity as well, observing the rule on the labial

surface that obtains in the preparation of the cavo-surface angle in Class III cavities.

This preparation provides a restoration that is much more esthetic than the incisal step cavity, and one that is fully as likely to maintain itself against the stress of mastication and wear.

The same rules apply to cavities in the lower incisors and cuspids, but owing to their diminutive size the preparation is more difficult and calls for a larger degree of patience and skill to accomplish the desired result.

Class V cavities occurring in the gingival thirds of any of the teeth are treated much the same as like cavities in the gold-filling series. The outline forms and the axial walls are the same, the only difference being in the preparation of the mesial, distal, gingival and occlusal walls. These will not admit of any undercuts and must be made as nearly parallel as the skill of the operator will permit. The departure from the parallel walls will proportionately make for a lack of retention, and while there is practically no stress that falls upon inlays in this position, it is a fact that if there is not sufficient retention these inlays will fall out. The saucer preparation is decidedly contra-indicated in making a gold inlay. The cavo-surface angle is beveled all around the cavity.

Making the Pattern.—Any good wax that is hard at mouth temperature and perfectly disappears under the amount of heat to which it is thought desirable to submit the investment may be used. It is preferable to use one that is hard at mouth temperature, as all of the steps of making the pattern, investing, etc., should be carried out at the same temperature, and if a wax were used that was so soft that it required a dash of cold water to harden it, it would shrink so much that a good pattern would not be obtained. Heat expands and cold contracts; therefore if the pattern is to be a perfect reproduction of the cavity it must be handled at as nearly the same temperature throughout the operation as it is possible to do.

The wax may be warmed in any way that is convenient but should not be melted in the warming. If softened over a flame it should be held high enough above the heat so that it softens slowly and should be constantly turned and watched to see that it does not melt. After a little trial the color of the wax will be the index to the eye of the operator of the degree of softness.

The wax may also be softened in warm water of about 130° F. A convenient way to do this is to obtain a large flat cork and thrust a number of pins through the cork. Upon these pins, portions of the wax may be impaled and the cork then inverted in a glass of water of the proper temperature. In a short time the wax will be of the right consistency to use. Dr. Taggart has invented a very valuable instrument which is designed to keep the wax at the proper temperature.

The wax should be drawn to an elongated cone, the apex of which is slightly softened a little more than the rest of the wax by holding it for a moment over a flame: this for the purpose of making a softer portion of wax to be inserted into the cavity and the harder part to act as a piston to force the wax into every part of the cavity. Pressure should



FIG. 223.—Taggart automatic heater for casting wax.

be made upon the wax from every direction and maintained until the wax is hard. This pressure is obtained by using the index finger and thumb of the left hand on the lingual and buccal sides of the tooth if a molar or bicuspid, and on the lingual and labial if an incisor or cuspid. This forms a matrix into which the wax is forced by the pressure of the

index finger or thumb of the right hand as it presses the wax into the cavity. This pressure is necessary as the wax shrinks in hardening and as the pressure is maintained more wax is forced into the cavity to take the place of the shrunken portions, thus obviating a discrepancy and a more nearly perfect reproduction of the cavity is obtained. After the wax has hardened it may be carved to form. It is not advisable to allow the patient to bite into the wax to obtain the occlusion, for the wax has now hardened and biting into it will disturb the adaptation. The pattern should be carved to occlusion and anatomic form. The patient may try the occlusion very easily from time to time if thought desirable, but the skillful operator will not need much of that, for he will know his dental anatomy so well that if there is no abnormal occlusion he will have very little difficulty in carving to form and occlusion. If there is an abnormality of occlusion, or if for any other reason the operator desires to obtain the direct occlusion of the opposing teeth, he may do so by warming slightly the occlusal surface of the wax with a warm ball burnisher or the hot-air syringe, then allowing the patient to bite into the warm wax. The body of the wax being hard and the surface soft there will be no danger of the distortion of the pattern. One of the best instruments to use in carving the proximate surface of the pattern, and especially that portion near the gingival margin, is a large sickle-shaped exploring instrument, the fine prong of which can be inserted into the interproximate space and the wax carved out at will. It is also convenient in obtaining the adaptation at the gingival below the free margin of the gum and cutting off any overhanging wax. The occlusal surface should be carved to anatomic form, being careful to restore the marginal ridge. The inlay lends itself beautifully to the artistic reproduction of all of the markings of the tooth, and an impression taken of the tooth after the inlay is in place should look as though it were the perfect tooth instead of a restoration thereof.

When the carving is finished the whole pattern should be washed with the oil of cajuput, which will smooth the surface by slightly dissolving a film of the wax.

In removing the model a sprue wire of the proper size may be warmed and allowed to melt its way into the pattern and kept there until it is perfectly cool and the wax around it has hardened, when the pattern may be lifted out of the cavity very easily. Or if a curved explorer be used the point should be inserted into the inlay about where the contact should be and the pattern carefully lifted out. Force should never be used in dislodging the pattern, for to do so will endanger the perfection of the impression. A slight distortion will spoil the entire operation.

If the model has been made for a proximo-occlusal cavity it is wise to take a shaving of the wax where it comes in contact with the occlusal

step. In the preparations it will be noticed that there are no shelves in the cavity on which the inlay may ride, and all of the lines of the preparation flow into the cavity, so that if the inlay did not reach the gingival portion of the cavity through some slight shrinkage of the wax or gold it would sink down into the cavity until it rested on the gingival seat if it were not for the occlusal step. Therefore, the relieving of the wax at that point will allow any descrepancy at the gingival to be corrected by the inlay seating a little deeper into the cavity, thereby making a perfect adaptation at all of the margins.

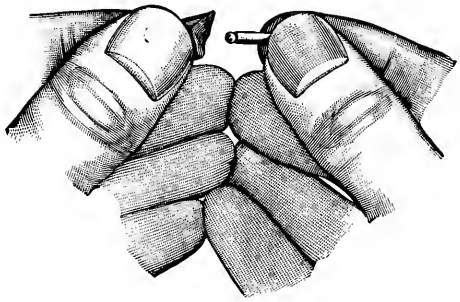

FIG. 224.—Position of hands while inserting warmed sprue into wax pattern after it has been removed on an explorer.

The pattern should be invested as soon as removed from the tooth to prevent any movement of the wax through any change of temperature that it might encounter in lying around the office waiting for the investment. The pattern should be washed with a soft camel's hair brush, using peroxide of hydrogen, alcohol or soap and water—to remove any oily or muciferous materials from its surface so that the investing material will more easily adapt itself to the wax. The water in which the investing compound is mixed should be the same temperature as that used to cool the wax while carving to avoid a change in the volume of the wax.

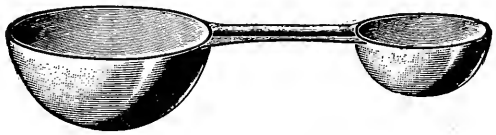

FIG. 225.—Taggart measuring device for investing material and water; large end for investing material, small end for water.

Any good investing compound may be used, or the operator may make one himself that is very satisfactory by taking 3 parts by measure of finely pulverized silex to 1 part of plaster of Paris. This should be

thoroughly mixed together. It may be mixed by taking an ordinary flour-sifter, such as housekeepers use in making bread, and sifting the mix through this three or four times, when a homogeneous mass will

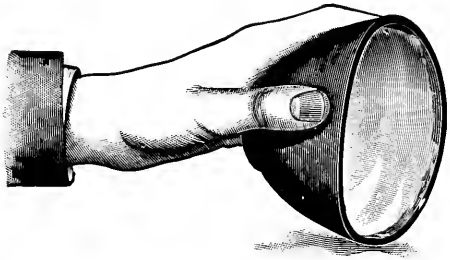

FIG. 226.—Position of plaster bowl while it is being revolved and jolted on the bench.



FIG. 227.—Taggart automatic mixing device for investing material and water.

be obtained. A balance or some kind of measuring device should always be used so that the proper proportions of the investing material and water may be used each time. The mix should be thoroughly

spatulated and then the bowl turned around and around, at the same time jolting it on the bench to cause the bubbles in the mix to rise to



FIG. 228.—Automatic mixer for investing material and water attached to ordinary laboratory lathe. (Suggested by Taggart.)



FIG. 229.—Taggart's crucible former with sprue inserted into the wax and into crucible former ready for investing.



FIG. 230.—Inlay covered with investing material previous to placing ring on crucible former.



FIG. 231.—Casting ring filled with hardened investing material, and crucible former and sprue removed.

the surface and break, thus obviating, to a great extent, the danger of bubbles upon the pattern, with a consequent ball of gold cast on the inlay where the bubble appeared on the pattern (Figs. 226, 227 and 228). The pattern on its sprue is placed in a crucible former supplied with the casting machine used and the investing compound is painted upon the surface (Figs. 229, 230 and 231). Great care should be used to see that the investing compound is evenly and thoroughly adapted to every surface and inequality of the pattern, repeatedly blowing the investment off of the pattern and repainting, to be sure there are no air bubbles adhering to its surface. The flask should be inverted, placed on a piece of paper and filled with the compound, and the pattern as it is painted with the investing material should be slowly inserted into the mass, all the time vibrating the pattern as it sinks into the investment, to clear it of any air that might attach to its surface. The investment should be allowed to harden, but not remain too long before the burning out is begun.

THE BURNING OUT OF THE PATTERN.

One of the most important parts of the entire operation is that of burning out the wax. It is necessary to dissipate the pattern in order to make the mold for the reception of the gold, but too great a degree of heat will disintegrate the plaster and cause a distortion of the finished inlay. More misfits are caused by the injudicious use of heat in the burning out of the wax than any other cause. A flame should never touch the investing material or flask and the temperature should never rise above 320° F. When the wax is dissipated, allow the flasks to cool perfectly and cast cold (Fig. 232).

In casting gold into a mold as small as one must be in order to make an inlay for a human tooth it is necessary to use some force in order to cause the metal to flow into the mold. It is also necessary to resort to some method in making the model that is a departure from the usual method of making molds, that is, the method of using separable flasks and making the mold in these flasks, then separating the flask and removing the model, then replace the separate parts of the flask in immediate contact and cast. In the case of an article as small as the inlay, and one that requires the exactness of duplication, the separable flask is out of the question; therefore use is made of the principle of the disappearing model. The model should be made of a material that would disappear under the influence of heat and then into the mold so made the melted metal is forced. There are a number of devices for casting the inlay. The first to be considered is the Taggart machine (Fig. 233). This is automatic in action and consists of a stand for the

reception of a nitrous oxid gas cylinder, which is used for the purpose of making the oxyhydrogen flame to be used in melting the gold and also for the purpose of making pressure with which to force the gold into the mold. On the same base is located the receptacle for the flask containing the mold. This seat for the flask is immediately under a movable disk which is actuated by a lever which forces it down upon the flask, completely closing it. When the lever closes, the flask also automatically throws the blowpipe away from the crucible contained



FIG. 232.—Taggart automatic gas apparatus for burning out the wax.[1]

in the upper part of the flask in which the gold is melted, and releases the gas from the cylinder, which by its pressure immediately forces the molten gold into the flask, thereby filling the mold with gold and completing the operation of casting.

The advantage of the Taggart machine is its automatic action, and having all the operations of casting, such as the blowpipe, release of

[1] Several electric devices have been designed for burning out the wax, but none seem to have been developed to a greater accuracy than the gas device.

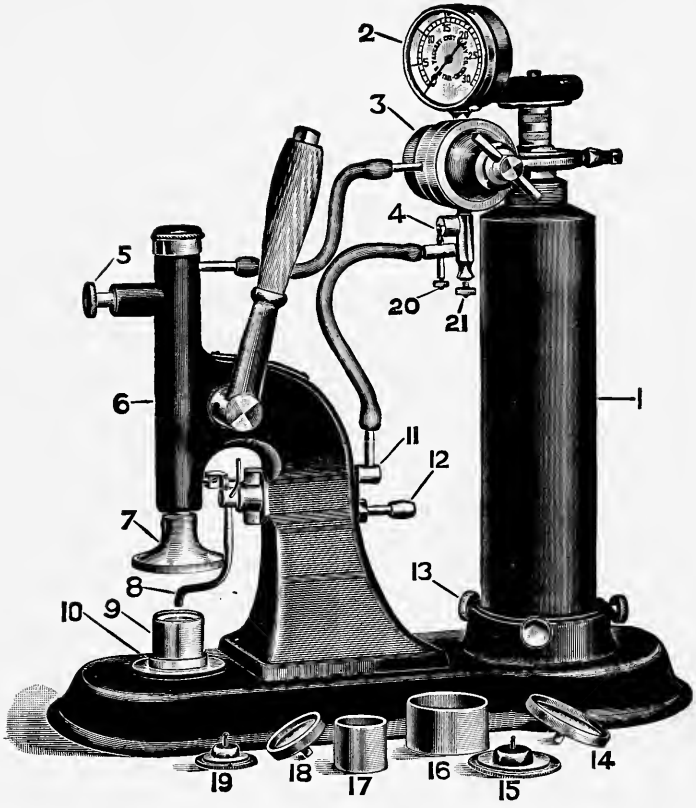

FIG. 233.—Taggart casting appliance.

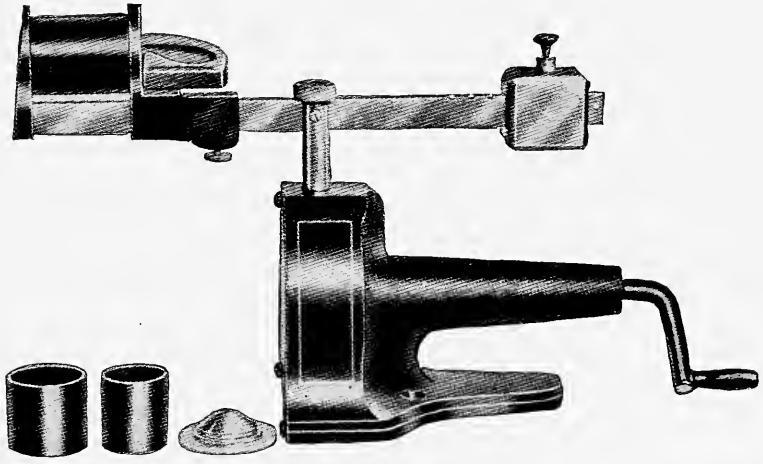

FIG. 234.—Monson's centrifugal casting machine.

the pressure principle, etc., in the same machine, the art of casting is quite simple. Besides, it enables the operator to retain pressure upon the casting as long as necessary, a very essential part of the casting principle.

Another very effective method is the centrifugal one (Fig. 234). This method takes advantage of the force that causes all matter to fly off at a tangent when revolved. The machine consists of an arm that revolves around a central base of some kind; the arm is actuated by a spring or geared wheel, which on being turned rapidly causes the arm to revolve. At the end of the arm is placed a receptacle for the flask. The gold may be melted in a crucible in the top of the flask, as in some machines, or it may be melted in a crucible placed in front of the orifice of the flask. In either case, when the gold is melted and the machine actuated, as the flask begins to revolve the gold is thrown into the flask and held there by centrifugal force. This method of casting is very popular and beautiful results are obtained by its use. Its advantages are simplicity of operation, possibility of retaining pressure, and in the machines that have a crucible away from the flask itself, the possibility of melting the gold without heating the flask or investment—a very desirable feature.

The suction method is an adaptation of the air-pressure principle, but instead of using direct pressure, atmospheric pressure is used, by exhausting the air in the flask and thereby causing the pressure of the atmosphere to force the gold into the mold. The machine consists of a vacuum chamber, from which the air is exhausted by an air pump, a table upon which the flask rests, which is connected to the vacuum chamber by a pipe to which is attached an air valve, which releases the vacuum when desired. The flask must rest upon the vacuum table with a contact that is perfectly air tight, or the vacuum will not be communicated to the flask but will be dissipated by the entrance of air through the leak between the table and flask. This method is popular with some operators and good results are obtained with it, but it is not so convenient nor simple as either of the other methods.

There are several crude methods that are used with home-made machines, using the principle of steam and mechanical pressure. The steam-pressure method consists of heating the gold in a crucible in the flask and when melted forcing a wet asbestos pad on the flask, which seals it, and, by the action of the heat contained in the melted gold, produces steam which forces the gold into the mold. This method is very uncertain and the same amount of pressure is never obtained at two consecutive castings, owing to the difference of heat and the amount of moisture contained on the pad. At best it is an unreliable method. The mechanical pressure method consists of making a pad of

molding, and upon the gold being melted the pad is forced into the crucible, when it seals the top of the flask and then by reason of its softness is forced deeper into the crucible and the gold is forced into the mold. This method is the least desirable of any and should not be used, if possible to make use of any other.

When it is said to cast cold it is meant to cast cold and not to heat up the flask to a red heat in making the cast, as is the habit of some. The flask should be so cool after the cast is made that it can be picked up immediately in the fingers. In order to accomplish this a blowpipe must be used and the small flame directed upon the gold nugget and not allowed to touch any part of the flask or investment compound. If a centrifugal machine is used the gold can be fused in a crucible away from the flask in some machines, and when melted the spring is released and the molten gold thrown into the cold flask. Pressure should be maintained for at least one minute in order to force additional gold into the mold as the fused gold takes on the solid state. Experiments conducted by Dr. Weston A. Price have appeared to demonstrate that up to a certain point additional gold will flow into the freezing mass, thereby reducing shrinkage to the minimum. The breaking away of the sprue from the inlay and the pitting of the inlay at or near the insertion of the sprue wire are sure indications that pressure has not been maintained sufficiently long to allow the compensation of additional fused gold to the freezing mass.

The inlay should be allowed to cool slowly before the flask is opened. When cold remove the inlay, wash and pickle in hydrofluoric acid, boil in hydrochloric acid or heat and drop into a 50 per cent. solution of sulphuric acid, and the inlay is ready for finishing.

FINISHING THE INLAY.

The inlay should be partially finished before it is tried in the cavity. If the model or pattern has been well made there will be little finishing to be done, as the casting will be like the pattern. The sprue should be cut off and the sanded finish smoothed with a disk; then it should be placed in the cavity and malleted to place. If it does not go to place perfectly it should be removed and search made for any bubble or fault in the investment that might militate against its perfect adaptation to the walls of the cavity. When perfectly adapted it should be burnished toward the walls all around the cavity, in order to make sure that the adaptation is perfect. An inlay that is not perfect will save the tooth for a time because the cement will fill up the defect, but the operator who depends upon a bruised reed of that kind for the security of his operations will surely come to grief. An inlay that shows a

discrepancy at any margin should be discarded and a new one made. The entire inlay may now be disked, always running the disk toward the margin of the cavity and never away from it. In this way the gold is flowed toward the margin and a more perfect adaptation is obtained. If the inlay is worth using the margins should be so tight that they are not discernible to the naked eye. If so the adaptation is so good that with the sealing virtue of the cement the inlay will save the tooth as long as the patient will need it, as far as any infiltration decay is concerned.

When this adaptation is secured the inlay should be removed and the tooth made ready for cementation. (See also Chapter V.) The ideal method is to place the rubber dam and dry the tooth with warm air supplemented by a bath of alcohol or chloroform. But most operators and patients object to the use of the dam for so short an operation, and the use of cotton rolls and the saliva ejector will keep the cavity dry sufficiently long to enable the operator to dry and disinfect the cavity and place the inlay. If so the cement slab with the proper portions of cement should be on the bracket ready for use, the cavity should be washed out with a strong dash of warm water from a good water syringe and the cotton rolls immediately placed in position. The tooth should be dried and washed out with alcohol or chloroform, again thoroughly dried with the hot-air syringe and the cement mixed to a creamy consistency. By a creamy consistency is meant a mix that will drop off of the spatula rather easily and yet will follow the instrument for some little distance as it is lifted in the air. If the mix is too thick the inlay will not go into place, and if too thin the cement will not have sufficient body to make a good cementation medium. The cavity should be filled with cement, care being used to see that all of the margins of the same are covered. Many failures have been noted on account of not perfectly filling the cavity with cement, thereby making a discrepancy between the inlay and tooth at some point, which later on will start an infiltration decay. If the inlay is well made this is about the only possibility for infiltration decay, for if the cement has been well adapted and protected by the inlay there is no possibility of a percolation of the fluids of the mouth between the inlay and dentin. If there is to be any further burnishing it must be done while the cement is soft and before it begins to crystalize, but there should be no necessity for burnishing at this time; the burnishing that might have been necessary should have been done when the inlay was tried in the cavity. After the cement has set, either at this time or at some future engagement, the inlay may be polished with sandpaper disks, rubber and pumice. The amount of polish that may be given is at the discretion of the operator, but better results are obtained by a finish that is not too high,

for too great a polish will so reflect the light that the gold will look black in some lights. Be sure that there is no cement under the free margin of the gums or between the teeth, wash out all cement particles and dismiss the patient.

INDIRECT METHOD OF MAKING GOLD INLAYS.

The reader is referred to Chapter VI for a description of this process.

CHAPTER V.

GOLD INLAYS AS BRIDGE ATTACHMENTS.

By MARCUS L. WARD, D.D.Sc.

This chapter is written as a short supplement to Chapter IV, in order to fill what appeared to some of my colleagues a void in the presentation of modern operative dentistry.

During very recent years, with the development of better technic for the construction of cast gold inlays, there has been a quite general use of the gold inlay as a bridge attachment which has brought a new branch of work from the field of bridge-work into operative dentistry. With the rapid recognition of the many advantages of the inlay form of attachment for bridge-work it appears likely there will be an even more general use of the gold inlay, thereby bringing the subjects of crown and bridge-work, and what has formerly been designated as operative dentistry, into such close relationship that it will be difficult to distinguish one from the other. It is this probability that makes the presentation of the subject of gold inlays appear incomplete without some reference to their use as bridge attachments. It does not seem advisable to enter into a discussion of the subject of bridge-work in this chapter, for that would involve a discussion of many problems that are at the present time properly assigned to books on bridge-work. It is rather to enlarge upon the statements made by the authors of Chapter IV with respect to the advantages of the gold inlay than to enter into a discussion of the subject of bridge-work. This is particularly true regarding the amount of stress that a gold inlay will resist without dislodgment.

It has been pointed out in Chapter IV that all fillings, gold inlays included, should have as nearly parallel walls as possible, and flat seatings in order to best resist the stress of mastication. This is unquestionably the most rational practice to pursue with every form of filling except possibly the gold inlay. Inasmuch as many operators have found it more advantageous to deviate from this form of cavity preparation in some cases, there has developed a group of operators who believe that the cavity for the gold inlay does not necessarily need parallel walls for retention. Not only do they believe that parallel walls are not always necessary for the single inlay, but they believe

that quite extensive fixed bridges may be attached to them without dislodgment, provided certain precautions have been taken to resist stress from certain directions. There is practically a unanimity of opinion on the technic of construction of the gold inlay, except the necessity for parallel walls, and the reader is referred to Chapter IV



FIG. 235

for this discussion. This chapter, therefore, will be devoted to a brief consideration of tapered walled cavities for gold inlays and their use in the construction of inlay attachments for bridge-work.

Fig. 236 shows a tooth and cavity which represent approximately the form of cavity preparation that the author used for gold inlays during the years just preceding and those immediately following the

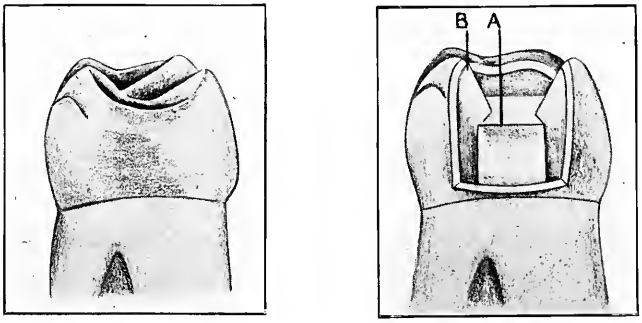

a *b*

FIG. 236

introduction of the cast gold inlay in 1907. The length of the bevel shown at *B* was varied, as necessity seemed to demand in order that the requirements of acceptable cavity formation might be met. Bucco-lingual extensions, as well as cervical extensions, were also varied with the susceptibility or immunity of the case in hand. Likewise the depth

of the occlusal portion of the cavity was varied with the stress likely to be applied, especially at the proximo-occlusal margin.

In October, 1908, on assuming charge of the inlay clinics at the University, an investigation was made with a view of improving the technic of making cast gold inlays which were receiving general attention. Many of the casts made at that time did not fit, some for one reason and some for another. Oftentimes it seemed impossible to get certain casts near to an acceptable fit of the cavity notwithstanding that much effort had been made to obtain one. It was noted that mesio-occluso-distal cavities were the most difficult to manage, the greatest defect appearing at the cervical portion of the inlay. Many other operators made the same observation. One large dental society had one of the profession's distinguished men give a clinic a second time to show how to remedy the defect observed by the use of crystal gold. The defect observed at the cervical portion of the casting was

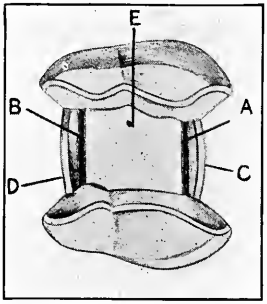

FIG. 237

large enough so that an explorer could be passed between the casting and the cervical wall of the cavity, and could be seen with the naked eye in ordinary light. Many dentists and a few investigators attributed this defect to the shrinkage of the gold. Others, however, knew that the shrinkage of gold on a piece of the size of an M O D inlay in a molar could not be seen with the naked eye as readily as the observed defect could, and proceeded to investigate other parts of the technic with the thought in mind that perhaps the form of the cavity was a factor of importance. The author was one of the latter and had made some hard metal molar teeth with cavities in them on the same plan as those shown in Figs. 235, 236 and 237 and several forms from which wax patterns could be made. The hardness of the metal teeth and the metal forms made bright spots on the castings at the places of contact when a little pressure was applied to the castings. In the M O D casting the bright spot occurred first at points *A* and *B* (Fig. 237).

As the pressure was applied to the occlusal part of the casting it continued to bulge out at the cervical part *C* and *D* until there was a space between the casting and cavity that would allow the passage of an ordinary explorer with ease. At this time it was observed that the casting had not become seated at the occlusal part *E*, which led to the belief that the shape of the cavity had much to do with the production of the defect so generally observed at the points *C* and *D*, for the casting had been brightened by the metal tooth at points *A* and *B* and at no others.

Cavities were then made in metal forms to correspond to the cavities shown in Figs. 235 and 236 from which castings were made. Careful inspection showed no particular place on the castings made for the occlusal cavity (Fig. 235), which seemed to come in contact with the tooth before other places did. They seemed to go to place without pressure and without any fitting. The castings made for the cavity shown in Fig. 236 almost always had a bright place on them at *A* when pressure was applied. When the bright spot was removed by grinding these castings would go to place without force. The conclusion drawn was that the angle formed by the axial and occlusal walls of the cavity at *A* was reproduced in the investing material and was not strong enough to resist the force of the gold when it was thrown into the mold. In other words, it appeared that there had been a slight compression of the investing material at the point *A*, resulting in a little too much gold in the casting. Work was then taken up on the M O D cavity (Fig. 237) in connection with the M O cavity (Fig. 236). In both cases the angles *A*, Fig. 236, and *A* and *B*, Fig. 237, were removed, making a distinctly flat surface instead of an approximate right angle. Castings made for these improved cavities showed that our conclusions were right. There had been a compression of the investing material at this attenuated point. The bright line did not appear at *A*, Fig. 236, when pressure was applied and these castings went to place almost as well as those made for the occlusal cavity, Fig. 235. The castings made for the M O D cavity did not go to place so well as did those for the occlusal and mesio-occlusal cavities. The bright line that had previously appeared at *A* and *B*, Fig. 237, now appeared slightly nearer to the cervical portion of the casting. This led to the conclusion that the gold had shrunk, and that shrinkage prevented placing the casting over the septum of dentin between the mesial and distal portions of the tooth. This presented an entirely different problem than was presented in the compression of the attenuated part of investing material. In neither the mesio-occlusal nor the occlusal cavity had it been necessary to construct a casting that would go over the septum of dentin which separated the mesial and distal portions. As we ground away the

mesial and distal axial walls of the cavity at *A* and *B*, and toward the cervical, these castings did not bulge out at *C* and *D* as before. From this it appeared that a problem in cavity preparation was presented in the M O D cavity that did not exist in any others. It was evident that a casting which had shortened in a mesio-distal direction in the slightest degree would not go to place until it had been stretched. This

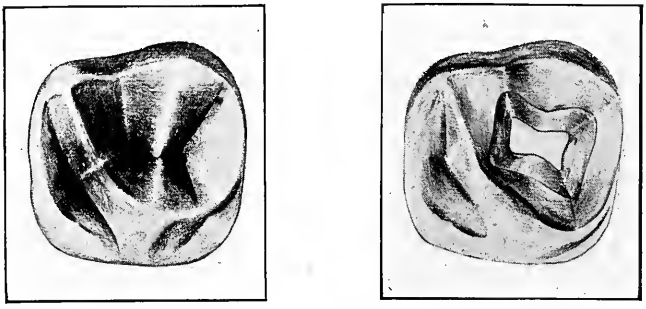

FIG. 238

deduction led to the adoption of tapered axial walls and the production of other metal teeth (Figs. 238, 239 and 240), with one incline from the seat of the cavity to the margins instead of the two inclines that we had used previously, and which are shown in Figs. 235, 236 and 237. This was done on the basis of first being able to get a wax pattern that was more accurate, and second, and equally important, to stretch the gold

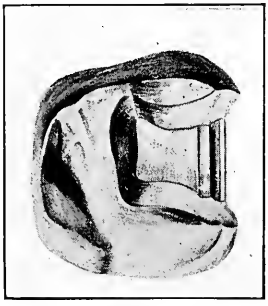

FIG. 239

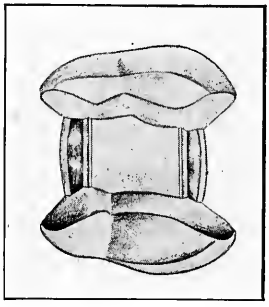

FIG. 240

better with a cone-shaped septum of dentin than with a septum which had parallel walls. The results with this form of cavity were very gratifying. The castings before they were fitted did not go to place. With the gradual taper that was given to the axial walls, however, only a little pressure was necessary to force castings of pure gold to place. In fact, these castings were forced to place so easily that one

was hardly conscious of having exerted any pressure. When other materials were used for these castings much more difficulty was encountered in fitting excellent castings. Such materials as dark 22 carat gold, clasp metal, etc., required repeated annealings and an equal number of applications of pressure in order to get them to fit as accurately as the pure gold ones did with little pressure.

The fact that the alloys of gold did not go to place as easily as the pure gold castings led many to believe that greater shrinkage had taken place when the former rather than the latter were used. While it is possible that future research may demonstrate a greater coefficient of volume change for the alloys of gold than for pure gold, it has not been done, and, as a result, we are left with only one explanation for



FIG. 241

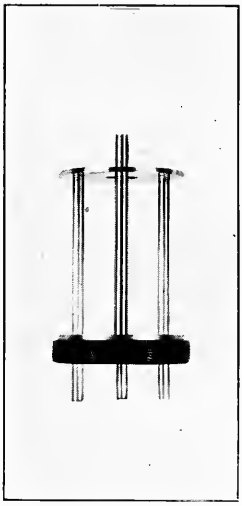

FIG. 242



FIG. 243

the greater ease with which the pure gold castings are fitted, namely, they stretch easily. The ease with which pure gold may be stretched may be shown by the use of a hardened steel cone such as is shown in Figs. 241 to 244 inclusive. Fig. 241 shows a receptacle for the formation of a wax washer and a paralleling device for the removal of the wax without distorting it. Fig. 242 shows the device partially opened with the wax lifted from its seat and not touching the steel cone. Fig. 243 shows the device with the wax trimmer placed over the cone for the purpose of making the wax washer perfectly flat on the top and of the same thickness all around. The steel cone is three inches high and 0.03 of an inch smaller at the top than the bottom which is 0.250 of an inch, and is as nearly a perfect taper as can be made. Fig. 244 shows a

set of six steel cones with tapers of 1, 5, 10, 15, 20 and 25 per cent. per inch taper. The longest of the six cones is three inches high and is exactly like the one shown in Fig. 241. This makes it possible to remove a wax washer from the wax former and from it make a gold washer, which may be used either on the cone, on the wax former or on the set of cones with their different tapers. If such a gold washer be made under the best technic known at present it will not go to the bottom of the steel cone from which the wax washer came. It will go to about the place shown on the cone at the left end of Fig. 244. If it be cast from pure gold, slight pressure will carry it farther down on the cone. Thorough annealing and another application of pressure will carry it nearer to the base of the cone. A repetition of the process of annealing and application of pressure will carry it still farther down. If, on the other hand, the washer be made from dark 22 carat gold, coin gold or clasp metal it will be found very difficult to get the washer down by



Fig. 244

repeated annealings and applications of the same pressure as was used on the pure gold washer. In fact, it will require a mallet to make much progress with a washer containing as much gold as the one used, which was 0.500 of an inch in diameter, 0.100 of an inch in thickness and had a hole in the center 0.250 of an inch in diameter. If a washer be made from the same material that contains less gold it will be just that much easier to carry it to the base of the cone.

If a perfectly straight rod be placed in the wax former instead of the cone with its 1 per cent. per inch taper and a pure gold washer be made, it will not even start over the rod on account of shrinkage of the gold. Any attempt to force it will result in an upsetting of the gold at the edge of the hole in the washer. This appears to be exactly what takes place when M O D cast inlays are made from cavities with parallel axial walls, for it is at this place that the shrinkage of the gold first interferes with placing the casting. From this it seems not only impracticable,

but impossible to construct satisfactory M O D cast gold inlays from patterns made from cavities with parallel axial walls. Some claim that they can do it, but it is doubtful if their observations are correct with respect to the walls being parallel, for it does not seem possible in the laboratory where accurate measurements can be taken. In the mouth it is not possible to tell whether the walls are parallel or not. A taper of 1 per cent. per inch on the walls of most cavities is not visible to the naked eye. Indeed, it is not distinctly visible on the steel cones until the cone has been carried to a height of about three inches. With a special caliper the author has been unable to be certain of tapered axial walls until about 5 per cent. per inch had been made on the average cases that have come to the clinics. (See second cone from left end.) As the taper reaches 25 per cent. per inch (see cone at right end) it may be seen readily even on very short cones.

With the set of cones as a guide and the special caliper the author and his staff have made a careful study of the amount of taper that could be used not only on the axial walls, but on the buccal and lingual portions of both the proximate and occlusal parts of such cavities as shown in Figs. 238, 239 and 240 as well as their modifications due to caries, and have the castings resist the forces of occlusion without dislodgment. The results of this study lead us to believe that from 5 per cent. per inch (see second cone from left end) to 20 per cent. per inch (see second cone from right end) is permissible, the amount used depending, first upon the length of the casting from the cervical to the occlusal, and second, upon the amount of stress to be applied. Short teeth which require short castings from cervical to occlusal are not suitable for bridge attachments in the work of mastication, for the amount of resistance to lateral stress is not sufficient to hold an ordinary fixed bridge.

In fact, it seems that the length of the cavity from cervical to occlu al is one of the most essential factors to be considered, and upon this question alone one may settle the question of advisability of using an inlay attachment for a bridge. It seems to make little difference whether there is a taper of 5 to 20 per cent. per inch provided the cavity is in a tooth that is long from the cervical to the occlusal. On the other hand, if the tooth be one that is short from cervical to occlusal there can be no question but that the least taper consistent with the removal of the wax pattern and the fitting of the casting the better will be the retention, though success cannot even then be expected to attend the use of such teeth for attachments for bridge-work unless the pulp be removed and a dowel inserted into the pulp chamber.

These deductions have led many to a deviation from the accepted policy of paralleling the walls of cavities for the reception of fillings.

These deviations as shown in Figs. 238, 239 and 240 are limited to the preparation of cavities for the reception of cast inlay fillings and bridge attachments for the following reasons:

1. Parallel walls cannot be detected in cavities in teeth in the mouth. It requires upward of 5 per cent. per inch on short axial walls in order to be certain that there are no undercuts.

2. Parallel walls will not permit the removal of an accurate wax pattern from the cavity.

3. Tapered walls facilitate the fitting, especially in M O D castings.

4. Parallel walls are not necessary for the retention of cast gold inlays either as fillings or bridge attachments except in teeth which are short from cervical to occlusal. In such cases it is a question whether the judgment of the profession will not eventually lead us to consider such cases contra-indicated for bridge attachments.

5. A sharp angle in any part of a cavity such as is shown at *A*, Fig. 236 or *A B*, Fig. 237, will produce an attenuated place in the present investing materials and result in an inaccurate casting.

A study similar to the one made on the shapes of cavities for fillings has been made on castings that are capable of retaining fixed bridges of four and five teeth, for example, one from cuspid to first or second molar or from cuspid to cuspid either in maxilla or mandible. Careful records of scores of cases have shown that the M O D cast inlay in molars (Fig. 240) or bicuspids that have their pulps in them and have not had the dentin cut away between the mesial and distal portions, and are of the average length from cervical to occlusal, will hold the average fixed bridge of the length mentioned, provided the casting has been done with an alloy of gold that is as strong or stronger than dark 22 carat gold. It should be obvious that a molar which has the dentin cut away between the mesial and distal portions is likely to fracture when the stress of a bridge involving only three teeth is attached to it. A bicuspid being a smaller tooth has even less dentin on the buccal and lingual walls if a channel has been cut through the dentin connecting the buccal and lingual walls by previous filling or caries, and is, as a result, less desirable than a molar under such conditions from the standpoint of the fracture of the tooth. Such inlays will often become dislodged more easily than those made from teeth which have a good septum of dentin between the buccal and lingual walls.

From the standpoint of liability of fracture of the tooth and the greater chance of dislodgment, the M O D inlay seems contra-indicated in cases which do not have a good, strong septum of dentin between the buccal and lingual walls in either teeth with pulps in them or pulpless teeth.

Many different forms of partial crowns have been suggested which

would protect the tooth from fracture, but, as a general rule, this has been done without having first given special attention to the forces which fracture such teeth. *Some of the partial crowns that have been suggested as bridge attachments have covered entirely too much of the tooth and the result has been either devitalized or irritated pulps within a year or two after the insertion of such a bridge.* The adventitious effect of large masses of metal in contact with tooth tissue has been studied by several pathologists, and some work has been reported which seems to indicate the use of the least amount of metal in contact with the tooth tissue that is consistent with strength. It is necessary that the inlay or partial crown does not stretch under the stress of mastication, for if it stretches even a slight amount it is usually dislodged soon afterward. The stretching will manifest itself by a pulling away from the remainder of the inlay of the proximate portion of the inlay that is soldered to the remainder of the bridge. This may be prevented by making the occlusal



FIG. 245

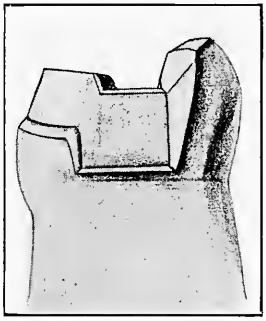

FIG. 246

portion of the inlay deeper and wider and by extending the gold around the lingual portion of the tooth as shown in the upper molar (Fig. 245) and around the buccal portion of the lower molar[1] (Fig. 246). These castings will stretch when pressed over a conical piece of dentin but will not stretch under the stress of mastication if proper precautions are taken to get the proper resistance to stress.

Some have suggested the extension of the gold toward the cervical to the point *A*, Fig. 247, and a similar place, Figs. 245, 246 and 249, but it seems to have only one thing in its favor, namely, it furnishes a little more surface retention for the cement between the tooth and inlay. The additional amount of metal that this extension necessitates in contact with the tooth at a vulnerable point appears to more than counterbalance any other thing in its favor. Up to the present

[1] The location of the contact points on the lower molars and bicuspids usually makes it more practicable to use the buccal side.

time inlays from such cavities as shown in Fig. 248 seem to be much less irritating to the pulps of teeth than those which extend near to the cervical portion of the teeth. This form of inlay attachment is simply an M O D inlay which has been extended over to the buccal and lingual surfaces sufficiently far to prevent fracture of the tooth.



Fig. 247

It may be seen that the hold which this attachment has on the tooth is much like that of a crown, though it has much less metal in contact with the tooth than the crown has. This attachment has been very satisfactory for pulpless teeth and for teeth with pulps in them which have had the dentin between the mesial and distal portions cut away. In fact this attachment is doing all that any gold crown has done in



Fig. 248

the author's hands and has been the means of nearly eliminating the full crown. It permits the retention of the pulp when the teeth are vital, and in all cases makes it unnecessary to employ a band, thereby eliminating one of the most frequent sources of irritation and infection.

Fig. 249 shows tooth and an attachment for upper bicuspids similar

to the one for molars, which has been equally satisfactory though applicable in a less number of cases on account of the greater objection to the exposure of gold to view as the teeth are located anterior to the molars.

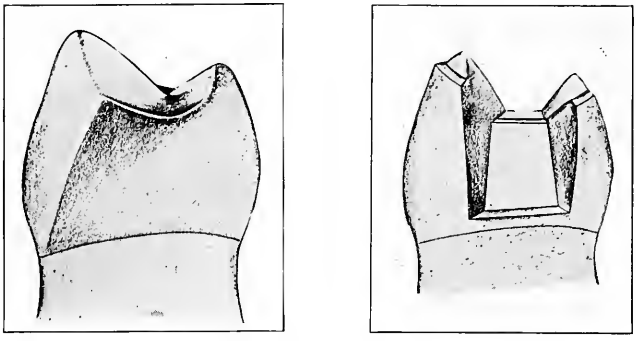

a *b*

FIG. 249

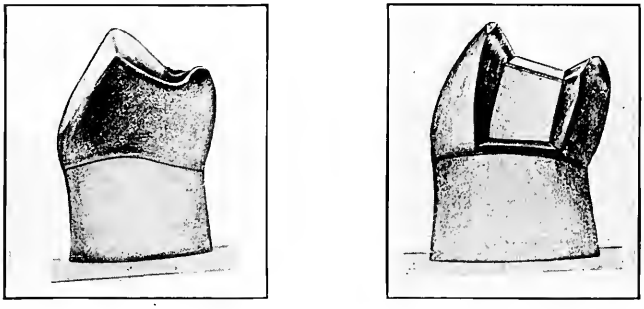

a *b*



c

FIG. 250

Fig. 250 shows a lower bicuspid, an M O D, and a partial crown preparation. It is seldom that the M O D inlay is indicated in the lower

bicuspids, for the lingual wall is usually weak. On account of the low lingual cusp, especially on the first bicuspid, and the narrowness from mesial to distal of the lingual side of these teeth, the preparation shown in Fig. 250 *c*, is preferable in nearly all cases. The location of the contacts of these teeth with adjacent teeth makes it necessary, as a rule,

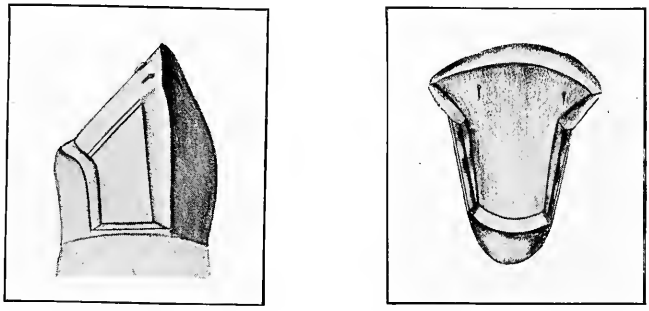

a *b*

FIG. 251

to make the partial crown preparation in order to get room to solder the attachment to the remainder of the bridge.

Figs. 251 and 252 show M O D inlays for cuspids that will carry one end of a bridge from cuspid to the first or second molar. They are simply M O D inlays that have either one 22 gauge iridio-platinum pin set each side of the horn of the pulp, Fig. 251, or a groove from mesial to distal (*A*, Fig. 252) for the purpose of resisting stress from the labial.

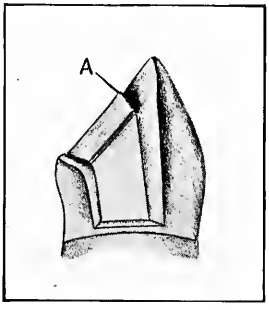

FIG. 252

Some have suggested preparations for the cuspid teeth that were cut on the lingual to the position *A*, Fig. 253. Such castings, however, will not resist labio-lingual and bucco-lingual stresses as well as those made from the cavities shown in Figs. 251 and 252, unless a groove has been cut along the axial wall at *B*, Fig. 253. Some claim they are able

to do this, but the author has been unsuccessful in his attempts to teach students to cut grooves along the axial walls of proximate cavities except in the teeth of middle aged and old people.

The development of the attachment shown in Figs. 251 and 252 seems to meet the demands of both young and old people, and for the present the grooving of all axial walls has been abandoned.

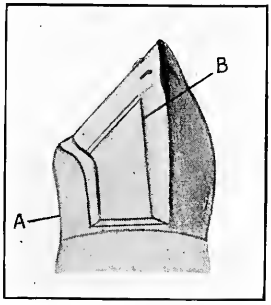

FIG. 253

Figs. 254 and 255 show preparations that have been successful in central incisors that are very similar to the cuspid preparations. As in the cuspid preparation the absence of the lingual cusp makes it necessary to use either the pins, *A*, Fig. 254, or groove, *A*, Fig. 255, to prevent force from the labial from dislodging the attachment. It

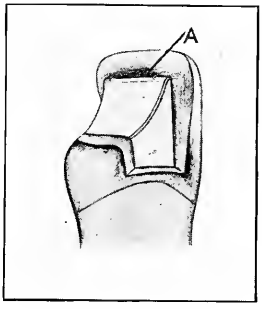

FIG. 254

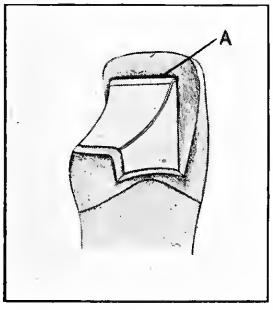

FIG. 255

should be remembered that cuspids, incisors, lower bicuspids and often second lower bicuspids do not have the same resistance to forces from the labial and buccal that a molar or upper bicuspid has, and when an attachment for a bridge is to be made for these teeth some form of resistance to these stresses must be made. Three ways have been suggested, namely:

1. Extension of the metal to either the labial or buccal or lingual, or both walls.

2. Placing small pins in the incisal portion of the tooth.

3. Cutting a groove either across the incisal portion of the tooth or along the axial walls, the latter usually applicable to teeth of persons who are middle aged or older.

It may be noted that all of the attachments suggested as having been successful are made on the plan of tapered walls. Scores of these attachments have been inserted during the last seven or eight years under all kinds of conditions *except in short teeth.* None, in recent years, have been placed in teeth which were short from cervical to occlusal, for success has not attended this kind of practice, notwithstanding that the walls of such cavities have been made as nearly parallel as possible, with proper protection against undercuts. With the exception of the short teeth, therefore, and with proper attention to the precautions pointed out with respect to liability to fracture, stretching of the inlay at the occlusal portion, protection against labial and buccal stresses on teeth without lingual cusps, the tapered walled cast inlay attachment may be regarded one of the most rational methods of practice.

CHAPTER VI.

HIGH FUSING PORCELAIN INLAYS.

By W. A. CAPON, D.D.S.

PREPARATION OF CAVITIES.

The success of an inlay will depend largely upon four points of difference between its cavity preparation and that for those of foil, gutta-percha, amalgam, or cements, viz., upright walls, square enamel edges, no undercuts, and depth. The walls being perpendicular or nearly so, allow the easy withdrawal of the metal matrix either of platinum or gold, or in the case of the impression for casting with wax or any material for the purpose of making a model. The enamel edges are made square so that the inlay will have no overhanging frail edges of porcelain.

An undercut will prevent the easy removal of the matrix frequently distorting it, and when using wax not even the slightest undercut is permissible. In connection with porcelain, depth of cavity has much to do with retention, in fact it is more important than various keys and irregular forms advocated by many writers on this subject. Unfortunately we cannot always get sufficient depth, and, on the contrary, many cavities, when entirely cleared of decay, are too deep to obtain an unmutilated matrix particularly with platinum; however, when this condition exists, it is an easy matter to reduce it by partially filling with cement or gutta-percha.

The advantages of depth are retention, strength, through quantity of material, and purity of shade by having sufficient volume of porcelain which assists materially in reducing the opacity caused by the cement.

This rule pertaining to deep cavities has not the same value when applied to the cast gold inlay, and it is well to note that the same rules which apply to porcelain inlays are applicable to matrix gold inlays, except that point pertaining to shading, because cavities prepared for matrices have always the burnishing feature prominent, which means curves and all surfaces accessible to the burnisher.

The formation of cavities is greatly assisted by special burs, stones and chisels of various sizes and curves, as illustrated in Figs. 256 and 257.

The following representations of various cavities in natural teeth where porcelain is indicated and applicable are shown with the same cavity prepared and ready for the matrix. By this means the student will readily note what is requisite and necessary without detailed description and technical nomenclature.

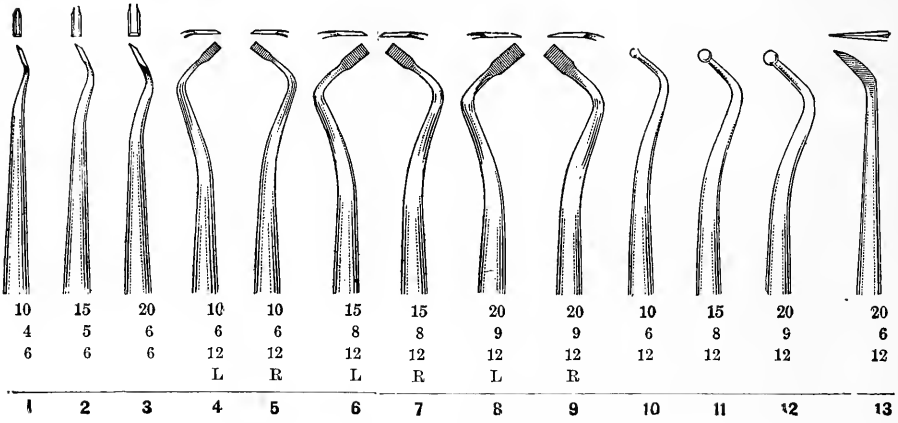

Fig. 256.—Simpson's automatic chisels (proximate).

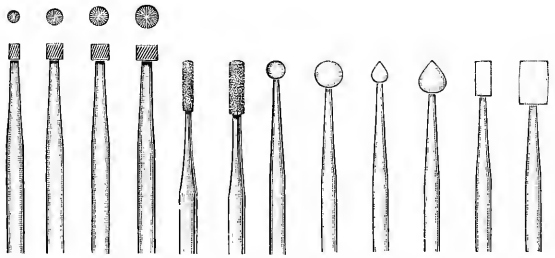

Fig. 257.—Burs and stones.

Simple Cavities.—Figs. 258 to 265 show simple cavities, and in each case the border has been extended beyond the outline of decay, for the same consideration with respect to extension is applied in this class of work as if the cavity were to be filled with gold.

Figs. 266 and 267 are in the same class but are more difficult, for they have resulted from another cause, viz., abrasion or erosion, and it is noted particularly because this condition is common, and the cavity preparation much more difficult. The depth is insufficient and the margins are never defined, which necessitates extensive cutting into hard and unusually sensitive dentin, and as this kind of cavity is almost as common in lower teeth, the difficulty of preparation and general manipulation is increased. This applies to all labial cavities and is

noticed more in porcelain operations, because when the cavity is ready the matrix must be held in position firmly, a procedure interfered with

FIG. 258

FIG. 259

FIG. 260

FIG. 261

FIG. 262

FIG. 263

by the lower lip and the saliva. The use of rubber dam is not desirable because it reduces the working space, but it has other advantages occasionally.

Proximate Cavities.—Figs. 268 to 277 show cavities presenting greater difficulties both in preparation and general manipulation. The preparation of cavities in such positions requires ample space between the

FIG. 264

FIG. 265

FIG. 266

FIG. 267

adjoining teeth, otherwise a matrix cannot be withdrawn or the finished filling inserted. Sometimes it is impossible to get sufficient space for drawing the matrix without distortion; in such instances the cavity is

prepared with this point as a first consideration. Fig. 277 shows a cavity of this kind. If there is not much difference in outline of the

FIG. 268

FIG. 269

FIG. 270

cavity labially or lingually, choose the labial side from which to remove the matrix; or, if cutting the labial margins does not interfere with the welfare of the tooth, resort to this assistance in preference to diffi-

FIG. 271

FIG. 272

culties of lingual matrix removals. In Figs. 269 and 271 the matrix under ordinary conditions will be withdrawn lingually. Figs. 270 and

272 show uncertain incisal edges which are reduced in Figs. 273 and 275; therefore the difficulties of drawing a matrix in this case are very much

FIG. 273

FIG. 274

FIG. 275

FIG. 276

FIG. 277

reduced, for the cavity is so large that working space is greatly extended. Large proximate cavities of Fig. 272 type, where the incisal edge is of greater strength and is retained, are very difficult and frequent.

The matrix formation requires skill and patience, but the reward is durability—for the inlay in this case is thoroughly protected and is rarely unseated.

Figs. 278 and 279 show a cavity on the gingival border extending under the gum margin and involving a considerable portion of the tooth mesially and distally. It is a typical representation of this form of cavity and the position is one demanding a restoration with porcelain. The cavity walls are governed by its extent, for the matrix will warp if a strict rule of upright walls is carried out here. The cervical wall will not be at right angles to the pulpal wall or floor, or if so made they cannot be of that form at the extreme mesial and distal border; therefore, in these cavities strict adherence to a right angle upright wall is not possible for the best result. When the matrix is burnished it should

FIG. 278

FIG. 279

be packed with gum camphor in preference to other materials recommended. It is not always possible to make a very extensive inlay of this kind of one piece, therefore it should be divided at the median line of the tooth and two operations made.

Proximo-incisal Cavities.—Figs. 280 to 284 represent extensive proximate cavities or fractures extending to the incisal edge, and in a position where porcelain is of great importance. The apparent insufficient anchorage deters many operators from using porcelain, and the preparation of these cavities is the cause of more different opinions than any other. It is claimed that, without a key or step on the lingual surface, porcelain will not be retained by the ordinarily prepared cavity, and unnecessary cutting of good tooth structure is taught with most deplorable results—in many instances, irregularity of cavity and its borders increase the matrix-formation difficulties, therefore a simple

preparation is taken advantage of. With few exceptions the cavity can be prepared similarly to Fig. 280, defining the labial and lingual

FIG. 280

FIG. 281

walls and anchorage increased by a groove with a round bur at the gingival border resembling a deep undercut, as for a gold filling.

FIG. 282

FIG. 283

FIG. 284

Anchorage is also increased by grooving between the enamel plates at the incisal edge. The matrix must be burnished to these surfaces,

otherwise the value of the preparation is lost. The labial outline, Fig. 283, can be varied in many ways, but angles are to be avoided whenever possible. Very often the corner is of the form of an irregular triangle tapering to a wedge point at the cutting edge. The porcelain at that point is very frail and will break, leaving an irreparable notch. To avoid this, cut an axial wall as in Fig. 284, and thus make a body of porcelain, giving strength at a weak point. This same cavity is sometimes so extensive that anchorage is made by wire pins or staples. In instances where the incisal section of the tooth has been lost by accident or decay, this process of retention is preferable and highly recommended for permanency.

FIG. 285

Fig. 285 shows a central tooth, a matrix, and the porcelain section with wire anchorage. This case shows loss of one-fourth of the tooth and the cavity made by cutting the dentin to the required depth, an operation possible with few exceptions. The enamel edges are made true by a flat stone, after which the matrix is made of the walls and edges, and shown without a floor. The wire is iridio-platinum, gauge 24, made in the form of a staple or loop, and inserted while the matrix is in place; with these in position, porcelain in paste form is pressed over all and excess moisture is absorbed by holding a napkin or bibulous paper to its surface. The combination is carefully taken from the cavity and fused, thus forming a base with a wire loop or pins held securely without soldering. This foundation is now placed on the tooth and matrix edges thoroughly burnished, after which the operation is completed by repeated fusing. When the matrix is removed, the contoured tip will resemble the third section of Fig. 286, and is ready for cementing. When the first porcelain is applied it will likely fill the loop, but this must not be corrected until after fusing, when the porcelain is easily broken away with blunt pliers. Frequently the staple or loop is inverted to suit conditions, but the form represented is the most durable in every particular. The difficulties of this operation are increased by the irregular form of fracture, for usually they extend lingually and frequently quite to the gum margin; a restoration of

this kind should not be attempted until the operator has had considerable practice, for the making of an incisal tip acceptably is one of the most difficult operations.

FIG. 286

FIG. 287

FIG. 288

FIG. 289

FIG. 290

FIG. 291

FIG. 292

FIG. 293

FIG. 294

FIG. 295

FIG. 296

Figs. 286 to 296 show the staples in various applications, including corner restorations.

Bicuspid and Molar Cavities.—Figs. 297 to 306 show cavities in bicuspids and molars for porcelain inlays. The forms are very similar and directions for cavity technique are applicable in either instance. The value of porcelain in these positions is questioned because the force of

FIG. 297

FIG. 298

FIG. 299

contact is increased and the esthetic value is decreased. There are many exceptions, and the opportunities exist in mesial surfaces of superior biscupids and molars. The occlusion is the first consideration, size and depth of cavity are next, although the latter is generally

regulated by a step as shown in the sketches. This step is made of cement or gutta-percha and not of the same extent as if preparing for

FIG. 300

FIG. 301

a gold inlay. The gingival borders are more curved and the step is rounded and allowance made for greater thickness of porcelain at the occlusal surface. The inlay will be more secure without a step or

FIG. 302

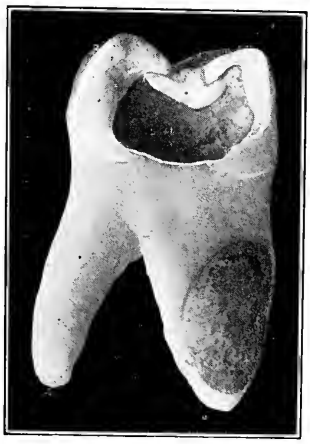

FIG. 303

interior preparation of any other material, but bicuspid and molar cavities are usually too deep for successful matrix formation. If

this can be accomplished, there still remains the difficulty of placing the inlay, because of greater bulk than it is possible to get space for; however, there can be no set rule, circumstances and good judgment



FIG. 304

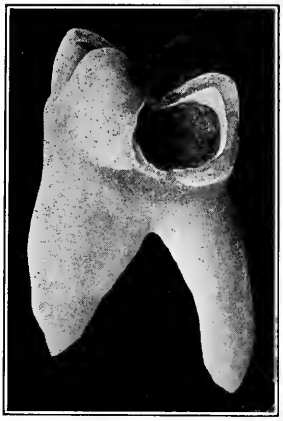

FIG. 305

must be factors at all times. In any case the cavity must not extend into the sulci between cusps unless the sulci are of sufficient size to assure strength of porcelain. Figs. 302, 304 and 306 show enamel surface edges without any extension to the sulci.

FIG. 306

The following illustrations represent what may be termed unusual cavities both in form and extent for porcelain inlays.

Fig. 307 incisal edge, requiring very accurate adaptation because of small opportunity of retention. If the mesial and distal walls are not too thin on the incisal enamel, a groove in the cavity will assist, but the general form of the tooth will govern this suggestion.

Fig. 308 an unusually large form of labial cavity extending to the extreme mesial and distal borders and leaving only the lingual enamel plate.

Fig. 309 a labial cavity toward the incisal edge more frequently seen at the gingival border.

FIG. 307 FIG. 308 FIG. 309

Fig. 310 represents a type of preparation for a porcelain tip, the original enamel being defective in form and color.

Fig. 311 a mesial cavity extending from the gingival border to the incisal edge of a central. Cavity converging extensively labially and the lingual cutting edge shortened because of decay and weak enamel.

FIG. 310 FIG. 311

Fig. 312 linguo-mesial cavity extending to incisal edge. Lingual wall reduced because of weakness of enamel, but that loss is added strength to the porcelain inlay.

Fig. 313 an extensive labial cavity involving the whole mesial surface and extending lingually. In preparing this cavity the pulpal wall angles must not be so acute that the matrix cannot be withdrawn from the incisal section between the enamel plates or reducing the axial wall at the incisal edge to a plain surface may be necessary to prevent distortion of the metal.

Fig. 314 incisal, labial and lingual preparation with angles to assist retention.

Fig. 315 lingual preparation for mesio-incisal restoration, more applicable to gold inlays. This form of retention for porcelain is not gener-

Fig. 312 Fig. 313

ally recommended because of increased difficulty in obtaining a matrix from the under surface and the doubtful assistance of a substance of such friable composition.

Fig. 314 Fig. 315

PORCELAIN RESTORATION FOR CHILDREN'S TEETH.

One of the most difficult operations for any dentist is the restoration of a broken permanent incisor of a child between the ages of seven and twelve years. The tooth is generally broken by an accident and frequently the pulp is not affected, but the tooth is extremely sensitive. If the pulp is exposed, devitalization is the only resort, and the restoration can be made with porcelain, using an iridio-platinum pin extending into the canal, or a wire loop of the same metal, No. 24, anchored in the remaining part of the crown.

This work is comparatively easy, because the main requisite for strength is anchorage, which is possible under these conditions. When the pulp is alive and apparently healthy it is generally desired that such a condition be preserved, which is not an easy matter under these

circumstances. Something must be applied for protection, and therefore cement is used because of its tenacity. No mechanical anchorage is possible. The child is young and the teeth are undeveloped, therefore they must be kept comfortable, if not presentable, for some years, for it is my experience that a case of this kind at the age mentioned is irresponsible and the dentist must bear the burden, which means continual replacement and general botheration. I recommend, therefore, that nothing permanent be attempted until the case has arrived at an age of maturity, when the patient is willing to use care with what has been done and has arrived at the age when personal appearance has some value.

A girl patient will be ready for a permanent operation about two years before a boy. Therefore, it is fairly safe to consider a finished operation at the age of thirteen to fifteen years. In the meantime, during the intervening years, fracture surfaces must be covered in some agreeable manner, and to that end I present the following plan of making a presentable restoration.

FIG. 316

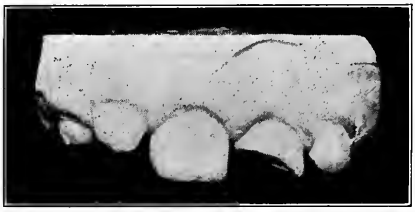

FIG. 317

Fig. 316 represents the case of a boy, aged eight years, left central broken by a fall, pulp not exposed, but too sensitive to allow any instrumentation whatever. I kept the surface covered with cement for one year, which demonstrated the fact that the pulp was not materially affected by the fracture. The parents insisted that something more presentable be done, so an accurate impression of the broken section was taken in plaster, and, after drying, a model was made of Mellotte's metal. Platinum foil No. 38 was swaged to fit the broken surface, extending lingually to the gum line and labially one millimeter.

This formed an accurate shell, which covered the tooth except on the labial and proximate surfaces. This thin platinum form was then reinforced by 25 per cent. platinum solder and a small staple attached to the broken surface (Fig. 317) for the purpose of holding the porcelain. After three fusings the restoration was completed as shown in Fig. 318. The small line of platinum on a labial surface did not detract from the finished operation to any objectionable extent because the porcelain

corner was so much greater in size; however, the improvement quite paid for the trouble.

Wire used for the staple was iridio-platinum No. 24. The surface of porcelain contact was etched to give every opportunity of attachment. This case was in use for five years and had the advantage of easy replacement of either the whole shell or repair of porcelain if necessary. If gold is preferred, the metal can be cast direct to the foundation, which should be made of gold instead of platinum.

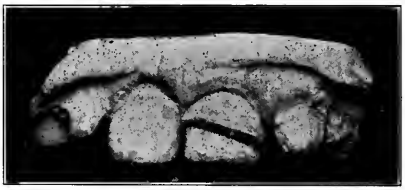

FIG. 318

FORMATION OF THE MATRIX FOR PORCELAIN.

The difficulties pertaining to the making of a matrix are much reduced by having plenty of space between the teeth, and this must be obtained prior to the operation by means of tape, cotton, or rubber wedges. Mechanical appliances may be used as an assistant when the inlay is made and the space for easy insertion is insufficient, but holding the teeth apart while making the matrix is usually an interference that can be avoided by giving this part of the work proper consideration. Room to work is a good rule to follow in any operation, but it is positively necessary with the inlay, because the mass is hard and unyielding with breakable edges. It must be placed while the cement is soft, and without delay, and the slightest interference may mean much loss of time and poor results.

A gold inlay can be forced to place without damage, but an unpleasant experience or two with porcelain will demonstrate the desirability of having plenty of space.

The reproduction of the form of a cavity in foil for an inlay is called the matrix, in which the porcelain is moulded by heating to a degree required to fuse the component parts of the material to a vitrified mass. The metal most generally used is pure platinum foil, $\frac{1}{1000}$ of an inch in thickness. Gold foil No. 40 is also largely used, but only in connection with a low fusing porcelain which fuses at a temperature of 300° to 500° less than gold. Platinum has the advantage in the fact that it cannot be affected by any heat required to fuse the highest grade porcelain. It is not so ductile, nor so easily moulded to form, but this dis-

advantage is counterbalanced by its stability, which allows greater freedom from care as to the changing of its form while filling with porcelain.

A gold matrix is invariably invested to prevent its changing form and protect it from overheat. This requires time and care, therefore platinum is more desirable from many points, and practice will assist greatly toward easy manipulation. There has been much discussion in the past upon the proper thickness, but it is now generally conceded that $\frac{1}{1000}$ of an inch will suit all cases better than any degree thinner or thicker. A thinner material has not the stretching quality, and anything heavier will cause a thicker cement line.



Fig. 319

A simple cavity on the labial surface of a central will serve to illustrate the mode of procedure, which is the cutting of a square section of the foil sufficiently large to extend over the adjoining teeth, holding the corners in the manner of Fig. 319, and while held securely by the fingers, press the foil over the cavity with some material such as spunk, cotton, small chamois disks, or a soft rubber point like a pencil end, and in this manner the cavity will be outlined on the foil and that portion covering the cavity concaved so there can be no mistake as to what portion is to be burnished. Then use ball-pointed burnishers of various sizes, such as amalgam instruments shown in Figs. 320 to 322, and gently rotate, gradually pushing the burnished surface to the cavity walls and floor, using care not to break the margins. The metal will probably split or break as it is forced to place, but unless extremely ruptured, it will not interfere with final results. When the interior portion is fairly fitted, packed with spunk, cotton, or gum camphor, and held securely with a blunt instrument, a flat, blunt instrument should be used to get perfect margins. Then the packing is removed (except when using camphor, which is burnt out), the matrix released with very fine

pointed pliers, and results noted. Three desirable sets of burnishing instruments are illustrated in Figs. 323, 324 and 325.



Fig. 320 Fig. 321 Fig. 322

If satisfactory, the next step is filling the mold with porcelain.

Platinum foil should be thoroughly annealed in the furnace muffle; the heat required to improve its softness is at least 2200° F. The foil purchased at the present time is usually ready for making the matrix, having already been thoroughly softened at a very high temperature. A matrix of complex character will require more than usual burnishing, which will have a tendency to make the metal harsh. It can then be re-annealed to advantage, provided the temperature is not less than the degree already mentioned.

An excess of material is recommended in labial cavities for the purpose of holding securely, but in other places the reverse is desired; notably on proximate surfaces, where the excess will interfere with removal after taking the form of the tooth. Burnishing the matrix in proximate cavities, corners, and tips is greatly assisted by strips of either cotton, rubber dam, or goldbeater's skin held securely over the metal, insuring its proper position and preventing tearing on the sharp cavity edges (Fig. 326). Avoid lapping or folding of matrix on cavity edges.

After the matrix is made, the next procedure is filling it with porcelain. This is done by holding the mold in straight, fine-pointed pliers, applying the porcelain with a fine sable pencil brush, or the end of a spatula made for the purpose (Fig. 327). The porcelain powder is mixed with pure water, distilled preferably, into a stiff paste, and after applying, it is shaken to position either by tapping or drawing the serrated instrument handle across the pliers. This jarring brings the moisture to the surface, and after tracing the cavity outline and removing

excess with brush, it is laid face down on a clean towel, bibulous or blotting paper, which absorbs the excessive moisture. The inlay is

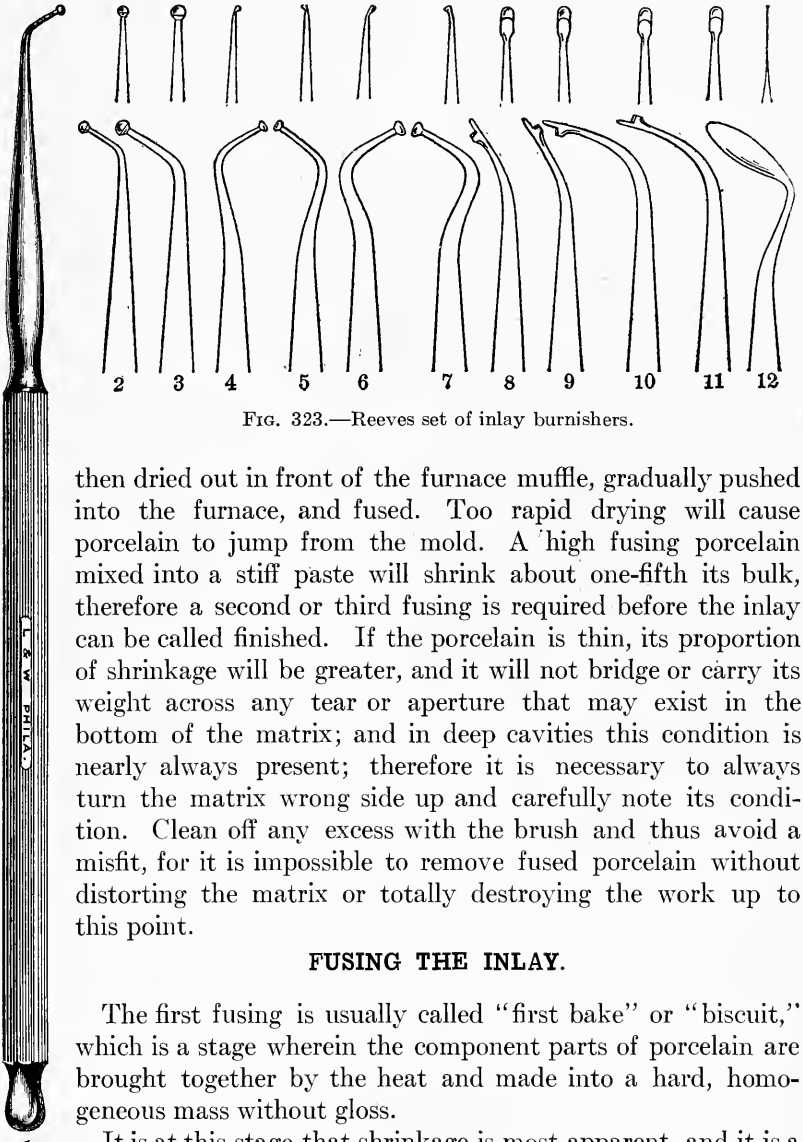

FIG. 323.—Reeves set of inlay burnishers.

then dried out in front of the furnace muffle, gradually pushed into the furnace, and fused. Too rapid drying will cause porcelain to jump from the mold. A high fusing porcelain mixed into a stiff paste will shrink about one-fifth its bulk, therefore a second or third fusing is required before the inlay can be called finished. If the porcelain is thin, its proportion of shrinkage will be greater, and it will not bridge or carry its weight across any tear or aperture that may exist in the bottom of the matrix; and in deep cavities this condition is nearly always present; therefore it is necessary to always turn the matrix wrong side up and carefully note its condition. Clean off any excess with the brush and thus avoid a misfit, for it is impossible to remove fused porcelain without distorting the matrix or totally destroying the work up to this point.

FUSING THE INLAY.

The first fusing is usually called "first bake" or "biscuit," which is a stage wherein the component parts of porcelain are brought together by the heat and made into a hard, homogeneous mass without gloss.

It is at this stage that shrinkage is most apparent, and it is a condition that exists in every porcelain operation of whatever dimensions. Shrinkage is governed by quantity and quality of material and is a prominent factor toward success or failure. In small inlays shrinkage is of less import, but in proportion to size it must be dealt with. This

shrinkage may be sufficient to distort the matrix or cause porcelain to attach to the matrix walls. As it is never consistent, it is very important to control it, but this is only possible to a small extent. Shrinkage toward the matrix wall is most desired and can be assisted by a slight cut or groove across its greatest extent, thereby giving the porcelain an impetus in that direction. In large spaces much assistance in controlling shrinkage is derived from using small particles of baked porcelain mixed with the unfused paste.

Fig. 324.—Weber's glass burnishers.

After the first fusing of the inlay the excess platinum or matrix material should be trimmed, leaving a working margin to allow a refitting in the cavity. In small, simple cases this may not be necessary, but in the majority of cavities it will assist greatly. If the matrix has become slightly altered by shrinkage or careless handling, the change is noted at once and corrected. In contour work it will assist the eye to determine where to add or reduce; in fact, there can be only very small argument against a trial of the embryo inlay in its place and reburnishing the cavity edges.

Selecting the shade is the first requirement, as the foundation should approximate the final shade, but after the inlay is reburnished, this

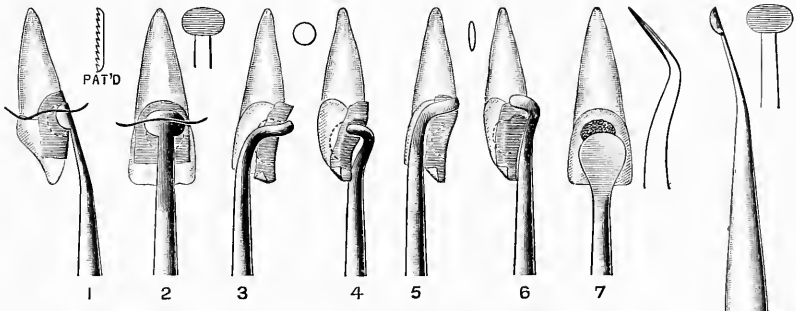

FIG. 325.—Sausser's matrix burnishers.

question must be settled in the operator's mind, and the final fusing proceeded with. First, clean off the inlay with a brush dipped in alcohol or warm water, thus removing saliva, blood or any undesirable particles, then carefully fill any crevice caused by shrinkage or breakage, finally filling the matrix or building the contour or section as desired, always considering shrinkage. A second bake may be sufficient, but usually a third is required or even a fourth. Frequent firing is not harmful, provided the porcelain has not been carried to a finishing heat previously. Shrinkage must be overcome, therefore withdraw the work from the furnace before it is fused and note its condition.

After the inlay is properly fired the matrix is removed by turning the metal back from the edge with pointed pliers, releasing the inlay. Frequently small particles of metal adhere to the porcelain. If a pointed instrument fails, use a discarded bur, but in larger inlays small quantities of adhering metal will make no difference in any way. The inlay is now tried in place, having the cavity wet, which helps the porcelain to blend with the natural tooth, and at this stage the patient should be shown the results, for at a later period the cement and drying of the tooth make a change not always satisfactory, but fortunately this is largely corrected by time.

The inlay is grooved or undercut by wheel disks such as hard-rubber, corundum, or copper coated with diamond dust. An additional retention is secured by using hydrofluoric acid. This acid has a great affinity for all vitrified surfaces, therefore great care is necessary that the outer and finished surface is thoroughly protected, and the most simple method is to soften the surface of a small piece of paraffin or beeswax, and embed the inlay face

downward. Then cover the exposed surface with a few drops of the hydrofluoric acid, and after about five minutes wash with a spray of water.

The use of acid for this purpose is very common, and the tendency to carelessness is sometimes checked by a bad burn, which is always

Fig. 326

painful and very slow to heal. After the inlay has been subjected to acid, it should be soaked in alcohol, which will soften the white scale, which is removed by scraping the surface with a sharp instrument, and thereby give the cement a better attachment to the roughened surface. This is a point not generally considered, but it is reasonable and practicable, and many small inlays have been lost through non-observance of this fact.

Fig. 327

As the inlay is now ready for inserting, the tooth is dried and protected from moisture either by napkins or rubber dam. The latter is preferable, but not necessary, provided the operator can use a napkin properly. Successful inlays depend upon perfect adaptation and cementation, but frequently the operation is spoiled through carelessness or a desire to hurry the case to a finish, therefore too much stress cannot be placed on this important part of the work. The cement, the shade of which should approximate that of the tooth and inlay, must be mixed thoroughly, be of creamy consistency and of medium to slow setting quality. Apply it to the cavity with a small spatula tip, then gently press the inlay into position, wipe off excess with spunk or tape, and note the line of demarcation. If this is satisfactory, hold the inlay in position until the cement has commenced to harden, then protect from moisture by covering with melted paraffin, wax, sandarac varnish, or chlora-percha. If the inlay is extensive, it can be ligated with floss silk or held by a wedge, always avoiding the use of excessive force, or the delicate porcelain edges will shatter.

Fig. 328

A later sitting is required for a final finishing, for the best of inlays will need smoothing of edges, which is done with small stones or sandpaper disks and strips.

MAKING INLAYS BY THE INDIRECT METHOD.

While the majority of porcelain workers are satisfied that the best results are to be obtained by working directly on the tooth from start to finish, it is claimed by others that results equally as good may be had by swaging, or by what was originally known as the water-bag process, introduced a few years ago by a London manufacturing firm.

The system has some ardent supporters who claim that by it the presence of the patient is needed only for the impression and the finish of the inlay, the rest of the operation being done in the patient's absence and by a laboratory assistant if so desired. The claim is plausible, and from the fact that many dentists use this process, it is worthy of consideration.

Dr. F. T. Van Woert is an ardent supporter of this form of operating, and in an article on this subject says: "The essentials necessary for securing an accurate impression of any cavity are (1) suitable trays; (2) proper impression material; and (3) a knowledge of its manipulation.

"The material for trays which has given me the most satisfaction is sheet platinoid of 32, 34 and 36 gauge, because it has a rigidity, together with more pliability than any other metal that I have been able to find. Another very good quality, while not essential, is that it has a finely finished surface, which at least has the appearance of being clean, and is pleasing to the patient. The second requisite is the impression material, and while it is a matter of opinion, personally, I prefer that made by the Detroit Dental Mfg. Co., because it softens at a lower temperature, sets quicker, and when cold is as hard if not harder, and gives a very much sharper definition of detail than others I have tried. After forming the tray, a suitable quantity of compound is heated, the tray held over the flame until it is hot enough for the material to adhere to it, and the compound then pressed into a cone-shaped mass with the fingers and then chilled. The surface of the cone should be held in a small flame, so that it is quickly heated to the point of running, and then forced into position, and either compressed air or cold water used for setting it.

"I find it a great advantage in large cavities in molars and bicuspids to force between the tray and adjoining tooth the blade of a thin cement spatula to bring up a sharp line at the cervix. This is easily removed after the chilling, and facilitates the removal of the impression as well.

This is frequently advantageous in approximate cavities of the anterior teeth also.

"**Method of Making Amalgam Models.**—If we have succeeded in securing an accurate impression, it is only the beginning of a successful ultimate result, and the next procedure, that of making the model, requires as careful consideration and manipulation as any part of the technic. Various materials have been recommended for this purpose, all of which I have given a most careful and impartial trial, and I am forced to the conclusion that there is but one reliable material, and that is a good amalgam. When I say 'a good amalgam,' I mean one having good edge strength, as little shrinkage as possible, and the property of setting quickly, although this is not essential. I use the standard alloy made after one of Dr. Black's formulæ.

"First the impression must be embedded in plaster to a sufficient depth, and with enough body surrounding it to permit of pressing the amalgam well down into the impression. The amalgam is then mixed with enough mercury to make it very plastic, and this is burnished into place with suitable instruments until the impression is filled. Then the excess of mercury can be eliminated by folding a piece of rubber dam several times, and placing it on the amalgam and pressing upon it with the thumb.

"The mixing of the amalgam is one of the most important points in the procedure. In my early efforts I tried to fill these impressions as I would a cavity in a tooth, and the force required in burnishing it to place invariably marred the impression which resulted in an imperfect model of the cavity.

"**Advantages of Impression Method.**—If we succeed in getting an accurate model, a filling made to fit it must fit the cavity which it represents. This being the case, let us consider the advantages to be derived from the impression method: first, we are none of us so perfect in any branch of our art that we are not liable to make mistakes. Second, it is beyond question that we all have many accidents that are just as deplorable as the mistakes we might make, and when such happen in the direct method of making inlays, we are obliged to acquaint our patients with the fact that we have erred, or met with a misfortune in the form of an accident, either of which is humilitating to the operator and frequently exasperating to the patient, and, occasionally, to such an extent that the patient loses confidence and seeks service elsewhere.

"We will take, for example, porcelain restorations. In the direct method, where the matrix is burnished to the cavity, which, by the way, is a much more tedious operation than that of taking an impression, we have confronting us the possibility of some distortion in its removal, or, perhaps, in the handling after it has been successfully removed, as

well as the possibility of warping in the fusing of the porcelain itself. There is still further the difficulty which arises in many cases of securing a suitable color, or just the proper form of contour, all of which is a large combination of defects which remains to be explained to the patient.

"The impression method eliminates all of these difficulties. In the first place, the matrix is secured by swedging the gold into the die with the Brewster press (Fig. 329) and the swedged matrix is less likely to change its shape when removed than the burnished one. The shape of the swedged matrix can be retained by filling it with a hard wax; it is then removed and invested, and later the wax washed out. Should the filling prove a failure, another, or several others, if necessary, can be made without the patient's knowledge; and where the question of color or contour is liable to cause trouble, several fillings, varying from a light to a dark shade, can be made; or if it be a troublesome contour, several of different shapes, so that when the patient presents, the suitable filling can be selected without subjecting him to another or several operations, and without the unnecessary loss of time to the operator.

"**Cast-gold Fillings.**—The same procedure is applicable with cast-gold inlays, with the exception that the wax filling is fitted to the tooth, as described by Dr. Taggart, omitting the final carving of detail in bite and contour which should be done to the die. If the die is correct, the wax filling will go to place without difficulty; but one is surprised to note the little defects in the filling, such as here and there a small point where the wax has not conformed to the sharp edge of the cavity margin. This is due to the lack of resistance at such places; the wax being of one temperature throughout its entire body, it is forced by the occlusion from inward out, and on a line with the cavity margin. It may be said that this defect can be remedied by running a hot spatula around the line, but I have found this extremely difficult, particularly at the cervix. It is also claimed that such defects may be corrected by burnishing the gold casting after it has been cemented to place. This has proved just as difficult and unreliable in my hands; and it is a potent point that these difficulties do not exist when cast fillings are made from the impression and amalgam model properly constructed."

SWAGING THE PLATINUM MATRIX.

The cavity is prepared as described for the usual method, edges square, margins strong, and without undercut. Talcum powder is rubbed into the cavity and on the adjacent surfaces.

Then an impression is taken in cement. This is invested in plaster of Paris, and the surplus cement which extended around the tooth on

both sides of the cavity is trimmed away to about one-sixteenth of an inch from the margins. Additional cement is then mixed to a very stiff consistence, the fingers being dipped in talcum powder and the cement



Fig. 329

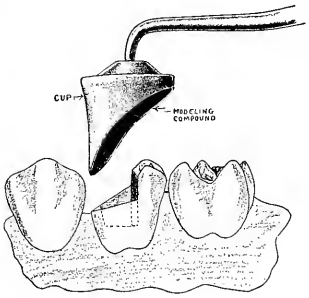

Fig. 330

well kneaded. The first impression is surfaced with talcum, and this second mix pressed into the first one and allowed to stand until quite

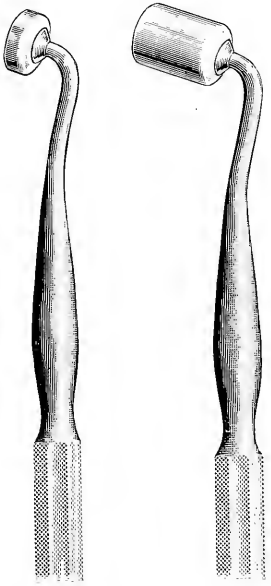

Fig. 331

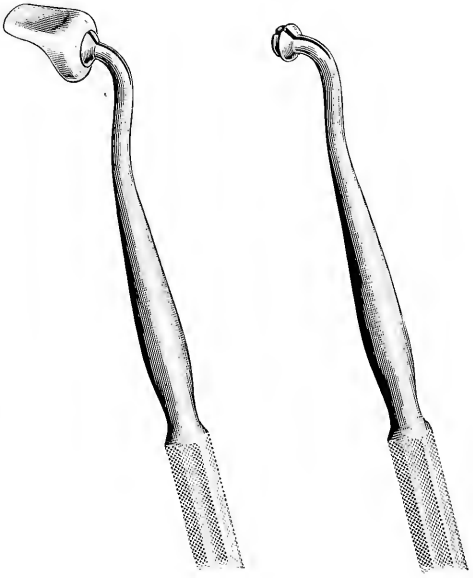

Fig. 332

hard. Then separate and invest this second impression or model in one of the steel cups, in plaster, or, if preferred, in one of the very shallow cups, in cement or sealing wax. Invest so that the center is slightly

higher than the edges of the cup. When the plaster is hard, place a square piece of platinum (one one-thousandth of an inch thick) on the cement model. With pledgets of cotton wool press the platinum down into the cavity; put into the swager, with a water bag over the wool, and swage. Remove from the swager and burnish out wrinkles or folds; then anneal well in the furnace, replace on the model and re-swage with water bag, but without the wool. Reverse the press handles, remove the cup from the cylinder, and examine the matrix. If any wrinkles or folds still remain on the margins, they must be burnished out; and if the matrix does not appear to be perfectly adapted to all parts of the cavity, it should be again annealed and then subjected to harder pressure in

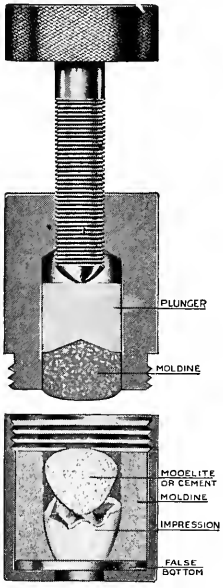

FIG. 333

the swager. Any crack in the matrix at the bottom or near the bottom of the cavity will not affect the fit of an inlay.

In building in the porcelain where the cavity is a large one, first grind an "inlay rod" to fit tightly across the matrix at its widest part; surround this, except upon its upper surface, with foundation body; and when it is quite dry, bake. Keep the foundation body sufficiently away from margins to allow for the thickness of enamel body necessary to produce the desired color. When baked, return to the model, and if baking the foundation body has caused any change in the fit of the matrix, the next swaging will correct it. After this last swaging proceed to fill in the enamel body. Lay the dark shades in first and bake;

then add the lighter colors necessary to finish. The foundation body first baked in the matrix will prevent any change of form during the baking of the enamel body.

The press should be screwed to the bench. The solid rubber is for swaging heavy metal cusps and also for inlays. Should a water bag break, carefully dry out the cylinder and plunger. Do not allow any rust to accumulate in the cylinder. The inlay rods above mentioned are made of high fusing material and are of assistance in large contour work by other methods.

The most recent appliance for this process is the Roach model press with trays which are cut to form of cavity and are recommended for bicuspids and molars (Figs. 330, 331, 332 and 333).

FUSING PORCELAIN.

For many years there was much controversy regarding the qualities of various products, particularly between the advocates of a high heat porcelain and those of low fusing qualities. While this question is still debatable, it is an indisputable fact that in America porcelains of the higher grade have the preference. This may be from the fact that the manufacturers of artificial teeth in this country have always used a high fusing material, and as the product has stood the test of time, it is only natural to apply this argument to the inlay question.

English tooth body fuses about 400° F. lower than the highest fusing American body, which places the English on our list as a medium fusing material, and its excellent quality is indisputable; in fact, the majority of our inlay bodies fuse at a medium heat, ranging from 2150° F. to 2300° F., therefore the difference between this fusing degree and that of low body of 1600° F. or thereabouts is the point of argument.

When porcelain inlays were introduced, the standard material was the continuous gum bodies then well known to porcelain workers and put on the market for their use. It was the only material to be had, and while it possessed the required quality, it had no variety of shade. After some years this was remedied, and the advent of the pyrometer enabled us to learn the approximate fusing temperatures of the old continuous gum bodies which were found to be about 2300° F. These bodies have not been much improved upon either in quality or finish. The first low fusing material was introduced in 1892 by Dr. Downie, but was not satisfactory for inlay work because of its poor shades, although it was quite extensively used for crowns. A few years later Ash & Sons made up a small assortment much improved in shades. Dr. Jenkins introduced his low fusing enamel in 1898. After this

date manufacturers of porcelain produced an assortment suitable to all circumstances.

The wearing qualities of various porcelains are practically equal in certain positions, notably in cavities not extending to incisal edges or masticating surfaces, and in shallow labial cavities. Low fusing porcelain has an advantage from the fact that its opacity prevents the cement from changing the shade, which is frequently the case with a high fusing and more translucent body.

Workers of higher fusing porcelain will be more or less conversant with all porcelains and their variations, because this field is greater and has practically no limitation; but a low fusing porcelain worker is usually at sea if not using that material, while anyone accustomed to the higher heats can fuse the lower, provided care is used not to overheat. Too much heat is fatal to low fusing body, as it means not only loss of shade, but also loss of strength. The same rule applies to all porcelains, but not to the same extent if the porcelain is high fusing, for its working latitude is much greater. Low fusing material is usually molded in a gold matrix which is invested. Platinum must be used as the matrix for higher heat porcelains, and no investment of it is necessary.

As pyrometers are commonly used, a list of the most popular bodies, and approximate fusing points will assist the student, bearing in mind that these figures are based on two-minute tests, with conditions favorable for accuracy.

Low fusing.
Ash & Sons, 1550° F.
Jenkins, 1550° F.

Medium fusing.
S. S. White's Medium, 2100° F.
Ash & Sons' "High," 1900° F.

High fusing.
S. S. White's Inlay, 2300° F.
Close's Continuous Gum, 2300° F.
Whiteley's Inlay, 2200° F.
Whiteley's Inlay special, 2400° F.
Consolidated Inlay, 2600° F.
Johnson & Lund's, 2500° F.

It is generally conceded that fusing porcelain is one of the greatest difficulties that must be overcome before the novice can feel that he has made any advancement toward the successful making of an inlay or anything in which porcelain is the component part. It is an indisputable fact that this part of the work is a veritable stumbling block, and the cause of much discouragement which is only overcome by persistent practice, for without this necessary knowledge successful results are not possible.

Porcelain may have a fusing point as low as 1600° F., and varying to 2600° F. or even higher, therefore the operator must become familiar with these varied heats and their productions. This will mean contin-

uous application and training the eye to the various stages and changes of the material. Using a timepiece with a pyrometer will be of great assistance, but the personal equation is always the dominant factor, and herein lies the difficulty of giving directions that will be accurate under all conditions. Before the advent of the pyrometer the eye was the only test of heat, therefore to the beginner this device has considerable value, together with the fact that the fusing points of the numerous porcelains are known. Thus a certain time by the watch with the fusing point of the porcelain already known and the pyrometer showing the temperature, the fusing of porcelain seems comparatively easy. Various sizes of porcelain require different heats, therefore it is absolutely necessary to know porcelain in all its changes, without any assistance whatever, otherwise the work will be either over or underfused, and only by chance will it be correct if the machines are depended upon entirely. There can be no difference of opinion on this fact, therefore the best equipment is the personal knowledge which makes one independent of any appliance or set of rules and regulations. It is generally contended that exposing the eye to such severe changes of light is injurious, and this may be true beyond a certain point, viz., 2300° F., a temperature sufficient for the majority of our porcelains. There is a product by a well-known firm which requires a heat of 2600° F., and there is no doubt that the eyes should be protected from the glare of this heat, which is unnecessarily high, especially for inlay work.

As electric furnaces are most commonly used for fusing porcelain, it is not very difficult for the student to become familiar with the various changes of heat as regulated by the rheostat, and thereby know what step will fuse a certain known product. For instance, the first step on the majority of furnaces will fuse a low fusing body of 1600° F. in probably one minute or even less, but the same heat will fuse a much higher porcelain if given longer time. Then again, voltage must be considered, for in many cases it is only approximate, sometimes varying three or four points less or that much more, and still coming under the class of 110 volts direct. This fact is particularly noticeable in local establishments such as office buildings. The alternating current is usually more even, that of 220, however, being very strong and harder on the furnace muffles.

The best fusing is obtained by inserting the porcelain at the lowest temperature and gradually and slowly raising the heat until the fusing point is obtained, thus passing the material through its various stages of condensation. These stages are called "biscuiting," and a porcelain partially fused may be called a medium or hard biscuit. In the latter condition the porcelain has a half glaze and has shrunk to a solid mass

and is ready for the additional material required to give form. Then the porcelain can be fired until it has the finished gloss, which is determined by the eye of the manipulator. The best results are always obtained by underfusing the first bake, because several high heats will overfuse the groundwork which reduces its strength and solidity. Using a porcelain of slightly lower fusing point the finishing will obviate this tendency, which is detrimental to the whole work.

As an instance of this, note a manufactured tooth which is finished in one baking, and the same directions are applicable to carved teeth for special cases. A student will readily learn the proper glaze required if he will take any plain or plate tooth and apply porcelain to its surface and watch the various changes until his material has reached the same condition. This simple experiment will also help him to recognize the heat required for these changes and ultimately enable him to acquire self-confidence in the management of the fusing process.

Porcelain.—Porcelain bodies made for inlay purposes are to be had in great variety, both in fusing point and texture; in fact, there is such a number for choice that the unexperienced must necessarily be bewildered.

However, this difficulty will settle itself like many others that may at one time have been just as perplexing.

FURNACES.

The advancement in the matter of furnaces has been so rapid that less than thirty years ago the user of porcelain depended on such an apparently crude appliance as is shown in Fig. 336 (old coke furnace), and yet the beautiful porcelain dentures and carved work of the older dentists have not been surpassed.

It was early recognized that a small, quick heating appliance was a necessity, and this difficulty was solved by Dr. C. H. Land by inventing the first gas furnace in 1886. This machine, while a great improvement, was slow and tiresome, as the constant use of bellows was necessary for half an hour before the furnace was hot enough for use. A smaller and quicker gas furnace succeeded this, more applicable for inlays and crowns, and was successfully used until superseded by electrical outfits, which have the advantage of cleanliness, purity, and noiselessness.

A gas furnace is noisy and gives much trouble in carbonizing the porcelain, or as it is usually termed "gassing." Fortunately, that is a discouragement of the past, for electricity has reduced fusing cares to the minimum. Other furnaces of that time were the Parker-Stoddard, Downie, and Fletcher.

FIG. 334.—Custer No. 1, for crown, bridge and inlay work.

FIG. 335.—Custer, No. 2, for crown, bridge, inlay and continuous gum work.

Dr. L. E. Custer invented the first electric furnace in 1894, and while it was a distinct improvement, there was much trouble in muffle wires burning out, which caused much delay and retarded the general



Fig. 336.—Old style coke furnace.

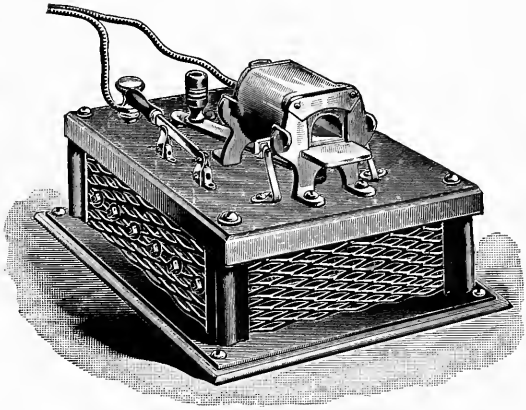

Fig. 337.—The Hammond furnace No. 1.



Fig. 338.—S. S. White furnace with pyrometer attachment.

use of this class of furnace. The Custer electric furnaces (Figs. 334 and 335) as now perfected are practically useful and are strong favorites. Five years later the Hammond was patented, and immediately became popular from the fact that a "damaged" muffle could be replaced immediately.

This furnace has remained a favorite until the present time, but is being gradually replaced by the S. S. White Co.'s new furnace (Fig. 338), which is similar, but improved in certain details, and it is also arranged with pyrometer attachment.

In 1902 the Pelton appeared. Besides these furnaces there are several others distinct in form, and all, with few exceptions, have a pyrometer attachment. They are: the Fletcher, Peck, Gerhardt, and Roach, and others including the Price, which has been withdrawn, although Dr. Price was the first to apply the pyrometer.

In addition, furnaces are also made for gasoline use. The principal types are the Turner and Brophy. They are of great value to the out-of-town dentist, because they not only fuse porcelain, but have equal facility in blowpipe work and metal heating, thus enabling those not possessing gas or electricity to be practically on the same footing with the city practitioner.

PRODUCING PROPER COLORS IN PORCELAIN INLAYS.

The pigments most commonly used in the manufacture of dental porcelains are precipitated gold and platinum, purple of Cassius and the oxids of gold, titanium, manganese, cobalt, iron, uranium, silver and zinc. The colors produced by the use of these pigments in varying proportions are red, yellow, blue, green, brown and gray. Red is not used extensively by inlay workers. All gum enamel frits are tints of red. It may be used in the manufacture of browns and grays, also to build the gingival portion of many inlays.

Yellow.—Yellow is the most important color for the porcelain worker. It is used to form the body of most inlays; it adds brilliancy to the browns or grays when combined with them. Yellows of a greenish hue tend to lose their luminosity in yellow light. Two yellows, in their deeper tones, may match each other perfectly, but when diluted to give lighter tints, may differ quite widely. One may be of a greenish hue, while the other may tend toward a grayish.

Blue.—This color is used to build the body of the incisal or occlusal portion of inlays for those teeth with blue incisal edges or cusps. There is a variation in tone from greenish blues to those of a reddish hue. Blues of a greenish hue appear to be more translucent.

Other Colors.—Green is seldom used alone, it may be added to blue to increase its translucency. Browns are used to build the gingival portion of some inlays and for the body of inlays for discolored teeth with a brownish hue. They may be added to yellows to modify them. Grays are used to build the middle and incisal or occlusal portions of many inlays. They are also used to tone yellows and blues.

Shading.—This part of making porcelain inlays is the most difficult to the majority, and is an uncertainty with all of us. The problem of shrinkage is an unknown quantity, and its remedy is purely mechanical, but the problem of shading is a combination of various considerations which may be followed most minutely and then the object may be defeated by some detail not always possible to avoid, and this most common defect is caused by the opaque cements. The most experienced have this discouragement, but it can be decreased by using a variety of shades and matching carefully. We have and can mix an almost endless variety of porcelain shades, but this is only a part of the requirement, for position and tooth density must also be considered, together with quantity of porcelain to be fused. There is also the additional difficulty of correct fusing to reproduce the desired shade.

Overfusing is the cause of more shade failures than any other, but practice will largely obviate this trouble as in other difficulties. The most careful directions are inadequate as compared with actual demonstrations. After all has been said, there is still the possibility of failure to appreciate this phase of the work, because this part of it appeals directly to the artistic sense, and can only be comprehended through observation and experience.

The difficulty of obtaining colors that accurately match the natural teeth is a part of inlay work which will always be perplexing, for the teeth are largely composed of organic matter, while the material used for repair is an inorganic composition, differing in texture and density. When selecting the colors for inlays, note the various shades of the natural tooth, for frequently there are three or more. If the tooth is vital these hues have a distinction which is lost after devitalization, thus increasing the difficulties of matching, but if the variant and uncertain hues of the pulpless tooth are once reproduced in an inlay, the subsequent change attending the cementation is not so marked because of the pulpless tooth opacity.

Position of the inlay is a factor which largely governs the shade, for the shadow problem is an incident which forces consideration also. This is particularly evident in proximate cavities, aud is remedied to some extent by making the inlay a shade lighter, and is also controlled by the size of the inlay. A lateral incisor being much smaller than a cuspid must be treated accordingly, for the density of the latter is much

greater and will allow a deeper shade. Labial inlays, particularly bordering the gingival line, can safely be made a shade deeper; but due consideration must be given to depth, for if very shallow, the porcelain should be of greater density and thus overcome the cement change. Inlays of this kind are improved in texture by using nearly all base body, and in some instances low fusing porcelain is more effective because of its less translucency.

With one exception all inlay porcelains are of the same texture from base to finish, which is an advantage in the instance just cited, but the introduction of a combination consisting of a basal body to be covered by enamels was a step toward procuring more natural results in the majority of cases. This basal body represents the dentin, which in turn is covered by a more transparent material representing the enamel, thus enabling the operator to blend the various hues of shade of which the natural tooth is composed, thereby producing a translucent effect not possible by one dense porcelain no matter how expert the operator may be.

The restoration of an incisal tip or corner is an operation that requires much practice and artistic skill, for its prominence demands perfect shading and adaptation. An operation of this character, while testing the ability to shade, has the advantage of not being affected by the cement line because of greater proportion or volume of porcelain. However, perfection must not be expected because there is always the difference between the natural translucency of tooth structure and the unavoidable density of porcelain which in certain positions is more noticeable by the deflection of light rays.

A common mistake in shading is in not considering the difference between the volume of shade exposed on the porcelain shade guide and the quantity required to fill the cavity.

The mixing of several shades to gain the one desired is largely one of intuition, because that shade cannot be known until properly fused. This difficulty is unfortunate, but cannot be avoided, as all porcelain powders are practically the same, with the exception of a few extreme shades, and herein lies the difference between the porcelain artist and the painter whose pigments are mixed and the desired shade revealed to the eye by simple manipulation.

CEMENTS AND MANIPULATION.

It is generally conceded by porcelain operators that while a material of this kind is almost an ideal filling, it falls short of the ideal because we are forced to use as an attachment a substance detrimental to that

aim which we have in view, namely, the absolutely invisible restoration of tooth form.

What cement do you use? is an ever-present query in all porcelain discussion, for when there is a failure the cement is generally blamed for it. This is a natural deduction when it is considered that a student in porcelain is more familiar with cement than with other parts of the operation, and if there is a failure it is a natural supposition that it is caused by poor material. A cement must be tenacious, finely ground, and not quick setting, and of a quality most likely to resist moisture when setting, for it is not always possible to keep the work free from dampness during that important stage. There are many cements manufactured that have these requirements, and, like other materials with similar merits, the choice rests with the operator. They all have the same disadvantage, viz., opacity, and the perfect porcelain operation cannot be claimed until the attaching medium is transparent, or nearly so. A common trouble is mixing cement too thick, thus preventing proper seating of inlay, which makes the joint conspicuous and unfinished. When this occurs, quickly remove and cleanse every part thoroughly, replacing with a thinner mixed material.

As already stated, a filling of porcelain can be made perfect in shape and shade and the texture may approximate tooth substance in a highly satisfactory manner; but immediately upon attaching it permanently the shade is changed through the differences between the three substances, all of different density, which come in close contact, namely, porcelain, cement, and tooth. The cement being the chief point of difficulty, it is important that its objectionable features should be reduced to the minimum.

It is a poor cement that is not at least preservative. Many cements are similar in manipulative qualities with the difference of slow, medium and quick setting tendencies. Some are coarse and others are fine, and a few have a combination of many good qualities but with that tendency to "pack" under pressure which causes annoyance to porcelain workers. A cement closely ground, of clear color and medium to slow setting, having the maximum adhesiveness with the least amount of powder, is what is recommended for a successful operation; add to this one that has the greatest amount of resistance to moisture during what is usually called the "setting" period.

Shading a cement to match the tooth, or to lighten or darken either the porcelain or tooth, or both, is quite bothersome at times and disappointing also. It is of considerable assistance to mix pellets of cement of a variety of shades and mount them in the most convenient manner to allow of comparison, in that way saving much time and avoiding guess-work. Whenever possible use the deepest yellow because pure

calcined oxid of zinc is quite yellow, and its chemical combination with phosphoric acid is more complete than when otherwise changed.[1]

For instance, a white or very light yellow is made so by oxid of zinc, thus reducing the chemical union to a marked degree; and the same applies to darker shades, such as browns, blues, and grays. This is a point of some advantage in setting crowns and bridges, or whenever tenacity is a first requirement; for such purposes use the purest yellow cement just as it comes from the bolting cloth without the slightest manipulation whatever.

Some years ago there was invented by Dr. C. H. Land a material in the form of a paste or paint which is applied to that part of the porcelain intended for attachment, and which is then subjected to heat of about 2000° F., thus giving the porcelain a semi-vitrified surface composed of a substance which has a chemical affinity for cement and acts as a medium of attachment. This promises to be of most important assistance in many cases wherein strength is of first consideration. This material is called "Media" and is made for both high and low fusing porcelain, and will also be found of value in repairing facings of broken crowns and bridges. It is claimed that by its use added strength is given to porcelain, enabling the operator to extend the field of porcelain work to all masticating surfaces or other places where the strain is too great to use porcelain with cement as the only attachment. I am prompted to mention this article at this time, because I am interested in any and everything pertaining to this branch of dentistry that may seem to promote its advancement, and also because I have privately and publicly made tests sufficient to give confidence in its merit and convince me that its use will be general when once its advantages are known.

UNDERCUTS FOR RETENTION PURPOSES.

Undercuts are not necessary in the tooth cavities, but they are imperative in the filling for retentive purposes, and are made with diamond or hard rubber and corundum disks. The latter are made in such a variety of shapes and sizes that I think they are all that can be desired, for their cutting power is equal to any other and the cost very moderate. Some dentists claim that cuts in the porcelain are not necessary, as hydrofluoric acid will roughen the surface sufficiently to stand any strain and that cutting of porcelain is a source of weakness which is not occasioned by using acid. This may be so if the undercuts are made too near a wearing surface, but again experience is our test

[1] The reader is referred to the subject of cements, Chapter VII, for a further discussion of this subject.—Editor.

and that is much in favor of undercuts. In very small inlays acid can be used to advantage, and it cannot be a disadvantage to use it in connection with undercuts, but to stake your trust entirely on the use of acid is a mistake which will cause trouble.

The method of using it on very small inlays where an undercut is impossible, is to soften the surface of a piece of beeswax or paraffin and embed the porcelain, taking care not to have edges exposed, then drop a little acid on the exposed surface and allow it to act for a few minutes; then wash off with a water syringe.

Placing the porcelain in position is a part of this work that requires extreme care and frequently great patience. Care should be observed that the cavity is thoroughly dry before the insertion of the filling and kept dry until the cement is hard enough to resist moisture. Use alcohol freely in the cavity and on the filling; then apply hot air and mix the cement to a creamy consistence; this, when applied to the cavity walls, almost grows there, the affinity is so great. As quickly as possible place the inlay and gently press into position and hold until it becomes fixed. The excess of cement is removed by a small piece of firm spunk. In proximate work I use waxed silk, drawn over the surface gently working from center to edges, for in this way excess cement is easily taken from between the teeth, which, if left until hardened, may loosen the filling in removing it. It is risky to try to get everything clean, much better to leave the surfaces a little smeary. For protection against saliva the parts should be covered with a little hot paraffin. Rubber and sandarac varnish and chloropercha are used by some, but paraffin is the favorite because it is cleaner and has a blending effect which is quite an advantage at that time, for the tooth is lighter by the drying process and the cement has given the porcelain a more opaque appearance; so it is just as well that the patient should not be allowed to inspect the result too closely just after the insertion of the filling. The time to show it to the patient is before the tooth is dried; put the filling in its place and allow the saliva to be the cement for the time being. Frequently it is never seen to better advantage.

At a subsequent sitting the edges are touched with a stone, and the most expert operator will find this necessary, for the tongue will find an edge if he cannot. Fortunately for us, after a time there is a blending of the porcelain and tooth that is quite gratifying; but it is better to explain this to the patient, for some people are unreasonable enough to expect perfect results with very imperfect agencies. The difficulties besetting a porcelain worker are growing less each year because when a thing is demanded and that demand comes through confidence, then allowances are made which will assist the operator provided he has skill and is tactful.

Cementation of Inlays with Silicate Cements.—The attachment of inlays with silicate cement greatly adds to the beauty and completeness of the inlay, but its use is governed by certain conditions. This cement is not so adhesive to the tooth structure as oxyphosphate, therefore a decided undercut in the cavity is absolutely necessary. The silicate cement will adhere to the porcelain with small assistance and apparently has all the adhesiveness necessary in the cavity, but after a time, probably a few months, this tenacity is diminished, rendering an undercut a necessity. This condition is a reversal of the qualities of the older cements and may be remedied in the future, thereby overcoming the "cement line" objection. A porcelain inlay well shaded and adapted, then attached with a silicate cement, is a perfect restoration.

CHAPTER VII.

PROPERTIES OF FILLING MATERIALS.

By MARCUS L. WARD, D.D.Sc.

Introductory.—The chapter on properties of filling materials is written as a separate chapter in order not to break the continuity of thought that a student or practitioner of dentistry has when engaged in a study of the operations described in the chapters dealing with the practice of dentistry. This chapter is intended to be more a correlation of the more important data on the physical and chemical properties of materials used in the practice of dentistry than a treatise on practice. It appears to have been customary in former years to omit data of this nature from text-books on operative dentistry and to refer the readers of such work to text-books on metallurgy, which, in most instances, have not treated the subject with specific reference to operative dentistry. This practice on the part of editors seems to have become antiquated, for it has been tried long enough to have produced better results if it had possessed much merit. It is hoped, therefore, that the manner of treating the subject and the close promixity of the data in question to the data on the more practical part of dentistry will result in a better understanding of the materials that are in so general use. Gold is treated comparatively briefly because the use of all the available data on it does not seem warranted in a text-book on operative dentistry, and because students of dentistry usually receive more instruction on this subject than on most others. The subject of amalgam has included in it a discussion of the subject of manipulation because many of the properties depend so largely upon the manipulation. Porcelain has been omitted from the list of materials considered, primarily because the data concerning it are largely in the hands of the manufacturers and secondarily because the comparatively limited knowledge of the subject is well covered in Chapter V.

GOLD.

Gold is one of the first metals with which man became acquainted. As a result of this an appreciable amount of data has accumulated,

for from the first gold has attracted much attention because of its wonderful properties and intrinsic value. In the search for gold, men have endeavored to produce it by the transmutation of base metals, and in doing so have made many discoveries which have probably aided in laying the foundations for the science of metallurgy. It is doubtful if the metallurgy of some metals would have been as well developed if it had not been for the work done on gold. On account of the part it has played in the development of metallurgy, its intrinsic value and wonderful properties, gold has been termed the most noble of metals. A solid mass of pure gold is yellow in color, but when finely divided, as it is when volatilized, or when precipitated from solution it may be violet, ruby, purple or brown in color. Common examples of violet gold are seen when the oxyhydrogen blow-pipe has been used to melt gold for casting purposes, the gold having collected around the edges of the cold casting ring. Examples of brown gold may be observed in the various sponge golds in the market for the purpose of filling teeth. If a very thin sheet of gold be supported upon a glass plate, it appears green, on account of transmitted light. If the plate containing the gold be heated to 250° C. it will appear white, due to the formation of aggregates of gold between which the light passes. Various colored golds may be produced by alloying with other metals.[1]

Gold possesses a very high specific gravity. Schnabel[2] gives the specific gravity of gold as follows: 19.30 to 19.33 at 17.4° C. after it has been fused and cast. Rose[3] gives it as 19.33 to 19.34 when it has been compressed and 19.55 to 20.72 when precipitated by ferrous sulphate. Hoffman[4] lists gold along with other metals in a table to show the effect of rolling and hammering upon specific gravity. His figures are 19.25 for cast gold and 19.35 for hammered gold. The specific gravity of fillings made from foil varies between 14 and 18 for good operators.

The melting-point of gold is usually given by dental authorities above 2000° F. and by metallurgical authorities as 1063° to 1065° C. The most reliable authority, however, gives it as 1064.4° C. (1947.92° F.)

The approximate melting-points of the various gold products of the J. M. Ney Company are published by this company according to the table on the opposite page.

[1] For a discussion of this subject the reader is referred to the various works on metal coloring.

[2] Handbook of Metallurgy, vol. i.

[3] Metallurgy of Gold.

[4] General Metallurgy.

Degs. Fahrenheit.		Degs. Centigrade.
2200	Ney-Oro gold plate No. 3	1204
2100	Ney-Oro "elastic" gold	1150
2075	Ney-Oro gold plate No. 1	1135
1975	Ney's high fusing clasp metal	1080
1975	Ney-Oro gold plate No. 2	1080
1960	Ney-Oro casting gold "E"	1070
1945	Ney's pure gold (24 k.)	1063
1945	Ney-Oro casting gold "A"	1063
1940	Ney's green backing	1060
1900	Ney-Oro casting gold "B"	1035
1900	Ney's light 22 k. plate	1035
1825	Ney's dark 22 k. plate	1010
1800	Ney-Oro casting gold "C"	980
1735	Coin gold (U. S. standard)	946
1735	Ney-Oro casting gold "F"	946
1725	Ney's regular clasp metal	940
1675	Ney-Oro gold solder No. 84	915
1625	Ney's gold solder for 22 k.	885
1550	Ney-Oro gold solder No. 76	840
1525	Ney's gold solder for 20 k.	820
1450	Ney-Oro gold solder No. 68	785
1425	Ney's gold solder for 18 k.	770

The gold products of the S. S. White Company have approximately the following melting-points according to this company's statements:

Metal.	Melting-point. Degree F.	Degree C.
Plates and Wires:		
18 k.	1740	949
20 k.	1729	943
No. 1 clasp	1850	1010
No. 3 clasp	1760	960
Plates:		
18 k. light	1895	1035
Coin	1706	930
22 k. dark	1859	1015
22 k. light	1913	1045
Solders:		
For 14 k.	1360	738
16 k.	1441	783
18 k.	1470	709
20 k.	1521	827
Coin	1567	853
22 k.	1578	859

The boiling-point of gold at atmospheric pressure is approximately 2200° C. The volatility of gold is given by Schnabel as very little at 1045° C. and barely appreciable at 1075° C. He states, however, that at 1250° C. it is four times greater than at 1100° C. The specific heat, or ratio between the heat required to raise the temperature of water and metal 1° is given as 0.030 to 0.032.

Ductility, or the property of gold to extend by traction as compared with some of the common metals, is as follows: gold, silver, platinum, iron, nickel, copper, aluminum, zinc, tin, antimony. It is stated that one grain of gold can be drawn into a wire 160 yards long and can be

beaten into a sheet $\frac{1}{250000}$ of an inch thick. Schnabel states that Réaumur succeeded in producing a sheet 0.00000087 of an inch thick.

Malleability, or the property of being extended in all directions without cracking when rolled or hammered, is shown to be in the same position as ductility with the order of the other metals somewhat changed. It is as follows: gold, silver, aluminum, copper, tin, platinum, lead, zinc, iron, nickel.

The hardness of gold as compared with some of the other non-ferrous metals is given in hardness numbers on a Brinnell hardness testing machine as follows:

Copper	74.00
Silver	59.00
Antimony	55.00
Gold	48.00
Zinc	46.00
Aluminum	38.00
Tin	14.00

The hardness of gold and the principal alloys of gold in use in dentistry were recently tested with a Shore Scleroscope and found to be as follows:[1]

HARDNESS OF VARIOUS DENTAL GOLDS.

Each of the values is the average of ten readings on a Shore Scleroscope.

	24 k.	Ney's 22 k. L. C.	Ney's 22 k. D. C.	Ney's 20 k. plate.	Ney's 22 k. solder.	Ney's 20 k. soder.	Ney's 18 k. solder.	Ney-Oro "E" clasp metal.	S.S. White clasp metal.
Cast	4.9	5.5	12.5	18.3	25.4	33.8	59.8	25.4	37.9
Rolled	33.0	45.2	52.0	70.7	73.9	79.1	80.7	86.5	80.4
Annealed[2] after rolling	5.8	6.4	14.3	22.5	30.8	39.9	42.9	50.9	41.2

The hardness of a metal varies with the treatment given it. The hardness values of the common dental golds are shown in the table to be high when rolled or hammered, low when cast and somewhat between the two when annealed after rolling or hammering, with the exception of 18-carat solder. As a rule, metals are soft when cast and hard when rolled or hammered. Alloys, especially the more complex ones, do not follow this rule but may be either hard or soft when cast. A good example of this is shown in the softness of the clasp metals, which are soft when cast, and the 18-carat solder, which is hard when cast, both of which contain four metals. (See paragraph on annealing.)

The rate of cooling may cause the hardness of a metal to vary, and usually has a marked effect upon the hardness of alloys. The author recently subjected the various golds shown in the table to different

[1] These tests were made for this chapter by Marcus L. Ward and E. O. Scott.

[2] The annealing was done by heating to redness and quenching.

rates of cooling and found that the practice of dentists of heating to redness and quenching produced the results desired in the higher carat golds and solders, but as the 18 and lower carat solders and clasp metals were reached the results were very irregular. In fact, they were so irregular that it seemed inadvisable to publish them until they could be confirmed with further work. It seems, therefore, in order to obtain the desired properties from the complex alloys, such as the solders and clasp metals, that research work on cooling is necessary for each one of them and that instructions should be given for the cooling of such products.

The term hardness may often be taken as synonymous with strength. This is not always true, however, for the term hardness is used to express at least five ideas: resistance to scratching, to indentation, to elastic impact, to cutting and to permanent deformation, and the term strength is used to define resistance to at least five forces, as follows: forces which fracture, twist, pull, compress and change shape. A good illustration of hardness without toughness or proper resistance to all stresses is the hardness of the minerologist, as follows: showing ten minerals in the order of their hardness: talc, gypsum, calcite, fluorspar, apatite, feldspar, quartz, topaz, corundum and the diamond.

Metals or alloys which are as hard and brittle as these materials would be of little use in dentistry, for they would not resist the forces of mastication. Whenever the terms hardness and strength are used synonymously, therefore, it should be understood that strength implies both hardness and toughness.

Gold which has been hardened by rolling or hammering may be softened by annealing, which is usually done by heating the gold to redness and quenching in hydrochloric acid (50 per cent. or more) or in sulphuric acid of the same strength. The former is preferred by many for the reason that it is not so destructive to linen or clothing with which it may come in contact. It is not necessary to heat gold to redness in order to anneal it. It has been shown[1] that if gold is heated to 150° C. and held at this temperature for thirty minutes or longer it will become quite well annealed. Other metals may be annealed at comparatively low temperatures if the heat be maintained for a long time, and like gold will be annealed more completely and quickly with slight vibration in connection with the heat. The manner of annealing the complex alloys, as has been stated, is not known. Dentists usually give them the same treatment as pure gold, though it seems likely that investigation will show this practice to be

[1] Rose, Institute of Metals.

erroneous in some cases. In this connection it may be stated that Gulliver[1] and others refer to the hardening of steel by quenching and the softening of bell metal by the same treatment. When a pure metal is chilled rapidly from a molten condition about the only difference that is observed from the normal structure is the smallness of the grains. This is because the number of centers of crystallization have been increased. If, on the other hand, the metal is allowed to cool more slowly the centers of crystallization are fewer in number and the metal appears more coarse-grained. This, obviously, will alter markedly the physical properties of some metals and most alloys.

The tensile strength of gold is given by Hoffman as 37,000 pounds per square inch for hard-drawn wire and 24,000 pounds per square inch for soft-drawn wire. It is probable that these figures refer to unannealed and annealed drawn wire. Hiorns gives the tensile strength of gold as 7 tons per square inch, but does not state whether it is annealed or unannealed. It is strange that more work has not been done on the strength of gold. Perhaps the figures available are quite accurate. It appears, however, that they hardly represent the differences that should exist between the annealed and unannealed metal. It is not strange that compression tests have not been made on gold, for with gold as with many metals there is no definite crushing point under compressive stress, as is the case when metals are subjected to a tensile or traction test. When some metals are subjected to a compressive stress they simply spread when the elastic limit has been reached. Inside of this point they return to the original form after the load is removed. With other metals, however, and with some alloys, when the elastic limit is reached there is a definite breaking-point. Amalgams furnish a good example of the common alloys which have quite definite breaking-points and for which a compressive stress test is preferable to a tensile stress test.

Gold has a coefficient of linear expansion for 1° C. between 0° and 100° of 0.0000144. In general, when heat energy is added to a body its volume changes. Volume change is known as cubical expansion. In the discussion of expansion and contraction, however, one dimension is usually all that is considered. This is along a linear dimension of the body and is known as linear expansion. The coefficient of expansion increases with increases in temperature and is quite marked near the melting-point. It also varies with the physical condition of the metal. An operation which increases the density will also increase the expansion. It is a general rule that all metals expand when heated and contract when cooled. There are one or two exceptions, however.

[1] Metallic Alloys.

Copper, bismuth and antimony are among the metals claimed to expand while cooling. It is claimed that copper expands while cooling only under conditions which have been favorable to occlusion and dissolving of gases which are expelled during the cooling process. For bismuth and antimony, however, no explanation seems to have been made which would account for the phenomenon of expansion when cooling. Coefficients of expansion and contraction are for given temperatures only, for as the melting-point of most metals is reached the volume is decidedly increased.

Shrinkage being the reverse of expansion may be estimated by the expansion, as a general rule. Shrinkage, therefore, is very marked as the metal changes from the liquid to the solid state and corresponds to the expansion at other temperatures than the ones which bring it to a liquid state. It would be interesting to know the coefficient of volume change for gold at its liquefying point, for with the advent of the casting process into general use it is necessary to fill molds of every conceivable shape with gold or gold alloys in order to meet the demands of modern dentistry. The only research that has been done to determine the shrinkage of gold in casting it into molds would lead one to believe that it was about 2 per cent. The absence of some very essential data in connection with this work makes it of little value. It is probable, however, that the total shrinkage of gold from a state of fluidity which would permit the filling of a mold for a filling is somewhat above 1 per cent., depending upon the temperature of the gold when it is forced into the mold. Many operators make the mistake of casting gold at or near its boiling-point, at which the gold is in a very much expanded condition, and, consequently, must result in an excessive shrinkage.

Numerous theories have been advanced by practitioners of dentistry about the excessive shrinkage of gold under certain conditions. It is probable that too much heat has been used or the gold has been alloyed with something which results in excessive shrinkage. It should be remembered that the volume change of many alloys, especially the complex ones, cannot be calculated. *Metals* are subject to volume change from changes in temperature, but *alloys* have volume change from changes in temperature and from the reaction between the constituent metals which cannot be calculated.

Pure gold can be welded in a cold state. Ordinarily welding is accomplished by bringing the metals to a temperature that makes them pasty when the motion of the molecules is so accelerated that they interpenetrate or diffuse into one another when slight pressure is applied. In heating readily oxidizable metals it is necessary to exclude the air or use fluxes which will slag any oxids formed and form a somewhat

impervious coating. Inasmuch as gold does not oxidize under ordinary conditions, or have the ordinary contents of the air condense upon its surface, it may be welded in a cold state. There are certain gases, however, which do combine with and condense upon the surface of gold and prevent both cohesion and welding. The following are said to be capable of condensing upon the surface of gold to such an extent that its cohesion and welding are impaired: carbon dioxid, sulphur compounds, iodin, the various oils used in dentistry and other volatile substances. Chlorin is said to combine with gold sufficiently when condensed upon the surface in the form of ammonium chlorid to prevent cohesion and welding. It is claimed by some that, as a result of this action, ammonia has been adopted for condensation upon the surface of pure gold to make cohesive gold non-cohesive.

The thermal conductivity of gold is 53.20, copper being 73.60 and silver 100, according to Hoffman. The electric conductivity of gold has been given by Matthiessen as 77.96, copper as 99.95 and silver as 100, all of which were drawn metal. Cast metals are poorer conductors than those which have been hardened by drawing, hammering or rolling. Conductivity may vary with purity and temperature.

Gold in solid form is said to absorb gases when heated to redness and in spongy form at ordinary temperatures (Schnabel). Some other writers claim that gold is an exception to the general rule that molten metals absorb gases and does not absorb an appreciable amount. The conclusion that seems to be warranted is that the subject is not well understood at the present time.

Gold is not soluble in a single acid except selenic (H_2SeO_4). It is soluble in aqua regia on account of the chlorin available. Gold is readily dissolved by chlorin or any substance which yields chlorin. Gold may be precipitated by organic substances, several gases, most metals and by some metallic salts.

Gold does not oxidize either at the ordinary temperatures or at elevated ones. Two oxids of gold are claimed to exist, however, aurous oxid, Au_2O, and auric oxid, Au_2O_3. The former results when mercurous nitrate and neutral auric chlorid are put together or by treating aurous chlorid or bromid in the cold with caustic potash. The latter is obtained when auric chlorid solutions are treated with some alkaline substance. Gold is not acted upon by sulphur and sulphur compounds in the same manner as most metals are. With free sulphur it does not combine at all and with hydrogen sulphid it does not appear to combine except when the hydrogen sulphid is introduced into solutions of gold. Gold alloys readily unite with other metals, sometimes forming definite chemical compounds.

From the foregoing it is clear that gold is one of the most perfect of

the metals, but it is necessary to impart to it a greater degree of strength than it alone possesses, for the manufacture of jewelry, coins and many dental restorations.

Silver and copper are the metals most commonly used, and when used in small quantities do not alter very markedly the properties of gold. Copper seems to produce a greater change in properties than silver. The effect of alloying gold with 10 per cent. of copper to produce the standard coin is well known. The effect of alloying gold with silver is less well known, though it appears quite probable that in the future, as restrictions are placed upon the use of large quantities of gold in places where something else will serve quite as well, there will be created a new interest in alloys of gold and silver for many large castings. The difference in the effect of alloying gold with copper and silver is shown in the table of hardness tests. It may be seen that there is a marked difference in hardness between Ney's dark 22 k. gold and 22 k. light gold. The formula of each may be seen in the following list of formulæ[1] of gold plates in general use:

22 k. dark gold plate.		22 k. light gold plate.		20 k. gold plate.	
Gold	92.00	Gold	92.00	Gold	83.25
Silver	4.50	Silver	7.70	Silver	12.00
Copper	3.50	Copper	0.30	Copper	4.75

It may be noted that almost 8 per cent. of silver has made practically no difference between the hardness of the light 22 k. gold and that of pure gold. The slight difference in hardness shown is probably due to the very small amount of copper contained in this alloy. Silver and copper unite in all proportions and form a valuable series of alloys, having many applications in the arts. Whenever these two metals in the form of an alloy are combined with gold they seem to have a marked influence in hardening it, as may be observed by the tests on the 20 k. gold plate, which has considerably higher percentages of both copper and silver than the higher carat golds. The alloys of gold, silver and copper are also sufficiently tough to resist the forces of mastication when used in the quantities which are permissible, and are used in large quantities by dentists in the construction of crowns, bands, inlays and other restorations.

Zinc is also used to alloy gold in the production of solders for the operations which require the union of the various parts of restorations. The gold solders are designated as 22 carat, 20 carat, 18 carat, etc., as the case may be, which indicates the carat of the gold upon which they may be melted without loss of form of the gold plate. The following

[1] These and the following analyses shown for the various alloys of gold were made for this chapter by E. O. Scott during the early part of 1920 from alloys obtained from the market.

formulæ of three of these alloys show that they are not of the carat that they are named, but are intended to be used upon gold of the carat marked upon them.

FORMULÆ OF SOLDERS.

22 k. solder.		20 k. solder.		18 k. solder.	
Gold	84.00 parts.	Gold	76.00 parts.	Gold	68.00 parts.
Copper	7.50 "	Copper	11.50 "	Copper	14.50 "
Silver	5.50 "	Silver	8.50 "	Silver	12.50 "
Zinc	3.00 "	Zinc	4.00 "	Zinc	5.00 "

Zinc, like copper, lowers the melting-point and hardens the gold. The latter, however, seems to be the principal reason for the use of zinc in solders, for the former could be obtained with copper. Zinc also controls the color to some extent.

The formulæ of the solders given are correct for one manufacturer's product only. There are variations in the quantities of gold used by the different manufacturers. Some of them may reduce the quantity of gold for the purpose of reducing the melting-point, some may want to vary the color somewhat and some undoubtedly pursue this practice to lessen the cost of production of the solder. The following table shows the advertised fineness of three manufacturers' solders:

1		2		3	
Carat.	Fineness.	Carat.	Fineness.	Carat.	Fineness.
22	750	22	802	22	830
20	729	20	735	20	708
18	666⅔	18	656	18	615

The variations in the amount of gold used are likely to cause variations in the color of the solder and appreciable differences in the melting-points. It is generally safer, therefore, to use the same make of solder as the plate.

Platinum and palladium are used with copper and silver to alloy gold to produce hard and elastic alloys known as clasp metals. The following formulæ represent two well-known clasp metals in the market:

Gold	64.00 per cent.	Gold	63.25 per cent.
Platinum	11.00 "	Platinum	10.00 "
Palladium	16.50 "	Silver	19.35 "
Silver	1.50 "	Copper	7.40 "
Copper	7.00 "		

Other alloys containing gold, platinum, palladium, silver and copper have been recently introduced as desirable for casting fillings, crowns, etc. This class of alloys usually contains not less than 80 per cent. of gold, from 6 per cent. to 10 per cent. of platinum, about 2 per cent. of

palladium, 0.05 per cent. to 2 per cent. of silver and 2 per cent. to 9 per cent. of copper. This class of alloys generally has lower melting-points than either platinum or pure gold. They are said to be more fluid when melted and as a result enable the mold to be filled more perfectly than with other alloys.

NATURE OF AMALGAM.

An amalgam is a combination of two or more metals, one of which is mercury, and may be either a liquid, solid or semi-solid. The term amalgam is derived from the Greek malagma, from mallasso, to soften, the presence of mercury lowering the melting-point of such a mixture.

The term metal indicates a certain number of chemical elements which in the present state of chemical science are undecomposable and possess certain well-defined characters in common, such as opacity, luster, conductivity, high specific gravity and plasticity or capability of being drawn, squeezed or hammered without loss of continuity..

Comparatively few of the metals possess characters such as render them suitable to be employed alone by manufacturers, although there are many applications for most of them when two or more are caused to unite permanently. The compound thus formed by the union of two or more metals is termed an alloy. The word alloy is believed to have been derived from the French aloi (the metal of the standard coin), a contraction of a la loi (according to law). An amalgam, then, represents that class of alloys which contain mercury: the agencies by which the union of metals is effected are heat, electro-deposition, pressure at ordinary temperatures and the dissolving of one or more metals which exist in a solid state at ordinary temperatures in a metal which exists in a liquid state at ordinary temperatures.

Practically all alloys, except dental amalgam alloys, are formed through the agency of heat, but certain soft metals, such as lead, tin, bismuth, cadmium, etc., have been shown by Professor Spring, of Liege, to form true alloys under pressure and absence of heat. This process, however, has not as yet found application much beyond the laboratories, where it is used to demonstrate that there is actual union between the particles of different metals in the cold when they are brought into intimate contact. Certain alloys, such as gold and copper, or copper and zinc, may be prepared by electro-deposition. Several alloys are prepared by this method on a large scale.

The utility of dental amalgam alloys depends largely upon the property which mercury has of dissolving most other metals to the point of saturation, forming alloys which, when allowed to stand for some time, harden or set. This hardening or setting process is probably

due to the formation of a chemical compound between the mercury and one or more of the metals used in combination with it. The mass thus formed of metal or alloy in combination with mercury cannot be regarded, however, as a true amalgam, for Matthiessen has pointed out that such a mixture may be either a chemical compound, a solidified solution or a mixture of all three.

There are some phenomena, such as change in volume, change in strength and evolution of heat that lead to the belief that definite compounds do exist in definite proportions by weight. Most of the metals used to form the alloy which is combined with mercury to form an amalgam are capable of existing in a state of chemical combination, although they are subject to Matthiessen's classification, and are usually united by feeble affinities, for it is necessary, in order to produce energetic union, that the constituents exhibit much dissimilarity in properties. There is little doubt that some of these metals do unite in definite proportions, although it is difficult to obtain them as such since the compounds thus formed dissolve in all proportions in the melted metals from which they do not differ very widely in their melting-points. For these reasons it has been questioned whether not only amalgams, but any alloy were a true chemical compound.

Definite compounds have been proved to exist, however, in both the native and artificial states. Hiorns[1] has given a good illustration of a chemical compound between two metals in the alloy of copper and tin which may be represented by the formula $SnCu_2$, containing 38.4 parts of tin and 61.6 parts of copper. A well-known native chemical compound of two metals is represented by silver and mercury, which are found crystallized together in the following proportions: (Ag_2Hg_2 or Ag_2Hg_6) and (Ag_2Hg_6). Many other examples may be given.

Under the term solution of one metal in another we understand one like ether and alcohol, or any two substances which may be mixed in all proportions and will not separate into layers by standing. Solidified solution would indicate the solidification of a perfectly homogeneous diffusion of one body in another and has been represented by glass, which is formed in the liquid state at a high temperature and solidified on cooling without separation of the different silicates. Hiorns quotes Mendeleef as saying that solutions are fluid, unstable, definite chemical compounds in a state of dissociation, and that of such a kind are most metallic alloys. They have been considered in the *Journal of the Chemical Society* as solidified solutions of metals which contain definite compounds in excess of one of the constituent metals. The subject of solution apparently has a most important application in the production of dental amalgams.

[1] Mixed Metals or Metallic Alloys.

In the same manner that water dissolves saline substances, alcohol dissolves resins, ether dissolves fats, etc., mercury dissolves most metals. A very interesting phenomenon to observe in this connection is the manner in which most solvents act upon solids (Hiorns.) As a rule the dissolving power of each liquid is confined to a certain class of solids. It is also a general rule that the solubility of a body in any medium depends upon a similarity in the constitution of the body and the solvent.

When a liquid has dissolved all of a solid that it is capable of retaining at a given temperature it is said to have become saturated; but even if it be saturated with one solid it may yet take up another, and oftentimes that solvent power is thereby increased.

A general survey of the literature reveals quite a lack of knowledge of the peculiarity of solidified solutions and appears to explain to some extent why there has been so much misunderstanding connected with the use of amalgam. While it appears important that the subjects of solutions, crystallization and diffusion should be considered in connection with the formation of dental amalgams, it does not seem possible to make anything but general statements from the data available.

It seems to be generally accepted that when one or more metals combine with mercury to form a dental amalgam, when the mass subsequently sets and the final complete diffusion takes place the same agencies control ordinary chemical phenomena. External heat, for example, influences these phenomena[1] to a marked degree in some instances, it being considered that a rise in temperature of 10° C. will double the velocity of most chemical reactions. The conversion of chemical energy into heat may also influence these phenomena. The condition of contact between the mercury and metal or alloy will likewise have its influence upon these phenomena.[2] Internal movements of the component parts of the mass may facilitate diffusion, solution and chemical reactions. Vibration, in some cases, will do the same. In fact, about the only difference that appears between dental amalgams and most chemical reactions in regard to controlling factors is that the metals are united by feeble affinities, and there exists a tendency for the amalgam to possess the properties of the constituents. There are some cases where a combination is totally different from either constituent but the general effect is for each constituent metal to maintain its identity. Oftentimes two metals with like physical properties may be combined to produce a whole series of alloys which have the same properties as the constituent metals. On the other

[1] Arthur W. Gray, Director of the Caulk Physical Research Laboratory, Journal National Dental Assn., 1919, and Transactions of the American Institute of Mining Engineers, 1918.

[2] Ibid.

hand, if two metals with dissimilar physical properties be combined, the result may be a product quite different from either constituent depending upon the nature and arrangement of the eutectic.

The advantage in alloying metals, therefore, seems to be to assemble in one compound a number of properties which cannot be found in one metal.

Through the work of Flagg and Black, silver, tin, copper, zinc, and occasionally gold in small quantities have been found to possess more desirable and less undesirable properties than any other equal number of metals. Since the work of Dr. Black[1] two new but distinct classes of alloys have appeared as the principal products of nearly all leading manufacturers. One of them contains from 65 to 68 per cent. of silver, 26 to 28 per cent. of tin, 3 to 5 per cent. of copper, and $\frac{1}{2}$ to 2 per cent. of zinc. The other contains from 43 to 48 per cent. of silver, 48 to 58 per cent. of tin, and 1 to 2 per cent. of zinc. The first class is known as high percentage silver alloys, quick setting alloys, and Black's alloys, the three names being synonymous. The second class is known as low percentage silver alloys, slow setting alloys, and plastic alloys. Both classes seem to have grown out of Black's work, the latter class undoubtedly to the detriment of dentistry.

The first class seems to be based upon the properties of $72\frac{1}{2}$ per cent. of silver and $27\frac{1}{2}$ per cent. of tin, the most important of which is the small amount of shrinkage which takes place when this alloy is converted into amalgam. The second class seems to be based upon the dual movement of 50 per cent. of silver and 50 per cent. of tin, which, by referring to Dr. Black's[2] charts is seen to be about 2 points. Besides the two principal classes of alloys mentioned, there are in the market many of the alloys made and used previous to Dr. Black's work in 1895–1896.

Townsend's original alloy of silver 42 per cent. and tin 58 per cent. is still used by some.

Flagg's alloys, especially the one containing silver 60 per cent., tin 35 per cent. and copper 5 per cent., are still in the market and used by some.

There are a dozen or more alloys made to supply the varied demands of the profession. Some of them have one or more prominent qualities, but, as a rule, they are not free from a reduction in volume at the time of and subsequent to insertion, nor do they seem to be based upon any particular principle, as are the two classes which have resulted from Black's work. Inasmuch as these alloys are also composed of silver, tin, copper and zinc, they are subject to the same consideration

[1] Dental Cosmos, 1895–1896. [2] Ibid.

as far as physical and chemical properties are concerned. It would seem that dental amalgams are best understood by dividing them into the two classes spoken of as high percentage silver alloys and low percentage silver alloys. The difference between the two can probably be best represented by first considering the most important properties of each constituent.

Silver unites with mercury in definite proportions, and through its comparatively strong affinity for mercury and its large proportions it largely controls the setting. It tarnishes quite readily in sulphuretted hydrogen and soluble sulphids. It increases in volume when amalgamated. It increases edge strength, lessens the flow and because of its great tendency to crystallize and its property of going into solution in mercury slowly at ordinary temperatures it causes the alloy to amalgamate tardily and the mass to work hard.

Tin unites with mercury in all proportions at all temperatures, forming a weak crystalline compound. It retards the setting, decreases in volume when amalgamated, decreases edge strength, increases the flow, and imparts plasticity, thus causing the mass to work easily.

Copper unites with mercury with difficulty at ordinary temperatures, although in definite proportions it generally hastens the setting, increases edge strength, lessens flow, does not change appreciably in volume when amalgamated and is easily tarnished by sulphuretted hydrogen and soluble sulphids.

Zinc unites with mercury easily and in definite proportions, increases in volume when amalgamated, hastens the setting, increases edge strength, lessens flow, improves color and imparts a peculiar smoothness to the mass during amalgamation.

Gold when melted with the other constituents, as most of the present alloys are made, adds almost no desirable properties and adds one or two undesirable properties. It adds a little to the color and makes a very tough amalgam, but imparts a peculiar pasty springiness which makes it difficult to pack. There are some possibilities in the use of gold in small quantities, however, that are not fully developed and which may lead to a more general use of this metal.

From the nature of metallic alloys we may assume that certain proportions of these constituents enter into combination and other portions are simply in a state of mixture or solution. From the similarity of the metals we may assume that energetic union has not taken place, and, as a result, the portions united chemically are not expected to have properties diverging widely from their constituents.

Since solutions and mixtures generally possess the properties of their constituents, we would expect a compound of these metals to be quite largely the sum of the properties of its constituents. Such seems

to be the case with these alloys. A point to be observed in the consideration of these alloys is that one or two metals are used as the base of the alloy and the others as modifiers, the attempt being made to add to the properties of the basal constituents some of the properties of other constituents.

A consideration of the alloys now in use, with one or two exceptions shows that the selection of these metals and the proportions of each have been made with reference to their physical behavior, special emphasis being placed upon changes in volume, color and strength. Fenchel,[1] however, has studied amalgams from a different point of view. He has taken a break in the cooling curve of any liquid (including melted metals) to indicate a change in physical constitution, and from this traced the crystallizing curve of some of these alloys in increasing proportions to each other. He has studied the structure of these alloys microscopically as well as with reference to alteration in form, resistance to stress, specific gravity and electromotive force of currents set up in the mouth by different metals, all of which form a very valuable part of scientific literature. Fenchel's work may be said to follow more closely the chemical phases of alloys than the physical ones, while the work of others seems to be devoted largely to the physical properties.



A B C D E F

FIG. 339.—Test cylinders of amalgam prepared by amalgamating 6 gm. alloy. Cylinders A and B from low-silver alloy compress and crack. Cylinders C, D, E, and F from high-silver alloy burst explosively. Cylinders B and D, both packed under 400 kg. show difference in size of amalgam from same weight of alloy. D is 25 per cent. larger and 75 per cent. stronger than B. C, D, and E are packed under 141, 400, and 1131 kg. per cir. cm. respectively. Natural size 10 mm. in diameter.

It would appear that a clear understanding of the physical behavior of these alloys cannot be had without at least a working knowledge of their chemical behavior. For the present, however, our knowledge of alloys (the two classes mentioned) is confined largely to their physical behavior. The principal difference between the two classes of alloys should be obvious. The first, with more silver, less tin and some copper is stronger, more stable in form, more free from decrease in volume, though it works hard and sets quickly. The second, with

[1] For a study of Fenchel's work see his various papers in the Dental Cosmos,

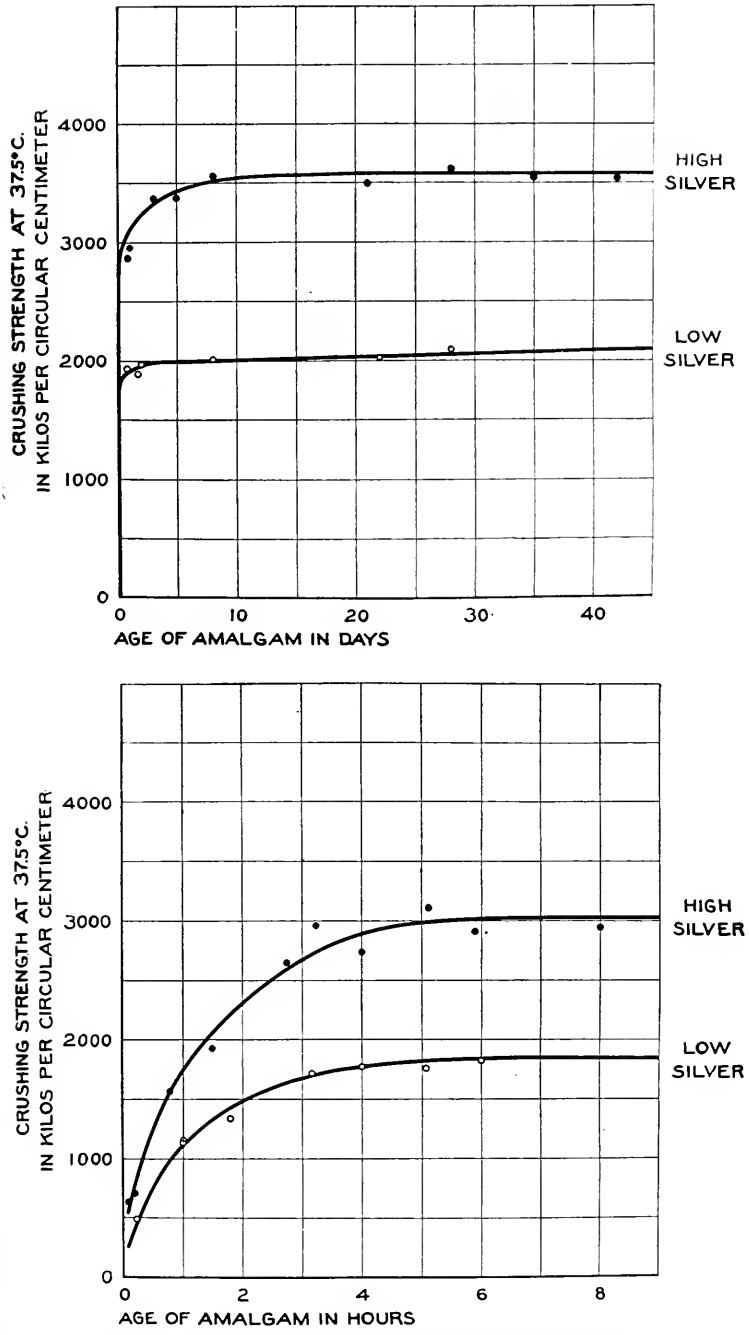

FIG. 340.—Hardening of amalgams. Amalgam from high-silver alloy is 75 per cent. stronger than that from low-silver alloy.

its high percentage of tin, low percentage of silver and absence of copper is easier to amalgamate, sets slower, is weaker and is a little lighter in color (Figs. 339 and 340).[1] [2]

These two classes of alloys resemble some of the older as well as many of the newer ones by having some properties in common.

Contraction and expansion, for example, seem to be phenomena accompanying the setting of all dental amalgams. Pioneer workers seem to have attributed these properties to the composition of the alloy. Later work showed that annealing the cut alloy had a marked influence upon change in volume. The most recent work has furnished additional evidence to substantiate the claims of the author in a former edition of this book that other things than composition and annealing of the cut alloy had their influence upon the phenomena accompanying the setting of dental amalgams.

The thoroughness with which this recent work has been done seems to have proved, beyond doubt, that many of the same factors which control the behavior of other alloys control dental amalgams. Prominent among such factors are: packing pressure, packing time, trituration time, mercury alloy ratio, size of the alloy particles, temperature at which the dental amalgam is kept and age of the amalgam. On account of the acknowledged inferiority of the low percentage silver alloys little or no data will be presented to show their behavior, it being assumed that a modern high-grade practice cannot be conducted by the use of these materials. What follows, therefore, has special reference to the high percentage silver alloys (Figs. 341 and 342).[3] [4]

It may be seen that the curves (Fig. 342 and curve 180, Fig. 341) agree in a general way with respect to the changes in volume that take place at the time and subsequent to the combination of the mercury and alloy in a high percentage silver amalgam. There appears to be a contraction at the time and immediately after the combination of mercury and alloy has taken place, which is followed by a slow expansion. This is followed by a still slower contraction which, if the alloy be properly made, brings the volume of the amalgam to approximately the point of beginning. Earlier workers have failed to note the first movement of dental amalgams on account of the use of instruments not suitable for this work, and have, in many instances, failed to detect the final slow contraction.

This manner of manipulation to produce this typical reaction curve is described under the chapter on Manipulation of Amalgams, with the possible exception of the pressure used in packing. In Fig. 341, curve No. 180 was packed with 100 kg. per circular centimeter, No.

[1] Arthur W. Gray. [2] Ibid. [3] Ibid.
[4] Souder and Peters: Dental Cosmos, March, 1920.

178 with 400 kg. per circular centimeter and No. 181 with 1600 kg. per circular centimeter. It remains to be proved that the pressure used in the production of the typical reaction curves is not more than

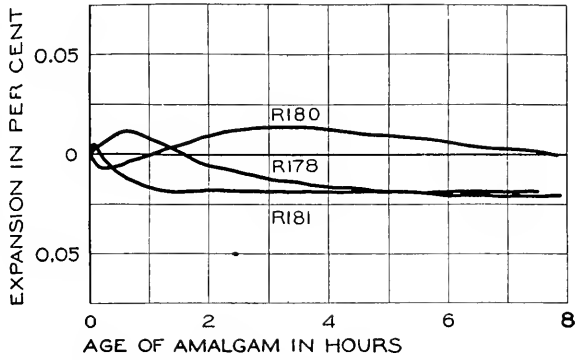

FIG. 341.—Typical reaction expansion curve (R180) and modifications caused by increase of packing pressure.

is used in practice if the movements represented by these curves are to be taken as indicative of what takes place in practice. There seems to be no doubt but that they are quite accurate and furnish a valuable lesson for those who have been inclined to ignore the packing pressure as a factor in modifying the behavior of dental amalgams. It may

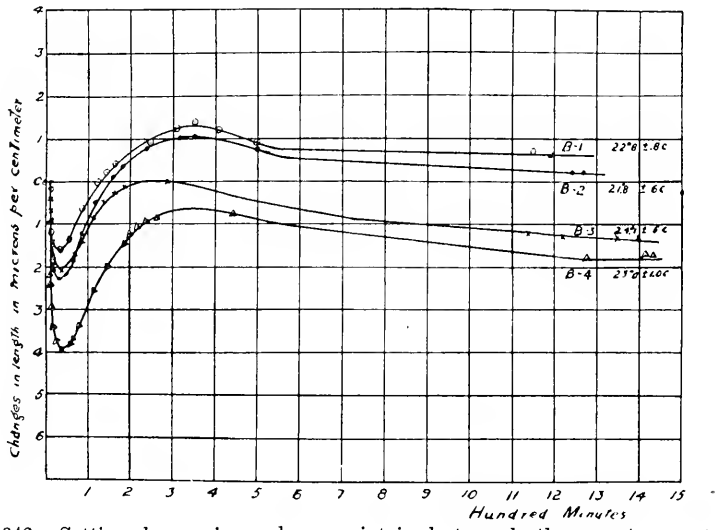

FIG. 342.—Setting changes in amalgam maintained at nearly the same temperature.

be noted that in curve No. 178, where the packing pressure was raised from 100 kg. to 400 kg. there is no initial contraction shown, for the reason that the increase in the pressure has hastened the reaction to

such an extent that this movement has taken place before it could be detected or possibly during the mixing of the alloy and mercury. Curve No. 181 shows the slow expansion that we formerly thought took place in an hour or two to have taken place during the first few minutes, due to a further increase in the packing pressure from 400 kg.

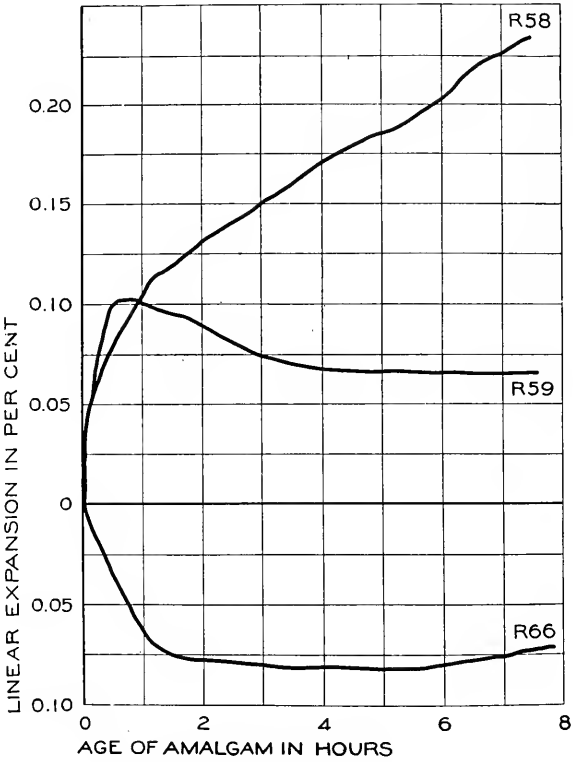

FIG. 343.—Effects of changing size of alloy particles.

to 1600 kg. and consequently a further hastening of the setting. While it is true there is less mercury retained in a mass of amalgam (Fig. 343) as the pressure is raised, these and other data that are available appear to show that increases in pressure hasten the reaction between alloy and mercury and, as a result, change the reaction curve of volume change. This should be expected, for it is well known that as combining substances are brought into more intimate contact the more rapid will be the reaction.

It has recently been demonstrated that continuing the pressure longer than usual will produce somewhat the same result as increasing the pressure, though undoubtedly to a less extent. Increasing the trituration time (see Mixing Alloys) of alloy and mercury also has to

do with condition of contact and has been demonstrated to accelerate the reaction of the alloy and mercury up to a certain point where setting begins. This will likewise change the reaction curve. In a similar manner the rate of reaction may be modified by varying the percentages of mercury and alloy for this, too, may modify the condition of contact.

Still further data on modification of the reaction curve by varying the condition of contact between the reacting substances are contained in Fig. 343,[1] which shows the results of amalgamating three different sizes of alloy particles.

Curve R58 represents the reaction that took place from the use of alloy particles that were too coarse to pass through a sieve of 48 meshes to the inch. Curve R59 shows the reaction when alloy particles that would pass through a sieve 200 meshes to the inch were used and R66 when still finer particles were used. By comparing these curves with the typical reaction curves (Figs. 341 and 342) it may be seen that as the alloy particles were made progressively finer the reaction was accelerated and characteristic features appeared earlier and more prominently.

It is well known that as heat is increased, molecular activity is also increased, resulting in accelerated chemical reactions and increased solubility of some substances for others. Not until recently, however, has this been recognized as having its influence upon the reaction between mercury and alloys with which to produce dental amalgams. It does not appear that the temperature of amalgam fillings inserted by the dentist can be detected and controlled, hence this factor in volume change is not of special interest to him. Those who are doing experimental work, such as comparing different products with delicate instruments for detecting changes in volume, may observe marked differences in the reactions that will take place at freezing temperatures and temperature of the body.

It has not been customary for those familiar with the behavior of dental amalgams to mention the age of the amalgam when descriptions of changes in volume were given. Notwithstanding this custom it has been known for many years that amalgams changed in volume and that this change in volume did not all take place suddenly. By referring to Fig. 341, it may be seen that Gray shows changes in volume at the end of seven hours and Souder and Peters (Fig. 342) show changes at the end of twenty-five hours. The author has repeatedly found these changes to continue over a period of several months when the amalgam was packed with hand-pressure and the mass has been incompletely mixed, as is often done in practice. If, therefore, the

[1] Gray, Arthur W.

amount of volume change that accompanies the setting of these amalgams is to be given, the age should also be given, for it is of little value to know that an amalgam expands or contracts a certain number of points unless it is known whether the figures represent the total volume change or only a portion of it.

From the foregoing it seems established that there are several ways that one who makes a dental amalgam filling may vary its volume change. The two factors of most importance, however, are composition and the annealing of the cut alloy, both of which are under the control of the manufacturer of these products, the former entirely and the latter to a marked degree.

With Flagg's work as a basis, Black seems to have established sufficiently accurately for practical purposes the contraction and expansion ranges for the metals that appear most suitable for the production of alloys for making dental amalgams. He assumed that of the properties which amalgams possess, nothing was of as much importance as freedom from contraction. He regarded it as imperative that there must be absolute freedom from contraction and only a minimum of expansion. With this view of the situation he constructed more accurate instruments than had been used previously and made numerous experiments to determine not only the metals but the proportions which would yield such an amalgam as the one referred to.

He concluded that an amalgam could be made that would lie absolutely still while hardening. Later workers,[1] [2] [3] with more delicate instruments than those used by Black, seem to have demonstrated (Figs. 341 and 342) that none of the amalgams now in use are entirely free from change in volume.

In describing his experiments, Black[4] stated that a fixed formula was not good for general use on account of inability to get metals which are chemically pure at a price that was permissible for the production of these alloys for amalgams. He and those who followed his teachings claimed that a general formula might be adopted for a given batch of metals, and then it was necessary to experiment with this batch of metals by varying this general formula in order to get a product that would lie still.

Some reputable manufacturers declined to accept this view and claimed their products were made from fixed formulæ. Inasmuch as the claims of the adherents to a fixed formula have not been disproved and their products appear to show the same behavior as the products that are said to be made from a plan instead of a fixed formula, it appears more reasonable to believe that fixed formulæ will yield given results provided the technic in production is properly controlled. Since

[1] Souder and Peters.
[2] Gray, Arthur W.
[3] Ward, Marcus L.: Dental Cosmos.
[4] Operative Dentistry, vol. ii.

nothing has been written by Dr. Black or his followers about the manner of preparing these products nor the character of the impurities that silver, tin, copper and zinc are said to contain, it appears likely that inability to produce fixed products from fixed formulæ was due to inability to maintain fixed conditions in the process of production. A review of Fenchel's work and the earlier work of Kirk and Burchard, each of whom has viewed more closely the chemical phases of alloys, would not suggest the plan offered by Black.

The question, "Why does a fixed formula not give an alloy with a definite volume change," has been asked of the author so many times by teachers and practitioners alike, that it would seem that the plan suggested by Black has not been understood nor accepted by the profession. All seem agreed, however, that the plan gives as good results, and furnishes the profession with as good alloys, as our present knowledge of the subject will permit. It is in the manner of reaching the result that there seems to be a difference of opinion. The plan implies more than the mere assumption that impure metals will not give a definite change in volume. It implies that metals cannot be constantly obtained with a degree of impurity, for if a metal contained a certain impurity in certain quantities every time it was purchased, allowance could be made for it in the formula.

While, as a rule, native metals are not to be relied upon, there are some instances in which impurity can be determined and allowance made for it comparatively easily. It is quite sweeping in its scope, however, to say that refined metals cannot be obtained which are quite constant in their impurities.

The author made analyses of three high percentage silver alloys within the last year, which were, in his opinion, most widely used and most accurately made, with a view of further confirming his opinion that more than one formula will give practically the same volume of change provided the formula selected lies within the ranges given for a high percentage silver alloy. They are as follows:

No. 1

Silver	68.00	per cent.
Tin	26.00	"
Copper	5.00	"
Zinc	1.00	"

No. 2

Silver	67.00	"
Tin	27.00	"
Copper	5.00	"
Zinc	1.00	"

No. 3

Silver	67.00	"
Tin	27.00	"
Copper	5.00	"
Zinc	1.00	"

By comparing these analyses with the many published formulæ contained in dental literature it may be seen there is a much nearer uniformity in composition than existed about ten years ago. Repeated analyses of the first alloy, however, have shown a constant tendency to contain more silver than most alloys in the market, though the volume change seems to be the same under the same conditions of manipulation.

There appears to be one thing of special interest in the three analyses given, namely, the uniform use of zinc in small quantities. Within recent years a very few manufacturers have eliminated the zinc entirely, apparently on the basis of some of the last words from Dr. Black on the subject of amalgam, which seem not to have been substantiated by experimental work. Dr. Black stated that 0.05 per cent. of zinc was not desirable, for the reason that amalgams containing it would continue to change in volume for five years or more. Determinations for zinc in alloys for amalgams have been made by the author on several of the best products now in use, with affirmative results in most cases showing that the judgment of a large majority of the manufacturers is in favor of the use of zinc in small quantities, in order that their products will be more free from contraction and more permanently light in color. The few who manufacture so-called high percentage silver alloys without any zinc are not known to possess modern instruments for detecting changes in volume, nor are they among those who have published anything with respect to the effect of using zinc in alloys except that Dr. Black advised against its use in his latter days.

Since Dr. Black is supposed to have approved of the use of zinc in his earlier days of experimentation, and practically all of the best products in the market (the high percentage silver alloys) have been based upon its use, the placing in the market of the same alloys without the zinc has caused some controversy. Both participants to the controversy claim to have products made according to Black's plans. Those who use no zinc claim to have a product that is more free from expansion, while those using the zinc claim to have products more free from contraction. The author has studied this problem for some time and has had hearty coöperation on the part of some of the most able manufacturers as well as advice from the Bureau of Standards on instruments for detecting changes in volume. As these studies have proceeded it has become more evident that if an alloy for a dental amalgam is to have a minimum of contraction it must contain from $\frac{1}{2}$ per cent. upward, not exceeding 2 per cent. of zinc. Reference to the analyses given shows the judgment of three large, reliable, and, in the opinion of the author, most capable manufacturers, which is that about 1 per cent. of zinc should be used.

The other known factor in changes in volume, annealing the cut alloy, is of special interest for the reason that to a small degree it is controlled by the dentist, though it must be kept in mind that this variable is controlled largely by the manufacturer.

Annealing of Alloys.—Dr. J. Foster Flagg seems to have been the first to call attention to the fact that alloys which were freshly cut behaved differently when amalgamated than the same alloys did after they had stood for some time. Dr. Black traced the phenomenon through a great number of experiments and finally arrived at the conclusion that the cut alloy is hardened by the violence in cutting, the condition thus produced being analogous to the condition of the same metals in hammering. His earlier observations led to the belief that motion brought about the change, but later experiments showed that it had no influence. Oxidation was thought to be a factor, but was finally eliminated as one of the causes. After a great many experiments it was proved that the change was produced by annealing or tempering, that is, a molecular alteration of the cut alloy. The temperature at which this is produced ranges from room temperature upward. If the alloy be subjected to room temperature for a year or more the same effect is produced as when it is subjected to a higher temperature for a shorter time. It has been found that the low temperature and longer time of exposure bring about a more complete annealing. The change can be brought about by subjecting the cut alloy to the temperature of boiling water for about twenty minutes, although there is not quite the same quality to the alloy that there is when it is subjected to a temperature of 120° F. for from two days to a week. The amount of heat required to bring about the change is not the same for all alloys, although each formula seems to change in many of its properties with this treatment. That the property of these alloys to change by so-called ageing or annealing is a physical phenomenon, has been the opinion of Dr. Black and of Fenchel,[1] but whether it is caused by hardening during the cutting process, as suggested by Dr. Black, is a question worthy of consideration by those interested in the cause of this peculiarity.

It is well known that the working of metals forces their molecules into unnatural positions, and that by annealing they are largely restored to their normal state. But it is also well known that the rate and manner of cooling of many metals may preserve in some cases and alter in others the mode of existence of the molecules at the time they were molten. It is also worthy of note in this connection that unequal stresses are set up in some castings by cooling the outer layers of the

[1] Dental Cosmos.

metal much more quickly than the interior, thereby causing a compression of the interior by the outer layers.

By annealing, which is the reverse of hardening, the metal flows, and this tension is relieved. The effect of annealing upon changes in volume appears to reduce the amount of expansion of alloys which expand and to increase the contraction of those which contract. Its effect upon the strength of amalgam seems to be to increase the strength of those which set very quickly up to a certain point, after which it seems to decrease the strength somewhat. It does not appear to have the same effect upon the strength of amalgams made from low percentages of silver. Whether or not these alloys are not hardened as much in their production cannot be said definitely. It seems, however, that practically all alloys for amalgams are hardened to some extent in their production in one way or another and the annealing restores them to what appears to be their natural condition. The makers of high percentage silver alloys for amalgams recognize that these products are in a different physical condition after annealing, and as a result of the change produced by the annealing arrange the formulæ for these products so that the properties desired are obtained after the annealing has taken place. This procedure is necessary for the reason that annealing of these alloys takes place at room temperature and upward. If, therefore, the change that takes place in the annealing had not been provided for by the maker, and if the annealing had not been given to the alloy by the maker, the practicing dentist would very often have an alloy for amalgam that would vary in the results it would give.

Another interesting phenomenon brought out by annealing is reduction in the percentage of mercury required to make a plastic mass of alloy and mercury. When the high percentage silver alloys are freshly cut they set so quickly that it is almost impossible to add enough mercury to keep the mass plastic for longer than a very few seconds. As annealing takes place the mass sets more slowly and less mercury is required to make the mass of alloy and mercury plastic. As much as 70 per cent. of the mass of alloy and mercury must be mercury before annealing takes place if the alloy used be a high percentage one, while after the same alloy has been fully annealed 50 per cent. will be sufficient.

This makes four ways that annealing is known to have an effect upon the final result: (1) upon change in volume; (2) upon strength; (3) upon the rate of setting; (4) upon the percentage of mercury to make a plastic mass.

Some of the makers of these products take advantage of the annealing to control the rate of setting and place upon the market alloys for

amalgams which are marked rapid setting, medium setting, and slow setting. Present knowledge of the subject leads to the conclusion that this practice is not likely to produce the best result for the reason that annealing also controls, to some extent, volume change. It appears more likely that this practice is followed in order to produce, without adopting the other alternative of altering the formula, alloys with different rates of setting for those who want the mass of alloy and mercury to set quickly enough to enable it to be polished to some extent at the time of setting.

Thermal Expansion.—Until very recently no data were available to show the relation of amalgam to other materials in common use in dentistry with respect to the expansion that takes place when a substance is heated, and the contraction when cold is applied. The following chart[1] has been prepared recently to show how some of the more common materials behave in this respect:

TABLE I.—AVERAGE EXPANSION COEFFICIENTS. RANGE 20° TO 50° C.

Material.	Expansion. Coeff. x 10^6
Tooth (root)	8.3
Tooth (across crown)	11.4
Tooth (root and crown)	6.4
" "	8.7
" "	8.3
Synthetic porcelain	7.1
" "	8.1
" "	7.5
Amalgam H	26.4
C	25.0
K	22.1
P	24.5
A	25.4
B	28.0
L	24.8
C	25.0
C	24.7
C	28.0
Porcelain (Bayeux)	4.1
Gold	14.4
Platinum	9.0
Silver	19.2
Mercury (linear)	60.6
Zinc	29.2
Tin	22.3
Copper	16.8
Gutta-percha	198.3
Aluminum	23.1
Steel	11.0

NOTE.—The above expansions are tabulated as amount of expansion, in microns, for a specimen 1 mm. in length, when heated 1° C., *e. g.*, amalgam C will change 25 microns per meter per degree; or, in terms of a specimen 1 cm. long (the approximate diameter of a molar) the expansion is 0.25 micron per degree = 2.5 micron per 10 degree range = 12.5 microns per 50 degree range, etc.

[1] Souder and Peters.

Strength of Amalgams.—Strength of alloys indicates those properties by which alloys sustain the application of force or strain without yielding or breaking, and may be considered under two heads, namely, crushing resistance and flow. Crushing resistance is that property by virtue of which alloys resist force without fracturing, while flow is that property by virtue of which they resist force without change in shape.

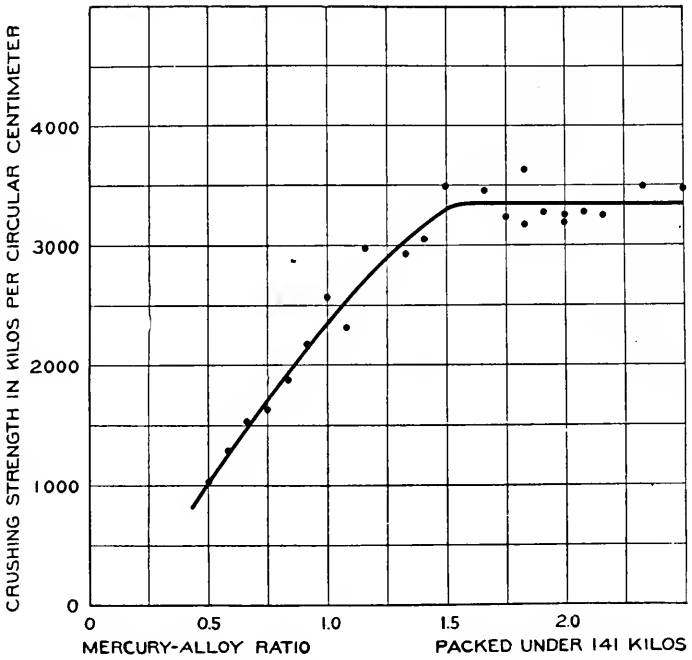

FIG. 344.—Effects of varying relative amounts of mercury and alloy that are mixed together in making an amalgam.

Crushing resistance of dental amalgams may be treated (1) as a property of the alloys used to form amalgams, and (2) as a property of the amalgam mass. The crushing resistance of the alloys from which dental amalgams are made seems to be controlled primarily by the composition of the alloy, and secondarily by the annealing and possibly by the process of alloying and chilling. It should be obvious that as the percentages of silver and copper are increased, strength will be increased, other things being the same. Tin being a very soft metal, will decrease the strength as the percentage is increased, other things being equal. The effect of zinc on strength seems to lie between tin and silver and copper. The crushing resistance of amalgam prepared from these alloys presents not only the same phenomena as the alloys,

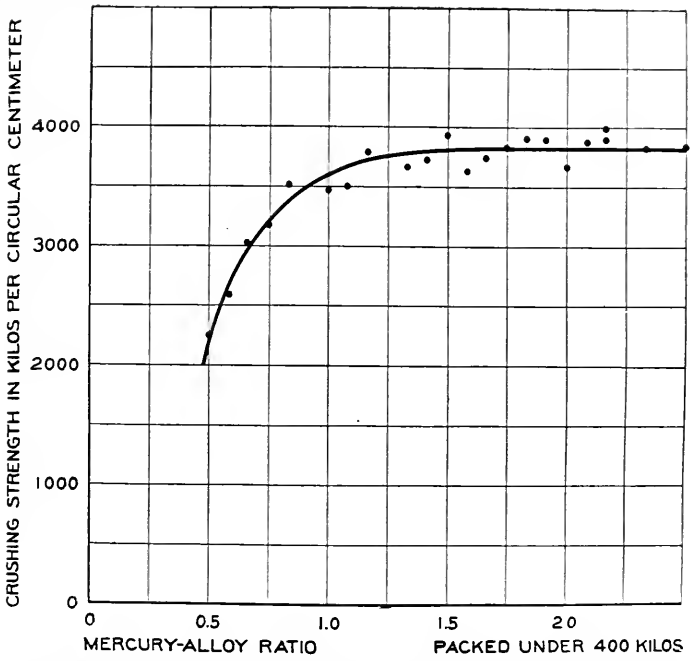

FIG. 345.—Modification of Fig. 344, produced by increasing packing pressure from 141 to 400 kg. per cir. cm.

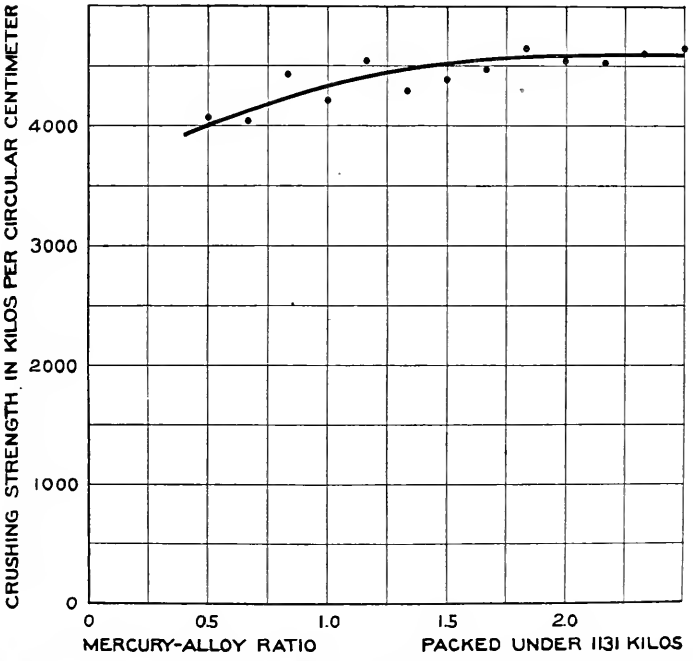

FIG. 346.—Modification of Figs. 344 and 345 by further increase of packing pressure to 1131 kg. per cir. cm.

but the additional complications arising from the union of the mercury with the alloy, and the conditions under which these alloys are combined with mercury in the practice of dentistry.

Gray has shown (Figs. 344,[1] 345[2] and 346[3]) that as the pressure in packing is increased from 141 kg. to 1131 kg., the crushing resistance in circular centimeters is raised from 800 kg. to 4600 kg. There seems to be no doubt that the variations in the pressure used in packing amalgam in the great variety of places where this material is used in the practice of dentistry result in similar variations in strength.

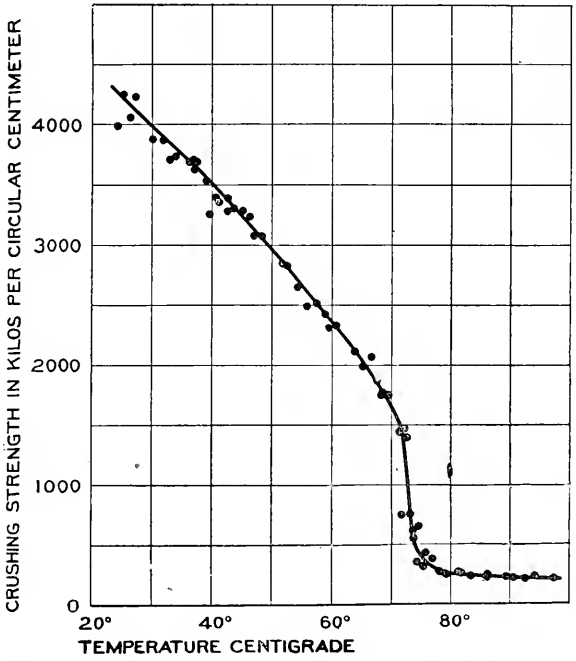

FIG. 347.—Effect of temperature on crushing strength. Transition region shown by the rapid fall in strength between 70° and 80°.

The same writer has shown that the temperature of the amalgam when it is subjected to stress has a marked influence upon its resistance to force (Fig. 347[4]).

When this feature of the behavior of amalgam was first published it was questioned somewhat on account of the comparatively low temperatures used for the tests, but as the work was checked up by experiments it seemed to be no more cause for surprise than was the discovery of the low temperatures at which alloys for amalgams would

[1] Gray, Arthur W. [2] Ibid. [3] Ibid. [4] Ibid.

become annealed. As this is compared with the various processes in nature which are known to be going on at equally low temperatures, and with the known behavior of other materials at different temperatures, it seems strange that other investigators had not observed this phenomenon before. Hadfield, Dewar and Le Chatelier[1] and others have investigated the tensile strength and elongation of copper at temperatures varying from −182° C. to 530° C. and found that the tensile strength was approximately six times as much at the former temperature as it was at the latter. They found the elongation was approximately three times as much. The tensile strength of aluminum has likewise been studied[2] and found to be much less at elevated temperatures. Several alloys of commercial interest have been studied with similar results. There seems to be so much similarity between the apparent behavior of amalgam at different temperatures and what is known about the behavior of other metals that the phenomena shown in Fig. 347 will probably be accepted. It is possible, however, that the curve shown by Gray will be modified somewhat for the reason that the 400 kg. per circular centimeter pressure used in making the fillings for the tests seems somewhat higher than is permissible in practice. When metals have been worked in the cold state or have been subjected to high pressures their decrease in strength is more rapid as the temperature rises than in those which have been cast and allowed to cool. From this it seems likely that the curve shown may be modified to show a little less rapid change in crushing strength with rise in temperature.

From the beginning of the use of amalgam it has been recognized that the time devoted to trituration of the mercury and alloy had a marked effect upon the strength of amalgam. With comparatively simple instruments for the purpose of detecting differences in strength, teachers and practitioners alike have been able to show that fillings could be made to show little or no strength when there had been little trituration of the mercury and alloy, and that as the trituration time was increased, the strength increased rapidly to the maximum. With this knowledge of the situation, the author carried on an appreciable number of experiments to determine approximately, at least, how much trituration was necessary in order to develop the maximum strength of amalgam and stated in the former edition of this book that it required from three to five minutes, depending upon the rapidity of the operation. It should be obvious that one operator may leisurely triturate the mercury and alloy while another may work rapidly and as a result accomplish double the number of units of work. Recently

[1] Law, E. F.: Alloys and Their Industrial Application. [2] Ibid.

the matter of trituration time has been given further consideration and found to be approximately as previously stated. It may be noted that Fig. 348[1] shows that the trituration may be carried on for six minutes before the incipient setting begins to show a decline in the crushing strength. Since the amount of annealing that was given the alloy used for the tests and the rapidity of the operator are unknown, it appears to the author there is a possibility that the person who triturated the mercury and alloy for these tests worked a little slower than the one who made those for the author and as a result did not

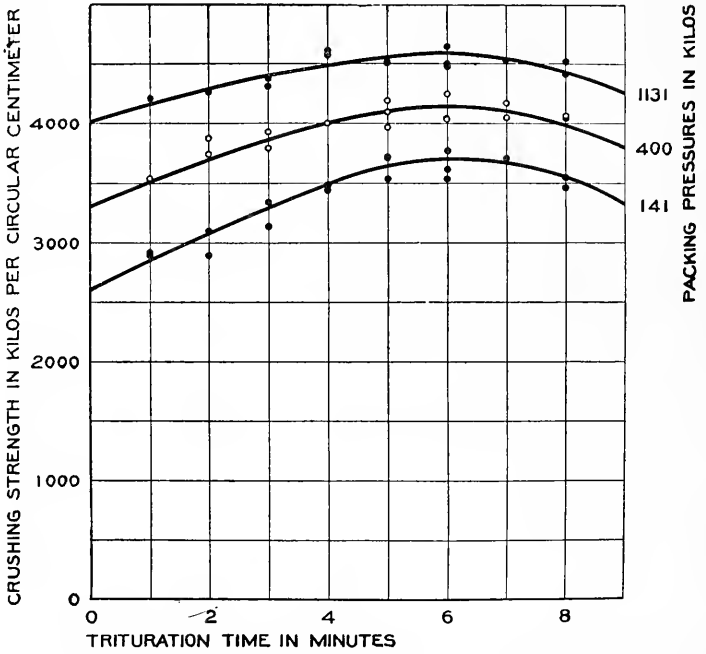

FIG. 348.—Gain in crushing strength produced by increasing trituration time.

reach a stage in the setting of the mass where the decline begins quite so soon.

It seems quite probable, therefore, that six minutes is the maximum time that will bring out the maximum strength. It should be kept in mind in this connection that if the maximum time has been devoted to trituration, the packing must be done very quickly. Inasmuch as this is not always possible in the practice of dentistry, it is questionable whether it is advisable to triturate the mercury and alloy which have been fully annealed for a longer time than four and one-half or five minutes.

[1] Gray, Arthur W.

In arriving at accurate conclusions with respect to the strength of amalgams it is assumed that the proper proportions of mercury and alloy have been used. If in one instance too little mercury has been used there will have been too little alloy dissolved in the mercury, and the mass when set will be comparatively weak. If, on the other hand, too much has been used and it has been left in the mass, the filling will be comparatively weak, due to the presence of more mercury than is necessary to react with the alloy used. By referring to Fig. 344, it may be seen that the maximum strength is obtained when about 1.6 per cent. of mercury is used. It may also be seen that no further increase of strength was observed by further increasing the percentage of mercury and that the pressure was sufficient to remove the excess of mercury, for no decline in strength is shown as the proportions of mercury reach 2.5 per cent. If in this case the pressure had been low there would have been a decline of strength shown, as excess mercury was retained in the filling.

It seems to be generally accepted that the age of a filling should be given when statements regarding strength are made, for it is well known that strength begins to develop as the setting progresses. Inasmuch as the reaction curves previously given seem to indicate continuations of the setting process that begins as soon as the alloy and mercury begin to combine, it is to be expected that variations in the strength will follow variations in the reaction curve. It may be noted that Gray has shown the strength of these amalgams at the end of forty days. This is undoubtedly quite accurate for the pressures he has used. For lower pressures, such as are common in inaccessible places in the practice of dentistry, it may be expected that the maximum strength will not develop until at least three or four months have elapsed.

It is well known that the heat treatment given to the cut alloy has a marked effect upon the strength. When freshly cut particles of alloy are combined with mercury the combination takes place so rapidly that it is not possible to continue the trituration to a place where the mass becomes fine grained for the reason that incipient setting takes place. This mass appears to be composed of a cementing layer of amalgam around the comparatively coarse alloy particles. If the alloy be annealed the combination takes place less rapidly and trituration may be carried on further, resulting in a mass in which there are particles much smaller. The general effect of making the combination of mercury and alloy slower seems to be to increase the strength up to a certain point and then a continuation of the annealing seems to cause a decline in the strength. The amount of annealing that should be given to each formula varies with the composition of the alloy and the mechanical treatment given it during the cutting process.

Flow of Amalgam.—A solid metal can flow like a viscous fluid if sufficient pressure is applied.[1] The property seems to be different with different metals and varies with different forms of the *same* metal. Some metals with a distinctly granular structure seem to flow less than the same metal when in a less granular structure, though the tenacity and elongation of the two forms may be nearly identical. The differences in the rate of flow between different metals depend largely upon their *plasticity*, by virtue of which they yield to the pressure and allow the molecules to slip over each other and assume new positions.

If we subject a bar of pure silver or copper 3 mm. square to a force of 200 kg. it will yield a very little soon after the pressure is applied, then it will yield no more until the weight is increased. If we try a similar block of tin in the same way we find that it yields much more easily; 15 kg. will cause considerable change, and if we leave it under this pressure without increasing it will continue to yield until the greater part of the tin has flowed from between the points and been reduced to a thin sheet. One writer[2] has stated that this is proof that tin is not only a softer metal but has a physical property totally different from any possessed by silver, the property of continuous flow under a given pressure. This indicates the effect of tin and silver upon flow, though it implies that the flow of tin is a peculiar property rather than that it is a property of all metals, tin being one possessed of a high rate of flow.

A hard metal like silver has an *elastic limit* which must be exceeded and the pressure maintained in excess if a continuous flow is produced, while a soft metal like tin has practically no elasticity, and is therefore capable of being changed in form with almost any pressure. The composition of the alloy controls largely the property of flow, the hard and elastic metals reducing it and the soft ones increasing it. The effect of annealing upon flow depends upon the composition, some formulæ being affected more by annealing than others. Generally speaking the softening of an alloy by annealing increases flow, although with some formulæ flow may be slightly decreased by annealing.

The manner of incorporating the alloy and mercury, percentage of mercury used during amalgamation, the condition of the cut, or the amount of mercury left in the filling modify flow, although apparently not with regularity even in a given alloy. The least change in composition so modifies flow that each of these phases must be considered separately with each formula. An excess of mercury left in the filling, however, increases flow quite regularly, there being some exceptions in the ternary amalgams, which are high in silver and low in tin. The

[1] Hiorns: Mixed Metals and Metallic Alloys.
[2] Black: Operative Dentistry, vol. ii.

property of flow depends largely upon the softness and absence of elasticity, and is at its maximum in alloys known as low silver alloys.

Spheroiding of amalgams is a phenomenon associated with flow and increase in volume. It has been held that amalgams possess a strong tendency to become spherical in shape, due to the influence of mercury which is spherical in shape when divided finely. This influence which mercury is supposed to exert seems to be a misconception of the cause of the tendency to spheroid. Mercury is spheroidal or globular in shape when divided somewhat, the smaller the particle the more nearly a sphere. There seems to have been a tendency to regard this as a property peculiar to mercury. This is not true. The property is possessed by other metals when in a fluid condition.



FIG. 349.

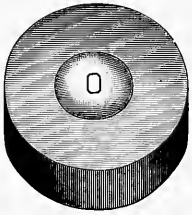

FIG. 350.

The above illustrations show a spheroided filling produced by an alloy which increased in volume and flowed easily. It was composed of silver, 49 per cent.; tin, 49.1 per cent.; zinc, 1.9 per cent. Fig. 350 shows the surface of a filling made from this plastic alloy and kept in



FIG. 351.

the thermostat at body temperature for eight months. The surface is seen to be spheroided. Fig. 349 shows a companion filling like that of Fig. 350, except that the walls of the test-tubes are highly polished, this being accomplished by making the test-tube with removable bottom, as seen in Fig. 351. It may be seen that the filling (Fig. 349),

instead of spheroiding, has risen nearly as much at the borders as it has at the center of the filling. The filling (Fig. 350) has assumed a much more spheroidal surface than the one (Fig. 349), due apparently to the walls of the cavity being purposely roughened. This spheroidal tendency seems to disappear somewhat with alloys high in silver and copper, these alloys possessing less flow. It has not been produced to any extent in alloys which do not expand decidedly and flow comparatively easily, although irregular expansions and contractions appear to produce in some instances bulged surfaces and in others concave surfaces in alloys possessing little flow and expansion.

General Considerations.—Washing Amalgam.—Much importance has been attached to the washing of the alloy particles during the process of incorporation with the mercury. Such substances as dilute acids, alcohol, ether, chloroform and sodium carbonate have been used, but with doubtful value in many cases, for the reason that the profession has not mastered the technic of mixing the alloy and mercury. The advantage of washing the alloy is to remove some of the metallic compounds that have formed during the cutting process and annealing process, and by subsequent standing exposed to contaminating atmospheres for some time. It has been stated that washing alloys increases shrinkage, but this can be accounted for easily when it is considered that practically all alloys had considerable shrinkage previous to 1895. Since that time alloys have been made that possessed little shrinkage and litte or nothing has been said about the effect of washing alloys. Another disadvantage of washing alloys is that it is difficult to prevent some of the material from becoming incorporated in the amalgam as a foreign body, thus lessening the strength. If, however, the material used for washing actually loosens the metallic compounds upon the surface of the alloy particles, or if it dissolves them and they are then well removed by rolling the amalgam mass into a thin sheet between two pieces of absorbent material, the result will be a better solution of the alloy in the mercury with a brighter color and better strength.

A still better plan than washing the alloy at the time of making a mix with mercury is to wash it some time in advance. This is probably better done by the manufacturer, though it may be desirable for the dentist to do it if a quantity of alloy has become contaminated by exposure after leaving the manufacturer.

One of the leading manufacturers has recently taken out a patent[1] on a process for washing and drying the alloy after it is cut and annealed. It seems likely that hydrochloric acid in small quantities in alcohol is used in this instance.

[1] Alloy and Method of Purifying Same, Paul Poetschke, patent No. 1278744.

Thermal and Chemical Relations.—Amalgam, like gold and other metals, is a conductor of thermal impressions. Just where amalgam stands as a conductor of heat and electricity is not known, although it can safely be placed quite near gold. The composition of the amalgam will influence its conductivity. Any rise in temperature will usually retard and a fall in temperature will increase conductivity, although the resistance of alloys to conductivity does not always behave in a manner that would be expected from the nature of their constituents. Certain anomalies which are known to exist make it seem possible that certain temperatures with certain formulæ might result in a variation from the general rule. Dental amalgams are practically insoluble in the fluids of the mouth. The common solvent found in the oral cavity, lactic acid, affects them only a little. There is, however, a constant wasting away of many amalgams, due to the formation of compounds which are soluble in the oral fluids or which are worn off during mastication. Amalgams that are high in copper furnish an example of the constant wasting which may be due to the formation of the green basic carbonate in small quantities or salts from the action of hydrogen sulphid and soluble sulphids. The two principal classes of alloys now in use are not affected in this manner to any appreciable extent.

There are probably no alloys in use which exert any particular influence upon the tooth tissues except those high in copper or possibly silver or tin. One or two alloys containing high percentages of copper are heralded as great tooth preservers, not simply because they are free from contraction, expansion and flow after insertion, but because they possess "antiseptic properties." A critical examination of them fails to reveal any reason why they should exert a marked influence on account of their comparative insolubility. The action of copper amalgam upon the tooth tissues, however, has been studied by Miller, Fletcher, Witzel and others, and the general opinion seems to be that it possesses antiseptic properties not possessed by amalgams containing small percentages of copper. (See Copper: 1. Amalgam. 2. Cements.)

Copper Amalgam.—Copper Amalgam differs so markedly from all other amalgams, both in composition and behavior, that it deserves separate consideration. The foregoing data apply only in slight degree to copper amalgam. It is an alloy of copper and mercury and may be made by adding freshly precipitated and washed metallic copper to an excess of mercury until the solution is complete; the excess mercury is then removed by compressing the mass in chamois skin. The portion which does not pass through the chamois skin is packed into molds and allowed to stiffen. The product may be

purchased in the form of small tablets, which may be softened by heating slowly in a spoon (Fig. 352) after which it may be molded and packed into the cavity. Many dentists have made copper amalgam by grinding copper filings in a mortar with dilute acids and washing with a variety of substances immediately before insertion of the amalgam. A far better method, and one which yields a product of greater purity and uniformity, has been suggested by Dr. E. C. Kirk. It is done by precipitating the copper directly into the mercury by electrolysis. "This may be done conveniently," says Dr. Kirk, "by pouring a quantity of mercury into a suitable glass vessel—a small battery jar, for example—and suspending a thick plate of copper, by means of a wooden support, some distance above the surface of the mercury.



Fig. 352.

"A saturated solution of cupric sulphate is then poured into the jar until the copper plate is completely submerged. The cathode pole of a battery or other source of electric current is then connected with the layer of mercury and the anode with the copper plate. All of the cathode electrode that is in contact with the cupric sulphate solution should be insulated with gutta-percha and only the point which is in contact with the mercury left exposed. The passage of the current causes solution of the copper from the anode and deposits it in the mercury continuously as long as the foregoing conditions are maintained. The precipitation should be continued until the mercury is saturated, which will be evidenced by the appearance of the characteristic red color of the excess of copper at the cathode pole.

"When the saturation point has been fully reached the mass should be washed, first in dilute hydrochloric acid and then in water, dried and compressed, as is usual with this amalgam when prepared by the ordinary process." Copper amalgam prepared in this manner changes in volume very little, if at all, as a result of the union of mercury with the copper, either in the mixing or subsequent to its insertion into the oral cavity. The only known alteration in form that occurs is the comparatively small one resulting from the thermal changes. It is antiseptic. These two qualities make one of the best tooth preservers now in use, although it has other qualities so undesirable as to exclude

its use in a great majority of cases. It turns almost black in most mouths, has a peculiar metallic taste, is sometimes a marked cause of voltaic disturbance, and if moisture through any cause enters between it and the walls of the tooth the latter becomes discolored. Often, although no visible leakage of the filling is apparent, there is discolored tooth tissue, due probably to the absorption of the salts of copper into the dentinal tubuli. Copper amalgam is not quite as indestructible in the fluids of the mouth as other amalgams, as it readily forms salts which are either dissolved or carried away by abrasion. This is commonly shown by a sort of cupping out of the surface of the filling.

Classification of Amalgams.—Amalgams may be divided into classes according to the number of constituent metals. A binary dental amalgam may be represented by copper and mercury or palladium and mercury, each of which has a very limited usefulness in dentistry. Some of the older alloys of silver, tin and mercury, such as that designed by Dr. Townsend, represent what may be called a ternary dental amalgam. Amalgams of silver, tin, copper and mercury, such as designed by Dr. Flagg, may be said to be quaternary dental amalgams. This class is also represented by the so-called plastic amalgams made since 1895–1896, and composed of silver, tin, zinc and mercury. The high percentage silver amalgams, composed of silver, tin, copper, zinc and mercury, may well represent a quinary amalgam. The terms binary, ternary, etc., have not gained in popularity with the profession in the last decade, although amalgams are in use representing each of the classes mentioned.

Buying and Keeping Alloys.—The question, "Which is the best alloy to buy?" is asked so often that it seems quite certain that the profession in this particular does not exercise the same judgment with which it selects other dental materials. It indicates quite clearly that there is yet much mystery surrounding the purchase of an alloy. When supplies the nature of which is not understood are required the majority of the profession select them from a dealer who is believed to be reliable in this respect and who is known to be wholly reliable in others. As a rule the larger supply houses are best equipped for distributing uniform supplies of all kinds, and most likely to secure the services of competent men to manufacture their products. This is true in the manufacture of alloys and should be used as a guide in their selection. Sometimes a good product comes from a dealer who is not well nor favorably known, but this is the exception rather than the rule. Alloys and cements above all other products should be made and placed upon the market by competent chemists if the dentist is to be rewarded for his work. The practicing dentist should never attempt the manufacture of these products himself without first spending considerable time preparing

himself by learning the peculiarities of these products with special apparatus built for the purpose.

Dentists, as a rule, are kept changing alloys by solicitous dealers who advance this or that quality of their alloy as a cure-all. For example, one dealer lauds his product as being superior because it contains more silver than a like article made by another. Another makes the same claims regarding the quantity of zinc in his product. Others advance the argument that the manner of cut of their manufacture has much to do with the success attending its use, and so it is with nearly every dealer. These arguments generally reward the dealer with sales because dentists, as a rule, are not sufficiently informed on the subject to enable them to judge the merits of the products themselves.

It is true that some of the best manufacturers differ as to what constitutes the "best alloy, all things considered," but, as a rule, the difference of opinion is an honest one rather than an effort on the part of the producer to lessen the first cost of the article. This is shown by several leading dealers' products, which are found to contain from 65 per cent. of silver to 68 per cent. of silver, yet each will claim to have an alloy made after Dr. Black's plan, etc. The maker who uses 68 per cent. of silver knows that he obtains a little stronger filling, although he is conscious of the fact that it works a little harder and sets faster than one that contains only 65 per cent. of silver. On the other hand, he who uses 65 per cent. of silver knows that his product works a little more easily and sets a little more slowly, although he is conscious that it is a little weaker. The maker who uses only 65 per cent. of silver probably considers it better to give the operator a little more time to work than to have a little stronger filling.

The same is true of the quantity of zinc now used in high percentage silver alloys. Some claim better and permanent light color in the mouth as a result of the use of a little more zinc, while others admit a loss in color as a result of its elimination, but claim to have a product more permanent in form, as a rule. Neither disputes the other's claims, but each places greater stress upon the distinctive qualities of his product in contrast to those of his competitors. Thus it becomes a matter of judgment which quality is of most importance.

The leading dealers' high percentage silver alloys are all good, well-made, uniform products, and except for the difference mentioned, they are nearly of equal value from a practical standpoint. Whether an alloy contains 65 or 68 per cent. of silver is not a guide to the quality of either. The same is generally true with the small quantities of zinc now used, although it is quite generally understood that zinc, while it improves color, facilitates change in volume subsequent to insertion

when used in large quantities. This is not so, however, if used in small quantities. Dentists cannot rely upon the quantity of each or any constituent as a guide to quality, although present knowledge of the subject confines the qualities of each constituent for the best alloys to the ranges stated. All things considered the high percentage silver alloys are best, and should be chosen by dentists.

There are, perhaps, some places where the quick-setting properties make the use of these alloys questionable, but, taken as a general rule, dentists soon learn to open the orifice of the cavities and master the manipulation of these quick-setting, stiff-working products. When purchasing an alloy from a manufacturer who makes his product in both filings and shavings the filings should be chosen. Shavings as a rule, are too coarse and not of the proper shape to permit their being dissolved readily in mercury. Not all manufacturers make their products "cut in two forms." As some dentists demand them, the maker sometimes can hold his trade by no other means than by supplying shavings to those who want them.

Some makers of high percentage silver alloys make only one grade of alloys as regards setting qualities while others make their product in two or three grades. This, too, is usually done to catch trade, since most makers are aware that if more than one grade is supplied, some of the grades are imperfect products at the time of making. "Rapid setting," "slower setting," and "slow setting" are terms used to designate these products. They are the same in composition, but have not had the same amount of annealing.

Manipulation of Amalgam.—The high percentage silver alloys are made by some manufacturers in two and three grades of setting. They are of the same composition, cut just the same and marketed just the same, except that some packages may be marked "slow setting," some "rather rapid setting," and others "rapid setting." The difference in their production is in the amount of annealing given them, annealing causing them to set more slowly, and their behavior is usually more marked.

Alloys marked "rapid setting" will require much more mercury to amalgamate them if they have not been in stock long enough to become annealed. They will set so rapidly that it is difficult to pack them properly, even in cavities of easy access, and almost impossible to insert them where there is not ready access. The amount of expansion that will take place subsequent to insertion is much greater with improperly annealed alloys. The finished product is represented by alloys marked "slow setting." Some manufacturers make their high percentage silver alloys in one grade only. These alloys will have no mark to designate their manner of setting.

The alloy to be selected from general use is the finished product, although the occasional use of "rapid setting" alloy when the patient cannot be seen by the operator to finish the filling seems to be desirable. It should be remembered that while alloys marked "rapid setting" expand more than those marked "slow setting," contraction and expansion are not controlled by the manipulation of them during amalgamation and insertion. The operator may modify these movements but he cannot control them, the controlling factors being composition and annealing.

In choosing an alloy it should be remembered that the property which can be controlled most by the operator is strength, and even then the alloy must be properly made or a strong filling cannot be produced.

A strong filling cannot be made from a poor alloy, although a weak filling may be made from a good one. The amount of alloy necessary for the filling should be placed in a small ground glass or Wedgwood mortar and ground with the required amount of mercury until the mass becomes coherent enough to be turned into the palm of the hand conveniently, after which it should be kneaded rapidly and vigorously for from three to five minutes, depending upon the coarseness of the cut, amount of annealing and composition of the alloy.

A complete union of the alloy and mercury cannot be effected at ordinary temperatures. The operator must be guided in amalgamating these alloys by the consistency of the mass. It should be fine grained and smooth and tough enough to be rolled out into a long roll without breaking before the mixing is discontinued.

The amount of mercury to be used with a given weight of alloy is slightly more than the weight of the alloy. The proportions given by most makers of high percentage silver alloys are, approximately: alloy, 5 parts; mercury, 7 parts, by weight. These proportions are as nearly correct as can be determined by experiment, although 7 parts of mercury will be found none too much for alloys marked "rapid setting." The low percentage silver alloys of all grades will require less mercury. It will usually be found necessary to use more than equal weight of mercury for a given weight of alloy to make a smooth, fine-grained mass. The amount of mercury to be used with a given amount of alloy of known composition is a question which cannot be answered unless the "condition of the cut" and the age of the alloy are known.

All alloys require less mercury as they become annealed, hence the proportions given by makers of alloys are correct for a comparatively freshly made alloy only.

The older any alloy becomes, the more easily it works, the weaker it

is, and the less mercury it requires, although if properly made, it will not contract appreciably. It may be noted that manufacturers having similar products recommend slightly different amounts of mercury to be used with a given amount of alloy. Some products may be marked: "Use 5 parts of alloy with 7 parts of mercury;" "4 parts of alloy with 5 parts of mercury;" "9 parts of alloy with 11 parts of mercury," etc. Chemical analyses show many of these alloys to be nearly identical in composition, but there is some difference in the "cut" of them, a little difference in the amount of annealing, and probably some difference in the manner of casting and cooling, which accounts for the variation of about 10 per cent. in the amount of mercury required. The correct amount of mercury to be used during amalgamation does not mean the amount of mercury to be left in the filling. It means that a slight excess of mercury should always be used to start the filling, and as soon as it is noticed it should be removed. Dr. Black has stated[1] that "it is certainly best to have just the right amount," but in the same sentence states that "superfluous mercury does little harm if removed as soon as noticed."

Dr. Black has remained practically silent on the subject of "permanency of form" or changes in amalgam subsequent to insertion. Consistency of the mass seems to have been a prominent factor with him. This is unquestionably a vital point in the packing process, but an amalgam which packs nicely may be the most unstable kind.

The factor of supreme importance in the production of a stable amalgam is a fairly complete solution of the alloy in the mercury. This can only be produced by the use at all times during the amalgamation process of slightly more mercury than makes a mass of the consistency to pack well. As soon as the mass begins to stiffen and shows a tendency to set, any surplus mercury should be removed. There is not even a remote possibility of an operator producing a true amalgam out of modern high percentage silver alloys under ordinary conditions. The best that can be done is to produce as much true amalgam as possible around the undissolved particles of alloy and yet keep the mass of a consistency to pack well. The latter often depends upon the presence of a certain number of undissolved alloy particles.

Alloys low in silver and those high in silver that are very old may dissolve so completely in mercury that the mass is too soft to pack well.

The ultimate aim of the operator should be the production of a mass of amalgam that is both stiff and tough and with the alloy well into solution in the mercury. To accomplish this more mercury than

[1] Operative Dentistry, vol. ii.

is to be left in the filling should be used to start amalgamation. This amount is stated on the packages of alloy, and is correct for freshly made alloys. The alloy and mercury may be weighed on a balance or turned out approximately correct by an experienced operator from the containers. It is immaterial whether the exact amount of mercury is weighed or not, as the operator never knows whether these proportions are correct. It is convenient, however, to have them weighed in the proportions the maker has determined for fresh alloys, since a little mercury is easily removed during the amalgamation process if it be found necessary. Earlier observations of the author led to the belief that the alloy and mercury should be determined and weighed carefully, as in that way a mass was obtained of a consistency to pack well; but later observations on the changes occurring in these bodies subsequent to insertion lead to the belief that while the packing of an alloy is a vital point, it is not of so much importance to the life of the filling as to have the alloy worked with sufficient (though not enough to make a sloppy mass) mercury at all stages up to and including the packing.

After the alloy and mercury have been ground in a mortar, then turned into the hand and worked vigorously for a few seconds, it should be noted whether the mass is becoming sloppy. If it is, a little mercury should be removed quickly between the thumb and forefinger. The mass should not be put into pliers, chamois skin or muslin, as these processes require too much time. Surplus mercury should be removed quickly, or the mass stiffens so that the object of the operation is partially or wholly defeated. The mass should be quickly turned into the hand and again kneaded vigorously. If it again appears a little sloppy, remove some mercury as before. Do not remove too much mercury or the alloy will not be anywhere near completely into solution. This process should be repeated three or four times, the last time using all the pressure that can be exerted in removing the excess mercury, so that the mass will be stiff enough to enable it to be packed well. Three or four repetitions of this process usually consume from three to five minutes and result in a tough, stiff and fine-grained mass.

The question might then be asked, "What is an excess of mercury?" And it might be answered in a general way by saying that it is the difference between the amount used to amalgamate the mass and the amount that should be left in the filling.

Any amount of mercury left in the filling over and above an amount which makes a stiff, tough and fine-grained mass of amalgam would, of course, be regarded as superfluous. Every step in the amalgamation process should be done rapidly, not allowing the amalgam to lie still. If the mass lies still a few seconds it stiffens so much that the particles

of alloy are not broken down in the mixing and surplus mercury is usually retained in the mass. The packing should be begun immediately using flat-end serrated instruments. Several instruments have been designed for the packing operation, but the consensus of opinion seems to favor a flat-end or cup-shaped serrated instrument such as shown in Chapter IV.

The round burnisher has been used with some degree of success, but it has been proved that it does not give the maximum density or adaptation. Pluggers used for foil fillings have been used somewhat successfully, but they are too small for most places, and as a result chop the amalgam mass to pieces and do not compress it. Great care should be exercised in packing amalgam, as it is a most difficult material to adapt to cavity walls. Too little pressure results in a weak filling. Too much pressure, such as that exerted by sudden blows from a mallet, disturbs the whole mass, and as a result weakens the filling. Heavy, steady pressure gives the strongest and best adapted filling (Figs. 344, 345 and 346). The amalgam mass should not be broken up any more than is necessary for convenience in placing it into the different parts of the cavity. Much has been said in regard to the part of the cavity in which to begin the packing, but it is doubtful if any one method can be carried out in all cavities.

In all cases an effort should be made to wedge the amalgam, piece after piece, between the opposing walls or between one wall and the already condensed amalgam, finishing by wedging some amalgam between the main mass and the cavity walls. Experience will teach how much force can be used in the wedging and what size of pluggers will not chop the mass to pieces. Instruments of varying sizes must be in readiness on the table, so that the operator has at his immediate command instruments that will compress and wedge amalgam into any pocket or crevice that may appear during the operation. Amalgam to be packed properly must be stiff. Soft amalgam cannot be packed to make even a fair margin when examined under the lens. It is in this part of the work that the modern high percentage silver alloys exceed all others, the low percentage silver alloys with no copper scarcely deserving comparison. The cavity must have four walls if any degree of compression is obtained. With the great variety of matrices and matrix retainers provided by the manufacturers, together with the facilities at the operator's command for making special matrices, there is seldom occasion for the insertion of an amalgam filling unless the cavity has four walls. (See Chapter IV.)

The cavity should always be filled to overflowing. Amalgam should be packed with steady force and with as large pluggers as are consistent with the operation, upon the orifice of the cavity and left until the

mass has become hard before any of it is removed. After the mass has hardened somewhat, surplus amalgam should be removed by carving toward the borders with sharp plastic instruments or excavators, so that amalgam once packed along the margin and allowed to stiffen will not be disturbed. Attention may be directed to the fact that this can only be accomplished with the high percentage silver alloys.

Only very light burnishing should be done at the time of insertion of an alloy lest the margins be disturbed. The matrix should be removed with great care or it may disturb the margins or even the bulk of the filling. An amalgam filling should be finished in the same manner as a gold filling after it has "fully set." (See Chapter IV.)

If the filling be given its final finish prior to reaching its maximum hardness the best finish cannot be obtained. Generally speaking, forty-eight hours is sufficient to lapse between the insertion of amalgam filling and the time of giving its final finish, although a week is better.

Amalgam fillings should be polished repeatedly. Not more than a year should lapse after the insertion of an amalgam filling before it should again have its margin polished and burnished.

Attention has been called to the fact that alloys have bulk changes after as well as at the time of insertion. This often causes the filling to appear spheroided, tilted, warped or otherwise distorted within a year or two after insertion. Such fillings should be ground down with small stones and the surface again finished.

During the packing operation mercury is often removed from the amalgam mass and remains upon the surface. This is almost always true if the operator uses very high pressure (Fig. 353),[1] but is not very marked if the mass has been worked properly and the excess mercury removed by good, firm pressure just previous to packing, when the regular amalgam pluggers are used. The use of quick blows, as has been mentioned before, is bad practice, since it disturbs the amalgam mass even when large pluggers are used. As fast as mercury appears at the surface during packing it should be removed hastily with an excavator or other instrument and more amalgam inserted into the cavity.

If there is no easy access to the cavity, pressure enough to bring mercury to the surface will seldom be exerted. This is also the case if the matrix is not used. It is quite generally true that if there is good access, if a little mercury is not removed during the packing the pressure has been faulty. Gold foil, silver foil and tin foil have been used to absorb the excess of mercury appearing at the surface of

[1] Gray, Arthur W.

amalgam fillings, and little harm has probably resulted, although this practice cannot be said to add to the qualities of the amalgam. New alloys are formed upon the surface when anyone of these materials is used, and experiments have proved that mercury and one metal do not form an alloy having the most desirable qualities.

When tin foil is used to absorb mercury appearing at the surface a soft non-crystalline, shrinking alloy results. Similar comment may be made upon the use of the other materials, gold being no exception.

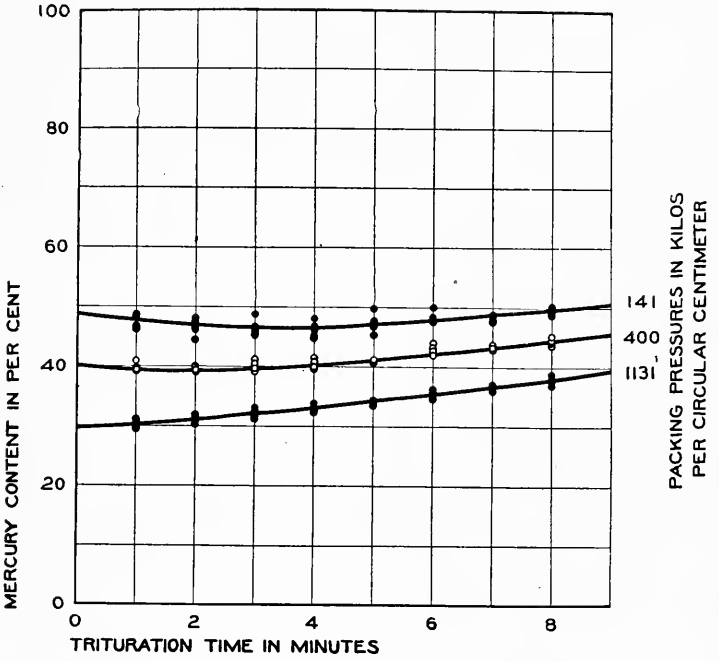

FIG. 353.—Percentage of mercury in an amalgam filling is less when high pressure has been used to pack it than when low pressure has been used.

Mercury which has appeared on the surface during the packing provided the packing has been done with care, should be removed and not used again without being redistilled. The affinity of such mercury for other metals is probably weaker, even though it remains liquid.

It is possible that the presence of other metals in mercury may be found to improve its different qualities, but it has not yet been done. On the other hand, mercury which has been removed from amalgam during packing has almost invariably been found to contain more tin than other constituents. Dr. Black's later observations seem to confirm this,[1] but in the same chapter he has stated that "if the alloying

[1] Operative Dentistry, vol. ii.

is a perfect combination, I have reason to believe that no one metal will be dissolved more than another." It is a fact, however, that when two metals are cooled, certain alloys of these metals may solidify first and a more fusible alloy of these metals is left, and is known as the eutectic alloy. It is a general rule that this defect is intensified when four or five metals are used, as is the case in the production of dental amalgam alloys. With these facts in view we may assume that an ingot of alloy before it is cut contains quantities of globules or strata of eutectics which may be more soluble as well as more fusible. Mercury which has had ever so slight a contact with alloys should be discarded, since it will pick up some of the alloy and have its affinity partially satisfied.

CEMENTS.

The term cement formerly implied a material which was used to unite two or more substances. This has required that the uniting material should be plastic and highly adhesive and have other properties similar to those possessed by filling materials. During recent years the possibility of obtaining these products in a more translucent form has led to the development of several products known as cements, because of their composition, which have little of the power of uniting substances. Comparatively recently it has been shown that the solubility of these products could be taken advantage of by the introduction of compounds known to have antiseptic properties, and the result has been the development of a class of cements not possessed primarily of adhesive properties, but of antiseptic properties together with a fair degree of adhesive properties.

The term cement as it is used today, therefore, is a much broader term than it was formerly, and includes a variety of products which may be grouped, for convenience, under three heads, namely, zinc oxyphosphates, copper oxyphosphates and silicates. In each case these products reach the practitioner of dentistry in the form of a liquid which in all cases is an acid and a powder which may be one or more inorganic compounds. When the acid is placed in contact with the basic material the result is the formation of a new compound accompanied by many of the usual phenomena that accompany the union of the more common and simple acids and bases. For example, heat is generated, strength is changed, solubility is changed and the working properties are different. Inasmuch as most of the cements now in use are the result of recent investigations, it is not possible to give the same amount of information with respect to their properties and behavior as is the case with amalgams. Only general statements seem to be recorded.

Liquid Portion.—The liquids which are used in all three classes of cements are compounds of ortho-phosphoric acid, aluminum hydroxid, and water. The following is the result of an analysis[1] of the liquid of one of the leading zinc oxyphosphates:

Orthophosphoric acid (85 per cent. acid)	79.00 per cent.
Aluminum hydroxid	10.00 "
Water	11.00 "
	100.00 "

A few of these cements may be found to contain small quantities of zinc oxid, and one or two compounds of iron probably in phosphate form, and still others a little copper, also probably in phosphate form. Possibly some of the older products may be found that contain alkaline modifiers in the liquid, but it seems unlikely since practically all investigators report the use of aluminum phosphate as the best modifier and partial neutralizer of the ortho-phosphoric acid for use with zinc oxid. One writer[2] reports the use of the oxids of calcium strontium, beryllium, zinc, and aluminum in solution in the ortho-phosphoric acid as the liquid for the silicates. The introduction of new products containing these compounds confirms this report. From this it seems that it is quite probable that the composition of the liquid for the silicates may be changed eventually into a more complex compound than the one most desirable for use in the formation of a zinc oxyphosphate.

About the only generally accepted effect that is recorded with respect to metallic modifiers in the ortho-phosphoric acid is that aluminum phosphate so modifies the acid that less heat is generated when the liquid and powder are brought into contact. Improvements in the physical properties of dental cements of several years ago, including the property of setting promptly in the presence of moisture, are probably due in a degree to the presence of aluminum phosphate in the liquid.

Much the same may be said in regard to reliable information concerning modifications of the acid by the addition of water. Ortho-phosphoric acid is ordinarily known as a colorless, odorless syrup, with a specific gravity of 1.7 and containing from 83 per cent. to 85 per cent. of phosphoric acid (H_3PO_4).

In chemistry, however, it is known as a translucent, very deliquescent soft solid, with a specific gravity of 1.88, containing nothing else.

It should be obvious, therefore, that the 100 per cent. acid is not in a form suitable for combination with a prepared powder. The

[1] Ward, Marcus L. and McCormick, R. M.: Jour. Nat. Dent. Assn., 1915.
[2] Voght, C. C.: Jour. Nat. Dent. Assn., April, 1918.

85 per cent. acid is in a much more favorable form, but it has been proved less desirable from many standpoints than a still more dilute and partially neutralized acid such as previously given for use in the formation of a zinc oxyphosphate. The acid with a greater dilution not only acts as a better solvent, but the water apparently plays an important part in the chemical reactions with the powder resulting in beneficial changes in physical properties of the product after it has set. With certain cement powders the addition of a small percentage of water to the phosphoric acid will hasten the setting while with others the subtraction of water will retard the setting. This should be kept in mind as well as the fact that phosphoric acid is deliquescent, for a cement liquid may be nicely balanced with respect to water content when it leaves the manufacturers' hands and later become unbalanced upon exposure to the air, with marked changes in properties. An atmosphere such as exists in a steam-heated room in the winter months is usually dry. If a bottle of cement liquid be left exposed to such an atmosphere it may lose from 10 per cent. to 20 per cent. of the water content. If, on the other hand, the bottle be left exposed in a room that is warm and saturated with moisture, such as frequently happens in rainy weather, the liquid may take up as much as from 1 per cent. to 4 per cent. of water. Such changes have been shown to produce marked changes in the properties of the cement, and should, therefore, be guarded against in every way possible.

Powder Portion.—Zinc-oxyphosphates.—For many years zinc oxid has been regarded the most suitable single constituent to combine with modified phosphoric acid to produce a dental cement. Earliest observations, however, showed that unmodified zinc oxid did not yield a cement that possessed as many desirable properties as zinc oxid which was modified by either calcination of the zinc oxid or combining some other compound with it. When unmodified zinc oxid combines with phosphoric acid, or the prepared phosphoric acids now in use, the mass sets too rapidly, making it impossible to make a smooth mass. The mass is also less adhesive, weaker and more soluble. Many of the earlier cements were made from plain zinc oxid, slightly pigmented, to produce different shades, though they failed to meet the demands placed upon these products. As the cements have been developed to meet more of the demands on these products, more and more modification of the zinc oxid has taken place. Among the first modifications to be adopted was calcination of the zinc oxid. As zinc oxid is heated it becomes fused and takes on the appearance of powdered glass or powdered silica, turns slightly yellow in color, is less soluble, becomes much less flocculent and reacts with phosphoric acid much less rapidly. Its chemical composition does not change but its

physical composition is markedly different, and when combined with phosphoric acid or a prepared phosphoric acid the result is quite different than when used unmodified. Another method of modifying zinc oxid for use in dental cements consists of dissolving zinc oxid in nitric acid and subsequently evaporating to dryness. The zinc oxid thus produced from the nitrate is quite similar to zinc oxid prepared by calcination, except that in this instance the particles of zinc oxid are in a definite form. If the nitration process has been carried out carefully, practically every particle seems to be of the same

1. Heating or nitration practiced by all manufacturers.
2. Fineness of comminution practiced by all manufacturers.

Cement powder is zinc oxid (ZnO) modified by

3. Addition of other compounds

(*a*) To improve properties: Bi_2O_3 (used by Caulk, Ames, Smith and Fleck); MgO (used by Caulk, White, Smith and Fleck).

(*b*) To color the powder: MnO_2 (black); Fe_2O_3 (red).

(*c*) To add antiseptic properties:

CuO (black)	99% Ames.
" "	25% Caulk.
Cu_2O (red)	25% Fleck.
" "	8% Caulk.
Cu_2I_2 (white)	2% Caulk.
$CuSiO_3$ (greenish-blue)	2% Smith.
AgCl (white)	2% S. S. White.
Ag_3PO_4 (yellow). Both turn black on exposure to light.	2% S. S. White.

size and shape, while with the calcination process the particles may be of all sizes and shapes. As shown in the foregoing chart, both of these processes are adaptable to practically all manufacturers' products which, as a result of the combination of zinc oxid and phosphoric acid, are known as zinc oxyphosphates.

By referring to the chart on cement powders it may be observed also that zinc oxid may be modified in a third way, namely, by the addition of other compounds. The first class of compounds is added for the purpose of improving the color, the second to change the color and the third to add antiseptic properties.

The principal compounds that have been found to be desirable in modifying zinc oxid for cement powders are bismuth trioxid and magnesium dioxid. Just what part these compounds play in the cement-making process has not been recorded and the author has done comparatively little work on them.[1]

The limited work done by the author on the influence of bismuth trioxid tends to show that it is added principally for the purpose

[1] Ward, Marcus L., and McCormick, R. M.: Jour. Nat. Dent. Assn., November, 1915.

of making a smoother mass. It does not appear that the bismuth compound sets when combined with a prepared phosphoric acid but produces a smooth, oily appearing mass, which remains in a plastic state. It would seem from this that bismuth trioxid exerted a retarding influence upon the rate of setting. While nothing definite is recorded with respect to the influence of magnesium dioxid upon the cement mass, it is to be expected that it plays a very important part in the hydration process, for its behavior alone and in combination with other compounds is well known.

Examination of the various products in the market reveals that in some instances something has been added to the zinc oxid, magnesium dioxid, bismuth trioxid compound to color it. Zinc oxid is white before it has been heated or nitrated and yellow after either treatment. Bismuth trioxid is a citron yellow compound and magnesium dioxid is a white compound. When the three are combined it is obvious that the result is likely to be white or yellow in proportion to the amount of calcination given to the zinc oxid; the amount of heat applied to the mixture of bismuth trioxid, zinc oxid, and magnesium dioxid; and the percentage of bismuth trioxid used.

The white and yellow powders thus produced may be converted into various shades of gray, including greenish gray, by the addition of very small quantities of a black compound. The author has repeatedly found one manufacturer's product to contain manganese dioxid in the gray powders and has found upon experiment that as low a percentage as 0.20 of this black compound will produce the shades of gray and greenish gray.

The author has also repeatedly found some of the brown and reddish-brown powders to be colored with ferric oxid. This appears to be the only other coloring matter than manganese dioxid necessary to produce the various shades of zinc oxyphosphates now in the market, which are at present limited to shades white, yellow, gray and brown.

Copper.—Oxyphosphates (Antiseptic Cements).—The third class of compounds added to the zinc oxid is for the purpose of adding antiseptic properties, and, as may be noted from the chart, is limited at present to compounds of copper and silver, both of which, for a long time, have been known to possess antiseptic properties largely in proportion to the percentage of the copper or silver compound added. Four compounds of copper have been found in present products; one is black (cupric oxid), one red (cuprous oxid), one white (cuprous iodid) and one greenish-blue (cupric silicate). Recently two compounds of silver have been introduced, one of which is white (silver chlorid) and one yellow (silver phosphate). With the exception of the first product marketed by the W. V. B. Ames Company containing

practically all cupric oxid, all of the leading cement powders in the market which have compounds of copper or silver added for the purpose of adding antiseptic properties are modifications of the regular cement powders. The first product shown contains cupric oxid, with a very small quantity of a compound of cobalt, and is placed in the group of modifiers of zinc oxid only for the purpose of showing at a glance those cement powders which have varying degrees of antisepsis. By the total elimination of the zinc oxid, bismuth trioxid, and magnesium dioxid the maker of this product has a material which represents the maximum in germicidal efficiency. All the other products shown may be treated as ordinary cement powders which have had added to them a copper or silver compound for the purpose of making them more antiseptic than the ordinary cement powder is. It may be noted that these products have been used in quantities ranging from about 2 per cent. to about 25 per cent. It may be noted also that the compounds of copper and silver, in the quantities used, result in the production of three classes of cement powders with respect to color, one black, one red and one light.

The class of light copper cements may contain any one of the last four compounds shown in the chart on cement powders. This class of cements is not light in color on account of the original color of the copper or silver compound, but because there is not a sufficient quantity of the silver or copper compound contained in this class of antiseptic cements to turn the cement mass into a dark color. Both of the copper and both of the silver compounds shown which, when introduced into a cement powder, are comparatively light in color, are capable of turning almost, if not quite, black upon exposure. The only way, therefore, that is known by which a class of copper or silver antiseptic cements may be made is to keep the percentage of copper or silver compound so low that when they have turned dark they will not make the mass very dark.

It seems that with one or two exceptions, compounds of copper and silver are added to the ordinary cement powders in quantities ranging from about 2 per cent. to about 25 per cent., resulting in the production of three classes of compounds with respect to color. Because the question of antisepsis is of principal importance, and because of the more general use of compounds of copper than of silver for the purpose of obtaining antisepsis, these products have been designated as copper oxyphosphates to distinguish them from the ordinary cements known as *zinc oxyphosphates*. The general practitioner of dentistry has furnished to him by the manufacturers of dental products these three colors of copper oxyphosphates, some of which have very little more antiseptic value than the ordinary cement, while others have decidedly

more, depending upon the quantity of copper or silver present and the solubility of the cement after it has hardened. It is to be expected that the dental profession will undertake to determine what degree of antisepsis is necessary in these products in order to maintain a satisfactorily hygienic condition on, and adjacent to, many of the restorations retained in the mouth by cementation. At the present time, however, practically all that is recorded regarding antiseptic cements is by the manufacturers of dental materials, and is so conflicting in substance[1] that it is of little value to the average general practitioner of dentistry.

The first of the articles,[2 3 4 5 6] was written in 1914 by W. V. B. Ames, who is the maker of the first product shown in the chart. This product differs from the others by having its germicidal agent the principal cement-making material. In this article the writer speaks of the impregnation of a cement powder with cuprous iodid as "a senseless temporary expedient," and designates his product as the "real oxyphosphate." Since the appearance of this article several others have appeared apparently, in most instances, as a defence of the procedure which Ames condemns. Among other things, Poetschke speaks very highly of cuprous iodid, but does not say that the product marketed by Ames is not more antiseptic. Smirnow's work leads to the conclusion that cuprous oxid is the most germicidal, while Bacon's work implies that all of the copper cements are sufficiently germicidal. Quite recently the S. S. White Dental Manufacturing Company has published a statement that their experience with these products has caused them to eliminate compounds of copper from consideration.

This company has sent out some literature, with the following chart, to show the reason for the use of silver compounds instead of the more generally used copper compounds:

	Comparative germicidal strength.	Necessary for efficiency. Per cent.	Natural color.	Comparative tooth and cement discoloration in efficient percentage strength.
Copper oxid (black)	100	50	Jet black	100
Copper oxid (red)	100	50	Red	100
Copper silicate	100	30	Green white	40
Copper iodid	350	30	Light brown	35
Silver chlorid	3200	2	White	0
Silver phosphate	10400	1 to 2	Light gray	slight

Paul Poetschke,[7] a chemist for the L. D. Caulk Company, states that his results show that silver cements are not as efficient as most

[1] The reader is referred to an article on this subject in the Dental Review for August, 1916, Marcus L. Ward.

[2] Ames, W. V. B.: Dental Review, 1914.

[3] Poetschke, Paul: Jour. Indus. and Engin. Chem., 1915.

[4] Smirnow, M. R.: Dental Cosmos, 1915.

[5] Bacon, Raymond F.: Ibid, 1916.

[6] Poetschke, Paul: Ibid., 1916.

[7] Caulk Scientific Bulletin No. 1.

of the copper cements, and claims to be able to obtain an efficiency of only 72 per cent. to 80 per cent. after fifteen minutes' exposure. In the same contribution and in the following chart[1] he shows that an efficiency is obtained with the use of copper cements as high as 100 in the same length of exposure.

RECENT GERMICIDAL EFFICIENCY TESTS OF SILVER CEMENTS.

Sample.	No. of living bacteria per c.c. just before addition of 1 gram of sample.	After exposure of 15 minutes.	Per cent. germicidal efficiency after exposure of 15 minutes.
S. S. White silver cement A . .	21,110,000	5,830,000	72.3
S. S. White silver cement B . .	28,300,000	5,380,000	80.9
S. S. White zinc cement . . .	21,510,000	21,450,000	0.3

GERMICIDAL EFFICIENCY, CRUSHING STRENGTH, AND RETROGRESSION IN STRENGTH IN SALIVA.

Sample.	Percentage of germicidal efficiency after exposure of			Crushing strength in saliva after exposure of			Percentage retrogression in strength in saliva.
	5 min.	15 min.	1 hour.	1 day.	7 days.	28 days.	
1	0.0	66.6	83.3	970	903	797	17.8
2	99.4	100.0	100.0	595	755	833	0.0
3	97.1	100.0	100.0	788	800	918	0.0
4	96.0	100.0	100.0	935	1000	788	21.2
5	10.0	96.0	98.0	280	270	0	100.0
6	0.0	96.4	97.1	530	570	705	0.0

These two charts are quite indicative of the condition of the dental literature with respect to antiseptic cements. Obviously they do not agree, nor do they mention the question of relative solubility. The authors of both charts refer rather briefly to solubility in their contributions but do not include data on this property. Without these data it is very difficult to draw conclusions of value in the practice of dentistry.

It seems to be generally acknowledged that all cements are antiseptic while in the plastic state, due to free phosphoric acid and acid phosphates. The free phosphoric acid and acid phosphates are soon fixed through the chemical combination with the basic constituents of the powder, and through occlusion in the set mass of cement. This transition from the plastic to the hardened state is of short duration, and coincident with it there is a marked change in the physical and chemical properties of the cement.

It should be obvious, therefore, that if prolonged germicidal action is to obtain the hardened cement and not the plastic cement must furnish it. If the hardened cement were wholly insoluble there would be no germicidal action even though it contained large quantities of

[1] Jour. Engin. Chem., No. 4, viii, 308.

germicidal compounds. On the other hand if the cement be somewhat soluble the germicidal compounds will be slowly released. If two cements possess equal solubility germicidal efficiency will depend upon the presence of potent germicides, but if they have unequal solubility the one with the less solubility will be less efficient as a germicide. The question that at once arises in the mind of the practitioner of dentistry is which is the better of the two. No definite answer can be made until more definite knowledge regarding the degree of germicidal efficiency necessary under the varying mouth conditions is known. In the light of our present knowledge of the far-reaching effects of pericemental infections, and in view of the demands now being made for their prevention, it seems that whenever there is a question between solubility and germicidal efficiency a proper degree of germicidal efficiency should be given the preference if the cement is located where it is in contact with susceptible tissue. This question, however, is not likely to be of much interest to the practitioner of dentistry for the reason that most manufacturers prefer to increase the quantity of germicidal compound or select a more potent one than to increase solubility for the purpose of making their cement more germicidal. Some manufacturers make two or three antiseptic cements so that a given solubility may be preserved and at the same time have a variety of germicidal efficiencies.

It is to be hoped that in the near future more data will be available on what constitutes the proper degree of germicidal efficiency, for, as may be seen, the chart shows a variety of opinions expressed in the manufacture of a variety of products with no information as to the places where they are indicated. It seems safe to prophesy a very limited use of the copper cements containing only about 2 per cent. of a copper compound (light copper cements). As a class they seem not much more germicidal than the ordinary cements for general use. The manufacturers of some of these products claim that they are sufficiently germicidal and that they will not discolor in the mouth. The claim of sufficient germicidal efficiency is not based upon proof that is known to be reliable. The claim that they will not discolor in the mouth is perfectly justifiable because any light compound of copper when oxidized into cupric or cuprous form, thus becoming black or red, will not discolor cement or tooth appreciably when used in only 2 per cent.

One manufacturer furnishes a small bottle of cement powder containing 10 per cent. of cuprous iodid with the ordinary product of the company. Instructions accompany the package advising the use of as much of the cuprous iodid with the ordinary cement powder as is thought necessary. This allows the practitioner of dentistry to obtain

any percentage of cuprous iodid up to ten, and, in principle, appears to be more in harmony with modern therapeutics than the adoption of fixed percentages.

It may be possible, however, to determine upon fixed percentages that will meet the demands of average cases. It seems at this time that if this course be adopted it will not be necessary to manufacture products containing less than 5 per cent. of cuprous iodid or its equivalent, for as the subject is studied, more and more evidence accumulates to show that the light copper cements containing about 2 per cent. of copper are comparatively inefficient as germicides.

Silicate Cements.—Comparatively recent improvements in the zinc oxyphosphates and the copper oxyphosphates have stimulated investigation with the use of compounds which would yield products which were more translucent than were obtainable with zinc. The efforts of themanufacturers have been directed toward the development of a product that would have most of the properties of the zinc cement and at the same time possess the additional property of translucency. At the present stage of these efforts such materials as silicon dioxid, calcium oxid, aluminum oxid are used to form a powder which, when mixed with a liquid composed of phosphoric acid and water and metallic oxids, sets in much the same manner as the zinc cements.

The general use of silicon dioxid and the similarity between these products in translucency has apparently led to the adoption of the name *silicate cements.*

On account of the recent development of these products to a place where they were suitable for a trial in practice, little reliable information is available. In fact, only two writers,[1] [2] have attempted to reveal the information that is possessed by the manufacturers. A few others have written at some length, but have revealed little.

Voght claims that in addition to the constituents mentioned it is necessary to add some additional components, such as fluorids, in order to aid in fusing at a low enough temperature to keep the aluminum oxid in such a condition that it is chemically active while the mass remains translucent.

He also states that the oxids that are used in solution in the phosphoric acid and water are aluminum, beryllium, calcium and zinc. It is assumed that not all of these oxids are used in any one liquid. Probably one or two are used, making the liquid not much different from the liquids used for the production of the zinc cements, so far as constituents are concerned. The same writer states that non-metallic oxids or acid anhydrids, as, for example, the oxids of phosphorus,

[1] Voght, C. C.: Jour. Nat. Dent. Assn., vol. v.
[2] Poetschke, Paul: Jour. Indus. and Engin. Chem., April, 1916.

boron and titanium, may also be present in the powder portion. From this it may be seen that these products are very complex and little understood, or that those in possession of information are not inclined to reveal it. In either case it does not seem possible to discuss the subject except in a very limited way.

It seems to be common clinical observation that the silicate cements are more translucent and more insoluble than the zinc cements, and that, as a class, they are less adhesive, less tough and less hydraulic.

Some Properties Common to all Cements.—It should be obvious that each class of cements has one or more properties developed to a greater degree than other classes which are intended to be used for other purposes. For example, a zinc oxyphosphate that was not quite adhesive and possessed of a high degree of hydraulicity would not be generally accepted for the reason that such cements are used, as a rule, for the retention of inlays, crowns, bridges, bands, etc. In accordance with the needs, the manufacturers develop these two properties to a higher degree than they do with the other cements. It should be equally obvious that a copper oxyphosphate or silver oxyphosphate must have a higher antiseptic value than other cements or there would be little reason for their manufacture. Likewise, silicate cements should be more translucent than other cements or there would be little demand for them.

Among the properties which are most desired in any dental cement are: insolubility, constancy of volume, high resistance to stresses, hydraulicity, adhesion, density, non-porosity. In addition it has been pointed out that some cases demand a cement which is antiseptic and some demand one that is translucent.

Among other properties which are usually taken into consideration by the manufacturer are: heat generated during and subsequent to the insertion of the cement into the tooth, toxic action on the pulp, rate of setting and permanency of color.

It does not appear that present knowledge of chemistry and physics will permit the production of a cement which possesses all of these properties developed to a degree desired by dentists, so the manufacturers have done the best possible to meet all the demands placed upon these products rather than to develop one or two properties to the exclusion of others. If it were not quite necessary to have dental cements of certain colors and have them set at a given rate it might be possible to produce a dental cement that is as insoluble as some of the commercial cements. To ignore color and rate of setting would render some cements worthless in the practice of dentistry. The situation is much the same regarding other properties. A dental cement must possess properties which are acceptable from several standpoints and will

not be useful if the varied demands of dentists upon these products have not been taken into consideration by those who produce them.

Solubility.—One of the properties which all cements should possess is a reasonable degree of insolubility, for in few instances in the practice of dentistry is it practicable to completely prevent these products from coming into contact with the saliva. At the present time no reliable standard of insolubility has been established except that of clinical observation. Dentists usually are able to observe whether cements remain in position a reasonable length of time without loss of mass. In comparison with metallic fillings they are seen to be the more soluble of the two. In comparison with one another cements are seen to be more soluble in some cases than in others. This may be due to the composition and manufacture of the cement, or to the greater solvent action of the saliva in some cases than in others, or to the manipulation given the cement.

A cement which has been so manufactured that it is more soluble than another when used under the most favorable conditions cannot be improved much by the manipulation, nor will the media in which it is placed improve its inherent solubility.

A cement which is known to be one of the most insoluble may show much more loss of material in some cases than others, even though the abrasion on the two has been equal. This is due to differences in the solvent power of the saliva. More than a decade ago Joseph Head[1] pointed out the restraining power of saliva upon lactic acid and other substances. He showed that a 1 to 500 lactic acid and water may in some instances turn tooth enamel white in one-half an hour, while in other cases it may not turn it white in several weeks and yet the latter solution would turn blue litmus red and possess an acid taste. He also showed that the saliva of an individual may change from time to time.

Dr. Kirk[2] has called attention to the possibility of mucin being a protective element in the saliva which prevents the action of dilute acids upon the teeth. He has also called attention to a quite analogous phenomenon, in which he showed that both acid and basic sodium phosphate may exist in the same saliva and not be neutralized by each other.

With further reference to the solubility of cements it should be remembered that debris and food particles may restrain the action of acids in much the same manner as mucin or other constituents of saliva.

Inasmuch as calcination or nitration of zinc oxid lessens its solubility, it is natural to expect the yellow cements to be more insoluble than the very light ones. It is possible, however, to make a very light

[1] Dental Cosmos, 1908. [2] Ibid., lii, 735.

cement yellow by heating it with the bismuth-tri-oxid that is often used which would not lessen the solubility. The average yellow cement, however, is not made this color this way, which makes it generally safer to choose the yellow cements where this color is not objectionable and the maximum insolubility is desirable.

Furthermore, cements which have a given solubility when tested by the manufacturer may show a different solubility test when tested by someone else if the instructions of the maker have not been followed closely. In fact, such influences as temperature and humidity which are usually neglected by those inexperienced in testing these products are likely to mislead the novice. Fully as important as these, however, is the consistency of the mix. If the manufacturer of one of these products has after long experimentation so balanced his product that there is a minimum of solubility, it is likely that another consistency of the mass than the one used by the manufacturer will show another rate of solubility. With some cements this is known to be the case. With all others it is probable. A hardened mass of cement mixed to such a consistency that it may be handled with the fingers without sticking to them contains many granules of zinc oxid which have been attacked only slightly, if at all, by the liquid. As a rule such a mass possesses not only quite a different solubility than a hardened mass which was mixed so that it would drop easily from the spatula, but also different strength, volume change, adhesion, etc. Solubility, therefore, is dependent, to some extent, upon the consistency of the mass. (See Mixing Cements.)

From these data it does not seem possible to establish a standard by which the solubility of cements can be determined in advance of clinical use for the reason that there are too many variables. Laboratory tests furnish excellent guides to what may be expected in practice if conducted under fixed conditions, but if they are not conducted under fixed conditions they are often worthless.

Volume Changes.—The better cements are tested for volumetric change at the time of making the mix and during the setting. On account of the energetic action between the ordinary cement liquid and powder it is very difficult to learn the first movement that takes place during the initial stages of setting. With some of these products the first movement will have nearly all taken place before a contact can be made to determine the amount of it.

It is the aim of the manufacturer of these products to have them as free from volume change as possible. If the directions that the better manufacturers place upon the packages are followed the volume change that occurs subsequent to insertion will not be detrimental to the products. If, however, no attention is given to them there may be a

marked change in volume, thereby making operations in which cements are used of less value than they would otherwise be. For example a cement which will shrink markedly when kept perfectly dry may expand very much if subjected to a water-bath during the early stages of setting. Likewise a cement which is accompanied by a certain movement when mixed thin may give a different one when mixed to a thicker consistence.

In much the same manner a cement which is mixed rapidly and for a long time may have a different movement if hastily mixed for a short time. In the one instance there is more nearly a combining weight of powder for each combining weight of liquid, while with the other there are likely to be many more combining weights of powder than of liquid or many granules of zinc oxid not acted upon by the liquid on account of insufficient mixing. Like the question of solubility, no standards have been established, and it is therefore not possible to give the same amount of data concerning this phenomenon as is possible with amalgams.

Strength.—What has been said regarding the variables connected with solubility and volume change in a general way applies to the strength of cements. Almost any strength may be obtained from 150 kg. to 700 kg. on a cylinder 1 cm. in diameter, depending upon the kind of cement, the manner of mixing, humidity of the atmosphere in which it sets, etc.

Some cements show a retrogression in strength if tested dry and after having been subjected to saliva or water. This is an indication of the destructive influence of the saliva and water, and is also somewhat of an index of the solubility of the cement.

Hydraulicity.—Hydraulicity is a term comparatively recently applied to dental cements which set promptly in the presence of considerable moisture in the atmosphere or even in the presence of water. This property seems to accompany the cements so manufactured that they are rapid setting. With a given manufacturer's cements it will be found that the rate of setting is controlled by the dentist by furnishing different grades of liquid. These are often marked "A," "B," "C," etc. Sometimes they are marked rapid setting, medium setting, slow setting, etc. It will generally be observed that hydraulicity disappears somewhat as the slower setting liquids are used. Since the rate of setting is controlled to a large extent by the amount of water in the liquid and powder, hydraulicity may be changed by exposure of either liquid or powder to the atmosphere. As a general rule the silicate cements are more sensitive to alteration than the zinc oxyphosphates. What generally happens when cement liquids are exposed is loss of water, and as a result the cement is slower setting and

less hydraulic; and when cement powders are exposed to a humid atmosphere the result is absorption of water and more rapid setting. It should be remembered, however, that the formula of the cement and the method of manufacture are factors which influence these phenomena.

Adhesion.—The property of adhesion is one that is usually developed to the highest degree in the zinc oxyphosphates. Like most other properties of cements it is influenced by mixing, humidity, consistency, etc. Adhesion gradually appears as the powder portion is added to the liquid portion up to a certain consistency for each cement and gradually disappears as a putty-like consistency is reached. For the retention of inlays, bands or crowns which are likely to be subjected to considerable stress it is desirable to have adhesion developed to the highest degree. It should be the aim of the dentist, therefore, to learn the consistency which results in the greatest adhesion.

Mixing Oxyphosphate Cement.—It is usually advisable to have everything in readiness before the powder and liquid are exposed to the air, for, as has been pointed out, both are likely to have marked changes produced in them by alteration of the water content. When the powder and liquid are placed upon the glass slab they should be mixed at once and inserted. The amount of cement to be mixed may be determined by placing upon one end of the slab, one, two, three or more drops of the liquid. On the other end may be placed a sufficient amount of powder to make either a thin mix or a thick one as the case demands. The powder should be divided into from six to eight portions before beginning the mix. One of the portions should be drawn into the full amount of liquid and thoroughly spatulated, after which another should be drawn in. This should be repeated until the consistency required for a given operation is obtained. For the cementation of an inlay a consistency that will permit the cement to drop slowly from the spatula is most suitable. For a cement filling a consistency that is thick enough to enable the operator to handle it with but little adherence to instruments is usually best. If a large mass of powder be suddenly incorporated with the liquid and stirred the result will be the generation of excessive heat, and as a result of the heat the cement will set very rapidly. If, on the other hand, the powder be added slowly and each portion thoroughly spatulated the heat generated will be conducted away by the slab. There is a marked difference in the properties of a cement which has a given consistency reached by adding rapidly a little powder thus causing the cement to set rapidly, and one which has a similar consistency reached by adding much more powder more slowly. The latter with more powder will possess many more desirable properties than the former. The aim of the dentist should

be to incorporate with the liquid all the powder possible and maintain the consistency which the operation demands. This is overlooked by many dentists and their failures from the use of cements may in many cases be traced to the use of a cement which had a consistency reached by rapid setting instead of one which had a consistency reached by the incorporation of more powder. A mass of cement which has reached a certain consistency by the addition of plenty of powder will set very quickly when it comes in contact with a warm tooth, but when set is a much better cement from every other standpoint.

Cements should be mixed upon a large glass slab that will remain cool during the mix, and should be spatulated with a large spatula that will hold a large amount of the cement mass under the spatula. Otherwise the spatulation is little more than a stirring process which does not combine the powder and liquid as well as thorough spatulation. The temperature of the glass slab should never be above that of normal room temperature, and usually it is much better to cool the slab to about 16° C. The mass should be spread well over the slab so that the temperature will not rise much above that of the slab. There is no occasion to hurry, for from one and one-half to two and one-half minutes may be devoted to spatulation and incorporation of the powder and liquid. German silver or platinum or gold spatulas are preferable for mixing the oxyphosphates and agate spatulas or some other spatulas which are highly non-corrosive and non-abrasive should be used for the silicate cements.

The technic for mixing the silicate cements varies somewhat with the different manufacturers' products, making it inadvisable to outline a technic for mixing them. It is much more likely to yield good results if the user of these products follows carefully the instructions of each manufacturer as they are issued from time to time as these cements are developed.

GUTTA-PERCHA.

The gutta-percha of commerce is the concrete juice of the Isonandra gutta, an evergreen tree of the order of Sapotaceæ, found chiefly in the Malay peninsula and archipelago. The juice is secured by tapping the cambium layer of the tree and catching the juice as it exudes. The juice thus obtained undergoes many processes for purification before it is formed into sheets as seen in commerce (see works on gutta-percha) and several more before it appears in the market for dental purposes.

"The purified gutta-percha probably consists of a hydrocarbon (pure gutta), having the formula $C_{10}H_{16}$; albane, $C_{40}H_{64}O_3$; and a variable compound named guttane. Pure gutta-percha possesses all

the good qualities of gutta-percha in a much enhanced degree, becoming soft and plastic on heating and hard and tenacious on cooling, without being in the least brittle. The resins seem to be simply accessory components which have a decidedly detrimental effect when they preponderate. Water, wood fibers, bark, sand, etc., occur as mechanical impurities of gutta-percha." (Obach.)

It will be seen that gutta-percha resembles rubber in composition, since it consists chiefly of a hydrocarbid, in which the two elements, carbon and hydrogen, are present in similar proportions. Gutta-percha resembles rubber also in its origin, both coming from the milky juice of certain trees, although some claim a superior quality of gutta is obtained by processes of extraction from the dried leaves and buds. Apart from these similarities the two substances are not so very similar. Rubber is a very elastic body, *i. e.*, it is capable of returning to its original form when a mechanical force causes it to undergo a change. Gutta-percha, on the other hand, has a tendency to preserve the change in form produced on it by the action of similar forces. Rubber containing no sulphur softens under heat, as does gutta-percha, but preserves its elasticity if the heat be kept within certain limits; beyond a definite degree of heat its physical and chemical properties are altered. Gutta-percha, on the contrary, under heat which does not exceed 110° C., is very plastic and malleable and on cooling preserves the appearance and shapes which have been given to it while in the plastic state. Several other differences between the two exist, such as the action of light, moisture, and air, the action of sulphur on the two, their non-conducting properties, etc., though the principal difference in this connection is their elasticity.

Because gutta-percha preserved the shape given to it exceedingly well for a material of its nature, it was introduced as a filling material into dental practice, according to Dr. Kirk, about the year 1847. Since that time several secret preparations have been introduced, all of which have probably been gutta-percha to which other substances have been added for the purpose of changing the physical properties by improving the desirable ones and masking or destroying the undesirable ones. One of the first to appear was by Dr. Hill, which received his name. Several analyses of Hill's stopping have been given, all of which are probably untrustworthy. Dr. Herman Prinz,[1] however, gives the formula of Hill's stopping as: feldspar, 1 part; quartz, 1 part; quicklime, 2 parts; gutta-percha base-plate, a sufficient quantity to make a stiff mass.

Dr. Prinz does not give his authority for this formula, although it

[1] Dental Formulary.

would seem that if both feldspar and quartz were added it would be done empirically. Dr. Kirk has said: "It subserved so useful a purpose that it received the tribute of wide imitation; in fact the white gutta-percha preparations of the present day had their foundation in this imitation." Undoubtedly the present gutta-perchas and their modifications have gradually developed from this preparation in the same manner that other filling materials have become very complex compounds as a result of years of study. The gutta-perchas for dental use are divided into three classes according to the temperature of softening: "Low heat," softening below 200° F.; "medium heat," becoming plastic at 200° to 212° F.; "high heat," 210° to 220° F. The three kinds are often numbered to distinguish them from each other, one manufacturer assigning No. 6½ to the low heat, No. 7½ to the medium heat and No. 8½ to the high heat gutta-percha. According to Kirk the low heat gutta-percha contains about 1 part by weight of gutta-percha to 4 of zinc oxid; in medium heat the ratio is 1 to 6 or 7; and in the high heat specimens the gutta-percha is almost saturated with zinc oxid.

In some of the products materials other than zinc oxid are used to mix with the gutta-percha. The proportions, however, remain about the same. Calcium carbonate, some of the sulphates, silica and other oxids are among the substances claimed to be substituted for the zinc oxid.

Physical Properties.—Gutta-percha in the pure state is almost colorless, the small amount of coloration varying from rose to grayish white. It is inodorous and insipid. It is naturally cellular in structure but if drawn out its texture becomes fibrous and more resistant lengthwise and less transversely. It will not break until a load of about 25 kg. per square millimeter has been applied to it. It is but slightly elastic. It is a very good non-conductor of both heat and electricity. It contracts in hardening, *i. e.*, cooling. Its density varies from slightly under that of water to slightly over it, depending upon the compression given to it in forming it into sheets. To the vital tissues it is very bland. Gutta-percha which has been in the mouth for some time often becomes harder, and its surface porosity is increased. Kirk states in regard to these changes: "The increased hardness is observed in such situations as those in which putrefactive decomposition occurs; that is, in places where there is an evolution of hydrogen sulphid; the gutta-percha apparently undergoes a species of vulcanization. It becomes somewhat porous in those situations where the formation of a solvent is active (lactic acid), which abstracts the soluble zinc oxid from the mass. The pink variety containing the insoluble mercury sulphid does not become porous but wears with a comparatively

smooth surface when subjected to attrition." This would seem to explain some of the changes very satisfactorily, but there are some where other explanations would seem to apply. For example, gutta-percha which has been exposed to air and light becomes friable like resin and its solubility in certain reagents is increased. If, however, the gutta-percha be submerged in water no perceptible change is produced. Oxygen aided by light is supposed to be the factor of prime importance in this change, and as a result the process is generally spoken of as oxidation, although some refer to it as resinification, since the extent of the change depends largely upon the resin present in the gutta-percha. Thus it would seem that oxygen produces a condition in gutta-percha quite analogous to the one observed by Kirk, which he has attributed to the action of sulphids. In both cases, however, whether the gutta-percha be in the mouth or out of it, the change is apparently what he has called "a species of vulcanization." What Kirk states regarding the porosity of the surface is probably true. It would seem, however, since the solubility of gutta-percha in alkalies increases with oxidation, that there was a chance for the surface to become porous in the absence of lactic acid. Gutta-percha in the normal condition is insoluble in dilute acids and concentrated alkalin solutions. It is soluble in carbon bisulphid, chloroform, coal-tar oils, benzol,boiling ether and oil of turpentine.

Indications for Employment.—Gutta-percha in its white and pink forms, and in the three classes, low, medium and high heat, is used as a temporary filling material for both the temporary and permanent teeth. Its non-conductivity makes it a good material to place near the pulp. Conditions are met in which the use of gold, amalgam, zinc oxyphosphates, and silicate cements alone is contra-indicated because of the close proximity to the pulp. In such cases a thin layer of gutta-percha may be placed over the pulp, after which the permanent filling materials may be inserted without serious injury to the pulp from thermal changes. It has been quite a common practice to fill deep undercuts with gutta-percha and cover it with amalgam or cement, or cement and gold, but recent requirements for better cavity formation seem to have created a demand for a harder material, and as a result the zinc oxyphosphates have been more widely used.

Gutta-percha is generally used to fill the pulp chambers of devitalized teeth, but even here it is, as a rule, conceded better practice to confine it to the root portion of the pulp cavity and to fill any remaining portions which require a similar plastic material with one of the best zinc oxyphosphates. It has been used extensively for cervical cavities in molars and bicuspids which do not extend to the masticating surfaces, but the demand for better oral hygiene is such that this practice has become

less common except for relatively temporary operations. It has been used for all classes of cavities in the temporary teeth, and often seems to be practically the only available material which will meet the requirements of these cases. There is a tendency, however, to use less gutta-percha in the temporary teeth because of the demands of orthodontists for the retention of normal contact when restoring proximate portions of these teeth. There is likewise a tendency to use it less in other locations in the deciduous teeth for the reasons previously given in regard to better oral hygiene.

To the casual observer it might seem from this that there was little use to which gutta-percha might be put. Such, however, is not the case. Instead there are a great many places where gutta-percha seems to satisfy more of the requirements than any other material. There are places, however, where its insertion represents almost anything but cleanliness. Many have a misconception regarding the impermeability of gutta-percha, and as a result are reluctant to substitute other materials when it can as well be done.

Dr. Black[1] says: "The trial that has been made of gutta-percha for the exclusion of moisture for long periods of time from ocean cables has shown its absolute impermeability." That gutta-percha, used as a cover for ocean cables, is almost impervious, is conceded, but it is to be regretted that this statement was not qualified somewhat, because as it stands the average person would take it that gutta-percha was likewise impervious in the mouth.

Attention has already been called to the fact that gutta-percha did not combine perceptibly with the oxygen of water, but that it did with the oxygen of the air in the presence of light. Under the latter conditions gutta-percha undergoes rapid decay and gives off an acrid odor. Kirk has called attention to the action of sulphids upon gutta-percha. Thus while gutta-percha is impervious when inserted it undergoes decay from at least two causes. Of course, it will remain in the mouth for a considerable length of time before the decay becomes very perceptible, but fillings of long standing will show considerable change.

Gutta-percha is still a very useful material, but it should not be allowed to remain exposed to the oral fluids for any great length of time. It may be used to set almost all kinds of crowns on roots which have been prepared for their reception, but should be allowed to remain for a comparatively short time only. Often an operation may be nearly complete, but the operator may wish to do something more before a crown is placed permanently. In such cases a little gutta-percha which has been made plastic by heat may serve to retain a crown.

[1] Operative Dentistry, vol. ii.

The same is true regarding its use for fillings. In an extensive inlay practice gutta-percha is almost indispensable as a temporary stopping from the time the cavity is prepared until the inlay is ready to be set. It is usually best not to allow much time to elapse between the preparation of the cavity and the setting of the inlay, but in an extensive practice occasions continually arise in which this is necessary. Gutta-percha may be used for sealing in treatments in the teeth when the cavity is sufficiently large to permit of its adaptation without compression of the pulp, or where the stress of mastication will not dislodge it. Dr. Black[1] states that "It should be the only material used for sealing in dressing and for the temporary stoppings in connection with treatments." As he says, gutta-percha is a trying material to handle until the technic of its manipulation has been mastered, but it is difficult to understand why he should declare that it is the only material which should be used for sealing in dressings, etc., when it is generally conceded that the zinc oxyphosphates fulfil many requirements better than gutta-percha. For example, suppose an accidental exposure is made in the preparation of a cavity of a young patient in whom the pulp is near the surface, or suppose that the exposure has been made by caries and the pulp is in a highly inflamed condition. In either case the medicinal agent would probably be mixed with one of the nicely prepared oxids as a carrying agent and placed gently over the exposure.

As a sealing for the cavity, shallow as most are, nothing would seem to meet the requirements as well as one of the adhesive zinc oxyphosphates, which could be applied without perceptible pressure. There are many cavities which present a different problem. They may be deep and easy of access. In such cases gutta-percha would be preferable to any other material.

One of the first considerations is that the surfaces to which gutta-percha is applied should be dry and free from greasy materials. This may be accomplished by the adjustment of the rubber dam or by the use of rolls and the aid of an assistant, according to the case treated. If the gutta-percha is to be inserted into a cavity the walls should be parallel or even have slight retaining points, although in most cases the cavity formation may be varied somewhat from that for gold or amalgam.

When the cavity has been prepared for the filling it is often found advantageous to moisten the walls with eucalyptol or cajuput oil. This will soften the gutta-percha somewhat and add to its adhesiveness. The gutta-percha should then be made plastic by passing it over the flame or by placing it upon one of the specially designed heaters. It is often convenient to use the different varieties of gold annealers

[1] Operative Dentistry, vol. ii.

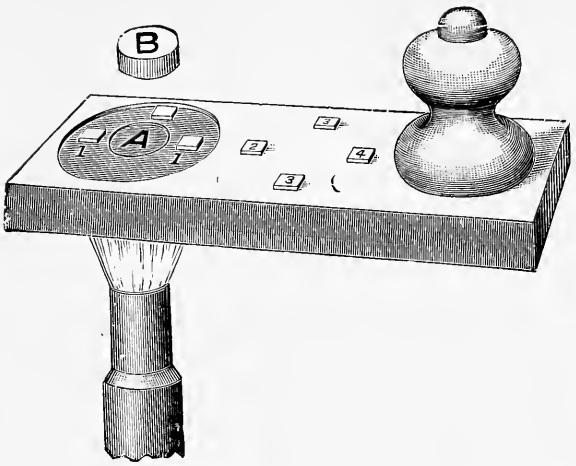

FIG. 354.—Thermoscopic heater for gutta-percha.

FIG. 355.—Flagg's gutta-percha softener and tool heater.

for this purpose. The heater most commonly used is made of steatite, and is shown in Fig. 354. The heat-retaining properties of soapstone, together with its desirable surface, make it as good a heater as any



FIG. 356.—Trimmer for gutta-percha heated by electricity.

that have been designed. After the gutta-percha has been softened it may be rolled into a single piece of a shape convenient for insertion, and packed in place with cool instruments. It may also be inserted gradually by adding piece after piece to the walls of the cavity and the

already inserted gutta-percha. This method is usually better if there is not easy access or if there is danger of compressing the pulp or forcing medicinal agents through the apical foramen in devitalized teeth. After the cavity is filled it should be trimmed to shape with the ordinary plastic instruments by warming them to a point where they will cut through the gutta-percha without tending to draw it from the cavity. The instruments should be heated gently in the flame or in one of the heaters, as shown in Fig. 355. Several instruments which are heated by the electric current have been designed for trimming gutta-percha (Fig. 356). They are very useful for some operations, but, as a general rule, a little more clumsy than the regular plastic instruments.



Fig. 357

For finishing some gutta-percha fillings where it is not necessary to direct the blast of hot air against the soft tissues the hot air syringe is useful. It may be used in heating crowns which have been set temporarily with gutta-percha. With this instrument a blast of hot air may be directed against a porcelain crown, having a metal post, until it can be removed easily. When the hot-air syringe is used to soften the gutta-percha only very sharp instruments should be used to trim off the excess, or the mass will be moved in the cavity. In general, gutta-percha should not be warmed after being inserted into the cavity, but should be chilled and trimmed with warm, sharp instruments. Gutta-percha may be trimmed into shape with the ordinary plastic instruments by warming them. It is better, however, to use more of the sharp-edged instruments, such as carvers and excavators. Heat may also be conveyed to large masses of gutta-percha, especially in removing crowns set with this material, by heating a larger burnisher and placing it upon the mass of gutta-percha. It is still better to place a good-sized piece of copper upon an instrument handle (Fig. 357).

For the use of gutta-percha as a root canal filling see Chapter IX.

Gutta-percha with Other Materials.—Temporary Stopping.—This material differs from ordinary gutta-percha chiefly in its working qualities. It is prepared from both white and pink gutta-percha by the addition of some of the gums or waxes, together with other materials such as certain sulphates, carbonates or oxids.

It is also made without the gums or waxes. It may be prepared so that it exhibits considerable adhesiveness by the addition of Burgundy pitch. These preparations are designed for a variety of purposes; their principal use is the stopping of excavated cavities for a short time.

As the name implies they are intended for work more temporary in nature than that which would require gutta-percha. As a result of their use for the most temporary operations many of the qualities of other plastics have been given to this material by the addition of some of the above-named materials. Many of these preparations remain quite hard in the mouth, although some are less resistant than gutta-percha, and more plastic in every way. The most conspicuous differences between them and gutta-percha are that they are generally softened with lower heat and have little or none of the toughness and stringiness so prominent in gutta-percha. Their manipulation is similar to that of gutta-percha.

Gutta-percha and Gum Shellac.—Gutta-percha may be mixed with gum shellac to make a stiff and yet tough material, for use largely as a base-plate. It may be used, however, for a variety of purposes where other forms of gutta-percha would scarcely be rigid enough.

Gutta-percha with Medicinal Agents.—Such substances as oxid of copper, finely divided tin, silver nitrate, eucalyptol, creosote, etc., are often incorporated with gutta-percha. It is claimed by the makers of some of the gutta-percha points supplied for filling root canals that the process of refining the crude gutta-percha removes a natural oil which should be supplied before the points are suitable for use. The addition of some of the oils in such cases not only supplies what it is asserted to have been removed, but for a time makes the points more or less antiseptic.

The other substances mentioned are less frequently added to gutta-percha. The salts of copper and finely divided tin may be advantageously incorporated when it seems imperative to leave gutta-percha in the mouth exposed to the saliva for some time. The use of gutta-percha with either of these materials is limited to remote parts of the mouth on account of their color. The manipulation of these mixtures is similar to that of gutta-percha alone. When these two materials, or other similar substances, are combined with gutta-percha, the resulting product is not unlike it, but some of the properties of the combined substance are added.

CHAPTER VIII.

THERAPEUTIC PROCEDURES IN THE TREATMENT OF INFECTED ROOT CANALS.

By HERMANN PRINZ, A.M., M.D., D.D.S.

A most serious question that confronts the dental profession today—and for that matter has confronted it in the past—is that which is involved in establishing absolute sterility of an infected root canal. The disposal of this problem in a truly scientific manner necessitates the determination of the established sterility by bacteriologic tests in each individual case. While the author realizes that the carrying out of such procedures in the average dental office of today will meet with numerous difficulties, due to the fact that the older members of our profession have not had sufficient training in these directions, nevertheless there exists no good reason why it should not be done by the recent graduate who has received adequate instructions in laboratory technic. The time is not far distant when the public will demand a laboratory diagnosis of serious root-canal infections for the same reason that a bacteriologic examination of a diphtheritic throat is demanded at present. Since the sequences of imperfect root-canal sterilization in the form of focal infections resulting in metastatic disturbances of distant organs are of common occurrence, it must follow that our present methods of establishing perfect sterility of an infected root canal are inadequate.

From a logical deduction based upon the much discussed problem of infected root canals, it is evident that its treatment resolves itself into three definite procedures: the mechanical, the chemical and the therapeutic. Mechanical manipulations are intended to dispose of the debris of the dead pulp, chemical procedures are primarily applied for the purpose of facilitating the removal of obstructions, and therapeutic applications are utilized to overcome septic conditions.

Chemical Procedures.—For the chemical disintegration of the pulp detritus, but primarily for the purpose of assisting in the opening of obliterated root canals, two specific methods are in vogue, viz., the alkali method, as introduced by Schreier in 1892, and the acid method, as advocated by the late Callahan in 1893. Schreier's alkali method intends to destroy the organic substances by means of the freshly formed hydroxids of potassium and sodium derived from an alloy of

potassium and sodium in the presence of water. Thereby the remaining inorganic debris is rendered more friable and offers less resistance to the advancing broach or reamer. Callahan's sulphuric acid treatment produces the opposite effect, *i. e.*, it destroys the inorganic substances by dissolution and carbonizes the remaining organic material. Both methods have their advocates, and as they virtually accomplish the same purpose, it is difficult to recommend one method as being superior to the other. The preference in selecting one specific method is largely a matter of personality. However, a most important physical property possessed by the alloy and not possessed by the acid should be mentioned which places the alkali treatment somewhat at an advantage over the acid treatment. This property manifests itself as a pronounced capillary affinity of the freshly formed hydroxids for moisture, and, consequently, the caustic alkali solution penetrates into those minute apertures of the root canal which a broach cannot reach and in which the acid will not flow. The author has observed that the opening of completely obliterated canals is often materially facilitated by alternating the alkali and acid methods. Both methods incidentally destroy the offensive odor of putrescence which is always very pronounced in a closed root canal and less so in an open canal. However, it should be clearly understood that the complete absence of foul odors is by no means an indication of sterility.

Dental potassium sodium (kalium-natrium) usually consists of one part of metallic potassium and two parts of metallic sodium melted together beneath kerosene. It is of a pasty consistency and resembles mercury in appearance. The alloy is supplied in small glass tubes sealed with wax or paraffin to protect it from moisture. In using this alloy a barbed tantalum or an iridio-platinum broach is thrust through the paraffin stopper or directly into the broken-off upper end of the tube. Steel broaches are not to be recommended for this work; the alloy disintegrates the metal, and, as a consequence, the broaches frequently break in the canal. The very small quantity of the paste adhering to the broach is worked into the pulp debris. At once a chemical decomposition of the contents of the root canal takes place, manifesting itself by heat and a hissing sound, with the escape of gas. Potassium-sodium alloy in the presence of water is changed at once into its respective hydroxids with the liberation of hydrogen. The hydroxids dissolve in the remaining water and form a more or less concentrated caustic alkaline solution. The putrescent pulp contains water, fat, fatty acids, gases and the debris of decomposed protein material. The rationale of the action of the potassium-sodium alloy on the putrescent pulp debris present in a root canal may be summarized as follows: fat and fatty acids are changed to soluble soaps.

The protein substances are rendered soluble by the caustic hydroxid solution and the liberated hydrogen forces the undissolved debris to the surface of the canal. The calcareous deposits in the lumen and upon the walls of the canals lose their crystalline structure and become friable and thereby offer less resistance to the advancing broach. The offensive odor of putrescence is almost instantly destroyed. Copious washing with water will remove the saponified contents of the canal, and, on drying, its clean ivory-white walls are visible. The substitution of the hydroxids of potassium and sodium for the metallic alloy is not to be recommended; their application is difficult and their physical nature does not lend itself to this procedure as readily as the alloy from which the above hydroxids are obtained *in statu nacendi* during their application. The tube containing the alloy must be hermetically sealed directly after using to prevent the decomposition of the latter by moisture absorbed from the air. If the sealing is not carried out in a proper manner the operator will find that the contents of the tube will change to a hard, crystalline mass, namely, the hydroxids of the two metals.

The sulphuric acid method for opening obstruction root canals has found many admirers among the practitioners, and it is probably more widely employed at present than any other chemical procedure. Other acids, such as hydrochloric, nitric, nitro-hydrochloric and phenol-sulfonic have been advocated for this purpose during the last twenty-five years. The strength of these various acids as used for this specific purpose should be carefully noted as it varies greatly. Sulphuric acid is usually employed in approximately a 50 per cent. solution, hydrochloric acid in a 10 per cent. solution, nitro-hydrochloric acid either pure or in a 50 per cent. solution, while phenol-sulfonic acid is used in its pure form only. The therapeutic absurdity of the last compound has been dealt with by the author on a former occasion, and consequently it is omitted in the present discussion.

Nitro-hydrochloric acid (aqua regia) as introduced by G. W. Weld in 1897 is the most efficient acid for the above purposes. It should be preserved in glass-stoppered bottles and kept outside of the operating room, as its fumes are most destructive to metallic instruments. A 50 per cent. solution of this acid may be prepared as follows:

Nitric acid	1 dram (4 c.c.)
Hydrochloric acid	4 drams (16 c.c.)
Water	5 drams (20 c.c.)

It may be applied upon a steel broach. Concentrated aqua regia has practically very little effect on steel, as the broach is at once covered by a protective oxid by the action of the evolved nitrosyl chlorid, which checks the further action of the acid upon the metal.

Whatever acid is employed it should be neutralized by sodium dioxid, as recommended by Kirk in 1893, and *not* by sodium bicarbonate, which is practically of very little value for this specific purpose. The sodium dioxid is carried into the root-canal by means of a broach previously dipped into chloroform; the latter liquid merely acts as an indifferent conveyer of the sodium dioxid to the root canal, which if water or ordinary alcohol were used readily decomposes. The chemical interchange between the various acids may be portrayed by their respective reactions as follows:

$$\begin{aligned} H_2SO_4 &+ Na_2O_2 = Na_2SO_4 + H_2O_2. \\ \text{or } 2HCL &+ Na_2O_2 = 2NaCl + H_2O_2. \\ \text{or } 2HNO_3 &+ Na_2O_2 = 2NaNO_3 + H_2O_2 \text{ and} \\ 2HCL &+ Na_2O_2 = 2NaCl + H_2O_2. \end{aligned}$$

The freshly formed hydrogen dioxid of the last reaction combines with the available hydrochloric acid and forms nascent chlorin:

$$H_2O_2 + 2HCl = 2H_2O + Cl_2.$$

There seems to be quite a diversity of opinion concerning the self-limiting action of these acids upon tooth structure. Fifty per cent. sulphuric acid solution is self-limiting; a tooth placed in this acid will be coated within a day or so on every accessible surface with freshly precipitated insoluble calcium sulphate, and consequently no further action occurs. A tooth placed in 10 per cent. hydrochloric acid, in pure or in 50 per cent. nitro-hydrochloric acid, will be completely dissolved in two or three days; these acids form soluble calcium salts. The greatest solvent power is exhibited by 50 per cent. nitro-hydrochloric acid.

From a clinical point of view it is readily understood that the small quantities of either acid pumped into a root canal when used with caution will do no harm, especially when neutralized by sodium dioxid. It is to be understood, however, that no acid should be forced through the foramen.

Therapeutic Procedures.—Soon after the inauguration of the antiseptic era in surgery (in 1868 by Lister), dentistry adopted his methods for the treatment of root canals in an empiric way by using phenol as advocated by Witzel in 1873. Since then innumerable other drugs and drug compounds have been recommended at various times for this purpose, among which may be mentioned: creosote, phenol, chlorophenol, lysol, cresol, creolin, beta-naphthol, salicylic acid, hydrogen dioxid, zinc chlorid, mercury bichlorid, silver nitrate, iodin solutions, iodoform, the essential oils, thymol, eugenol, eucalyptol, Black's 1–2–3, sodium dioxid, formaldehyd, electro-sterilization (ionization), dichloramin-T, and many others. From a clinical point of view the

cresol-formalin mixture, as introduced by Gysi in 1899 and widely popularized by Buckley in 1904, has received greater approval than any other medicinal compound recommended for such purposes. The true criterion of the efficiency of an antiseptic is its bacteriologic test upon clinical cases. The high standard of the germicidal activity of formalin has been frequently established by rigorous experiments. Clinical data collected in the early days of the use of the above mixture pointed to most favorable results. In due time, however, it was observed that while "clearing up" of an infected root canal, as far as the ordinary diagnostic evidence is concerned, as applied in the average dental office, *i. e.*, absence of foul odor, occurred much more rapidly by the use of this mixture than by employing any of the numerous other drugs usually advocated for this purpose, nevertheless secondary manifestations about the periapical tissues were of frequent occurrence. These disturbances are an indication that the supposed sterility of the canal was not obtained at the time of its treatment with the cresol-formalin mixture or that this compound produces a predisposition of the periapical tissues to future infections. To be sure, dental literature is pregnant with statements such as this (referring to the cresol-formalin mixture): "This dressing should remain for at least three days, by which time the remedy will have sterilized the entire tubular structure of the dentin, thus establishing asepsis." As no bacteriologic proof is furnished to substantiate the claim, this empirical statement does not carry any scientific weight, and it is out of harmony with existing facts. Asepsis of an infected root canal can be temporarily established by applying mechanical and chemical measures, but complete sterilization of "the entire tubular structure of the dentin" in a tooth *in situ* is impossible with the methods at present in vogue.

In regard to the application of a powerful antiseptic drug for the treatment of infected root canals, one should be always mindful of the following facts:

1. The agent must be able to develop the highest degree of antiseptic power without doing harm to the periapical tissue.
2. It must maintain its activity for at least twenty-four hours when sealed into the root canal.
3. It must not cause pain.
4. It must not discolor the tooth structure.

Of all the above enumerated drugs only a very few answer these requirements. Without entering into a lengthy discussion of the merits or demerits of these drugs, it may be stated that, in general, the aromatic series, *i. e.*, phenol and its isomers, are caustic when applied in concentrated solution. The metallic salts are strong precipitants

of albumin; incidentally, some of these salts, *i. e.*, mercury, bichlorid and silver nitrate, permanently discolor the tooth structure. Iodoform, on account of its most disagreeable odor and other drawbacks, cannot be recommended for the work and some of the iodin compounds produce lasting stains. The essential oils do not possess sufficient antiseptic power as compared with other drugs. Formaldehyd in the strength in which it is usually applied for root-canal treatment will always kill the soft tissues when brought in contact therewith either directly or in vapor form in the same manner, as the ill-fated desensitizing paste by its formalin content eventually kills the pulp through any thickness of sound dentin. As will be pointed out in detail later under Reinfection of Root Canals, no antiseptic treatment now in vogue will permanently sterilize a once infected root canal.

Of all known antiseptics, chlorin, freshly prepared, and in the presence of moisture and a suitable temperature, possesses the highest germicidal power. In suitable concentration, especially in an oily solution, it is harmless to the periapical tissues and maintains its activity for about twenty-four hours when sealed into a root canal. These oily chlorin solutions will not cause pain and they do not discolor, but rather "bleach" tooth structure.

Regarding the concentration of the solution of dichloramin-T for the purpose of treating infected root-canals, we have found that a 5 per cent. solution of the salt in chlorinated paraffin, *i. e.*, chlorcosane, answers our purpose quite satisfactorily. We have heard an opinion expressed to the effect that a 5 per cent. solution is too irritating when used in root-canal work. We cannot subscribe to such assertions; we rather believe that the pain resulting from its application was due to two causes—a spoiled solution and a faulty technic.

Solutions of dichloramin-T preserve their activity for a limited time only; they usually deteriorate within two or three months, and therefore it is best to prepare a convenient quantity which may be readily used up within a month or so. To prepare an ounce of the solution, 25 grains of dichloramin-T are placed in a dark amber-colored glass-stoppered bottle, which must be absolutely clean and free from moisture. One ounce of chlorcosane is added, the whole is thoroughly shaken and the bottle is placed in a pan containing very hot water or upon a radiator or other source of indirect heat. Within a quarter of an hour complete solution usually results. Direct heat in making the solution is to be avoided, as it is likely to injure the compound. The solution is immediately ready for use; filtering is not necessary. As stated above, only dark amber-colored or black bottles should be employed as storage vessels; blue glass does not protect the solution against the actinic effects of strong light.

Solutions of dichloramin-T must be carefully protected against heat, light, water, alcohol and most metals; in fact, most common substances have a strong affinity for chlorin, hence the ready decomposition of this solution when brought in contact therewith. Whenever the solution becomes turbid and forms a deposit of crystals in the bottom of the bottle or develops a pronounced odor of hypochlorous acid it should be discarded. Fresh solutions, if chilled, may temporarily become cloudy or even precipitate, owing to the separation of either dichloramin-T or solid paraffin. Slightly warming the solution quickly restores its usefulness.



FIG. 358.—Office-preparation bottle.

For office purposes it is best to keep the dichloramin-T solution in an amber-colored office-preparation bottle with a ground cap (Fig. 358). A small glass rod or tube kept in the bottle readily assists in obtaining the few drops necessary for each treatment, to be placed upon an aseptic glass tray. Under no condition should pliers charged with cotton, etc., be introduced into the preparation in the bottle, and no unused portions of the solution should be returned to the stock-bottle.

Dichloramin-T shares with other chlorin compounds the property of being a very active lymphagogue, *i. e.*, the amount of wound secretion, especially in the beginning of the treatment, may be considerably increased. The author's attention has been frequently drawn to this fact by fellow-practitioners who have tried the compound in treating root canals and who complained of the increased secretions from the canals, which, incidentally, influences the granulation of the wound most beneficially.

The application of the antiseptic principle as utilized in wound sterilization depends primarily upon three definite conditions:

1. Absolute contact of the antiseptic with the infecting organism.

2. Time during which this contact is maintained.

3. Sufficient concentration of the antiseptic at the point of contact.

Absolute contact between the antiseptic agent and the substances to be acted upon must be rigidly observed, as no antiseptic is known to act at a distance.

Finally the permissible concentration of the antiseptic depends largely upon the tolerance of the tissues with which it is brought in contact, and is usually obtained from clinical observation. The concentration of the antiseptic solution determines its mass action, which can be safely employed for tissue sterilization (Fig. 359).

After the root canal has been suitably prepared by mechanical and chemical means, so as to present a conical shaped tube, a freshly flamed wire is inserted to the very apex and bent so as to form a shoulder near the pulpal wall and a roentgen picture is taken. The tooth is again placed under a rubber dam, the wire is removed and the canal is

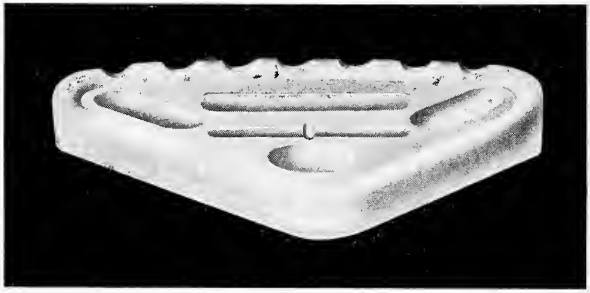

FIG. 359.—Aseptic medicament tray.

washed with sterile water and dried out. Sterile paper points assisted by a few drops of acetone or absolute alcohol and warm air are serviceable for this purpose. Fair dryness of the canal must be insisted upon, as otherwise the future treatment with dichloramin-T is materially impaired.

A suitable paper point is now saturated with dichloramin-T, carried to the root canal and with a pumping motion an attempt is made to coat the walls of the latter, and if possible a drop is forced into the periapical space. The use of the warm air blast is of material assistance in getting the oily solution into the finer ramifications of the canal. The warm air blast is recommended in this connection solely for its mechanical effect in aiding the diffusion of the dichloramin-T throughout the dentin. The natural moisture present in the tooth structure will assist in the production of the nascent chlorin from the reaction of the dichloramin-T with the water of the organic structure of the tooth.

A fresh point carrying a drop or two of the chlorin solution is now

slowly forced into the canal to its very end and immediately sealed with a suitable retainer. As we have stated above, close contact of the antiseptic solution with the walls of the root canal, and if possible with the surface of the involved infected area within the periapical tissues, is essential to obtain therapeutic results. The first application remains undisturbed for twenty-four hours. At the return of the patient the point is removed aseptically and carefully examined.

A second, a third or, on rare occasions, a fourth dichloramin-T treatment is placed in the dry canal and these applications again remain respectively undisturbed for twenty-four hours. The paper cone removed at the last sitting must show no discoloration; it must have a distinct odor of chlorin and *not* of hypochlorous acid and it must be fairly free from absorbed exudates. If possible the treatments should not be left in the canal over twenty-four hours; at the end of this time the chlorin compound is completely exhausted and usually a flow of lymph, as referred to above, is the sequence. Should the flow of lymph be rather copious a dry, sterile paper cone may be inserted for a day or two under a hermetical seal; usually normal conditions of the periapical tissues will speedily return. If at the last treatment the canal is found satisfactorily clean a microscopic examination in the form of a smear obtained from the removed cone is made. If the examination indicates sterility no time should be lost in filling the canal at once.

Regarding the existing sterility of a primarily infected root canal as treated by the above-outlined dichloramin-T method, it should be emphasized that rigorous bacteriologic tests were made in numerous instances in the routine way by plating out scrapings by incubation upon agar plates in bouillon, etc. After exposure in an incubator for various lengths of time, usually from forty-eight to seventy-two hours, it was observed that bacterial growth from the previously infected canals was negative, *i. e.*, no cultures were obtained usually after the third, and, in a few cases, after the fourth treatment.

ELECTRO-STERILIZATION.

When a solid, a liquid or a gas enters into solution and is capable of conducting an electric current, according to Arrhenius, the solution undergoes certain changes which are grouped under the generic term electrolysis. This latter term, with the following nomenclature, was introduced by the English physicist Faraday (1791–1867) and is still generally employed. The solution itself is known as the electrolyte while the dissociated products are referred to as ions. The terminals at which the electric current enters or leaves the electrolyte are called electrodes. An ion (ion = going) may be referred to as being the dis-

sociated product of a chemical decomposition which is capable of conducting an electric charge and which travels in the direction of an oppositely charged pole. Those ions, which are charged negatively, migrate to the anode, *i. e.*, the positive pole, and are known as anions, while the positively charged ions migrate to the negative pole, the cathode and are known as cations. Relatively speaking, all metals, alkaloids and hydrogen are positive ions, *i. e.*, cations, while all acids, bases, halogens, hydroxyl compounds and oxygen are negative ions, *i. e.*, anions.

As Ostwald has suggested the cation may be designated by the positive sign + or by ·, and the anion by the negative sign — or by ′. "An ion may be either a charged atom, as in the case of the silver ion, or a charged group of atoms or molecules. In the case of silver nitrate $AgNO_3$ the cation is Ag and the anion is the molecule or radicle NO_3. The charge of the NO_3 ion is one negative unit and that of the Ag ion is one of positive unit, as both the ions are monads or monatomic." (Lewis Jones.)

A simple solution of salt in water dissociates the salt into electromolecules, the ions, which exist independently of the action of a galvanic current. The number of positively and negatively charged ions is equimolecular, *i. e.*, the solution is electrically neutral. The ions themselves are suspended in the solution in a chaotic mixture. The passing of the galvanic current, according to Nernst, by its electromotive force, causes a definite movement of the ions in an orderly direction to their specific centers of attraction, *i. e.*, respectively to the positive and the negative poles.

The degree of concentration of the solution to be ionized has no effect upon the number of ions produced; the latter depends upon the strength of the current multiplied by the time for which it is applied. In other words, ionization is a manifestation of transformed electric energy in accordance with Faraday's law. The amount of decomposition of an electrolyte is proportional to the amount of electricity which flows through it.

The process of electro-sterilization of infected root canals concerns itself primarily with the disinfectant action of the liberated ions and less so with their supposed medicinal qualities. The disinfectant action is principally confined to the surface of the object treated, although a certain depth of penetration is desirable.

The electric current, *per se*, at least in the strength suitable for root sterilization, does not produce any measurable bactericidal action. A weak current passed for hours through diluted sulphuric acid prior to entering an inoculated Petri dish does not inhibit the growth. In the presence of an electrolyte the current acts on the dissociated ions

of the latter, and, depending upon their specific chemical nature, some of the most powerful disinfectants may be obtained. It is claimed that certain pure metals as such possess slight antiseptic action. This property was first observed by the late Professor Miller. According to Behring this antiseptic action is the result of the reaction of certain waste products of bacteria, primarily lactic acid, with those metals which are capable of forming soluble salts and which diffuse through the medium. This antiseptic action of metals must not be confounded with the oligo-dynamic action of certain pure metals in their colloidal

FIG. 360.—Long-handle electrode with iridio-platinum point.

FIG. 361.—Insulated electrode holder.

state, as copper, for instance, on low-type plant cells. Of the pure metals, according to the classic experiments made by Thiele and Wolf, mercury, silver and copper are the only ones which produce poisonous salts in the presence of bacteria, while the other tested metals, *i. e.*, platinum, palladium, gold, aluminum, magnesium, zinc, lead, tin and iron are wholly devoid of action. In the discussion of electro-sterilization of infected root canals great stress is frequently laid by certain men upon the specific nature of the metallic electrode placed in the root canal as being *the* factor which produces the desired germicidal effect.

Rheim, for instance, insists on using a chemically pure zinc electrode in the presence of a sodium chlorid solution, claiming that "nascent zinc chlorid" is formed during the process of electrolysis. Other practitioners employ a copper electrode and a weak zinc chlorid solution as a substitute for the sodium chlorid solution. A zinc electrode employed for electro-sterilization of root canals is not only devoid of any germicidal action, but it is also an ill-chosen metal for this purpose, because a zinc wire is too brittle to be filed fine enough to readily enter a minute root canal without inviting danger of breaking (Figs. 360 and 361).

Ionization of a metallic electrode occurs primarily in the presence of a suitable electrolyte, *i. e.*, a solution of a salt of the metal of the respective electrode. While theoretically it is true that ions of the respective electrode must be produced as a secondary sequence of the primary ionization of the electrolyte, *practically*, in employing the low ampèrage tolerated by the human body these ions are *not* demonstrable with the ordinary chemical reactions, consequently they cannot exercise any therapeutic effect. A zinc electrode in the presence of a sodium chlorid solution is *not* ionized in the short space of time and with the low ampèrage employed in the electro-sterilization of root canals, consequently "nascent zinc chlorid" ions, which are believed to have been produced from zinc electrodes, are imaginary therapeutic bodies. When a high ampèrage is employed in experimental work outside of the human body, sufficient hydrochloric acid is obtained as a secondary product which will act on the zinc pole, forming zinc chlorid.

The Electric Current and Its Accessories.—The only current suitable for electro-sterilization is the direct current. The alternating current cannot be used unless it is changed by a transformer. This may be accomplished by a chemical "rectifier" or a small motor dynamo. The chemical rectifier without potential equalizer has not been found satisfactory by the author. The source of the current may be obtained from the main line, from an accumulator or a storage battery or from a series of cells. If the street current is used it must be reduced by a rheostat to about 30 to 40 volts. A number of lamps, mounted in series, one lamp of sufficiently high voltage, or a wire rheostat, is usually employed for this purpose. An ordinary switchboard is less suitable, as there is always danger of shocking the patient through imperfect control (Fig. 362). If the street current is used a knife switch should be interposed between the rheostat and the current controller. If cells are employed—and many practitioners and most of the reliable electric supply houses regard a cell series as the safest means for the purpose in view—about 18 to 24 Leclanché wet cells or an equal number of ordinary dry cells (Columbia No. 6) are most

useful (Fig. 363). The silver chlorid cell is less serviceable for our purpose. An ordinary wet or dry cell furnishes approximately a little



FIG. 362.—Switchboard for electro-sterilization. (McIntosh.)



FIG. 363.—Galvanic battery for electro-sterilization.

over one and a half volts. Recently, compact types of dry-cell batteries furnishing a current of very low ampèrage and medium voltage, intended for wireless telegraphy, have been placed on the market.

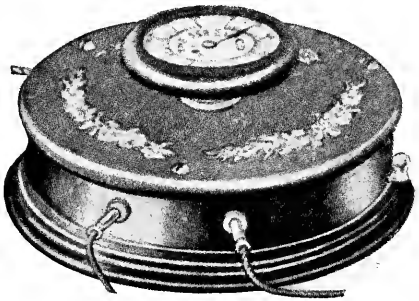

FIG. 364.—The S. S. White current controller.

These cells are mounted in series and connected to binding-posts. From these posts the current is conveyed by means of flexible conducting cords to a suitable controller (Fig. 364). The most important feature of a serviceable controller consists in the gradual increase or

FIG. 365.—Weston milliampèremeter.

decrease of the current in very small fractions of a milliampère without shocking the patient. A graphite or a series wire rheostat, either plain or as a shunt, is serviceable for such purposes. The markings

on the current controller, be they volts or arbitrary numbers, have little bearing on the practical application of the current.

The current controller, in turn, is connected with a milliampèremeter, an instrument for measuring the quantity of strength of the current (Fig. 365). The milliampèremeter is *the* instrument of precision which guides the operator in his work, consequently too much emphasis cannot be placed upon the importance of obtaining a perfect working instrument.

At this point the author may be permitted to digress for a moment from the subject proper and call to the mind of the reader the fundamental nomenclature governing electrical measurements—as far as it is utilized in the following discussion. By the term ampère is meant the unit of strength of a current. A milliampère is a thousandth part of an ampère, expressed as MA. A volt is the measure of the unit of pressure of the current, *i. e.*, the electric power necessary to drive a current of one ampère through a resistance of one ohm. It is referred to as the electromotive force and expressed as E. M. F. An ohm measures the resistance of a circuit through which a current flows.

From the above explanation, as related to the process of electro-sterilization, it is obvious that the correct measurement of the amount of current applied to a patient is of the utmost importance, as it is the safest means of guiding us during its application. Hence the importance of procuring a trustworthy milliampèremeter. The best instruments are those constructed after the Deprez-d'Arsonval deadbeat (non-trembling) type. The Weston milliampèremeter is a most reliable current gauge. The face of the latter instrument, suitable for this work, should be calibrated into 5 milliampères, with subdivisions of a tenth to a twentieth of a milliampère. To convey the current to the patient, different colored flexible cords are employed which terminate in suitable electrodes (Fig. 366). In connecting up the whole apparatus extreme care must be observed in joining equal poles to each other, namely, positive pole must be connected to positive pole, and *vice versa*. To locate the respective poles the following simple experiment may be employed. Moisten a piece of blue litmus paper with water, place the two poles of the battery about one inch apart on the wet paper and turn on the current. In a few moments a pink spot will develop where the *positive* pole touches the paper.

The two electrodes are terminals attached for the purpose of conveying the current to the patient, and consist of a negative electrode which is to be placed on the patient's skin surface, and a positive electrode to be introduced into the tooth. The negative electrode may be a piece of metallic tubing held firmly in the patient's hand, or a sponge electrode fastened to his wrist, or one of various modifications

thereof. The size of the negative hand electrode is important; it should present at least five square inches of surface area, which are to be brought into contact with the patient. A large surface of the negative electrode reduces the resistance, and consequently the tingling sensation or even blistering caused by the heat of a small electrode is



FIG. 366.—Metal negative hand electrode.

avoided. The author prefers the plain tube hand electrode, as it avoids the cumbersome wetting with salt water, loss of time in adjusting it, etc. It is immaterial in which hand the electrode is held. Rings, bracelets, wrist watches, etc., must be removed, otherwise blistering of the patient's skin by mere contact may occur. Placing the negative

electrode upon the patient's cheek, lip or gum surface by means of a clamp or spring, as recommended by some operators, is to be avoided, for the reason that severe burns may result. It has been stated that this blistering results from the formation of caustic sodium hydroxid near the negative pole. The blistering is the result of imperfect contact between the skin and the metal electrode, thereby increasing the resistance of a small area to such an extent as to produce high heat, *i. e.*, an electric burn. The positive electrode to be introduced into the tooth consists of a piece of iridio-platinum wire, No. 20 gauge, about one inch long and tapered to a delicate point. The iridio-platinum alloy possesses the necessary flexibility, which is lacking in pure platinum. The point itself is ground blunt so as to avoid being caught when introduced into tortuous canals. Various sizes of these points may be kept on hand. No other metal should be employed for such purposes. To substitute the iridio-platinum point by zinc, copper or any other metal, with the view of aiding its therapeutic effects is not only useless, but markedly interferes with the action of electrolysis in the relatively small area of a root canal and the resultant ions may discolor the tooth. A long-handle electrode holder, insulated with hard rubber, is essential to suitably unite the electrode with the conducting cord. The holders may be of various types so as to give ready access to all parts of the oral cavity. From the foregoing description of the source of the current, its control and its mode of application, it may be observed that essentially it is a duplicate of the armamentarium as applied in producing cataphoresis. Any apparatus, therefore, that is or has been used for inducing cataphoresis may be equally successfully employed for the electro-sterilization of root canals.

Electro-sterilization Equation.—In the various communications treating on root sterilization by electrolysis the very important questions concerning the *time* during which the current is applied, the *number of milliampères* employed and *bacteriologic tests* of the resultant sterility are usually vaguely treated. When sterility of a primarily infected root canal is spoken of in the present light of bacteriologic knowledge the truth of this assertion has to be proved by rigorous tests, otherwise the term sterility loses its significance. These tests are readily made by obtaining cultures at stated intervals from the canal under treatment until complete negative results of growth are obtained. Regarding the bacteriologic tests as applied to electro-sterilization, the author proceeded as follows: cultures of the infected root canal were made before treatment was instituted and then every five minutes thereafter for a given period of time, usually twenty minutes. The infected agar plates were incubated in the routine manner. Incidentally the time of applying the current and its

strength were carefully noted. By comparing the results obtained a definite relationship between the strength of the current, the time of application and the resultant sterility could be established. Zierler deserves credit for having first noted the interrelationship of these factors, and he has suggested the use of a numerical constant which furnishes a working basis for its clinical application. This constant is 30. By multiplying the number of milliampères employed by the time in minutes used in the process of obtaining a sterile root canal, invariably a number was obtained which closely hovered about the figure 30; or, reversely, by dividing the constant 30 by the number of milliampères employed a quotient is obtained which gives the time in minutes during which the current must be applied. Apparently a given infected surface area requires for its sterilization a specific amount of migrating ions; at least this assertion can be verified, as far as the germicidal action of ionized chlorin is concerned, in the sterilization of infected root canals. Hence the numerical constant 30 may be looked upon as expressing in units the surface area of an average root canal. In the author's experimental work and in clinical practice he has based his observations upon the above principle and has collected sufficient data as proofs that the appended electro-sterilization equation, as this formula has been termed, is a reliable guide for the application of these procedures in the treatment of infected root canals; 30 MA = T, the 30 representing the numerical constant, MA the number of milliampères and T the time in minutes.

Clinical Application of Electro-sterilization.—To convey to the reader a practical working knowledge of the clinical application of the principles of electro-sterilization it is probably best to describe the actual *modus operandi* in detail as employed in a typical case. The patient seated in the chair is covered with a rubber apron sufficiently large to reach over the chair arms, so as to protect him from accidental shock by "grounding" the current. The root canal of the tooth to be treated must be mechanically cleansed of its debris, and if necessary enlarged so as to give free access to the wire electrode. Before starting the ionizing process it is best to assure one's self of the correct working of the current by bringing the two poles together for a moment; the moving of the needle of the milliampèremeter in the right direction acts as an indicator that the apparatus is in working order. The rubber dam having been adjusted the root canal is now flooded with a 1 per cent. saline solution—an S. S. W. minimum syringe is useful for such purposes. The patient takes a firm hold of the negative electrode with his hand, which must not carry rings, bracelets, etc. Before introducing the freshly flamed positive pole into the canal the operator should see that the knife switch is open, and that the controller is

set at zero. If the wire electrode fits the canal too loosely a few fibers of cotton moistened with salt water are wrapped about it. The needle is introduced as near to the apex as possible and the knife switch is closed. The controller is now very slowly turned on and the patient is told to at once raise his hand when he feels the slightest sensation. The moving needle of the milliampèremeter will indicate to the operator that the current is flowing in the right direction. When the patient raises his hand the controller is turned very slightly back, left at this point for about half a minute and again very slowly turned forward until the patient again responds or until the point of tolerance is established. This point the author has termed the "irritation point." A glance at the milliampèremeter informs the operator of the number of milliampères employed. The operator now recalls to his mind the numerical constant 30 and quickly calculates the time of his particular case of electro-sterilization by dividing thirty by the number of milliampères employed. The resultant quotient gives the time in minutes for which the current must be applied. Example: if the patient's irritation point is 2.5 MA, twelve minutes by the watch are required for the sterilization of this particular root canal. If the resultant quotient is a fraction the author recommends that the next higher unit be substituted as the indicator of the time. Each root canal of a multirooted tooth is preferably treated separately. If a clamp electrode holder is employed to clasp the two or three wires inserted into the multirooted tooth care should be exercised to prevent short-circuiting. To avoid polarization of the positive electrode, *i. e.*, covering by a film of nascent gases which materially interferes with the flow of the current, the needle should be removed at five-minute intervals (turn off current previously!) and wiped off. During the process of electro-sterilization a drop of salt water should be added about every minute to make up for loss by evaporation. Care must be exercised to prevent short-circuiting of the current by allowing salt water to seep under the rubber dam and thus transfer the current to the gum tissue. After finishing the operation the controller is slowly turned to zero, the knife switch is opened and the electrode removed from the tooth. Never remove the electrode without having first cut off the current, otherwise the patient receives a disagreeable shock or a flash of light passing in the eyes. On passing a few fibers of cotton or a paper cone in the root canal a pronounced odor of chlorin should be perceptible. A wisp of cotton or a cone wet with salt water is placed in the root canal and the latter is closed with gutta-percha stopping. The treatment is to be repeated within twenty-four hours, and if necessary again on the third day, and the canal is immediately filled after the last treatment. A root canal should never be filled immediately after the initial treatment; an interval of at least twenty-four hours should

be allowed before doing so. Migrating ions do not develop their maximum degree of therapeutic efficiency within the short period of time during which the current is applied. It requires practically twenty-four hours to produce their full activity within the region of a root canal and its surroundings. The clinical indications of complete sterility are definite odor of chlorin and a clean paper or cotton cone after twenty-four hours' insertion. In doubtful cases sterility should be verified by a bacteriologic test. If a metal filling is present in the tooth under treatment it should be removed, because if touched by the electrode after the current is turned on it may be short-circuited through the filling and the patient will receive a shock. Moreover the action of the chlorin ions upon the metals of the filling materials results in the formation of metallic chlorids, which infiltrate the dentin structure, producing discoloration. This is particularly true in the case of gold chlorid thus formed, which by secondary decomposition stains the tooth structure a deep purple tint.

When the products of pulp decomposition pass beyond the foramen of a tooth, localized pathologic disturbances of the pericementum arise, which usually lead to the formation of an abscess. Without entering into the further discussion of the pathology of the disturbances at this moment, let us assume that the disturbances are eradicated by establishing drainage along the lines of least resistance. If the drainage takes place through the root canal this condition is spoken of, although wrongly, as a blind abscess, while if the drainage occurs through an artificially established canal through the bone and gum tissue a fistula results. Acute types of the enumerated disturbances yield readily to electro-sterilization, provided the salt solution and the positive electrode reach the seat of the infection. For the treatment of an abscess draining through the root canal the positive electrode is thrust through the foramen into the abscess cavity; the treatment of an abscess with a fistula requires a somewhat modified application. In the latter case complete communication between the root canal and the mouth of the fistula must be first established by forcing warm salt water through the canal. The root canal is now treated as outlined above; the fistula itself requires a separate application of the procedure. The positive electrode is passed into the fistula, entering at its outlet and carried along the fistulous tract until the root is felt, while the negative pole, consisting of a piece of copper wire surrounded by salt water, is placed in the root canal. The sterilization equation for this treatment is the same as already outlined. Usually the patient requires a lower milliampèrage for such work. All types of chronic abscesses will yield to this method of treatment, provided the necrotic area involved is very small and that the seat of disturbance is reached by the electrode and by the salt water.

CHAPTER IX.

THE PREPARATION AND FILLING OF ROOT CANALS.[1]

By EDGAR D. COOLIDGE, D.D.S.

Introduction.—There never has been a time when a greater or more vital problem confronted the dental profession than the present one in the proper handling of pulpless teeth. The one extreme practice of extracting all pulpless teeth or the other extreme of retaining all teeth regardless of the condition of the peridental membrane and alveolar process about their roots is not the best service to mankind. There are many teeth being extracted which should be properly treated and the roots filled and at the same time some of the profession are failing to recognize the danger to the general health of the patient in retaining badly infected teeth involving the periapical tissue. The difficulties encountered in the operation of pulp removal and filling root canals of most teeth are weighing down upon the profession and as a result the tendency to extract teeth requiring root-canal operations is becoming too general. The tooth which is saved by good root-canal filling is usually able to render a service to the patient unequaled by an artificial substitute. It requires much patience and skill coupled with perseverance to accomplish good results in root-canal filling and the operator who acquires these characteristics and takes advantage of the improved equipment and the higher standards of excellence in this work will doubtless have a degree of success in proportion to his effort.

EQUIPMENT FOR ROOT-CANAL OPERATIONS.

The equipment for root-canal operations may be grouped for convenience under the following headings:

Sterilizers.

Root canal instrument cabinet.

[1] Credit is hereby given to those in whose minds many of the ideas herein expressed originated or were developed. The continued study of the most excellent chapters on root canal operations in the two books: "Operative Dentistry" and "Special Dental Pathology" by Dr. G. V. Black has been the guiding light in my efforts to successfully fill root-canals. Dr. Black's minute description of dental anatomy and his detailed and most complete exposition of the operations on root canals have been of immeasurable benefit to the dental profession in standardizing root-canal operations and the greatest tribute to his work is the fact that hundreds of dentists are attempting to follow his teaching.

Supply bottles.
Containers.
Cotton supply.
Burs and broaches.
Pluggers.
Filling materials.
Operating tray.

Sterilizers.—Sterilization may be accomplished by the following methods:

Boiling.
Steam.
Dry heat.
Disinfectant drugs.

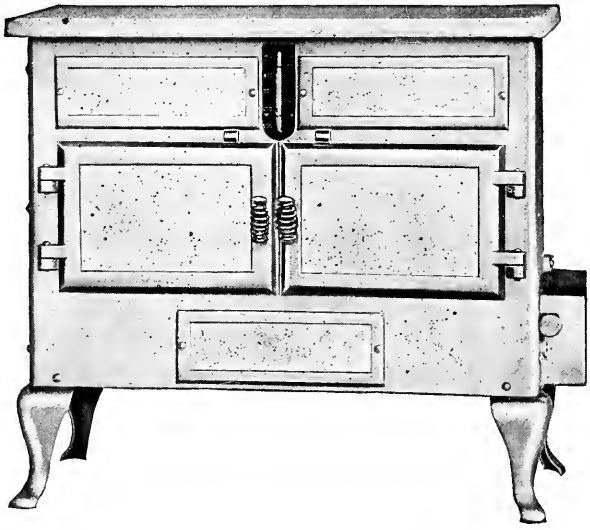

FIG. 367.—Dry heat sterilizer. Automatic control makes it possible to maintain any degree of temperature from 200° F. to 350° F. for an indefinite period. A temperature of 230° F. will sterilize in ten minutes, with a higher degree of temperature less time is required, and with a lower temperature the time must be lengthened proportionately. Especially useful for cotton, absorbent points, gutta-percha cones, napkins, dressings, etc.

The first equipment for root-canal operations is a sterilizer that is practical and efficient. For the sterilization of metal instruments most any water heater in which instruments can be conveniently boiled for at least twenty minutes answers the purpose for sterilizing by boiling and there are many satisfactory makes available for the particular needs of every office. The sterilization of dressings, cotton, towels and other root-canal materials has become a necessity for the dental office and it is necessary to have a suitable sterilizer for this purpose (Figs. 367 and 368). Simplicity is an important item in the construction and operation of a sterilizer for dressings and other materials for root canal

work. If the operation of the sterilizer is too burdensome or there is too much time lost in sterilization there is a great temptation to neglect this most important procedure. The initial cost should not be so great



FIG. 368.—Steam chest sterilizer. Moist heat may be obtained varying from 190° F. to 215° F. and can be maintained for an indefinite period. It is necessary to maintain this temperature at least thirty minutes and is safer to sterilize three successive days before using the materials under sterilization. Especially useful for materials used in root-canal operations as Fig. 367.

as to limit the use of proper equipment in any office. There are some objections to boiling broaches, especially those with barbs. These may be subjected to dry heat at 230° F. for ten minutes or they may be

immersed in a 10 per cent. solution of lysol in water (Fig. 369). For barbed broaches, root files and surgical knives this form of sterilization is quite satisfactory if all organic matter and debris are thoroughly cleansed from the instruments before immersing them in the solution. The solution should be renewed daily. While the operation is under-



FIG. 369.—Biddle broach sterilizer. Compartments to keep broaches separate while in lysol solution.

way, broaches should be immersed in 95 per cent. phenol followed by alcohol before each insertion into the pulp chamber and canal. This necessitates a suitable container for these liquid sterilizing agents which is convenient and attractive. The container or medicament tray (Fig. 370) should be kept before the operator constantly and used for the purpose of maintaining asepsis of the broaches during the

operation. It is quite as important to provide against contamination of the instruments while operating as it is to start with sterile instruments and this method of immersing the broach is simple and convenient and soon becomes a matter of unconscious habit.



FIG. 370.—Medicament tray. Convenient tray with compartments for phenol and alcohol to sterilize broaches while operating. Other compartments for other drugs and for broaches.

Root Canal Instrument Cabinet.—The equipment for root-canal operations should be kept separate from the other operating instruments. The large instrument cabinet has no satisfactory place in which to keep these instruments and materials. They should all be kept together as a unit in a small cabinet separated from all other equipment and as an aseptic precaution should be constantly subjected



FIG. 371.—Root canal instrument cabinet. Air tight cabinet for formaldehyde sterilization. Shelves being removable make convenient operating trays with complete equipment for operation in place.

to formaldehyde to maintain sterilization (Fig. 371). The cabinet shelves should be removable so that the entire contents of a shelf may be taken out at one move to be used as an operating tray carrying the entire operating unit. This shelf containing all the instruments and materials makes an ideal aseptic operating tray to be placed upon the bracket before the operator.

Supply Bottles.—It is quite necessary to have a stock of broaches sterilized, ready for use and kept within easy reach while operating, for one is often compelled to draw upon the surplus supply during an operation. By placing the stock in small screw top glass bottles



FIG. 372.—Broach bottles. Screw top bottles for surplus broach supply. Broaches sterilized and kept ready for use.

(Fig. 372) the operator can see at a glance when the stock is low and order before the supply is exhausted, saving much inconvenience.

The drugs which are regularly used may be kept in dropping bottles to save time and inconvenience. Glass dropper stoppered bottles

FIG. 373.—Glass dropping stoppered bottles. For dropping drugs upon the medicament tray instead of dipping into bottles.

one-half ounce in size (Fig. 373) make very satisfactory containers for daily use. The habit of dipping into bottles containing drugs should be discontinued.

Chloropercha can best be kept in a small bottle with a glass cap top

from which a small portion may be removed when needed for the operation.

Containers.—In operating in root canals it is necessary to use many small instruments of different sizes as well as several drugs. In order to accommodate these various articles during the operation it is well



FIG. 374.—Glass container for gutta-percha cones. Gutta-percha cones cut in short lengths ready for use.

to have several small glass or porcelain dishes (minim trays) for the broaches, small cups for different drugs for use during the operation thus to avoid dipping into the medicine bottle. A suitable dish with compartments for different sizes and lengths of gutta-percha cones (Fig. 374) may be obtained which accommodates these various pieces without their becoming mixed, thus conserving the operator's time as they should always be prepared for use by the assistant in advance.

FIG. 375. — Absorbent paper point.

The Cotton Supply.—The cotton supply for root-canal operations should include sterile cotton pellets and absorbent paper points (Fig. 375). There is no need for loose cotton. It is not necessary to wrap cotton upon a broach since the advent of the absorbent paper point. The method of keeping cotton constantly before one in an open jar and rolling it with the fingers should be abandoned because it is not aseptic without sterilization after being handled. Sterilization of cotton wrapped upon a broach is easily overlooked or neglected, hence it is far safer to abandon the loose cotton than to attempt to sterilize it after wrapping it upon the broach. When the broach is removed from the canal it usually carries debris or organic matter which must be cleaned from it. A small square of sterile gauze or muslin, five inches each way fastened to a corner of the towel covering the patient, is a

clean and convenient means with which to remove such debris and adds to the neatness of the operation. A pair of small scissors is necessary to cut pellets or points to satisfactory size.

Burs and Broaches.—There is a great variety of burs and broaches which may be used to advantage and different operators might vary in their selection. The spear drill for straight or contra angle hand-piece for cutting enamel; the cylinder or fissure bur No. 59 and the large



FIG. 376.—Short handle barbed broaches.

round bur No. 7 are all that seem necessary. The Gates-Glidden burs are very useful in opening the mouth of the canal to facilitate entering the canal with the broach.

Broaches should be selected in graded sizes from the XXX (triple X) fine to the fine in both smooth and barbed broaches. Short handled broaches (Fig. 376) are superior to long ones as the sense of touch is lessened in proportion to the distance from the working point. Metal broach handles should be used because of convenience of sterilization



FIG. 377.—Root canal files.

and in order to economize the operator's time it is well to have one for each size of broach to be used. The handles should be marked to prevent loss of time in looking for the proper size. The root canal file (Fig. 377) is an indispensable instrument for enlarging canals and should be used in the various graded sizes from extra fine to coarse.

Root Canal Pluggers.—The pluggers (Fig. 378) for packing the gutta-percha into the canal should be slender and long with sufficient

temper to stand considerable pressure. Untempered pluggers are of little use in packing. The Kerr Nos. 1–3–5 or the S. S. White Nos. 34–36–39 answer the requirements and are satisfactory and sufficient for usual cases.



FIG. 378.—Root canal pluggers.

Filling Material.—As a temporary sealing for the tooth between appointments, base plate gutta-percha has many advantages. It is easy to remove at the next sitting and if properly manipulated will seal the cavity from moisture. However, care must be used to prevent pressure upon the dressing or any contents of the canal which might be injurious to the periapical tissue. Gutta-percha unless carefully used will cause the fracture of the crown of the tooth weakened by the extensive drilling necessary to thoroughly uncover the canals. The

most satisfactory method of sealing is gutta-percha beneath covered well with temporary cement. Soft temporary stopping should not be used for root-canal operations.

Requirements of a satisfactory root-canal filling are as follows:

It should be plastic so as to be easily manipulated and carried into all parts of the canal.

It should not be irritating to the periapical tissue.

It should not absorb moisture.

It should be a non-conductor of thermal change.

It should not be soluble in the fluids of the body.

It should not shrink or change form after insertion.

It should be opaque to the Roentgen ray.

Up to the present time gutta-percha comes the nearest to meeting the requirements of a successful root-canal filling material. It can be made plastic by dissolving in chloroform or by softening with heat so that it can be forced and packed into all parts of the root canal. The

FIG. 379.—Gutta-percha cones.

addition of a few grains of resin or some antiseptic drug to the chloroform before adding the gutta-percha is recommended by some operators, but the advantages claimed for such drugs seem to be of little value and often they increase the difficulties of root-canal filling. The great problem of root-canal filling is the removal of the organic matter from the canal and wherever that may be removed gutta-percha can be placed to mechanically fill the space. If organic matter is left in the canal it will decompose and the presence of any drug is of little value to counteract the products of such decomposition. The ultimate purpose of filling root canals is to completely fill them and to maintain a healthy periapical tissue. This tissue is subject to injury by *mechanical irritation*, by *chemical action* of drugs or by *bacterial action* when invaded by virulent organisms which cause a destructive inflammation followed by suppuration. The filling material should be selected with the consideration of the effect it might have upon the periapical tissue should it escape through the apical foramen. The complete filling of the

canal is of great importance and this is a very difficult thing to accomplish without the escape of some of the material through the foramen.

Gutta-percha answers the requirements quite well. The tissue will accommodate itself to it although a mechanical injury is produced where it passes beyond the apical foramen. It does not absorb moisture nor is it soluble in the tissue fluids. It will not shrink away from the walls of the canal unless some other substance is added which will dissolve or evaporate. Solutions of gutta-percha will shrink but short pieces of gutta-percha (Figs. 374 and 379) softened and packed under pressure into a dense mass will not shrink and the filling will be impervious to moisture if it seals the canal at each end.



FIG. 380.—Operating tray. Aseptic tray from root canal instrument cabinet containing complete equipment of instruments and materials used in the operation. Always ready to use if sterilized before replacing in cabinet.

The Operating Tray.—The operating tray (Fig. 380) is simply a sterile tray or perhaps a shelf removed from the root canal instrument cabinet with sufficient room upon it to hold all the instruments and materials necessary for the operation. There are two distinct advantages in this plan. First, *cleanliness* and second, *convenience*. If the shelf or tray is prepared after each operation before replacing it in the cabinet it is in readiness when needed with every instrument sterilized and all sterile material in place upon it. This procedure encourages carefulness and cleanliness in the operator and assistant and gives the patient a feeling of confidence in the cleanliness of the operator and his work.

Upon the tray should be the aseptic medicament tray and several small porcelain minim trays for broaches of every size and style needed for the operation, sterilized cotton pellets and absorbent points, metal

broach handles and root canal pluggers, an acid loop and a pair of scissors and any other instruments or materials needed in the operation (Fig. 380).

ASEPSIS IN ROOT-CANAL OPERATIONS.

Asepsis in root-canal operations is as important as it is in any surgical operation. Doubtless, a large percentage of the infected conditions found in the periapical tissue about the roots of teeth originated in infection introduced during the operation of filling the root. At the present time there is no way to differentiate between the various causes of the infections found in the periapical tissue about the roots of pulpless teeth. It is evident, however, that in a very large percentage of all cases showing absorbed bone areas about the root apices the root is not well filled. A careful survey of a large number of roentgenograms of pulpless teeth and an accurate record of the condition found show substantial clinical evidence in favor of the right kind of root-canal filling. The report of such a survey by Dr. Arthur D. Black,[1] covering roentgenograms of 1500 root-canal fillings, shows an interesting record. Dr. Black classified the fillings according to large and small canals and good and poor fillings. The roots with large or small canals showing mechanically *good fillings* had an evidence of *periapical disturbances* in *only about* 10 *per cent.* of them while the large or small canals showing *poor fillings* gave evidence of periapical disturbance in about 65 *per cent. of them.* This tabulation was made in 1918, and there is no doubt that a very large percentage of the operations was completed before the campaign for greater asepsis in root-canal operations had been generally effective. It is safe to assume that with the aseptic precautions that are being used in the operations of today a much better showing will be made in a similar survey a few years hence. Root-canal fillings which the roentgenogram shows to be mechanically perfect usually have a healthy periapical tissue so with the proper methods of asepsis in these operations of today there should be a decided improvement in the future record of results.

The Instruments and Materials.—Under the heading of Sterilizers, several methods of sterilization of root-canal instruments and materials were mentioned. The all-important point is that adequate sterilization must be used. *It is not difficult to find suitable equipment for this but it is somewhat difficult to work out a routine of practice that is practicable and efficient.* When constant use is made of different instruments, all very small and hard to handle, *the routine should be as simple as is*

consistent with thoroughness so that adequate sterilization may never be neglected by either assistant or operator.

The cabinet containing the root canal unit constantly subjected to formaldehyde will maintain sterilization and keep instruments and materials previously sterilized ready for immediate use. They may be sterilized just previous to the operation if desired. There will not be the danger of neglecting sterilization, however, when the cabinet contains the instruments and materials always in readiness for use. Here again the time-saving method of having a removable cabinet shelf to use as an operating tray (Fig. 380) with all materials and instruments arranged for the operation is a decided advantage.

The operation upon the root canal may now be begun in an aseptic manner. To maintain asepsis during the operation the aseptic medicament tray (Fig. 370) containing phenol and alcohol should be before the operator constantly to dip the broach in each time before inserting it into the canal. This should become a matter of unconscious habit.

Preparing the Field of Operation.—It is needless to say that the rubber dam must be used in all cases of root-canal operations. When the tooth is badly broken down it becomes necessary to cement a thin copper band around the tooth to support the clamp to hold the rubber in place. If the band be properly fitted and cemented to place without interference with the occlusion it may be left upon the tooth until the root has been filled. There are special clamps for roots previously prepared for dowel crowns which will crowd the gum back and grip the end of the root in almost all cases, thus saving the time required to fit a copper band. The canal should never be open without the rubber in place. The rubber isolates the field of operation which is absolutely necessary to perform an aseptic operation. Just before adjusting the rubber the gums and teeth should be sprayed with an antiseptic wash and tincture of iodin painted on the gum and teeth adjacent to the tooth to be operated upon. When the rubber is in place the surface of the teeth included within the field should be again washed with tincture of iodin.

CLEANING AND ENLARGING THE CANAL.

1. **Gaining Access to the Pulp Chamber.**—The crown of the tooth should always be cut away sufficiently to expose the entire pulp chamber to view and show the openings of the canals. It is not possible to successfully manipulate broaches around curves and angles, therefore as many as possible of such obstructions should be eliminated by cutting away the enamel and dentin covering the pulp chamber. It is far better to sacrifice a little tooth structure which obstructs root-canal

operations than to work at a great disadvantage and perhaps fail to thoroughly clean and fill the canal.

Incisors and Cuspids.—Incisors and cuspids can best be treated through a small opening near the center of their lingual surfaces. However, when the tooth presents with a cavity on the mesial or distal surface through which access to the canal may be obtained with very little further cutting of the enamel it is better to make the entrance through the cavity. When entering on the proximate surface the opening of the canal should be cut well over toward the cavity to enable easy entrance of the broach into the canal. Both mesial and distal horns of the pulp chamber must be carefully opened and cleaned to prevent subsequent discoloration of the tooth.

Bicuspids and Molars.—In exposing the pulp chamber of a bicuspid or molar the tooth structure should be cut away according to the requirements of each case. The occlusal opening on a bicuspid should be extended buccally and lingually sufficiently to enable the operator to see the mouth of each canal. The entire roof of the pulp chamber should be cut away and the mesial wall beveled to facilitate access with the instruments. The molar crown should be cut both in a bucco-lingual and a mesio-distal direction according to the shape of the pulp chamber and the location of the canal openings. The upper and lower first molars require considerable cutting toward the mesio-buccal angle, for usually the mesio-buccal canal is located directly under the apex of the mesio-buccal cusp. The entire roof of the pulp chamber should be cut away and frequently the wall on the buccal needs cutting back because the canal lies so close in the angle of the pulp chamber. If the tooth presents with a disto-occlusal cavity it is best to seal it with cement and open directly on the occlusal surface cutting well to the mesio-marginal ridge. Should the tooth contain a good filling on the mesial surface extending on the occlusal surface it is better to remove it and enter the pulp chamber with convenience than to leave it to become an obstruction later and thereby interfere with the success of the operation. Each tooth requires a little different cutting, for there is a slight variation in the shape of the pulp chambers and location of the canals of each. There is a marked variation in the first and second upper molars. However, the location of the mesio-buccal canal is usually directly beneath the apex of the mesio-buccal cusp. The opening of the canals in the floor of the pulp chamber are usually located so that if lines should be drawn connecting them they would form the sides of a triangle (Fig. 381).

The opening of the canals should not be disturbed until the pulp chamber is entirely opened so that all cuttings may be blown away without allowing them to enter the canals to clog them up. Often it is

necessary to bevel the mesial wall toward the mesio-marginal ridge and cut away part of the buccal and lingual walls to bring the opening of the canals into view.

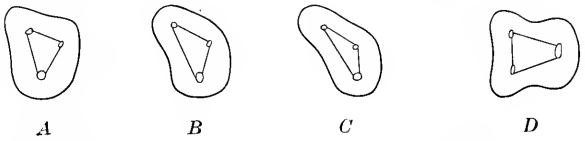

FIG. 381.—The molar triangle. Imaginary lines drawn between canal openings in pulp chamber. Drawings to illustrate location of canals in different forms of teeth. *A*, *B*, *C*, upper molars; *D*, lower molar.

2. **Gaining Access to the Apical Foramen.**—The object of filling root canals is to seal the apical foramen after the organic matter of the pulp tissue has been removed. This objective can only be attained when there is sufficient access to the foramen to enable the operator to cleanse the canal thoroughly and pack gutta-percha into the space. The large canals seldom give much trouble but the small canals like the mesial canals of lower molars and the buccal canals of upper molars and the upper first bicuspid canals are difficult to enlarge and cleanse and when the roots are curved or there is secondary dentin present to obstruct the canal the difficulty is greatly increased.

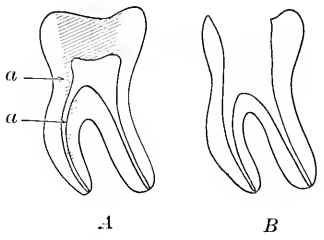

FIG. 382.—Gaining access to the apical foramen. *A*, Drawing to illustrate curved mesial root of lower molar. *B*, Drawing to illustrate straightening the canal. The obstructing dentin should be removed to allow a straight instrument to pass as far as possible, leaving only one curve to travel. Obstructing dentin at (*a*) should be carefully filed and cut away without making a ledge in the dentin.

The process of cleansing and enlarging the canal also straightens it and the more nearly straight it becomes the better access is obtained. A careful study should be made of the roentgenogram of the tooth before entering the canal and the obstructing dentin should be cut away as much as possible to allow more direct entrance into the canal (Fig. 382). When the finest broach will pass to the foramen of the root, and it usually will if the attempt is made before any other instru-

ment has been inserted into the canal, the process of cleansing and enlarging should be completed successfully and the canal filled perfectly. There are many difficulties to encounter during the process of enlargement, such as packing debris into the apical third of the canal, making a ledge on the side when the broach fails to follow a curve in the canal, or losing the tip of a broach on a curve; anyone of these three misfortunes makes the foramen inaccessible and a complete canal filling impossible. A brief consideration of these difficulties follows: to remove the debris from a canal does not seem to be a serious problem and is not if the broach used for cutting is frequently removed and the debris cleaned off. The files are very useful for enlarging but they do not remove the debris very well, so it becomes necessary to follow them with a very fine (XXX) barbed broach to rake out the filings and shreds of organic materials. This is attended with considerable danger of losing a point of the broach for the canal is very small and perhaps curved and the slightest binding of the barbs upon the side of the canal may cause a piece of the broach to break away and plug the canal at that point. Another difficulty, that of making a ledge or losing the canal, is caused by using too large a broach which will not follow the curve in the root and consequently bores a depression in the dentin at the curve instead of following the canal around the curve. When a curve is encountered the walls must be carefully filed away with small files to straighten the canal to give *access to the foramen* (Fig. 382). The opening of the canal in the pulp chamber may be enlarged with a small Gates-Glidden drill to facilitate locating it, but the point of the instrument must always be kept in the canal to prevent making a false pocket which would be a great handicap in the following operation. The curves should be carefully filed away and the debris removed, using the finest broaches until the foramen is reached. A broach should never be used which is too large to pass to the foramen each time until the canal has been enlarged and straightened to remove the danger of losing the canal and making a false pocket in the dentin.

3. **Checking up by Roentgenogram.**—A roentgenogram should be made of every tooth requiring treatment *before beginning the operation* in the pulp chamber or canals. Sometimes the roentgenogram will show a condition which makes canal operations inadvisable because of crooked roots or obstructed canals and very frequently the periapical tissue will be found so badly diseased that the retention of the tooth might be a menace to the general health of the patient.

When the operation is under way and there is some *difficulty encountered* or some doubt as to the progress of the operation it is well to insert a wire in the canal allowing one end to be flush with the occlusal surface of the tooth (Fig. 383) and, after sealing up the cavity with temporary

stopping, a roentgenogram should be taken to check up the work to this point. This is a great aid to the operator and requires but very little time and inconvenience especially where the operator makes his own roentgenograms.

When the canal is ready to fill a small stiff root canal plugger like Kerr No. 1 or the S. S. White No. 34 should pass to within three millimeters of the apical foramen (Fig. 384). The space between the end of the plugger and the apical foramen is the most important portion of the canal and the future health of the periapical tissue is largely dependent upon the successful filling of this part of the canal, especially of the larger canals.

4. **Measuring Length of the Canal and the Diameter of the Foramen.** —The length of the canal is determined by the length of the measure wire inserted before taking the roentgenogram. The roentgenogram shows the relative length of the wire in comparison to the root. The wire should be cut so that one end is flush with the occlusal surface when it is in the canal. Frequently the roentgenogram gives an elongated or shortened picture of the tooth and the inaccuracy of the picture can usually be estimated and added to, or deducted from, one end because the other end of the wire is even with a definite surface landmark from which measurement can be calculated.

The diameter of the apical foramen may be calculated by the size of the plugger which will pass to it, or by an absorbent paper point with the small end clipped off until it will just reach the foramen but not pass through.

Now with the measure wire corrected to the proper length and with a fairly close measure of the diameter of the foramen the filling of the canal may be started.

FILLING THE CANAL.

When the canal has been thoroughly cleansed and enlarged to accommodate instruments suited for packing gutta-percha to the apical foramen it is ready for filling unless some complication is encountered. The canal must be dry and aseptic and the apical tissue in a healthy condition before a successful root-canal filling can be inserted.

The measure wire and the absorbent point used to ascertain the length of the canal and the diameter of the foramen should be upon the tray before the operator. The plugger which will pass to the apical third of the canal should be marked or bent so as to show when it is within three millimeters of the apical foramen when placed in the canal. When it is in the canal as far as the mark, the operator has only to estimate the small space between the end of the plugger and the fora-

men (Figs. 384 and 385). This is the most important part of the entire filling and the more successful the operator is in thoroughly sealing the apical foramen without injury to the periapical tissue the nearer will the result approach a perfect operation. The gutta-percha cone

FIG. 383

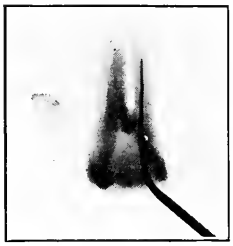

FIG. 384

FIG. 385

FIG. 383.—Measuring length of canal. Wires flush with occlusal landmark.

FIG. 384.—Plugger No. 1 inserted in buccal canals. The bend in shank indicates the distance necessary to insert.

FIG. 385.—Plugger to reach within 3 mm. of foramen. The space between the plugger and the foramen is the most important of the entire space to be filled.

suitable for the canal should be selected and cut in pieces of about three millimeters in length. It is necessary to use many more of the small ends of the gutta-percha cone than the other pieces, therefore it saves time to have a dish with compartments to contain cut cones of

FIG. 386

FIG. 387

FIG. 388

FIG. 386.—Plugger No. 1 carrying first piece of gutta-percha cone selected to seal the apical foramen. Plugger is inserted to bend in shank and gutta-percha should just reach the apical foramen and be large enough to prevent passing through the foramen.

FIG. 387.—First piece of gutta-percha cone packed in place sealing the foramen. If measurement is accurate there should be no excess filling. The second piece is packed against this with considerable pressure followed with piece after piece, until the canal is full.

FIG. 388.—Canals filled. Short pieces added one by one in same manner, packing each thoroughly until the roots are all filled.

different sizes (Fig. 374). The larger sizes, Nos. 3 and 6 (Fig. 379) furnish the best first points to be used in plugging the foramen while the smaller sizes 8, 10 and 12, furnish better pieces for filling the middle third of the canal.

The point piece of gutta-percha suitable for plugging the apical foramen should be selected and placed upon the end of the root-canal plugger. The plugger should be heated slightly in the flame so that the gutta-percha will adhere to it when pressed upon the larger end of the piece.

The canal should be dry before filling. It should then be slightly moistened with eucalyptol throughout its entire length. A very small amount of chlorapercha may be carried into the canal to adhere to the walls and to help in filling all the open space in the apical portion of

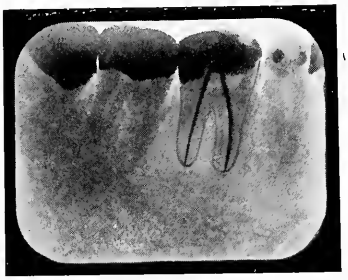

FIG. 389.—Wires measuring length of lower molar canals. Tooth in position.

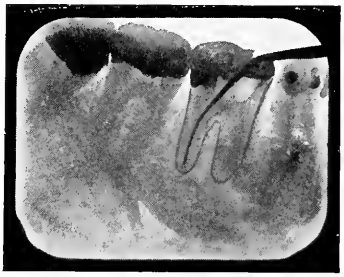

FIG. 390.—Root-canal plugger inserted in distal canal. Bend at occlusal surface marks the distance the plugger should be inserted to reach within 1 mm. of foramen.

FIG. 391.—Canals filled. Distal canal divided into two branches.

the canals. *The less chlorapercha used the more accurate should be the result* since it is impossible to prevent overfilling when much chlorapercha is used. The large canals require less chlorapercha than the small ones since the gutta-percha points can be packed clear to the apical foramen of large canals with little difficulty. Now the plugger carrying the selected piece of gutta-percha cone should be inserted into the canal and forced slowly down till the mark or bend indicates that it has gone to place (Fig. 386). If the measurement has been accurate this will seal the foramen since the gutta-percha on the end of the plugger should just reach the foramen when the plugger is

FIG. 392

FIG. 393

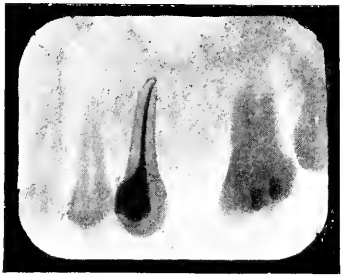

FIG. 394

FIG. 395

FIG. 396

FIG. 397

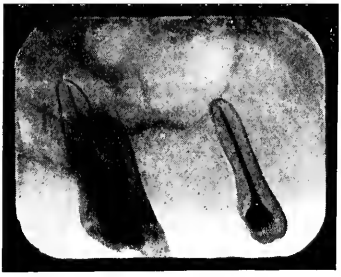

FIG. 398

FIG. 399

FIGS. 392 to 399.—Root-canal fillings. Figs. 392 and 393 show branches of the main canal have also been filled.

inserted as far as the mark (Fig. 387). This should be followed by selected pieces of cut cones softening each slightly by warming and packing them into the canal until it is filled. After sealing with a hot burnisher the filling is complete.

A roentgenogram of the tooth should be made to prove the filling (Fig. 388) and unless it is satisfactory it should be removed and the canal refilled.

TO REMOVE ROOT FILLINGS.

A gutta-percha root-canal filling can be removed easily by heating a small root-canal plugger or explorer and softening it as much as possible, then by flooding the pulp chamber with chloroform or xylol. The last named drug will soften gutta-percha very rapidly but care must be used to prevent it passing through the foramen, as it is quite irritating. Xylol should never be sealed in the tooth. Chloroform or eucalyptol may be sealed within the pulp chamber for twenty-four hours to a good advantage in some cases. Root-canal fillings of cement are extremely difficult to remove as this material is so hard that the instrument will not follow it. Hydrochloric acid will sometimes assist but it must be used with great care and must be neutralized with a solution of sodium carbonate. The difficulty of removal is one of the chief objections to the use of cement as a filling material for root canals.

RECORDING.

A complete record should be kept of every tooth having root-canal operations. The record should begin with the condition of the pulp and periapical tissue before the operations are begun. If we had a record today of the condition of the periapical tissue surrounding the teeth with root-canal fillings before they were inserted it would be possible to differentiate between some of the causes of the absorptions of periapical tissue. As we have not such a record we can only class all absorptions together. A detailed daily record of the method of pulp removal, the drugs used in the treatment and the method of sealing the treatment in the tooth should be kept. A very useful form has been suggested by Dr. A. D. Black of Chicago whereby such a record may be kept with very little inconvenience and loss of time (Fig. 400). If we record the condition of the pulp and periapical tissue of each tooth before the operation is begun and keep a complete roentgenographic record of the periapical tissue from the time of treatment, it will be of great value in the history of pulpless teeth relating to the development of future conditions. It is evident that every drug used in the treatment of pulpless teeth has some effect upon the condition

DENTAL PULP CASE HISTORY

PATIENT'S NAME _____ AGE _____

PATIENT'S NUMBER _____ ADDRESS _____

Tooth.		Diagnosis.							Color.		Removal.				Treatment.			Sealing.		Root filling.						Subsequent radiograph.				Color.	
RIGHT.	LEFT.	Vital, normal.	Vital, hyperemia	Vital, caries.	Dead, no abs.	Slight abs.	Abs. extract.	Previous R. F.	Normal.	Discolored.	Arsenic.	Cocain, Pres.	Infiltration.	Conductive.	Date, Removal.	Creosote.	Eugenol.	1-2-3.	Gutta-percha.	Cement.	Length, mm.	Gutta-percha.	C. P. and G. P.	Inaccess. apex.	Good.	Fair.	Resection.	Bone O. K.	Slight abs.	Abs. extract.	Uncertain.	Normal.	Discolored.

FIG. 400.—Dental pulp case history. Directions. This chart is printed on an envelop, the illustration being actual size. The history is to be made out as the case progresses; the radiographs of the case to be kept in the envelop. If the pulp is dead or if the root has been previously filled the patient is required to have a radiograph made before treatment is begun.

1. Enter patient's name, age and address.

2. Indicate tooth by number or letter.

3. Diagnosis: (*a*) If the pulp is vital and normal and is to be removed because a crown is to be made, or if it is accidentally exposed in cavity preparation, mark *X* in first column. (*b*) If pulp is vital and is removed on account of hyperemia which has developed into inflammation, mark *X* in second column. (*c*) If pulp is vital and exposed by caries or so nearly exposed that its removal is required, mark *X* in third column. (*d*) If pulp is dead, mark *X* in fourth, fifth or sixth column, according to the condition shown by the radiograph. It will be considered a slight abscess if any injury to the bone is shown and treatment is undertaken. It will be marked in column "Abs. Extract" if treatment is not considered advisable. (*e*) If there is a previous root filling, mark *X* in the last column also an *X* in column four, five or six, according to the condition shown by the radiograph.

4. Color of tooth: Mark *X* in proper column.

5. Removal of pulp: (*a*) If arsenic is applied, enter date in figures in proper column as 5, 2, 16. (*b*) If cocain-pressure is used or novocain anesthesia, infiltration or conductive, enter date in proper column. (*c*) Enter date the pulp is removed in proper column. This date is to be entered if arsenic was applied or if the tissues were anesthetized or if the pulp was dead.

6. Treatment: Enter date of application of medicaments. If a second treatment of the same drug is made, enter date on second horizontal, etc. Doubtless many dentists would prefer to have other drugs entered in these column headings.

7. Sealing: Mark *X* in the proper column.

8. Root filling: (*a*) Mark in first column length of tooth from occlusal surface or incisal edge in millimeters, making measurement with a fine smooth broach and using a Boley gauge. If the crown is broken off so state at bottom edge of envelop. Place diagnostic wire and have radiograph made. (*b*) Mark date in second or third column to indicate gutta-percha alone or chloropercha and gutta-percha used as root filling. (*c*) If canal is inaccessible to apex, indicate by fraction $\frac{1}{4}$, $\frac{2}{3}$ or $\frac{3}{4}$, etc., according to distance

of the periapical tissue so it is of great importance that such a record should be kept in the tooth history. The method of filling and the material used should be recorded and any other remarks regarding the nature or peculiarity of the case, which might have some bearing upon future conditions, should be kept. Teeth should be saved, not all diseased teeth, but teeth that are healthy or that can be made healthy and it is the duty of the profession to master this great problem and successfully cleanse and fill root canals so that they may be retained with safety to function in mastication as nature intended.

diagnostic wire shows in radiograph. (*d*) Have radiograph made of root filling. Mark *X* indicating whether it is considered a good or a fair filling. In case it is a poor filling a new root filling should be made, also another radiograph. (*e*) In cases of teeth having more than one canal, use a separate horizontal line for each canal and indicate each by writing the initials, as *m-l*, *m-b*, *d-b*, *dis.*, *ling.*, *buc.*, etc.

9. Resection: If root is resected, enter date in this column.

10. Subsequent Radiograph: It is the intention to send for patients to return in about six months and make a check-up radiograph. When this is done the date should be entered in the proper column, indicating the condition of the bone at that time. Additional radiographs should be made after several years.

11. Color. The color of the tooth will be marked by the date of a subsequent examination.—Dental Summary, October, 1919, xxxix, 749.

CHAPTER X.

PATHOLOGY AND TREATMENT OF HYPERSENSITIVE DENTIN.

By HERMANN PRINZ, M.D., D.D.S.

Hypersensitive dentin may be defined as a *state* in which the exposed dentin of a vital tooth is painfully responsive to mechanical, chemical, thermal and electrical irritation. The primary cause must be attributed to its exposure to an irritant. Absence of enamel or otherwise pathologically exposed dentin is the initial condition essential for its causation. Enamel, which protects the dentin of the crown, may be absent as a result of incomplete calcification, or may be lost through pathologic processes—that is, caries, erosion, abrasion or trauma, while the exposed dentin of the root of a tooth is primarily brought about by premature or senile atrophy of its protective alveolar process.

Pathology.—Before entering upon a discussion of the pathology of hypersensitive dentin the anatomy and physiology of normal dentin should be recalled briefly. Dentin is made up of about 72 per cent. inorganic salts, about 10 per cent. water and an organic matrix constituting the remaining percentage. The dentin is traversed by a very large number of tubuli measuring about $1\frac{1}{2}$ to 5 μ in diameter and radiating from the pulp cavity, more or less wave-like, toward the periphery, where they branch off, forming a deltoid network. Roemer has counted from 25,000 to 30,000 dentinal tubuli within the area of a square millimeter. The tubuli are filled with lymph and with the protoplasmic processes of the odontoblasts, as originally described by Koelliker, and they are known as Tomes's fibers. These fibers are structureless threads and are continuous through the full length of the tubuli and their branches.

Physiologically normal dentin has no sensation; its vital protoplasm transfers tactile impressions, thermal changes and chemical or electrical irritation to the pulp.

The so-called innervation of dentin is still a much mooted question. Professor Hopewell-Smith interprets its present status as follows: "It is an interesting and important fact that it has not yet been proved to the entire satisfaction of all observers that nerve fibers exist in the

dentinal tubes. Thus there is a wide difference in men's views as to the innervation or non-innervation of the dentin. One school of belief, headed by Boll, Morgenstern, Roemer, Dependorf, Fritzsch and Howard Mummery endeavors to explain sensitiveness to the occurrence of peripheral nerve fibers in the dentinal tubuli, while the other school denies the existence of nerve fibers in this tissue. Among those included in this group are Retzius, Koelliker, Tomes, Huber, Walkhoff, Gysi and Hopewell-Smith. By persistent search in teeth of mammals and reptiles no definite nervous system has been demonstrated, the nerve fibers terminating in arborizations around the odontoblasts on the surface of the dental pulp.

Impulses are carried through the dentin to the pulp *via* the contents of the dentinal tubuli, *i. e.*, dentinal fibrils, the peripheral processes of the odontoblasts, and lymph. There is an abundance of protoplasm in these innumerable channels. Members of the second school of thought are divided in their views as to the causes of sensation. The hylopathist ascribes it to abnormal movements of the molecules of the dentinal fibrils while the others claim that demarcation currents, convection and osmosis are responsible for pain. All, however, are agreed that the cerebro-spinal nervous system has no share in its production beyond that in the dental pulp."

Personally the author is in full accord with the concepts of the second school of histologists, *i. e.*, the non-innervation hypothesis of dentin. From a pharmacologic point of view he is able to furnish sufficient data to substantiate this assumption. Basing his own conception upon this hypothesis, he assumes that hypersensitive dentin denotes a state in which the contents of the dentinal tubuli are pathologically altered. This change is brought about by external physicochemical influences which interfere with surface tension, absorption and diffusion. All three of these processes are closely allied phenomena.

According to Gibb's law all substances which lower the surface tension of a solvent become more concentrated in the surface film than in the interior. It is a phenomenon which depends upon the increase of attraction of the molecules in the surface film for one another and puts the film under pressure. Thereby a hydrostatic pressure is created which materially increases the normal osmotic pressure. As a rule inorganic neutral salts and many sugars raise the surface tension very slightly, whereas acids, bases and most organic substances lower the surface tension. The colloids concentrated in the surface film become very viscous, finally forming a membrane insoluble in water. Colloidal solutions readily absorb water and dissolve salts from the surrounding medium. The absorption of water increases proportionally with the concentration of the salt solution to a certain point and

thereby an increase in the internal pressure of the colloidal solution is obtained.

Surface tension is constantly trying to reduce itself; in a uniform fluid this is impossible, while in a mixture consisting of two or more substances which in themselves possess different surface tension the lighter fluid has a tendency to collect on the surface of the more tense fluid. Under the influence of these different forces, dynamic equilibrium is established within a certain time.[1] These various factors favor mechanical absorption, reduction of surface tension, increase of solubility under pressure and compressibility of water.

Chemical absorption is of less interest in this connection. The most important factor which influences absorption is the ion concentration of a fluid. The equilibrium of a phase relative to its ion concentration is controlled by the law of mass action.

The relative viscosity of a fluid plays a most important role. If the surface of a solution absorbs a dissolved substance the viscosity of its surface may be markedly increased. As a consequence albumins, soaps, saponins, dyestuffs, etc., form a surface film which materially interferes with the diffusibility, as compared to pure water, of dissolved substances.

When the colloidal contents of the dentinal tubuli become exposed to the fluids present in the oral cavity their surface tension becomes altered by absorption and diffusion in accordance with the above enumerated physico-chemical processes; they become overdistended and thereby exert pressure upon the underlying odontoblastic cells. The fluids in the tubuli cannot be compressed as water possesses no elasticity; it represents a rigid column which transmits pressure in the form of motion undiminished in all directions. Any additional pressure which is exerted upon the overdistended surfaces is at once transmitted to the nerve filaments located at the surface of the pulp (the plexus of Boll), that is, the anatomic threshold of sensation.

Cutting the enamel does not produce painful sensation. As soon as the dento-enamel junction is reached, marked pain is usually experienced by the patient. Beneath the dento-enamel junction are located the interglobular spaces of Czermak, which are filled with semifluid protoplasm. Pressure and heat produced by the revolving bur upon a relatively large surface area of fluid in this region are quickly transmitted to the pulp, and hence pain is felt. Within the area of dentin which lies beyond this zone, sensation is lessened until the advancing bur reaches within close proximity of the pulp. In carious dentin, excavation of the zones of complete disorganization and of decalcifica-

[1] Decrease in surface tension is readily demonstrated by the following simple experiment: to 100 c.c. of absolute alcohol contained in a graduated cylinder, add 100 c.c. of distilled water. After equilibrium is established the mixture measures only 192 c.c.

tion does not produce sensation because the contents of the tubuli are destroyed. As soon as the zone of turbidity is reached, marked pain is manifested. Here the contents of the exposed dentinal tubuli are subjected to intense irritation brought about by acidity and other products of bacterial metabolism. The surface tension of the fluids in the tubuli is altered markedly, hence the quick response to pressure and thermal influences. Below this zone of turbidity the "translucent zone of Tomes" is observed in chronic caries. This translucency of dentin is the product of a vital reaction. The chronic irritation of the odontoblasts causes the pulp to respond promptly by depositing adventitious dentin within the lumen of the tubuli, which necessarily lessens their diameter in varying degrees, or even produces complete obliteration. Hence a smaller surface of the tubular contents is exposed to the advancing bur, and, consequently, lessened sensation is felt. The gradual reduction of surface area of the dentinal tubuli is a physiologic process in the life cycle of a tooth, hence sensitiveness diminishes with advancing age.

Mechanically abraded teeth or those subjected to the as yet little known process of erosion are rarely hypersensitive in the later stages. Abrasion and erosion are usually intensely chronic processes, hence their very slow progress offers to the irritated odontoblasts sufficient time to deposit adventitious dentin within the tubuli and thereby protects the underlying pulp from further irritation. Sections of mechanically or chemically abraded teeth containing living pulps always show a translucent zone.

As stated above the process of removal of enamel of a sound tooth by cutting and grinding, if done under proper precautions to avoid undue heat, is usually not painful. The freshly exposed dentin is relatively free from sensation. Within a short lapse of time, however, usually within twenty-four hours, this exposed dentin is extremely hypersensitive. The exposure of the contents of the tubuli to the fluids of the mouth, as explained above, changes the surface tension so as to cause pronounced irritation of the odontoblastic cells.

Dehydration of the overdistended tubuli by physical means relieves the hypertension; consequently, such an agent as warm air reduces the sensibility. Alcohol, potassium hydroxid or similar hygroscopic chemicals act synchronically as dehydrants and caustics. Self-limiting caustics, as silver nitrate, perhydrol, etc., superficially destroy the vitality of the protoplasmic fibers, and they protect the contents of the tubuli by solid plugs of precipitated albumin. The disturbing elements are thereby permanently excluded from reaching the dentin. The disturbed equilibrium of the tubular fluid readjusts itself in a short time and, consequently, hyperesthesia is relieved. A substantial

illustration of this fact is furnished by protecting immediately artifically exposed dentin with a coating of silver nitrate or a temporary cap set with gutta-percha and *not* with an irritating cement. Such dentin will exhibit no particular sensation at any time after the operation.

Any general condition which lowers the normal psychic reaction of a patient naturally also influences the reactivity of the tooth pulp. Therefore, such disturbances as acute nasal catarrh, influenza, exanthematous fevers, increased intradental blood-pressure, menstruation, anemia, general debility or certain neuropathic conditions, as neurasthenia, may leave their imprint upon the pulps in the form of congestive hyperemia and, consequently, any irritation of the exposed dentin of a tooth under these conditions is prone to exhibit indirectly excessive sensibility.

From the above discussion of its pathology the author concludes that hypersensitive dentin designates a state of irritation of the odontoblasts of a vital pulp. Irritation is produced only by external agents, *i. e.*, physico-chemical processes induce changes in the surface tension (hypertension) of the exposed contents of the tubuli. The increased reactivity of the disturbed equilibrium transmits any additional physical or chemical impulse at once *via* Tomes' fibers to the congested odontoblastic cells covering the pulp, which are in direct contact with the nerve fibers of the plexus of Boll, *i. e.*, the anatomic threshold of sensation.

Symptoms and Treatment.—The principal subjective symptom of hypersensitive dentin consists of more or less severe pain, which is usually elucidated by marked temperature changes, chemical irritation or mechanical interference of the exposed dentin surface. The pain is *not* continuous, it merely lasts as long as the irritant is present. The patient may present a carious or otherwise defective crown of a tooth, an exposure of its root or, frequently, an incomplete union at the periphery of the enamel and cementum at its neck. The thermal test with hot, and especially cold, water or pressure exerted by an instrument placed upon the exposed surface of the dentin is very pronounced. Changes in the color of the tooth, percussion, palpation and roentgenogram are negative. Hypersensitive dentin offers good chances for conservative treatment; under proper management it may be eradicated readily.

The rational principle of treatment should be based on the recognition of its pathologic cause, that is, hypertension of the contents of the dentinal tubuli. Any method or means which favors the readjustment of the altered colloidal equilibrium and prevents further irritation of the exposed dentin surface is useful for the purpose.

In general the remedies employed should conform to the following requirements:

1. The remedy must not injure the organic or inorganic constituents of the tooth.
2. The remedy must not permanently interfere with the welfare of the pulp.
3. The administration of the remedy must not require a complicated instrumentarium.
4. The pharmacologic action of the remedy must be exhibited within a few minutes.
5. The remedy must be readily applicable to all classes of cavities with regard to their location.
6. The remedy must not produce pain.
7. Permanent discoloration of dentin must not occur.

For convenience, we may divide the applied remedies into:

A. Physical and chemical procedures:
   1. Keen edged instruments.
   2. Caustics.

B. Local and general remedies:
   1. Local anesthetics and sedatives.
   2. General anesthetics and sedatives.

Sharp Instruments.—The superiority of sharp instruments over dull, ragged-edged tools when working upon living tissue is generally recognized by every-day experience. Sharp excavators cut without much pain when employed with a definite, precise movement at right angles to the long axis of the tubuli. Dull engine burs produce heat by friction and by being held in too continuous contact with the cavity wall. They should not only be sharp but run at high speed and allowed to touch the surface very lightly as they revolve. A thin coating of vaselin further reduces undue friction.

Caustics.—Caustics are substances which destroy living tissue by virtue of their coarse chemical or physical action. This action may manifest itself by abstracting water from albumin, by dissolution or precipitation of the albumin, by oxidation or substitution. Caustics which are employed for the purpose in view are principally dehydrants and albumin solvents or precipitants. Alkalies containing hydroxyl groups—KOH and NaOH—are very powerful albumin solvents, and they are not self-limiting. The albumin precipitants are represented primarily by the metallic salts, by certain organic compounds, as phenol, alcohol, etc., and by heat. Mineral acids should not be applied on living tooth structure for such purposes. The precipitates obtained by metallic salts differ widely in regard to their density; silver nitrate,

for instance, produces a dry, dense scab, while zinc chlorid combines with the albumin to form a loose, flocculent clot.

As we have stated above, hypertension of the contents of the dental tubuli is the primary cause of hypersensitive dentin. The removal of this tension will necessarily interfere with or prevent the transmission of impulses; hence the most simple and most logical method of reducing hyperesthesia of dentin for the purpose of excavating is to dispel the moisture from the tubuli. It has been found that desiccation of a cavity by subjecting it to a current of warm air in conjunction with absolute alcohol will bring about a condition of immunity to sensation in proportion as such desiccation is thorough or partial. To accomplish desiccation of the dentin best the rubber dam should be adjusted to the tooth and the greater portion of the carious mass carefully removed with spoon excavators; the cavity should be bathed with absolute alcohol[1] and then subjected to a stream of warm air applied in some convenient manner. The ordinary air syringe or chip-blower may have its point heated in a flame, and then, by forcing the air in the bulb slowly through the tube, a jet of warm air will be delivered into the cavity. By holding the nozzle of the syringe at the proper distance and having learned by experience how much heat to apply, one can often inject a current of air into the cavity at nearly the same temperature as that of the tooth; but if the air when it reaches the cavity should be either perceptibly above or below the proper temperature, pain will be produced. In some warm-air syringes the tube is provided with a hollow receptacle somewhere along its length, which, when heated, raises the temperature of the air within it before being directed into the tooth cavity. Neither of these methods is at all exact, and either is therefore liable to produce more or less pain in the act of dehydration. A better plan would be to employ a syringe in which a coil of fine platinum is contained within the orifice; this coil is connected by wires through the body of the syringe with a source of electric current; in operation the resistance encountered by the current of electricity passing through the platinum coil heats it and maintains a steady temperature. Air forced over this coil and through the nozzle, especially air supplied from a receiver and under pressure that can be controlled, may be heated to a temperature that will approximate very closely that of the tooth, and therefore produce little or no pain. If the air passing from the nozzle of the syringe should be too warm it can be modified by holding it a little farther away from the tooth, or if not warm enough, more heat will be delivered when it is held in closer proximity.

[1] Absolute alcohol for this purpose may be prepared by adding either ½ ounce anhydrous copper sulphate or an equal quantity of well-burned unslaked lime to 3 ounces of commercial alcohol.

An instrument of this character with a compressible bulb instead of an air supply from a receiver is represented in Fig. 401. The operation of desiccation should not be hurried; time must be allowed for raising the air to a suitable temperature, so as to cause as little pain as possible. In addition the operation should be continued until the dentinal walls of the cavity have become perceptibly lighter in color, indicating that they have been robbed of their moisture. If desiccation is not carried to this point it will fail in its effectiveness; but if the moisture has been removed from the dentin to a considerable depth, as it may be if desiccation be continued sufficiently, sensitiveness will have become nearly or entirely obliterated. Whether we depend entirely upon dryness to relieve hypersensation or not it should be resorted to, for it proves a most valuable preliminary means when it is to be followed by medication of any kind.

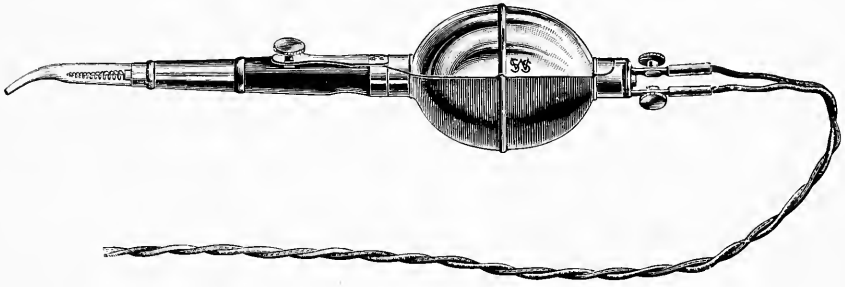

Fig. 401.—Electric warm-air syringe. (Guilford.)

Caustic alkalies are preferably applied in the well-known form of Robinson's remedy, which is composed of equal parts of potassium hydroxid and crystalline phenol forming potassium phenate when triturated together in a warmed mortar, with the addition of a very small quantity of glycerin to render it plastic. It should be preserved in well-stoppered bottles. A small quantity of this compound applied to the previously dehydrated painful dentin surface and rubbed into it with a warm burnisher will often prove to be of benefit. An intimate pasty mixture of potassium carbonate, four parts, and pure glycerin one part kept in a tightly corked bottle, has also been lauded very much. The caustic and dehydrating effect of these agents combined with the warm air blast lowers hyperesthesia markedly.

Their benumbing action, however, is only superficial, and they have to be applied repeatedly as the preparation of the cavity progresses.

Albumin precipitants are principally represented by silver nitrate, zinc chlorid and phenol. The silver salt acts very superficially and very slowly. Incidentally, by combining with the chlorin present in the

albumin and in the presence of light, it produces jet-black discoloration of the involved dentin. On all exposed dentin surface, especially on the exposed roots of the posterior teeth where the resultant color is no objection, it is an admirable desensitizer. It is best applied as a freshly prepared saturated aqueous solution. Other silver salts are of less value in this connection, as they are less caustic. It should be remembered that the pharmaco-dynamic action of silver nitrate depends upon the precipitation of albumin by the nitric acid ion and *not* upon the silver ion. The latter merely combines with the albumin forming a complicated double salt, *i. e.*, silver-albumin chlorid, which in the presence of light is partially reduced to a black oxid. Zinc chlorid is an admirable desensitizer; its application in crystal form or as a saturated solution is somewhat painful on account of its acid reaction. As it is not self-limiting it should not be applied into deep-seated cavities on account of the danger of pulp irritation at the time of its application or subsequently. Liquefied phenol does not penetrate deeply into tooth structure and may be applied safely to cavities of any depth. When applied into a dehydrated cavity in conjunction with the warm-air blast it produces quick and marked superficial benumbing effects, hence it is widely employed for this purpose. The addition of local anesthetics to phenol for this purpose, *i. e.*, cocain, etc., is an irrational procedure.

Within the last few years Buckley[1] has lauded dry formaldehyde (trioxymethylen) in the form of a paste as: "A new, safe and reliable remedy for hypersensitive dentin." This empirically compounded paste contains approximately 35 per cent. of dry formaldehyd mixed with vaselin and a few minor substances of no direct value. International dental literature of the last decade is filled with references relative to the use of formaldehyd as a desensitizing agent, and all writers, except Buckley, agree that it is a most dangerous agent for this purpose, as it will injure and, in most instances, kill the pulp. It produces numbness of dentin in the same manner as arsenic, only acting somewhat slower.

Trioxymethylen acts as a non-self-limiting caustic which penetrates comparatively quickly through any thickness of dentin.[2] As an illustration of the intense caustic action it may be stated that in the hands of some practitioners the Buckley desensitizing paste constitutes the routine application for the purpose of destroying the pulps in deciduous teeth. The same deleterious results are obtained with the so-called "Norwegian Dentin Anesthetic." This compound contains carpain

[1] Items of Interest, December, 1914.
[2] Prinz: Dental Cosmos, August, 1915.

and paucin, two alkaloids which act somewhat like erythrophlein, *i. e.*, they kill the pulp.

Occasionally, protoplasmic poisons are recommended for the purpose of desensitizing dentin. In many instances these drugs are referred to erroneously as caustics. A protoplasmic poison should be designated as a drug which endangers, or even kills living cell structure without visible changes. Protoplasmic poisons are not self-limiting in their action. Arsenic trioxid and, to a less extent, the alkaloids nervocidin, erythrophlein and paucin, are the principal substances of this group that have been employed as desensitizing agents. Arsenic when applied even in the very minutest quantities will usually kill the pulp, as its action cannot be controlled. This is equally true of the above-named alkaloids; they have only historical interest at present.

Local Anesthetics and Sedatives.—True local anesthetics, cocain or its substitutes, when applied to exposed sound dentin without pressure, do not produce any pharmacologic effects. Even if sealed into a fairly deep-seated cavity in which the underlying dentin is not decalcified no effect is obtained. Living protoplasm reacts unfavorably against the ready absorption of substances by endosmosis for two reasons: (1) the albumin molecule is relatively very large and is not easily diffusible, and (2) it possesses, as an integral part of its life, vital resistance toward foreign bodies. According to Hertwig, protoplasm primarily transfers irritation and, secondarily transmits absorbed materials. Therefore the anesthetic solution has to pass through the entire length of the dentinal fiber before the nerve tissue of the pulp proper is reached. Consequently a certain period of time is required before the physiologic effect of the anesthetic is manifested and the period of this latency is dependent upon the thickness of the intermediate layer of dentin. The migration of a protoplasmic poison through dentin may be observed by adding a vital stain to it, as, for instance, methylene blue added to arsenic or dry formaldehyd. The time required for its passage through about 5 mm. of sound adult dentin is twenty-four or more hours. The pharmaco-dynamic power of a drug depends upon its reaction with the living protoplasm through the catalytic action of ferments. The decomposition of the absorbed drug occurs comparatively quickly, usually within a few minutes. These observations are seen daily on injecting anesthetics or other solutions hypodermically. An average hypodermic dose of cocain is completely decomposed by the ferments of the protoplasm within the period of an hour, *i. e.*, its typical local anesthetic effect is manifested within a few minutes after the injection. The anesthesia remains at its height for about thirty minutes, and from then on it diminishes until by the end of the hour there is fairly complete recovery of normal sensation.

Therefore, if we apply cocain to sound dentin it is decomposed on its passage over Tomes' fibers before it reaches the anatomic threshold of sensation, *i. e.*, the nerve plexus at the surface of the pulp, and hence no anesthesia is produced. The nature of the cocain salt, whether it is a hydrochlorid, nitrate or lactate, has no bearing upon its therapeutic action. The apparent results obtained with these cocain salts must be attributed to the preliminary dehydration, protection of the exposed dentin by a temporary filling, etc., and *not* to its therapeutic effects. This is equally true in regard to most of the heterogeneous mixtures of cocain with other substances, as, for instance, potassocoin, vapocain, etc. Again, in the widely recommended solution of cocain (alkaloid) in chloroform and ether the cocain base plays no part. The apparent results obtained are produced by the process of evaporating to dryness and thereby obtaining a marked reduction in temperature, which is the obtundent factor. When cocain or any of its substitutes is forced into the living protoplasm of the unobstructed dentin tubuli under pressure, its anesthetic action is manifested within a few minutes. The vital resistance of protoplasm is readily overcome by comparatively slight force, which quickly transfers the anesthetic solution by an increased osmotic interchange to the surface of the pulp. The phenomenon is to be explained as an anesthesia obtained by intimate contact under pressure, either mechanical or by electromotive force (cataphoresis). The pulp of a tooth and, consequently, the dentin may be desensitized completely by any one of the well-known methods of contact anesthesia by using hand pressure or that derived from a dental hypodermic syringe or some other more complicated apparatus or by electricity. (See chapter XII.)

Electric Endosmosis.—Some years ago cataphoresis, for the purpose of desensitizing dentin, was much lauded. This process consists of placing a concentrated solution of cocain on cotton in the sensitive cavity and having it carried along the dentinal tubuli toward the pulp by means of a galvanic current, *i. e.*, by electromotive force. A battery is employed with the negative electrode, the cathode, inserted in the cavity, and the anode placed upon some part of the patient's body, as the hand, etc. The current carries the cocain *via* Tomes' fibers into the pulp and anesthetizes it. While in this condition, which usually lasts for an hour or more, the tooth may be worked upon without any pain. For a while this method met with great favor because of the perfect results obtained, but it was found to be a very slow process, requiring a cumbersome apparatus and often consuming more time than the operator had at his command, and occasionally requiring a second application in order to produce complete anesthesia; hence at present it has been largely discarded.

Of the numerous essential oils which have been suggested as obtundents of dentin, oil of cloves stands out prominently.

Its pharmacologic action depends on the presence of eugenol, an unsaturated aromatic phenol. The basic constituent of eugenol consists of para-amido-benzoic acid, a body which as such does not exhibit any marked therapeutic effects. Its methyl ester, anesthesin, is an efficient local anesthetic; however, it is only slightly soluble in water. Einhorn and Uhlfelder, taking anesthesin as a base for their synthetic research, finally succeeded in preparing para-amido-benzoyl-diethyl-amino-ethanol, commercially known as novocain or procain, which at present is the most efficient substitute for cocain.

Essential oils, in general, possess marked penetrating power. However, upon a fairly thick layer of sound dentin they are of little value when employed as obtundents. A different pharmaco-dynamic action is observed with arsenic. Arsenic trioxid, As_2O_3, in the presence of certain ferments of living protoplasm, *i. e.*, oxydases and catalases, is changed to the pentoxid, As_2O_5, which again is quickly reduced to the trioxid. This perpetual oxidation and reduction within the protoplasm of the cell causes a violent oscillation of the molecule of active oxygen, and thereby its therapeutic effects are manifested. The metalloid arsenic merely plays the role of an auto-oxidizer. The presence of the absorbed arsenic can be detected in the tissues by chemical analysis, that of absorbed cocain cannot.

Among the local sedatives, refrigerant anesthetics should be mentioned. These agents lower the temperature, diminish sensation and reduce the volume of the parts to which they are applied.

Physically reducing hyperesthesia of dentin by the application of cold is best accomplished by employing a chemical which has a low boiling-point. Pure ether (boiling-point 95° F., 35° C.), free from water, produces good results. Certain other hydrocarbons possess similar properties in varying degrees, depending upon their individual boiling-point. Pure ethyl chlorid (boiling-point 55° F., 13° C.) is best for this purpose, as it lowers the temperature of the tissues sufficiently to produce a short, superficial anesthesia in a few minutes. Too rapid cooling or prolonged freezing produces deep anesthesia, but such procedures are dangerous; circulation in the pulp may be cut off so completely as to produce death. Liquid nitrous oxid, liquid carbon dioxid, and liquid air, all of which have a boiling-point far below zero, are recommended for such purposes, but they require cumbersome apparatus, and some of these agents are extremely dangerous to handle.

In general, it should be stated that the application of cold for the purpose of obtunding hypersensitive dentin is a barbaric procedure. The initial pain produced by the cold is, in many instances, most

intense and more pronounced than that experienced by cutting the untreated dentin.

Indirectly, hyperesthesia of dentin may be eliminated completely by blocking locally the sensory nerve fibers leading to the pulp of the respective tooth. Any one of the well-known methods or combinations of methods, *i. e.*, infiltration and conduction anesthesia, is available for this purpose. On an average, most satisfactory results in a single tooth are obtained by using the pericemental injection, provided the pericementum is sound. (See Chapter XII.)

The paralyzation of the central end-organs in the brain by a general anesthetic will also anesthetize all the tooth pulps. Nitrous oxid is possibly more often used for this purpose than any other anesthetic agent. The much-lauded "analgesia" of a few years ago was, as might have been expected, a failure. With the improvement in the various methods of local anesthesia, general anesthesia for this specific purpose has lost much of its former significance.

The control of hypersensitive dentin by the administration of narcotics or sedatives is called for rarely. Of the general sedatives the bromids are usually recommended. Large, continuous doses are required to manifest their action, as they impair the perception of sensory stimuli only to a very mild degree. Average doses of morphin require at least one-half hour before a depression of the sensory impulse is manifested, while chloral hydrate shows a marked lowering within ten to fifteen minutes. Morphin-scopolamin administered hypodermically causes most pronounced general narcotic effects and, of course, marked lowering of the sensory reaction of the pulp.

Sensation in a tooth may be measured experimentally by passing a weak electrically induced current through it, and the above data are based upon observations obtained by such measurements.

Recently the author has been informed that certain practitioners advocate painless operations about the teeth by administering such powerful narcotic mixtures as morphin-scopolamin (hyoscin), also known by various trade names. These drugs are intended to imitate what is known in general surgery as "twilight sleep." Such procedures are eminently dangerous. It should be remembered that "doses of these drugs, which without the aid of one of the gaseous anesthetics cause a narcosis of sufficient depth, carry with them greater dangers than any of the other various methods of producing anesthesia." The author most emphatically discourages such practice. The dentist who, on account of ignorance, administers powerful narcotics of this type may suddenly find himself entangled in the meshes of the law.

CHAPTER XI.

DISCOLORED TEETH AND THEIR TREATMENT.[1]

By HERMANN PRINZ, M.D., D.D.S.

Pigments which cause discoloration of a tooth may be classified as *endogenous* pigments, pigments formed within the tooth, and *exogenous* pigments, pigmentary substances acquired from external sources. In the great majority of cases, endogenous pigments are the source of permanent tooth discoloration and are obtained from the blood. Temporary discoloration from endogenous pigments is occasionally observed as a sequence of general diseases, as Asiatic cholera, acute exanthematous skin eruptions, typhus fever and similar disturbances which produce a pinkish color or in pronounced cases of jaundice (icterus) a diffusion of bile pigment (bilirubin, which is isomeric with hematoidin) may occur in teeth having living pulps which produces a distinct orange-yellow stain. These various stains usually disappear with the termination of the underlying disease. Exogenous pigmentations usually result from the application of drugs employed in the treatment of teeth, from medicines, from food or from chewing stimulants, such as tobacco, betel nuts, etc.

Death of the pulp is the principal source of permanent discoloration. While this does not always nor necessarily involve discoloration of the tooth structures, yet when the condition does exist the general cause is as stated. Progressive interstitial staining of the entire dentin structure is the usual result, exclusive of certain metallic stains, also localized stains resulting from the imbibition of pigmentary matters occasionally observed when small areas of dentin have become denuded of enamel covering or when the latter has been so imperfectly formed as to afford an insufficient barrier to the ingress of pigmentary matters from the food or oral secretions.

Three classes of conditions are presented for consideration and treatment: (1) discoloration which has resulted from death of the pulp due to causes other than its exposure; (2) discoloration from death of the pulp caused by exposure; (3) special discolorations from death of the pulp due to adventitious causes superadded to the conditions affecting the cases included in the foregoing second division.

[1] The greater portion of this chapter has been written for former editions by Dr. Edward C. Kirk.

DISCOLORATION FROM DEATH OF PULP DUE TO CAUSES OTHER THAN EXPOSURE.

Any of the numerous traumatic causes which bring about death of the pulp, *viz.*, blows, sudden contact with hard substances, biting threads, violent thermal shocks, the injudicious application of continuous force in regulating, the application of arsenous oxid to the dentin, where no exposure or only minute exposure of the pulp exists, organic or inorganic poisons, certain bacteria or even the exposure to severe cold (ethyl chlorid), may produce hyperemia and congestion of the pulp, or strangulation of its circulatory system, the formation of emboli, thrombus, hemorrhagic infarct, etc., leading to a breaking down of the corpuscular elements of the blood, the escape of hemoglobin from the stroma of the red corpuscles, its solution in the blood plasma, and resulting infiltration of the tubular structure of the dentin by the hemoglobin solution, giving the tooth a distinctly pinkish hue when examined by direct light or by transillumination. An interesting observation relative to tooth discoloration is made by Thomas Bell.[1] He states: "I have frequently examined the teeth of persons whose death has been occasioned by hanging or drowning, and have invariably found the whole of the osseous part colored with a dull deep red, which could not have been the case if these structures were devoid of a vascular system. In both instances the enamel remains wholly free from discoloration."

Suffusion of the dentin structure by discharged hemoglobin may be produced readily by the topical application to the exposed pulp of medicaments having hemolytic properties; for example, spirit of trinitroglycerin (glonoin) as an ingredient of a cocain solution intended for the production of local anesthesia, will frequently produce hemolysis with suffusion of the dentin when the mixture is applied locally to a bleeding pulp. Even distilled water exerts a hemolytic effect, rupturing the stroma of erythrocytes by endosmosis; therefore, all solutions intended for topical application to a bleeding pulp should be at least isotonic with the plasma or preferably of greater density in order to avoid staining the dentin with diffused hemoglobin.

Teeth so affected rapidly change in color through various gradations in tint from the original pinkish hue, which becomes yellow; this growing darker, passes into brown, and after the lapse of considerable time the tooth may become a permanent slaty gray or black.

The violence of the hyperemia preceding the death and disintegration of the pulp determines, to a considerable degree, the rapidity of

[1] Anatomy, Physiology and Diseases of the Teeth, 3d Am. Edition, Philadelphia, 1837.

the process of subsequent tooth discoloration. When congestion of the pulp has been relatively slight and the necrotic process has proceeded slowly, the sudden infiltration of the dentin with hemoglobin does not occur; consequently the initial change in color following complete death of the pulp may be so slight as to escape detection except upon most searching examination, with special means of illumination, and even then may be manifested only by a slight diminution in the normal translucency of the tooth as compared with adjoining teeth. Such teeth, however, if permitted to remain untreated, eventually grow darker, and while they may not acquire a degree of discoloration equal to those which have suffered sudden or violent death of the pulp, they become so unsightly as to demand treatment for the restoration of their normal color.

The Rationale of the Process of Discoloration.—In teeth discolored as a consequence of the death of the pulp without its exposure it is evident that the sources of pigmentation are internal to the tooth and are sought for solely in the products of decomposition of the elements of the pulp tissue and its vascular supply.

The proteid elements of the pulp tissue are complex combinations of carbon, oxygen, hydrogen, nitrogen, sulfur, and phosphorus, which, in their gradual breaking down by the process of putrefactive decomposition, are split up finally into carbon dioxid, water, ammonia, and hydrogen sulfid, with possibly the formation of traces of phosphatic salts. The group of substances entering into the composition of the histologic elements of pulp tissue contains no constituents which in the progressive changes resulting from putrefactive decomposition should form compounds likely to cause permanent discoloration of the tooth structures.

When, however, the vascular supply is considered as a factor, the explanation of the cause of discoloration in the cases in question becomes reasonably clear. The red corpuscles contain as their characteristic component hemoglobin or oxyhemoglobin depending upon whether the blood is venous or arterial, and this substance is its essential coloring ingredient. When undergoing gradual decomposition, hemoglobin passes through a variety of alterations in its chemical constitution, accompanied by a corresponding series of color changes.

A familiar illustration of these color changes is furnished by the cycle of color alterations witnessed in a bruise. Immediately following an injury to the flesh, of the character alluded to, an extravasation of blood in the bruised territory occurs, causing undue reddening of the skin; this is soon followed by an increasing darkening of the tissue until there results what is popularly termed a black-and-blue spot. Further decomposition of the coloring matter of the extravasated blood

induces a variety of color changes ranging through the scale of yellows and browns, until the pigmentary matter is finally removed by absorption through the capillary bloodvessels and lymphatic system of the part.

In passing through the cycle of color changes due to its progressive decomposition, hemoglobin undergoes several alterations in composition, among which are formed a number of definite compounds, each having marked chromogenic features. Of these decomposition products, methemoglobin (brownish red), hemin (bluish black), hematin (dark brown or bluish black), and hematoidin (orange), are the most important and best known. While gradual decomposition of the coloring matter of the blood here noted may account for certain phases of tooth discoloration, other factors which exert a profoundly modifying influence upon the process are yet to be considered.

The putrefactive decomposition of the proteid elements of the pulp results, as before stated, in the production of hydrogen sulfid in considerable quantity. The albumins contain from 0.8 to 2.2 per cent. of sulfur (Hammersten), which in the splitting up of the compound during putrefaction yields a large amount of hydrogen sulfid. In pulp decomposition this hydrogen sulfid is generated in contact with the hemoglobin and necessarily exerts a marked modifying action upon the decomposition process of that substance. Miller says: "If a current of hydrogen sulfid is conducted through fresh blood or a solution of oxyhemoglobin in the presence of air or oxygen, sulfomethemoglobin is formed, which is greenish red in concentrated solutions and green in dilute solutions. If we lay a recently extracted tooth in a mixture of meat and saliva so that a part of the enamel surface remains free, and moisten the surface with blood, it will take on a dirty green color if kept at blood temperature in an absolutely moist condition for from twenty-four to forty-eight hours. It is quite possible that the dirty green deposits which form in putrid conditions of the mouth, in stomatitis mercurialis, scorbutica, gangrenosa, etc., or even in inflammatory conditions of less importance, as well as in cases of absolute neglect of the care of the mouth, may owe their green color to the presence of sulfomethemoglobin."

As in pulp decomposition hydrogen sulfid is being formed in the presence of hemoglobin, this fact warrants the belief that a combination takes place resulting in the formation of this same compound, which Miller regards as productive of certain stains upon the external surface of the teeth.

The slaty gray or bluish pigmentation always noticeable upon the visceral walls and frequently beneath the skin of animal bodies undergoing putrefactive decomposition is a familiar example of the action

of hydrogen sulfid or its ammonia combinations upon decomposing hemoglobin in hemorrhagic extravasations, and is a process and form of pigmentation exactly analogous to that which is here described as taking place in the dentinal structure from putrefactive decomposition of the pulp. "When red corpuscles are just beginning to disintegrate, the coloring matter formed is hemoglobin; but the yellow and brown granular masses found in cells and lying free in tissues are, as a rule, derivatives of hemoglobin, not hemoglobin itself. These derivatives are divided into two groups depending upon whether or not they contain iron, the former being called hemosiderin, the latter hematoidin. When acted upon by ammonium sulfid (a derivative of putrefactive decomposition of albumin), hemosiderin becomes black, iron sulfid being formed."[1] Hemosiderin is a mixture of pigments in which iron exists in a most accessible form to be demonstrated readily by the Prussian-blue reaction. Grohe[2] believes that as a result of putrefaction iron is liberated from its compound with hemoglobin, so that when thus freed it combines readily with the hydrogen sulfid.

Iron is the most important element to be considered in the list of factors causing the discoloration of this group of cases. It is the iron constituent of the red corpuscles which is the essential chromogenic factor from first to last in their cycle of color changes.

The process of putrefactive decomposition consists of a series of chemical changes brought about through the agency of microörganisms, involving the breaking down, by successive stages, of highly complex organic compounds and their resolution into compounds of much simpler composition. It is not known to what extent this splitting up of the components of the pulp and its vascular elements is ultimately carried in the series of changes resulting in the permanent discoloration of the tooth. From what is known of the ultimate composition of the compounds involved, it may be inferred that reduced to its lowest terms, the result so far as pigmentation is concerned, would be the formation of iron sulfid, the elements of which, with the exception of some unimportant alkaline and earthy salts, are the only ones entering into the original compounds which are fixed and therefore capable of forming a stable residuum in the tubular structure of the dentin. While iron sulfid cannot be held wholly accountable for the final bluish-black color of a tooth, the pigmentation is almost certainly due to it or to some allied compound in which iron and sulfur, with some organic constituents, largely enter, and which, by a further slight decomposition, would yield true iron sulfid.

[1] Ziegler: General Pathology, 1895.
[2] Virchow's Archiv, Band xx.

The significance and importance of a recognition of the possible presence of the iron compound as a factor in tooth discoloration are further brought out in the study of bleaching methods.

Discoloration of Teeth Following Death of the Pulp Consequent Upon Its Exposure.—When death and decomposition of the pulp are consequent upon exposure of that organ, through caries or otherwise, to the irritative influences of infective agents present in the oral secretions and food, or to thermal shock, etc., the putrefactive process involving the pulp tissues is modified in character and rapidity to a degree which may affect the character of the resulting discoloration. Thus, the yellowish or brownish discoloration so often seen in teeth whose pulps have been devitalized through systemic or traumatic causes, and which in many cases appears to be more or less permanent in character, is rarely observed in those teeth whose pulps have been devitalized through exposure by caries.

In these latter cases the original suffusion of the dentin by hemoglobin has not taken place ordinarily and, moreover, the progress of the putrefactive process is comparatively rapid, the conditions being more favorable, so that the coloring matter of the blood is sooner reduced to its lowest terms in the scale of decomposition products, *i. e.*, to the slaty blue or black pigmentation before noted. The pigmentation of the dentin in cases of pulp exposure with subsequent decomposition of that organ is due to the diffusion of some of the decomposition products of hemoglobin that have been formed in the pulp chamber and not in the tubuli as in the class of cases first considered. In addition to the increased rapidity of putrefactive decomposition incident to cases of discoloration following pulp exposure, another important modifying factor in the process of discoloration is the ingress afforded to the oral fluids, food materials, and other adventitious substances which find their way into the mouth, and ultimately, through the open cavity of the tooth, to its pulp canal, and thence to the tubular structure of the dentin. These extraneous substances, in the course of time, may infiltrate the tooth structure, and while no especially noticeable or characteristic effect may be observed so far as color is concerned, yet frequently they exert an influence upon the coloration of the tooth which so alters its character as to render successful bleaching treatment extremely difficult and a resort to special methods or a variety of methods necessary.

Fatty or oily substances or astringent and coagulant agents, for example, may act upon the coloring matter in such a way as to set it permanently in the same manner that mordants form insoluble compounds or lakes with the dyestuffs used in the dyeing of textile fabrics.

Another important class of substances which is frequently the cause of staining the tooth structure is metallic salts used in dental therapeutic treatment or accidentally formed during the application of corrosive medicaments to the teeth, through the action of such remedies upon fillings *in situ* or upon the instruments by which the applications are made. An example of this is the use of iodin or sulfuric acid or other metallic solvents in connection with steel instruments and the subsequent use of medicaments containing tannin as an ingredient.

Treatment.—The treatment of these conditions will be considered separately.

Teeth Suitable for the Bleaching Operation.—In deciding upon the advisability of attempting the bleaching operation in any given case, the general conditions which determine the action of the operator with respect to all dental operations should govern his course.

As most therapeutic and restorative measures in dentistry are a series of compromises with disease conditions or their sequelæ, it is usually the duty of the operator under the circumstances to capitulate upon the basis of greater advantage to the patient. Therefore, if discoloration of a tooth is practically the only factor in the problem presented by a given case, the effort should be made to restore the organ to its normal condition of color. The same rule should be applied to all cases of discolored teeth in which structural loss by caries or fracture has not been so great as to preclude a satisfactory restoration by proper filling or replacement of the lost structure by a porcelain inlay or other material. The cases in which it is not advisable to attempt a bleaching operation are only those in which loss of structure is so extensive as to require a crowning operation.

In the judgment of many operators it is useless to attempt the bleaching of any teeth excepting the incisors, because of the difficulty and length of time frequently required for the successful bleaching of cuspids, bicuspids, and molars, due to the thickness of their walls and the consequent depth of the structure requiring treatment. It is also held to be useless to attempt the bleaching of teeth which have been discolored throughout their structure by metallic stains. The fallacy of such a view is self-evident when it is considered that if any portion of the dentinal structure of a discolored tooth is amenable to the bleaching treatment, its complete restoration is simply a question of continuance or repetition of the operation until the desired end is attained.

While teeth discolored by metallic stains present problems of great complexity and require not only special methods of treatment based upon proper recognition of the chemical relationships involved between the nature of the stain and that of the agent used for its removal, in

justice to the patient the attempt should be made to bleach them, even though ultimate failure results, in order that the necessity for destruction of the natural crown for the purpose of its replacement by an artificial substitute may be postponed, if possible, for as long a period as may be attainable.

Nature of the Problem Involved in Tooth Bleaching.—The bleaching process is dependent upon a chemical reaction between a compound having color and some substance capable of so affecting its composition that the color is discharged, or, in other words, of so affecting the integrity of the color molecule as to destroy its identity, which results in a loss of its distinguishing characteristic, *viz.*, its color. For this very reason, the process of bleaching is extensively employed in the industries to textile fibers, to straw, paper stock, feathers, hair, oils and fats, etc.

The substances concerned in discoloration of tooth structure, as has been previously shown, are derived from the pulp and its vascular elements and the organic contents of the tubular structure of the dentin, through the gradual putrefactive processes which become operative subsequent to the death of the pulp. These pigmentary products of pulp decomposition we know to be organic in character; and further, that they exhibit the property of color by virtue of definite conditions of molecular composition—that is to say a certain arrangement of a molecule having its individual group of chemical and physical properties, among which latter is a characteristic *color*. If the surface of a body possesses the property of reflecting the combined spectrum of the sunlight without decomposition, that body is recognized upon our retina as white. If, however, the surface possesses the power of neutralizing a part of the projected white sunlight, *i. e.*, to decompose it, and to reflect its remaining part, the body will now be recognized by the retina as that *color* which is the characteristic property of the predominating reflected light rays, *viz.*, red, or green, or blue, etc.

Whatever brings about an alteration in the composition of a molecule at once destroys the identity of the matter so treated. Hence, if we can act upon the coloring matter which gives rise to staining of a tooth by means of an agent capable of effecting an alteration in the atomic arrangement of composition of the color molecule, we may expect incidentally to remove or discharge its color feature.

Two general classes of substances have been used successfully as bleaching agents: first, those which act by virtue of their power to evolve oxygen in the active or nascent condition, and known as oxidizing agents; second, those which act in an opposite manner by virtue of their strong affinity for oxygen, and which are called reducing agents. The oxidizing bleachers destroy the identity of the color molecule by

seizing upon its hydrogen element to form water. The reducing agents act by removing the oxygen atom from the color molecule to form by-products depending upon the character of the reducing agent used.

Chlorin and its congeners iodin and bromin act as indirect *oxidizing bleachers;* the dioxids of hydrogen and of sodium are direct oxidizers. Potassium permanganate may be classed also with this group, although its successful use as a bleaching agent depends upon a subsequent treatment of the substance to be bleached with some solvent capable of removing the manganese dioxid formed as a by-product of the action of the permanganate. It has somewhat extensive and satisfactory use as an agent for bleaching sponges, and has been used for bleaching teeth, but is of greatly inferior value to other agents for the latter use.

The only agent belonging to the group of *reducing bleachers* which thus far has been found available for bleaching teeth is sulfur dioxid, either in the gaseous state or in aqueous solution.

Chlorin as a Bleaching Agent.—The general use of chlorin as a bleaching agent in the arts no doubt suggested its use in the treatment of tooth discoloration. Its introduction as a tooth-bleaching agent, as well as the assembling of the general principles of its use for bleaching teeth into a coördinated system, was by the late Dr. James Truman, whose method depends upon the liberation of chlorin from calcium hypochlorite, commonly called bleaching powder or chlorinated lime, in the pulp chamber and cavity of decay in the tooth. Chlorin is liberated from the bleaching powder by the action of dilute acetic acid. When this takes place in contact with the discolored tooth, it is bleached rapidly as a result of the action of the chlorin upon the coloring matter contained in the dentinal tubuli. Numerous modifications of this original method of bleaching tooth structure have been suggested, but, as the ultimate result in each is accomplished through the activity of chlorin, a rational understanding of the mode of action of chlorin in this relation is of importance as an aid to the intelligent use of those methods for the tooth-bleaching which are dependent upon, or owe their efficacy to, that agent.

Chlorin is an elementary gaseous body, greenish in color, soluble in water, having a disagreeable odor, intensely irritating to the air passages when inhaled, and poisonous when breathed in sufficient quantity. It has a strong affinity for all metallic bodies, entering into direct combination with a number of them, under favorable circumstances, with great energy—forming, as a rule, compounds that are soluble in water.

One of the distinguishing features, and one which is directly concerned in its use as a bleaching agent, is a strong affinity for hydrogen. So strong is this affinity, that when a molecule of chlorin is brought

into contact with a molecule of water under favorable conditions, the hydrogen of the water molecule is seized upon by the chlorin to form chlorhydric acid, and the oxygen is set free in the nascent state, a condition under which its oxidizing powers are exhibited in their greatest intensity. This powerful affinity of chlorin for hydrogen enables it to decompose many other hydrogen-containing molecules in a similar manner, forming chlorhydric acid and destroying the identity of the matter acted upon.

It has been shown that all organic compounds which are the products of the vital processes of the animal body contain hydrogen as an important constituent. This applies also to the decomposition products whose presence in the tubular structure of the dentin is the cause of tooth discoloration.

These organic stains exhibit the property of color by virtue of certain definite conditions of molecular composition; hence, when chlorin acts upon the coloring matter in the tooth by seizing upon and combining with the hydrogen of the organic pigment, the identity of the compound as such is destroyed, and its characteristic feature, that of color, is lost.

The principle here outlined is involved in what is termed the direct action of chlorin in the bleaching. There is, however, another method by which chlorin is believed to act as a bleacher in which its function is indirect.

In some cases it has been observed that chlorin fails to act except in the presence of moisture, and the *rationale* of this is that the bleaching under such conditions is effected by nascent oxygen liberated from the water molecule when the chlorin combines with its hydrogen to form hydrochloric acid; thus: $Cl_2 + H_2O = 2HCl + O$. That such is the nature of the process in many cases is a reasonable deduction from the behavior of chlorin under analogous conditions when it acts indirectly as an oxidizing agent.

Whatever may be the exact nature of its ultimate action, it is to be borne in mind that the bleaching effect is due solely to the alteration which is made in the composition of the color molecule and that there is no solvent power whatever on the organic matter upon which it acts. Chlorin changes its characteristics, but does not remove the molecule by solution. It should be noted also, in this connection, that the chlorin compounds of most of the metallic elements, especially when in dilute solution, are almost colorless as compared with many of the other metallic compounds—the oxids and sulfids, for example. Hence it is that when stains owe their color to the presence of certain organic compounds with some of the metals, or even when the coloration is due to decomposition products of hemoglobin, the color may be discharged

readily by chlorin; but if the iron chlorid thus produced by the action of chlorin on the iron constituent of the hemoglobin remains in the tooth structure, it is gradually decomposed and new combinations of it are to occur, which result in a return of the discoloration.

All tooth-bleaching methods should aim not only to discharge the color by suitable chemical means, but to remove all organic debris and by-products of the bleaching process from tubuli, for as long as any remain, the tendency to a return of the discoloration is always a possible menace to the permanent success of the operation. However, care should be exercised in the removal of the organic constituents of the tooth structure so as not to weaken it unduly.

When the tubular contents cannot be removed successfully, the tendency to a return of discoloration may be combated by hermetically sealing the tubular orifices with an impermeable resinous varnish or by permanently coagulating them. This feature is described more fully in relation to the details of the bleaching procedure.

Preparation of the Tooth for the Operation of Bleaching.—It is necessary to observe certain general details in the preparation of teeth for the bleaching operation, whatever may be the method of treatment employed.

Appropriate treatment for the removal of all septic matter from the pulp chamber and canal, and for the relief of any existing conditions of irritation of the pericemental membrane and tissues of the apical region, should have been carried out and the tooth brought to the condition in which permanent closure of the apical foramen of the root may be performed safely.

The rubber dam should be adjusted with special care and should include only the tooth to be bleached. If two adjoining teeth are to be bleached, both may be isolated by the dam; but in no case should one or more adjacent normal teeth be included with the tooth to be bleached. While the inclusion of teeth adjacent to the one which is the subject of any ordinary dental operation is in all cases desirable, there are good reasons why such a plan should not be pursued in the bleaching procedure. The chemicals used for the purposes may possibly have some disintegrating or solvent action upon the enamel structure and such action, should it occur, should be confined strictly to the tooth undergoing treatment and held within the limits of safety by close observation and appropriate treatment, which conditions cannot be controlled as thoroughly and the process managed as satisfactorily when several teeth are included in the field of operation.

Furthermore, as nearly all of the bleaching agents used, or those which are employed as adjuvants to the process have a more or less irritative or escharotic effect upon the soft tissues of the mouth, extra

precautions must be taken in adjusting the dam against leakage at its attachment to the cervix of the tooth. For the reason that the chances of leakage are greatly multiplied when several holes are punched in the dam for adjustment to as many teeth, no other than the tooth to be treated should have the dam adjusted to it.

Supposing the tooth to be an upper incisor, the dam should be slipped over it and the margin of rubber encircling the cervix should be carried gently under the free margin of the gum either by means of a small flat burnisher of suitable angle and curvature, or by means of a waxed floss-silk thread. One or two turns of a ligature should be thrown around the cervix below the dam to hold it securely in place. The dam may be fixed with greater security, especially as against any accidental traction made upon it during the operation, by fastening it with a ligature made as follows and thrown around its cervix:

A piece of waxed ligature silk about eighteen inches in length has a large knot tied at about the center by making six or eight turns of the thread loosely around the end of the index finger of the left hand.

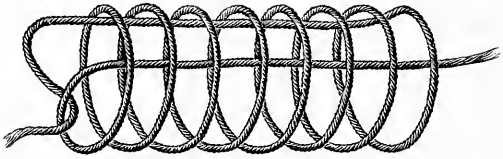

FIG. 402

Upon withdrawing the finger there is a series of loops through which one of the free ends of the thread is now passed, as in making the first half of a flat knot, as illustrated in Fig. 402. By drawing upon the free ends of the thread until all of the loops are closed upon themselves, a hard knot of more or less spheroidal shape is formed about midway between the ends of the ligature. The ligature so prepared is placed around the tooth in such a manner that the knot as described shall be located at the middle portion of the palatal cervical margin. A half knot is then made by tying the ligature in front so that it shall rest directly opposite the palatal knot, *viz.*, at the middle portion of the labio-cervical margin. The ligature is drawn into fairly close contact with the tooth, and, with both ends held firmly in the left hand and drawn somewhat tense, the portion encircling the tooth is firmly but gently forced up against the rubber dam and gingival margin, the ligature at the same time being drawn tightly until the anatomic constriction of the tooth at its cervix will serve to hold it from slipping downward, especially upon the palatal aspect of the tooth.

When the ligature is found to be securely placed as described, the

knot upon the labial aspect is completed and further enlarged by retying the thread four or five times. The free ends of the ligature should be cut off close to the knot. As an additional safeguard against leakage of irritating bleaching agents through the cervical attachment of the dam upon the soft tissues, it is well, after making the tooth perfectly dry, to paint the ligature and a narrow band of its adjacent territory with chloropercha, which, after evaporation of the solvent, will effectually prevent any accident from leakage. No clamps must be used, as chlorin acts directly upon the steel forming soluble salts.

The placing of a large knot upon the palatal aspect at the cervical margin has another decided advantage in that it not only holds the dam more securely against slipping downward, but holds it away from the palatal surface which is ordinarily the point of entrance to the pulp chamber and canals in these cases. The point of canal entrance, however, may be through a proximate cavity, if such a one affords sufficient access.

The canal filling in all cases of bleaching, without exception, should be gutta-percha. No other material used for canal filling possesses the generally desirable qualities needed for that purpose in this class of cases. The extent of the canal filling should include one-third or not over one-half of the distance from the apex. A considerable portion of the canal beyond the level of the gingival margin is thus left unfilled in order that the coronal end of the root may be bleached as well as the tooth crown. This is especially necessary when more or less recession of the gum from its normal attachment has occurred, leaving the cervical cementum exposed to the action of the oral fluids, food, etc., which have a tendency to cause discoloration of the exposed root tissue.

The root being filled as directed, all fillings wherever existent in the tooth should be removed. This is a preliminary procedure which should not be omitted in any case, but where any bleaching method is used which involves the employment of chlorin as the active agent it becomes necessary for reasons which are explained in connection with the description of the chlorin methods. Aside from other considerations, the removal of all fillings preparatory to the bleaching operation has a decided value in facilitating the process by exposing an increased area of dentinal structure and thereby permitting the action of the bleaching agent over a larger territory of ingress.

When all fillings or softened tooth structure have been removed by mechanical process, as well as all septic and extraneous matter of whatever character, the tooth should be washed thoroughly with dilute ammonia water, or better, with a hot saturated solution of borax in distilled water. The object of this treatment is to remove by

saponification and solution all fatty matters which may obstruct the ingress of the bleaching agent into the dentinal structure.

In nearly all cases where discoloration has occurred from a decomposed pulp, and where the canals and pulp chamber have been left untreated, there will be observed, on opening into such a pulp chamber for the first time, a dark layer of oily or greasy material lining its walls. The thorough removal of this dark layer should be effected prior to any attempt at bleaching, as it appears to prevent the ingress of the bleaching agent into the dentinal structure. The most satisfactory method for removing the dark greasy layer is by the use of suitable instruments—either properly shaped spoon or hoe excavators or round burs in the engine. The thorough removal of this layer necessitates free access to the pulp chamber, which, as a general rule, should be obtained by means of an ample opening upon the lingual aspect of the tooth, in the case of incisors, and through the morsal surface in bicuspids, etc.

After he has effected a thorough cleansing of the tooth by mechanical means and through the agency of borax or ammonia and hot distilled water, the operator should dry it to the extent of removing all superfluous moisture. Then the tooth will be in condition for the application of whatever method of bleaching may be chosen for the particular case in hand. When sodium dioxid or Schreier's kalium-natrium with hydrogen dioxid is to be used as the bleaching agent, the preliminary saponification of the canal contents with ammonia or hot borax solution becomes unnecessary.

Truman's Method.—This, as before stated, was the first method successfully employed for bleaching teeth. It consists of liberating chlorin from ordinary chlorinated lime by means of a weak acid in the pulp chamber of the tooth. Any acid will effect the liberation of chlorin from the bleaching powder, but acetic, tartaric, or oxalic acids are generally used. Care must be observed in selecting a good quality of bleaching powder, as that substance rapidly undergoes spontaneous decomposition, especially in a moist atmosphere. Good chlorinated lime is a dry powder having a strong odor of chlorin which should contain not less than 35 available per cents. If it is moist or pasty, and has but a feeble odor, it should be rejected as worthless. Brands of bleaching powder dispensed in metallic packages should not be used, as they are invariably contaminated with metallic chlorids due to the slow action of the contents upon the container. The return of discoloration in many cases after bleaching by the Truman method is undoubtedly due to the use of bleaching powder so contaminated. The powder dispensed in glass bottles or in paraffined paper cartons is more reliable.

Its application to the tooth may be effected in several ways:

(*a*) By packing the dry powder in the pulp chamber and then moistening the latter with the acid.

(*b*) By mixing the powder with sufficient distilled water to make a coherent mass which is more easily manipulated, then packing it in the pulp chamber and applying the acid.

(*c*) By first moistening the interior of the tooth with the acid, next dipping the instrument into the powder and then into the acid, each time carrying the mixed materials into the tooth until the desired change of color is produced.

Probably the most satisfactory method is to pack the dry powder into the tooth and apply the acid to it, after which immediately seal the cavity with a single pellet of gutta-percha. By using a 50 per cent. solution of acetic acid the evolution of chlorin will take place with a satisfactory degree of uniformity, and not so rapidly as to interfere with its penetration throughout the discolored tubular structure of the dentin. The bleaching mass may be sealed in place by means of zinc oxyphosphate if desired, but it is usually unnecessary to use anything other than gutta-percha or one of the soft temporary stopping materials for the purpose.

The case may be dismissed for one or two days and the treatment as outlined repeated at similar intervals until the tooth is restored to normal color.

The instruments used in connection with this process should be of vulcanite, bone, ivory or wood. Under no consideration should steel, gold, or platinum instruments be used, as chlorin acts directly upon each of these metals, forming soluble chlorids, which, if carried into the tooth structure, will give rise to a permanent staining of most intractable character. The only metals which may be used safely in connection with any chlorin process of bleaching are zinc and aluminum, the chlorids of which are colorless, but, nevertheless, they are objectionable for the reason that both are coagulant and color mordants. Aluminum instruments for the purpose may be improvised quickly out of wire or heavy plate. Gold instruments have been recommended but they are open to the very grave objection of forming a chlorid by direct combination with chlorin, which salt is one of the most important staining media known to the histologist; as a matter of fact, the author has seen several cases where a permanent purple staining of the tooth has resulted from neglect to remove gold fillings before applying the chlorin method of bleaching, and there is certainly no reason why the same result should not follow the using of gold instruments in the same connection.

It is good practice to bleach the discolored tooth a shade or two

lighter than its mate, as a bleached tooth usually darkens slightly in a short time.

When the tooth has been restored to its proper color it should be washed thoroughly with liberal quantities of very hot distilled water, dried out with bibulous paper, and thoroughly desiccated with a current of dry hot air, after which the canals, pulp chambers, and cavities should be filled with zinc oxychlorid.

The final filling of the cavities of entrance and of decay should be postponed until, by a lapse of considerable time, the permanence of the operation has been established. This probationary period may be prolonged to four or six months with advantage.

The final washing of the tooth with hot distilled water previous to the insertion of the zinc oxychlorid filling is a feature of the operation which requires special care and attention. As left after the application of the bleaching agent, the pulp chamber and canals and dentinal structure are filled with free chlorin in solution, iron chlorid from the combination of the chlorin with the iron element of the color molecule, calcium acetate, or other salt of calcium, depending upon the nature of the acid used in the process and probably some undecomposed bleaching powder. These substances should be removed thoroughly by the hot water douche. At least a pint of water should be injected strongly into the interior of the tooth by means of a large bulb syringe or other convenient means, before the dam is removed. A thick towel or a suitable basin held in close proximity to the tooth will catch the water as it returns from the tooth and protect the clothing of the patient. Distilled water should be used in all cases for this irrigating douche, as river water and many other specimens of water from natural sources contain iron in solution, which could readily become a contaminating factor, leading to subsequent return of discoloration.

Zinc oxychlorid is selected as the permanent filling for the pulp chamber, for the reason that it is necessary so to act upon the bleached organic residuum in the tubular structure as to prevent any alteration of its character, which may result in the production of a subsequent coloration.

Zinc chlorid possesses the property of converting many organic substances into unalterable compounds by its coagulant action, thus tanning or mummifying animal tissue and preserving it indefinitely. A mass of zinc oxychlorid, before it sets, that is, before chemical combination takes place between the zinc oxid powder and the zinc chlorid liquid is functionally free zinc chlorid, and, as a matter of fact, the properties of zinc chlorid are manifested by such a mass for a considerable period of time after the mass has apparently set. When introduced into the pulp chamber and canal, its action upon the organic

debris in the tubuli is as stated, and the material, if the operation has been performed successfully, is effectually prevented from further alteration, upon which condition the permanence of the operation depends.

Another method for preventing subsequent alteration of the bleached organic debris in the tubular structure is to desiccate the tooth thoroughly by means of the hot air blast and saturate the dentin with some insoluble resinous varnish, such as copal ether varnish, or, still better, the solution of trinitrocellulose in methyl alcohol and amyl acetate, known in commerce as "kristaline," or in the market as "cavitine." The pulp chamber and canals may then be filled with any suitable filling.

As between the zinc oxychlorid filling and the varnish lining, the choice in general should be of the former. The varnish lining is adaptable to cases of long standing, where complete liquefaction of the tubular contents had left them practically empty, and where, as a consequence, there is nothing upon which zinc chlorid can exert its coagulating effect.

Other Chlorid Methods:—The solution of chlorinated soda known as Labarraque's solution, or liquor sodæ chloratæ U. S. P., may be applied to the previously desiccated tooth structure until the dentin is saturated with the solution, after which an application of a dilute acid which liberates chlorin is made. The chemical principles involved are analogous to those upon which the methods with bleaching powder depend, the only difference being that the source of the active agent, chlorin, is in one case its calcium compound, which is a dry powder, and in the other the analcgous soluble sodium compound.

The precautions necessary to be observed are exactly the same as those required in Truman's method, already described. The results obtained by this process are not as thorough nor as satisfactory as by the Truman method.

Chlorin *per se* has been used for tooth bleaching, and was the basis of a method devised by Dr. E. P. Wright of Richmond, Virginia. This involved the use of a complicated apparatus by which a continuous jet of chlorin was thrown into and about the tooth. The complexity of the apparatus was a formidable obstacle to the general use of the method and it was abandoned, though the results were in many cases very satisfactory.

Iodin:—Reference has been made previously to iodin as a bleaching agent. Its chemical action is nearly analogous to that of chlorin, though less energetic. In slight discolorations, however, iodin often may be used to considerable advantage by simply saturating the dentin with an alcohol solution of iodin, *viz.*, the official 7 per

cent. tincture, until the tooth structure is stained a characteristic yellow. Then the cavity is sealed temporarily with a gutta-percha filling and the case dismissed for twenty-four hours, at the expiration of which period a marked improvement in color will be observed. The same precaution is necessary in the use of iodin for bleaching purposes as with the use of chlorin in regard to the removal of metallic fillings and the avoidance of contact with metallic instruments.

Bleaching by Means of the Dioxid of Hydrogen and of Sodium.—The commercial introduction of solutions of hydrogen dioxid marked a new era in the operation of bleaching discolored teeth. The bleaching property of hydrogen dioxid has been known to chemists for many years, but the application of this property to tooth bleaching dates from the medicinal use of hydrogen dioxid solutions for the treatment of purulent conditions of the pulp canal and about the roots of teeth. When applied in the canals of discolored and infected teeth, it was observed that a noticeable bleaching of the discolored structure resulted. The hint thus given was further studied until it was found that under proper conditions the whole structure of a discolored tooth might be restored successfully to normal color.

Nascent oxygen may be furnished by two kinds of auto-oxidizers—one direct source is its allotropic form known as ozone, and the other is represented by the many dioxids, chiefly hydrogen dioxid, and those of the alkali and alkaline earth metals. The nascent oxygen obtained from both sources is based on the same principle of formation.

Ozone = O—O—O, or O_3, is split up in O_2O (nascent state).

A dioxid, X—O—O, or XO_2, is split up in XO—O (nascent state).

According to Nernst, the formation and the association of ozone are illustrated by the following equation:

$$O_3 \rightleftarrows O_2 + O$$

$$O_2 \rightleftarrows O + O$$

Only one of the three atoms of the ozone molecule enters into active or atomic oxygen, the other two forming molecular or inactive oxygen. This is true of the oxygen molecule of a dioxid, one atom is set free while the other one remains combined with the metal in the form of an oxid. The ozone molecule and the dioxid molecule play the role of a single atom of oxygen in the reaction of oxidation. The amount of available oxygen in a dioxid depends on the degree of superoxidation of the original oxid. Ozone, as well as the dioxids, are endothermic compounds, that is, they require energy in the form of heat or electricity for their formation. They are comparatively easily decomposed, liberating again the same amount of energy in the form of heat which was absorbed in their formation. Ozone has, thus far, been produced

only as a gas, while the dioxids, with the exception of hydrogen dioxid, are solids. Oxygen obtained from ozone is usually produced by electric energy at the place of its consumption; it is an unstable gas which, for practical purposes, cannot well be stored. The dioxids are usually fairly stable compounds; they furnish any fixed amount of oxygen, if so desired, at any moment and are in reality transportable accumulators of available oxygen. Atomic oxygen—oxygen in its nascent state—has a free valency; it cannot remain in that state, but energetically seeks to combine with organic matter. This powerful affinity for every oxidizable substance, including albumin, is known as oxidation, or when accompanied by heat and light, as combustion.

The earlier dioxid preparations were found to be lacking in strength; aqueous solutions containing more than 3 or 4 per cent. of absolute hydrogen dioxid were found to be too unstable to keep for any length of time, and hence were unreliable. The problem of securing a stable high percentage solution of the dioxid was solved by using ether as a menstruum.

Subsequent to the introduction of the pyrozone preparations, the firm of Merck has produced a 100-volume solution of hydrogen dioxid under the trade name of perhydrol, which is the most active and efficient of the hydrogen dioxid preparations as tooth bleaching agents. Aside from the ordinary 3 per cent solution of hydrogen dioxid, higher concentrated solutions are found on the market. A 25 per cent. solution of hydrogen dioxid in ether is known as caustic pyrozone, and a 30 per cent. solution in water is known as perhydrol, or as peraquin. Caustic pyrozone is put up in glass tubes containing a few cubic centimeters, while perhydrol is marketed in paraffin-lined bottles of various sizes. In opening a pyrozone tube, great care should be exercised to prevent explosion by placing the tube in cold water and wrapping it in a wet towel before the end is broken off. Its contents must be transferred at once to a glass-stoppered bottle, provided with a ground cap, to prevent evaporation of the ether. Perhydrol solution is to be greatly preferred whenever a highly concentrated solution of hydrogen is desired. It is a chemically pure solution of H_2O_2 in distilled water, furnishing about 30 per cent. by weight or 100 per cent. by volume of available oxygen. It is absolutely free from acid, and may be diluted with water or alcohol to any desired strength. Solutions should be made fresh as needed. If carefully preserved in the original container and stored in a cool place perhydrol will retain its oxygen for some time. Very recently, hydrogen dioxid in dry form, known as perhydrit, has been placed on the market. Perhydrit is a compound of hydrogen dioxid and urea, containing about 30 to 35 per cent. of available hydrogen dioxid. It is a very unstable compound.

Any soluble dioxid compound intended for bleaching purposes should be tested for its oxygen content. A simple test is made as follows: mix ten cubic centimeters of distilled water with ten drops of dilute sulphuric acid, one drop of potassium chromate test-solution (one part potassium chromate dissolved in sufficient water to make one hundred cubic centimeters), and two cubic centimeters of ether. On the addition of the solution containing hydrogen dioxid, a blue color will appear at the line of contact which will, after shaking, separate with the ethereal layer.

Hydrogen dioxid, H_2O_2, belongs to the class of oxidizing bleachers, and owes its activity in this respect to the weak state of chemical combination in which one of its atoms of oxygen is bound to the water molecule. Many substances serve to disrupt the compound and liberate one of its oxygen atoms. In contact with pus, blood, inspissated mucus, albumin, and in fact, almost every kind of organic matter, its decomposition takes place, liberating oxygen and decomposing the organic matter either wholly or in part. Hydrogen dioxid does not bleach all of the decomposition products of hemoglobin with equal facility. It quickly removes the pink discoloration following the initial extravasation of hemoglobin into the dentin, but when the brown stage has been reached, indicative of the formation of hematin, its action is but slight. Later, however, it bleaches more readily. The refractory nature of hematin with respect to hydrogen dioxid has been tested experimentally upon the substance out of the mouth.

It is important to note that all acids promptly convert hemoglobin into hematin, which is highly resistant to the action of hydrogen dioxid; therefore, whenever hydrogen dioxid is used to bleach a tooth in the primary or pivot stage of discoloration the hydrogen dioxid should be made alkaline with sodium carbonate or hydroxid to neutralize at least its usual slight acidity, otherwise its acid content will act upon the hemoglobin, converting it into hematin, and thus set the color in such a way as to be invulnerable to the action of the hydrogen dioxid.

In bleaching discolored teeth with hydrogen dioxid, perhydrol or the ethereal 25 per cent. solution known as pyrozone is applied directly to the internal portions of the tooth upon small pledgets of cotton or cotton wisps rolled upon a fine flexible canal instrument. After each application the menstruum is evaporated by blasts of warmed air from a hot air syringe, and the applications similarly made are repeated until the desired effect is produced. It has been found in practice that more rapid and permanent effects are produced when the solution is rendered alkaline. This may be done readily by the addition of a few drops of liquor ammoniæ fortior or by a solution of one of the caustic alkalies, namely, sodium or potassium hydroxid or

sodium dioxid. A very satisfactory method of securing the alkaline effect in this process is that suggested by Dr. D. N. McQuillan. His method is to treat first the pulp chamber and canals with applications of Schreier's kalium-natrium preparation and after the debris from its action has been mechanically removed with instruments and cotton twists, without washing the canal, an application of pyrozone is made. The bleaching action follows with great rapidity, and has apparently greater permanence than when the pyrozone is used alone. In cases in which the action proceeds very slowly, for example, when at the end of a thirty minutes' continuous treatment the bleaching is not complete, it is well to seal an application of pyrozone upon cotton in the canal and allow it to remain for twenty-four hours, when a second treatment will usually complete the operation.

In this, as in all bleaching operations, it is advisable to fill the tooth temporarily with some filling which may be easily removed in order to test the permanence of the operation, and after the lapse of a reasonable time, if there is no tendency to a return of the discoloration, the canals and cavity may be filled permanently.

Harlan's method consists in acting upon hydrogen dioxid by aluminum chlorid. The aluminum salt is packed in the cavity and moistened with the dioxid. Experimental study of the reaction between aluminum chlorid and hydrogen dioxid by Dr. E. C. Kirk developed the fact that oxygen and no chlorin was given off, and that the aluminum chlorid was unaltered during the process. Hence it was discovered that the reaction was due simply to a catalytic action of the aluminum salt (a property which in this relation it shares in common with many other metallic salts, whereby nascent oxygen is liberated from the hydrogen dioxid. The process, therefore, has no greater value than those in which hydrogen dioxid is applied directly.

The Sodium Dioxid Method.—Sodium dioxid, Na_2O_2, is the chemical analogue of hydrogen dioxid, and like the latter is characterized by the readiness with which it parts with its atom of loosely combined oxygen under similar circumstances. The essential difference in its properties is the character of its by-product after its decomposition has taken place. Being a strong caustic alkali, sodium dioxid still retains its alkaline and caustic properties after the loss of one of its atoms of oxygen, becoming Na_2O, which in combination with water is ordinary sodium hydroxid or caustic soda. This substance, as well as the sodium dioxid, has not only a saponifying property for all of the vegetable and animal oils and fats, but also a solvent action upon animal tissue. This property is of great value in removing from the dentin structure all of the contained organic matter, whether normal or in a state of decomposition. Having the oxidizing and consequently the

bleaching quality in addition to its solvent and saponifying properties, it is, therefore, one of the most valuable bleaching and detergent agents at our command. The substance is dispensed as a yellowish-white powder in tin cans or glass bottles hermetically sealed, as it is very hygroscopic, and after twenty-four hours' exposure to moist air absorbs nearly its own weight of water; it also loses much of its activity.

For use as a bleaching agent, it is always applied to the dentin in saturated solution, and never in the solid. In making the solution special care is necessary in order to avoid raising of temperature, by reason of the energy with which it enters into combination with the water. If the solution is allowed to become heated in the making, decomposition of the compound with loss of oxygen occurs, and its bleaching power is destroyed. The solution is best made by pouring into a small beaker, of 1 ounce capacity, about 2 drams of distilled water, and immersing the beaker in a larger vessel or dish containing iced water or pounded ice. The can containing the dioxid powder should then have its lid perforated with a number of small holes similar to the lid of a pepper shaker, and the powder should be dusted slowly into the distilled water in the small beaker; or the powder may be dropped gradually into the water by tapping it from the point of a knife or spatula. The powder is added to the water until the solution assumes a semi-opaque appearance, indicating the point of saturation.

On removing the beaker from the cooling mixture, the dioxid solution in a few minutes will assume a transparent, straw-colored appearance and is ready for use.

The applications are to be made similarly to those of hydrogen dioxid, but upon asbestos fiber instead of cotton, as the latter is acted upon by the sodium dioxid and converted into a glue-like material, which is difficult to remove and which interferes with the success of the operation.

After the dentin, which should have been desiccated previously, is thoroughly saturated with the dioxid solution, an application of 10 per cent. sulfuric acid should be made, which neutralizes the strong alkali, forming sodium sulfate and hydrogen dioxid, thus:

$$Na_2O_2 + H_2SO_4 = Na_2SO_4 + H_2O_2.$$

The reaction is usually attended with some effervescence which, taking place in the tubular structure of the dentin, mechanically forces out its contents and thus exerts a detergent action upon it. The tooth should now be washed with hot distilled water in copious quantity and the dioxid application repeated, omitting the subsequent treatment with acid, but washing again thoroughly with the hot water.

Sodium dioxid solution, as prepared for bleaching, may be applied

to the pulp chamber and root canal without the preliminary treatment required where other bleaching agents are employed. It is without harmful irritative action upon the apical tissues unless used in excess or forced through the foramen by careless manipulation. It is a powerful germicide and disinfectant, and therefore peculiarly suited to the treatment of putrescent cases, which, by its action, are rendered sterile and aseptic as well as bleached at one operation. Its saponifying and solvent properties remove completely the greasy dark layer of decomposed material which is found lining the pulp chamber and canals, alluded to previously, so that the use of the sodium dioxid method makes unnecessary the preliminary application of borax or ammonia for its removal. When sodium dioxid is used for its sterilizing property, the foramen should be allowed to remain unsealed until after the bleaching operation has been completed. It happens sometimes that the improvement in color following the application of the dioxid methods is only partial, and the result falls short of restoration to normal; or, in other words, the bleaching reaches a certain point beyond which the color resists the further action of the bleaching agent. In such cases the decomposition of the color molecule has probably resulted in the formation of iron oxid as an end-product. In practice this residual discoloration can be removed generally by treatment with oxalic acid. A small crystal is to be sealed in the moist pulp chamber for twenty-four hours, and afterward washed out with a copious irrigation of hot distilled water.

The sodium dioxid method removes the tubular contents more completely than any other method, and the result is unique from the fact that not only is the tooth restored to normal color, but to normal translucency; the opaque white effect resulting from other methods of bleaching is due to the bleached organic debris remaining in the tubuli, but by the solvent action of the strong caustic alkali this is removed. The final treatment of the tooth is the same in this as in other methods, though the dentin should be desiccated and saturated as thoroughly as possible with an unalterable varnish before the final filling is inserted.

The Sulfur Dioxid Method.—Reference has already been made to sulfur dioxid as the single example of the reducing type of bleaching agent. Its activity is due to its affinity for oxygen, and it bleaches by seizing upon, and combining with, that element of the color molecule, thus destroying its identity and consequently its color. Attempts have been made to utilize the bleaching property of sulfur dioxid in the treatment of discolored teeth by direct application of the solution of the gas in water and by igniting small quantities of sulfur in the root canal by means of the electro-cautery wire. These methods have, however,

proved inefficient. The gas may be used successfully in bleaching teeth by evolving it from its compounds placed in the cavity and root canal in a manner analogous to that employed in the Truman chlorin process already described. For this purpose Dr. Kirk's method may be employed conveniently: 100 grains of sodium sulfite and 70 grains of boric acid are separately desiccated and afterward ground together in a warm dry mortar. The powder is then to be transferred to a tightly-stoppered bottle. For bleaching purposes the powder is packed into the root canal and cavity of the tooth, and then moistened with a drop of water and the cavity immediately closed as tightly as possible with a stopping of gutta-percha previously prepared and warmed. A reaction ensues between the boric acid and sodium sulfite whereby sulfur dioxid is liberated, thus:

$$2H_3BO_3 + 3Na_2SO_3 = 2Na_3BO_3 + 3H_2O + 3SO_2.$$

The process is effective in many cases in which the chlorin methods have failed, but is slow in its action, and is largely superseded by the hydrogen dioxid and sodium dioxid methods.

CATAPHORIC BLEACHING OF TEETH.

It has been found that aqueous solutions of hydrogen dioxid may be carried into the dentinal structure with great ease by the cataphoric action of the continuous electric current. The appliances necessary for tooth bleaching operations by this means are practically the same as those required in the treatment of hypersensitive dentin. The resistance offered by the hard structures of the tooth is much greater after loss of the tooth pulp, requiring a much higher voltage pressure to drive the bleaching agent into the tissue. While in some cases twenty-five to thirty volts will be all that is necessary, other cases will require as high as sixty volts to carry 1.5 milliampères of current through the dentin. The ethereal solution of hydrogen dioxid has been found to oppose too great resistance to the current but the aqueous solution, containing a slight addition of some salt to increase its conductivity, is entirely manageable.

A 25 per cent. aqueous solution of hydrogen dioxid may be made quickly by shaking together in a test-tube one volume of water and two volumes of 25 per cent. pyrozone. The H_2O_2 dissolves in the water, and the ether of the pyrozone may be removed by pouring the mixture into a small evaporating dish of porcelain or glass and gently heating it over a water-bath until all of the ether has evaporated. The addition of a small quantity of sodium acetate or

sulfate will diminish greatly the resistance of the solution to the passage of the current.

With the tooth isolated by the rubber dam and having received the treatment preliminary to bleaching, as already described in detail, the aqueous solution of H_2O_2 is dropped upon cotton in the tooth cavity and a platinum needle anode is applied in contact with it. The cathode may be a sponge electrode moistened with salt solution and held in the hand or applied to the cheek or neck. The hand, however, is preferable because of the amount of voltage required in the operation. Great care must be exercised that the external surfaces of the tooth are kept dry, so that short-circuiting of the current may not take place. In some cases a more rapid effect is obtained by making contact of the cathode pole through a needle electrode upon the external surface of the tooth, and with the anode applied to the pyrozone solution on cotton in the tooth. The cotton must at all times be kept wet with the solution.

The arrangement of the electric terminals with respect to the bleaching operation is both theoretically and practically correct as described, namely, the flow of current should be from the anode point through the bleaching solution and tooth and the body of the patient to the cathode. In practice it has been found in some cases which have failed to bleach, with the elements arranged in the series as stated, that upon reversing the poles and direction of current flow the bleaching has followed rapidly. The explanation of this apparent paradox is that by the application in normal order H_2O_2 was first carried into the tubular structure, and the reversal of the current has acted upon the tubular contents now saturated with the dioxid, and by its propulsive as well as electrolytic effect has removed the pigmentary matter pulpward from the tubuli. Bleaching with reversed poles would be impossible without previous saturation of the dentin by the dioxid solution.

Dr. M. W. Hollingsworth has devised an ingenious apparatus for cataphoric bleaching which is of special value, as it makes possible the enveloping of the entire tooth with the bleaching fluid, in which it is immersed. The appliance is shown *in situ* in Fig. 403, and consists of a thin vulcanized caoutchouc bulb shaped like the bulb of a medicine dropper. Through a perforation at its rounded end, made with the ordinary rubber dam punch, the tooth is slipped by mounting the bulb on the applicator (Fig. 404) and forcing it over the tooth as though it were a rubber dam. A glass tube is then attached to the open end of the bulb, and to the glass tube is connected a spiral platinum wire electrode (Fig. 405). Before the electrode is attached the bulb and glass tube are filled with the aqueous pyrozone solution by means of a duplex syringe (Fig. 406), the lower and larger bulb of which exhausts

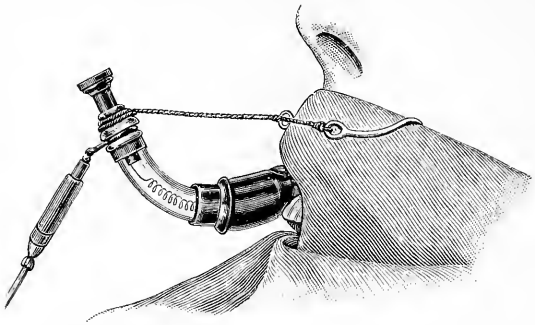

FIG. 403.—Hollingsworth's device for applying the bleaching agent to the tooth.

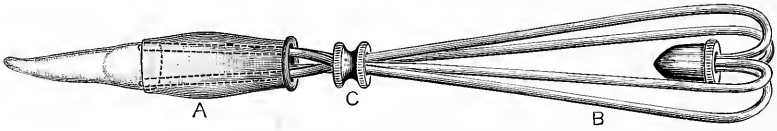

FIG. 404.—Applicator.

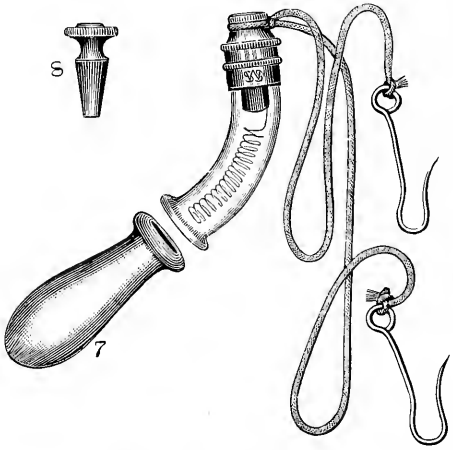

FIG. 405.—Tube electrode.

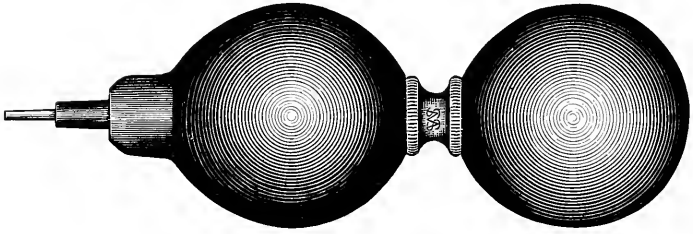

FIG. 406.—Duplex syringe.

the contained air in the apparatus and the smaller thumb bulb injects the bleaching solution into the exhausted apparatus. Connection is now made with the source of current as usual, and the bleaching is very rapidly effected. Dr. Hollingsworth recommends the addition of about 1 per cent. of zinc sulfate to the aqueous pyrozone solution, which not only diminishes the resistance to the passage of the current, but has a coagulating effect upon the bleached organic matter, which gives it translucency and greatly enhances the permanency of the operation. The results obtained by this method are extremely satisfactory.

LIGHT AS AN ADJUVANT TO THE BLEACHING PROCESS.

If a piece of raw textile fabric is subjected to the simultaneous influence of air, moisture and sunlight, it is bleached. This process is known as natural or Holland bleaching to differentiate it from chemical or artificial bleaching. Most likely, during the process of natural bleaching ozone, O_3, is obtained which in turn is split up in $O_2 + O$ (nascent state). This very slow process may be facilitated materially by utilizing a concentrated solution of hydrogen dioxid in the presence of concentrated artificial light.

In 1907 Magay[1] introduced an improved method of bleaching discolored teeth which consisted in applying perhydrol and concentrated sunlight. To overcome the inconvenience of the untrustworthy sunlight, Levy,[2] in 1912, substituted artificial light with most gratifying results.

For a clear understanding of the action of light in this respect, it is probably not amiss to recapitulate briefly the nature of light rays from the physicist's point of view. The solar spectrum furnishes a band of colors consisting of violet, indigo, blue, green, yellow, orange and red shades, which overlap each other. Beyond either end of the visible spectrum are found a number of rays, the more important ones being known as the electric, and ultra-red rays near the red shade and ultra-violet rays near the violet shade. The rays between the ultra-red and blue division are heat producers and are spoken of as thermic or caloric rays; the rays between the red and violet division are predominant in the production of light and are referred to as luminous or optic rays, while the rays between the red and the tri-ultra-violet division exercise a marked chemical influence on organic and inorganic matter and are known as chemical or actinic rays. The most active actinic rays are those between the blue and ultra-violet division and are known as

[1] Deutsche Monatschrift f. Zahnheilkunde, 1907, p. 65.
[2] Ibid., 1912, p. 138.

Finsen rays. By interposing either clear or various colored glass lenses in the path of the rays, certain rays are absorbed, as, for instance, red glass obstructs the passage of the light and chemical rays, clear glass absorbs most of the blue and ultra-violet rays (the Finsen rays), blue glass causes a partial absorption of heat rays. In experimenting with the various rays to ascertain their influence on the bleaching process, it has been observed that primarily the heat, and to a less extent the luminous rays, are the principal factors, the actinic rays apparently playing no part therein. The source of light for this purpose may be obtained from any illuminating device. However, a light of very high candle power which can be focussed in the desired direction is to be

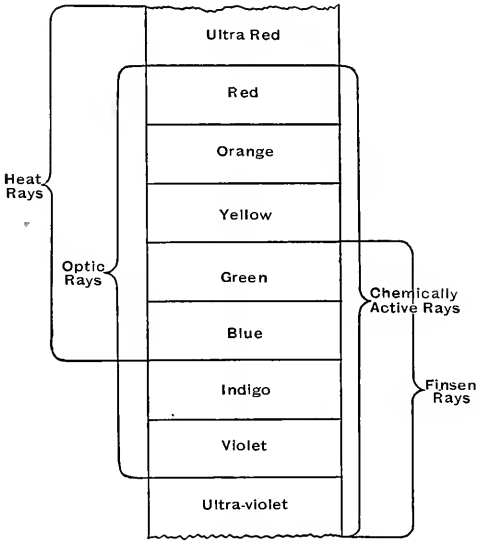

Fig. 407.—Diagram of the incomplete spectrum.

preferred. A tungsten flash light, a dental illuminator, an electric arc lamp or a special bleaching apparatus provided with a suitable reflector and a double convex collecting lens are serviceable. The preparation of the tooth for bleaching by this method is precisely the same as outlined above. The pulp chamber is loosely filled with cotton and a piece of gauze is tied about the tooth and moistened with perhydrol applied with a medicine dropper. The light is focussed directly upon the exposed tooth and a drop of perhydrol is added from time to time to replace the solution lost by evaporation. In the course of twenty to thirty minutes, the tooth is usually restored to its normal color in such cases as are amenable to the bleaching action of the

dioxids. It is always preferable to apply a second treatment after the lapse of a week.

The bleaching of discolored teeth by the combined utilization of concentrated hydrogen dioxid and light offers most satisfactory results.

SPECIAL DISCOLORATIONS AND THEIR TREATMENT.

Pulpless teeth are especially liable to discoloration from external and accidental causes. If decayed and the cavity has remained unfilled for a length of time, many substances which find their way into the oral cavity either as food or as medicine may produce discoloration when absorbed by the tooth through the open cavity walls.

Metallic Salts.—Metallic salts are particularly likely to cause such staining by reaction with the sulfids with which the dentin structure is usually saturated during decomposition of its organic contents. Many of the medicaments used in pulp-canal treatment, or even for hypersensitive dentin, may stain the tooth structure, and finally, the action of sulfids in the structure of a pulpless tooth may react with amalgam fillings, forming salts of mercury, silver, tin, copper, etc., which are absorbed by the tooth, resulting in its discoloration. The treatment of these stains, which were grouped as Class III at the beginning of this chapter, is extremely difficult and often unsatisfactory. However, there may arise individual cases of discoloration of this class. It is of the utmost importance to treat these, and much may be accomplished when the causes of the discoloration are known and the proper bleaching method is applied.

Gold Stains.—Gold stains may arise, as has been indicated, from the injudicious use of gold instruments or failure to remove all gold fillings when applying some of the chlorin methods of bleaching. In the course of time the tooth assumes a pinkish hue, which merges into a characteristic violet or purple, finally becoming black.

Iron Stains.—Iron stains may arise from the use of steel instruments in connection with the chlorin methods of bleaching or in contact with iodin or any of the mineral acids used in connection with canal treatment. The iron stain is yellowish at first, gradually becoming brown and finally black.

Copper and Nickel Stains.—Copper and nickel stains may arise from contact with these metals or their alloys, as copper amalgam or nickel or German silver dowels for artificial crowns or anchorages for fillings. The stains from these metals are—for copper, bluish to black, and for nickel, a characteristic chlorophyl green, which eventually becomes black.

The best general treatment for all of the foregoing stains is to bleach

the tooth by the chlorin method, with observance of the several precautions already recommended; and when the color of the metallic stain has been discharged by conversion of the dark-colored salt into a soluble chlorid, wash the tooth thoroughly first with dilute chlorin water 50 per cent., and afterward with hot distilled water, to remove all of the metallic chlorid which has been formed. The process may require repetition to secure permanent results.

Silver Stains—Silver stains are comparatively easy to remove, either by an application of the chlorin method or by saturating the tooth with tincture of iodin, thus converting the silver into a chlorid or iodid, as the case may be, after which it may be dissolved out with a saturated solution of ammonia or sodium hyposulfite applied as a bath to the tooth. For this purpose the Hollingsworth bulb dam (see Fig. 403) answers admirably, and although the experiment has not been as yet tried, there is good reason to believe that the cataphoric method with electrodes applied in reverse order would, under these circumstances, greatly facilitate the solution and removal of the metallic salts.

Mercurial Stains.—Mercurial stains are always black from the formation of mercuric sulfid, and are removable by the same method as are silver stains, with the exception that when the stain has been converted into a chlorid by the chlorin method, the mercuric chlorid is best removed by an aqueous ammoniacal solution of hydrogen dioxid, or when the stain has been converted into mercuric iodid by the use of a saturated solution of potassium iodid. In both cases a final washing with hot distilled water is a *sine quo non.*

Manganese Stains.—Manganese stains frequently occur from the use of potassium permanganate, in solution or in substance, in the treatment of putrescent canal conditions. The manganese stain is a characteristic mahogany brown. It is removed very readily by a 25 per cent. aqueous solution of hydrogen dioxid in which oxalic acid crystals have been dissolved to saturation. A few applications of this mixture will quickly decolorize the stain, after which a liberal treatment of hot distilled water is required as in the foregoing cases.

Organic Stains—Organic stains are occasionally observed after the use of organic drugs employed in the treatment of infected root canals. Preëminent among these drugs are the essential oils of cassia and to a very much less extent that of cloves. These oils contain furfurol, a colorless pyromucic aldehyd, which readily turns brown on exposure to air and light and stains the tooth structure a tan color. These pigments are removed readily by any one of the dioxid bleaching methods.

Superficial organic stains from foodstuffs, especially fruits, such as blueberries, black cherries, etc., from the use of tobacco or from chewing

betel nuts and the green discolorations upon the teeth of children (growth of various molds and fungi upon Nasmyth's membrane and formation of sulfomethemoglobin) and occasionally from colored dentifrices, are usually removed readily by employing a fine abrasive (pumice stone) mixed into a paste with hydrogen dioxid. In tobacco and betel nut stains alcohol mixed with pumice stone powder is to be preferred.

In bygone days it was customary with the married women of Japan to blacken their teeth with a concoction known as "Okaguro" or "Kane" and which is said to be composed of urine, iron filings and saké. The stain produced by this caustic fluid is more or less permanent. At present, this custom has fallen largely into disuse.

In all cases a careful diagnosis of the chemical nature of the discoloration should be made when possible. Much information upon this point may be gained by a detailed study of the present condition of the tooth and its environment, but in addition to this the patient should be questioned as to the history of the case, and especially as to its previous treatment. The data thus obtained should be noted carefully, and treatment instituted in accordance with the conditions to be met.

Success in the bleaching of teeth demands a recognition of the fact that each case presents individual peculiarities, that the problem is essentially a chemical one always, and that the bleaching method in any given case must be selected with special reference to the character of the discoloration and applied with due care to its details in order that the chemical requirements of the operation may be met intelligently, without which care success is impossible.

CHAPTER XII.

LOCAL ANESTHESIA.

By HERMANN PRINZ, M.D., D.D.S.

Local anesthetics are agents which are employed for the purpose of producing insensibility to pain in a circumscribed area of tissue.

History.—From an historical viewpoint, comparatively few important facts are to be recorded prior to the introduction of cocain for the purpose of obtunding pain locally. The compression of nerve trunks for the abolition of pain seems to be of an old and unknown origin, which was revived by Guy du Chauliac and Ambroise Paré, and indirectly found a permanent place in surgery as the Esmarch elastic bandage. Physically reducing the temperature of a part of the body by the application of cold was instituted much later. Bartholin and Severino introduced this method in the middle of the sixteenth century. It became a lost art, however, until John Hunter, of London, again called attention to its benefits by demonstrating it upon animals, and Larrey, the chief surgeon of Napoleon's army, employed it for amputations in 1807. Through the efforts of Sir B. W. Richardson, in 1866, it was placed upon a rational basis by the introduction of the ether spray. The various narcotics which were employed for internal purposes were also made use of as local applications. Mandragora, henbane, aconite, the juice of the poppyhead, and many other analgesic drugs enjoyed a world-wide reputation. The empirical search for new methods and means pressed the mysticism of the electric current into service, opening a prolific field to the charlatan which even to this day has not lost its charm. Richardson's voltaic narcotism for a time attracted the attention of the medical profession; and Francis, in 1858, recommended the attachment of the electric current to the handles of the forceps for the painless extraction of the teeth, and as dental markets still contain appliances of this nature for sale, it seems that the method is still in vogue with some operators. In the early days of modern dentistry we met with many feeble efforts to alleviate pain during trying operations. Chloroform, alcohol, ether, aconite, opium, the essential oils, and many other drugs were the usual means employed, either simply

or as compounds, usually under fanciful names, for such purposes. Snape's calorific fluid, composed of chloroform, tincture of lemon balm, and oil of cloves; nabolis, consisting of glycerite of tannic acid and a small quantity of chloral hydrate; Morton's letheon, which was sulphuric ether mixed with aromatic oils, are examples of proprietary preparations which enjoyed quite a reputation in their time.

In 1844 F. Rynd, an Irish surgeon, introduced a method of general medication by means of hypodermic injections which, in 1853, was much improved by Alexander Wood, of Edinburgh. It was suggested at once that such drugs as morphia or tincture of opium be employed for the purpose of producing local anesthesia. The results were not encouraging, however, until Koller, in 1884, advocated cocain. With the introduction of this drug into therapeutics, local anesthesia achieved results which were beyond expectations, and its adoption created a new era in local anesthesia.

Means of Producing Local Anesthesia.—The term anesthesia (without sensation), which was suggested to Dr. Morton in 1846 by that great physician-litterateur, Oliver Wendell Holmes, is usually defined as an artificial deprivation of all sensation, while the mere absence of pain is referred to as analgesia. Correctly speaking, the term local anesthesia is partially a misnomer. In producing local anesthesia we do not fully comply with all the requirements that anesthesia demands, because a part of the sensorium—the sense of touch, for instance—is not abolished. The term local anesthesia has, however, acquired such universal recognition that it would seem unwise to recommend a change.

Anesthesia may be produced artificially by inhibiting the sensory nerve fibers at their central end-organs in the brain or at their peripheral end-organs in the tissues, thus producing general and local anesthesia. Local anesthesia may be obtained in two definite ways: we may inhibit the function of the peripheral nerves in a circumscribed area of tissue, and refer to this process as terminal anesthesia; or, we may block the conductivity of a sensory nerve trunk somewhere between the brain and periphery, and speak of it as conduction anesthesia. Dental terminal anesthesia is usually produced by a subperiosteal injection (indirect anesthetization) or a peridental injection (direct anesthetization), while conduction anesthesia may be produced by injecting into the nerve trunk proper—endoneural injection—or by injecting into the tissues surrounding a nerve trunk—perineural injection. The latter form is the usual method pursued when conduction anesthesia for dental purposes is indicated.

LOCAL ANESTHESIA.

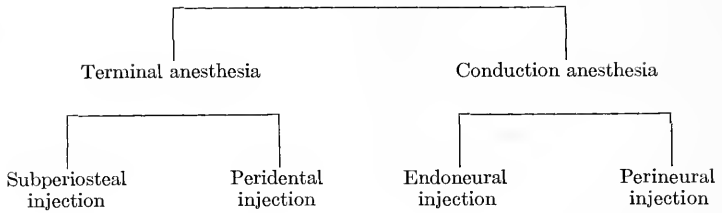

The successful practice of local anesthesia involves the carefully adjusted coöperation of a number of important details, each one constituting a definite feature in itself, which, when neglected, must necessarily result in failure. The more important details follow:

1. A sterile solution of drugs possessing active anesthetic potencies and which, in their composition, must correspond to the physical and physiologic laws which govern certain functions of the living cells.
2. A carefully selected sterile hypodermic armamentarium.
3. A complete mastery of the technic.
4. A proper selection of the correct methods of injection suitable for the case in hand.
5. Suitable preparation of the site of injection.
6. The complete coöperation of the patient.
7. Good judgment of prevailing conditions.

PHYSIOLOGIC ACTION OF ANESTHETICS.

According to more recent therapeutic conceptions, it is generally recognized that a drug or combination of drugs which simultaneously produces local anemia and inhibition of the functions of the sensory nerves in a circumscribed area of tissue is the logical solution of the question of local anesthesia. Certain important factors, however, relative to the physiologic and physical action of the solution employed for hypodermic injection upon the cell, govern the successful application of such methods. It is of prime importance, therefore, to comply with the laws regulating the absorption of injected solutions, namely, osmotic pressure.

If we separate two solutions of salt of different concentration by a permeable membrane, a continuous current of salt and water through the membrane results, which ceases only after equalization of the density of the two liquids, namely, when equal osmotic pressure, according to the Boyle—Van't Hoff's Law—is established. The current passes in both directions, drawing salt from the stronger to the weaker solution and water, vice versa, until osmotic equilibrium is obtained. The

resultant solutions are termed isotonic (De Vries). Osmotic pressure is a physical phenomenon which is possessed by water and all aqueous solutions; it is dependent upon the number of molecules of salt present in the solution and upon their power of dissociation. In organized nature these osmotic interchanges are an important factor in regulating the tissue fluids of both animals and plants. In the animal tissue the circulation depends principally upon the mechanical force exerted by the heart. The life of the cell depends upon the continuous passage of the fluids which furnish the nutrient materials, consisting of water, salts and albumin. These chemicals are normally present in certain definite proportions. The membrane of the living cell is, however, only semi-permeable, namely, the cell readily absorbs distilled water when surrounded therewith; it becomes macerated, loses its normal structure and finally dies. If, on the other hand, the surrounding fluid be a highly concentrated salt solution, the solution absorbs water from the cell; no salt molecules enter the cell body proper. The cell shrinks and finally dies. This process of cell death in general pathology is referred to as necrobiosis.

A further important factor teaches us that all aqueous solutions which are isotonic possess the same freezing point, namely, all solutions possessing an equal freezing point are equimolecular and possess equal osmotic pressure. This law of physical chemistry has materially simplified the preparation of such solutions. The freezing point of human blood, lymph, serum, etc., has been found to equal, approximately, 0.55° C., which in turn corresponds to a 0.85 per cent. sodium chlorid solution. Such a solution is termed a physiologic salt solution. In the older works on physiology a 0.6 per cent. sodium chlorid solution is referred to as a physiologic salt solution; this solution corresponds to the density of the blood of a frog. A slight deviation above and below the normal percentage of the solid constituents is permissible. When physiologic salt solution at body temperature is injected into the loose connective-tissue under the skin in moderate quantities, neither swelling nor shrinkage of the cells as such occurs; a simple wheal is formed which soon disappears; therefore no irritation results, and no pain is felt. Similar bodies which are equally soluble in water act in the same manner, with the exception of the salts of the alkali and earth metals, such as potassium or sodium bromid. The latter substances produce intense physical irritation, followed by prolonged anesthesia, and consequently, are termed by Liebreich "painful anesthetics." If, on the other hand, simple distilled water be injected, a superficial anesthesia only is produced; the injection itself is very painful and acts as a direct protoplasm poison by macerating the cell contents and resulting in severe damage or even death

of the cell. If distilled water approximately at the ratio of 10 drams to the pound of body weight be injected into dogs, they will succumb in a short time. The injection of higher concentrated salt solution produces opposite effects; water is removed from the cells with more or less pronounced pain, followed by superficial anesthesia. The red corpuscles are extremely susceptible to any injected fluid which is not isotonic in its nature. They are destroyed (hemolysis) by the injection of fluids which are not represented by an isotonic salt solution. Hypotonic solutions cause swelling of the tissues, while hypertonic solutions produce shrinkage. These manifestations are proportionately the more intense the further the solution is removed from the freezing point of the blood. Furthermore, hypotonic solutions as well as hypertonic solutions, require much more time for their absorption than isotonic solutions; the osmotic pressure must be standardized to the surrounding tissue fluids.

Local anemia prevents the rapid absorption of fluids that are injected into the affected area. Retarded absorption means increased action and consumption of the injected drug and, as a consequence, less danger from general absorption.

The more important means to produce local anemia are: (1) the Esmarch elastic bandage; (2) the application of cold, and (3) the extract of the suprarenal capsule.

Some observers have maintained that local anemia produces anesthesia. This, however, is not the case; it is merely an important means of confining the injected anesthetic to the anemic region, and thus bringing about an increased and prolonged action of the drug. Consequently, the concentration of the anesthetic solution may be of a lower percentage, which, of course, lessens the danger of intoxication. For plausible reasons the Esmarch elastic bandage cannot be made use of for dental operations.

Physically reducing the temperature of the body by the application of cold (ice pack, ice and salt mixture, cold, metals, etc.), was practiced by the older surgeons. Arnott in 1849 and Blundell in 1855 advocated ice packs for the painless extraction of teeth. Through the efforts of Sir B. W. Richardson, in 1866, this method was placed on a rational basis by the introduction of the ether spray. To obtain good results, a pure ether (boiling point 95° F., 35° C.) free from water is necessary. Certain other volatile hydrocarbons possess similar properties in varying degrees, depending upon their individual boiling point. In 1867 Rottenstein called attention to the use of ethyl chlorid as a refrigerating agent, and Rhein, in 1889, introduced methyl chlorid for the same purpose. In 1891, Redard reintroduced ethyl chlorid as a local anesthetic, which since has become known by many trade names—as

antidolorine, kelene, narcotile, etc. Mixtures of the first two in various proportions known as anestol, anestile, coryl, metethyl, etc., are extensively used in minor oral and general surgery. A pure ethyl chlorid (boiling point 55° F., 13° C.) is best suited for this purpose, as it lowers the temperature of the tissues sufficiently to produce a short superficial anesthesia in a few minutes. Too rapid cooling or prolonged freezing by methyl chlorid (boiling point, −12° F., −24.5° C.) or the various mixtures thereof, produces deeper anesthesia. Such procedures are dangerous because they frequently cut off circulation in the affected part so completely as to produce sloughing (necrosis). Liquid nitrous oxid, liquid or solid carbon dioxid (recently known as carbonic acid snow), and liquid air, all of which have a boiling point far below zero, are recommended for similar purposes, but they require cumbersome apparatus and are extremely dangerous.

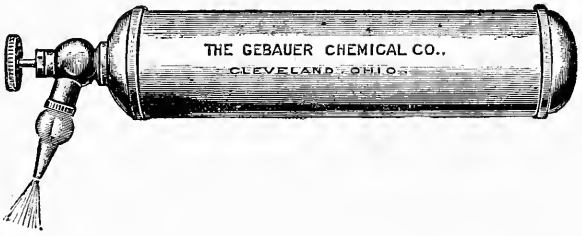

FIG. 408.—Ethyl chlorid spray tube. (Metal.)

ETHYL CHLORID AND ITS ADMINISTRATION.

Ethyl chlorid (monochlorethane; hydrochloric ether; C_2H_5Cl). "A haloid derivative, prepared by the action of hydrochloric acid gas on absolute alcohol." At normal temperature, ethyl chlorid is a gas and under a pressure of two atmospheres it condenses to a colorless, mobile, very volatile liquid, having a characteristic, rather agreeable odor, and burning taste. It boils at about 55° F. (13° C.) and is very inflammable, burning with a smoky, green-edged flame. It is stored in sealed glass or metal tubes, and when liberated at ordinary room temperature, 70° F. (21° C.) evaporates at once. In commerce it is supplied in plain or graduated tubes of from 30 to 60 grams capacity, or stored in metallic cylinders holding from 60 to 100 grams or more. To remove the ethyl chlorid from the hermetically sealed small tubes, the neck must be broken off, while the larger glass and metallic tubes are provided with suitable stopcocks of various designs to allow definite amounts of the liquid to be released.

Mode of Application.—For the extraction of teeth, immediate removal of the pulp, opening of abscesses and other minor operations about the

oral cavity, the tube should be warmed to body temperature by placing it in heated water, and its capillary end should be held about six to ten inches from the field of operation. The distance depends upon the size of the orifice of the nozzle. Complete vaporization should always be produced. The Gebauer tube is fitted with a spray nozzle, which shortens the distance one to two inches, and is especially well adapted for dental purposes. The stream is directed upon the tissues until the latter are covered with ice crystals and have turned white. For the extraction of teeth, the liquid should be projected directly upon the surface of the gum, as near to the apex of the root as possible, but care should be taken to protect the crown of the tooth on account of the painful action of cold on this part. The tissues to be anesthetized should first be dried and well surrounded by a film of vaselin or glycerin, and protected by cotton rolls and napkins, to prevent the liquid from running into the throat. Let the patient breathe through the nose. Occasionally light forms of general anesthesia are induced by inhaling the vapor. On account of the difficulty of directing the stream of ethyl chlorid upon the tissue in the posterior parts of the mouth, it is not successfully applied to those regions. The intense pain produced by the extreme cold prohibits its use in acute pulpitis and in pericementitis. To anesthetize the second and third branches of the fifth nerve, it is recommended that the stream of ethyl chlorid be directed upon the cheek in front of the tragus of the ear, but the author has not seen any good results from such a procedure. Caution should be exercised in using ethyl chlorid near an open flame or in conjunction with the thermocautery, as severe burns have resulted by setting the inflammable vapor on fire.

THE ACTIVE PRINCIPLE OF THE SUPRARENAL CAPSULE AND ITS SYNTHETIC SUBSTITUTES.

Within the last decade the active principle of the suprarenal capsule has evoked extensive comments in therapeutic literature. It has been isolated by a number of investigators under different names, as epinephrin by Abel, suprarenin by Fuerth, and adrenalin by Takamine and Aldrich. Many other titles are given to this chemical, as adnephrin, paranephrin, suprarenalin, supracapsulin, hemostasin, etc. Epinephrin is a grayish-white powder, slightly alkaline in reaction, and perfectly stable in dry form. It is sparingly soluble in cold and more soluble in hot water, is insoluble in ether or alcohol, and with acids it readily forms soluble salts. The preparation that is employed mostly for therapeutic purposes is a solution of epinephrin hydrochlorid in a 1 to 1000 physiologic salt solution, to which preservatives, as small

quantities of chloretone, thymol, etc., are added. Alkali of any kind is especially destructive to this sensitive alkaloid; even the small quantities of free alkali present in ordinary glass are dangerous. Bottles intended for storing epinephrin solutions should be made of amber-colored alkali-free or Jena glass or bottles of ordinary glass should be immersed in a diluted solution of hydrochloric acid for a few days and then thoroughly washed in running water before they are used. Epinephrin solution does not keep well. On exposure to the air or light it is easily decomposed, becoming pink, then red, and finally brown, and with this change of color its physiologic property is destroyed. If the epinephrin solution be further diluted, it becomes practically worthless within a few days.

When epinephrin is injected into the tissues, even in extremely small doses, it temporarily raises the arterial blood-pressure, acting as a powerful vasoconstrictor by stimulating the smooth muscular coat of the bloodvessels, and thus produces local anemia. Large doses finally reduce the blood-pressure, and heart failure results. The respiration at first quickly increases, but slows down and finally stops with expiration. Its action is largely confined to the smooth muscle fibers of the peripheral vessels. Epinephrin is destroyed by the living tissue cells, the body ridding itself of the poison in some unknown manner. While epinephrin does not possess local anesthetic action, it increases very markedly the effect of certain anesthetics when combined with them. These observations are of vast importance in connection with the production of local anesthesia. Carpenter, Peters, Möller, and others referred to the use of epinephrin in this respect, and finally Braun, in 1902, published his classic researches, and to him and his co-workers, especially Heinze and Laewen, belongs the credit of establishing a rational basis for the production of local anesthesia. It is claimed that secondary hemorrhage frequently occurs after the anemia produced by the epinephrin has subsided, and that the tissues themselves suffer from the poisoning effect of the drug, resulting in necrosis. Such results are produced only by the injection of too large quantities, which, by their deeper action, close up the larger capillaries. The prolonged anemia will give way to a dilation of the bloodvessels, and if the tissues are too long deprived of the circulation, we are able to understand why sloughing may result. Small doses of epinephrin have no effect upon the tissues or on the healing of a wound. Palpitation of the heart and muscular tremor, which were occasionally noticed in the early period of the use of the drug, are the direct result of too large doses. Recently a synthetic epinephrin has been successfully prepared by Stolz, which, with hydrochloric acid, forms a stable and readily soluble salt. It is known as synthetic suprarenin hydrochlorid.

The new chemical has been carefully tested physiologically and in clinical work, and the consensus of opinion points to the fact that it is not only equal, but in certain respects superior, to the organic preparations. Synthetic suprarenin solutions may be sterilized readily by boiling. They are relatively stable, and their chemical purity insures uniform results. They are comparatively free from dangerous side actions. The author's observations regarding the value of synthetic suprarenin relative to its general behavior are in full accordance with the above statements, and its advantage over the organic preparations has led him to adopt it as a component in the preparation of local anesthetic solutions. For dental purposes, that is for injecting into the gum tissue, the dose may be limited to one drop of the epinephrin solution (1 to 1000) or the synthetic suprarenin solution (1 to 1000) added to each cubic centimeter of the anesthetic solution, 5 drops being approximately the maximum dose to be injected at one time.

The dosage of the relative amounts of epinephrin solution may be arranged as follows:

Add 1 drop of epinephrin to 1 c.c. of the novocain solution.
Add 2 drops of epinephrin to 3 c.c. of the novocain solution.
Add 3 drops of epinephrin to 5 c.c. of the novocain solution.
Add 4 drops of epinephrin to 8 c.c. of the novocain solution.
Add 5 drops of epinephrin to 10 or more c.c. of the novocain solution.

THE LOCAL ANESTHETICS.

Cocain.—Cocain, when injected into the tissues, produces typical local and general effects. Locally, it possesses a definite affinity for the peripheral nerves; it causes constriction of the smaller arteries, producing slight anemia in the injected area with diminished action of the leukocytes. However, different parts of the organism require different doses to bring about the same reaction. Upon mucous surfaces, paralysis of the sensory nerves is produced; the senses of touch and smell are temporarily inhibited. The blood and the circulation suffer little. If cocain in sufficient quantities be absorbed by the circulation, general manifestations are produced from bringing other tissues in close contact with the poison. The principal disturbances of the central nervous system make themselves known by vertigo, a very soft pulse, enlarged and staring pupils, and difficult respiration. Vomiting may occur; the throat feels dry; intense excitement is followed by epileptiform spasms; finally complete loss of sensation and motility results, which terminates in death from cessation of respiration. The general character of the disturbances is closely related to that which occurs in chloroform or ether poisoning. The typical picture of

cocain poisoning is produced when the blood flowing through the central nervous system contains a sufficient quantity of the drug, even for a moment only, which is dangerous to this organ. No maximum dose can be positively established. This is equally true of chloroform and ether when used for general anesthetic purposes. The many cases of so-called idiosyncrasy probably find an explanation in the too large doses which formerly were administered so frequently.

With our increased knowledge of the action of cocain upon the tissues and a proper technic of the injection, dangerous results are comparatively rare at present. No direct antidotes are known; the treatment of general intoxication is purely symptomatic. Anemia of the brain, which is of little consequence, may be overcome readily by placing the patient in a recumbent position or by complete inversion, if necessary. As a powerful dilator of the peripheral vessels the vapors of amyl nitrite are exceedingly useful; it is best administered by placing 3 to 5 drops of the fluid upon a napkin and holding it before the nostrils for inhalation. Flushing of the face and an increase in the frequency of the pulse follow almost momentarily. For convenience, amyl nitrite may be procured in small glass capsules, holding the necessary quantity for one inhalation. Nausea may be remedied by administering small doses of spirits of peppermint, aromatic spirits of ammonia, etc. To overcome the disturbances of respiration, quickly instituted artificial respiration is the alpha and omega of all methods of resuscitation. In cases of shock, Mumford recommends the hypodermic injection of morphin. Engstadt lauds very highly the administration of ether for such purposes and claims that it is *the* antidote for cocain and novocain. To obtain the best results, the ether should be administered upon a mask by the drop method and only to the degree of mild surgical analgesia.

The relative toxicity of a given quantity of cocain solution depends upon the concentration of its solution. Reclus and others have clearly demonstrated that a fixed quantity of cocain in a 5 per cent. solution is almost equally as poisonous as five times the same quantity in a $\frac{1}{2}$ per cent. solution. From the extensive literature on the subject, we are safe in fixing the strength of the solution for dental purposes at 1 per cent. This quantity of cocain raises the freezing point of distilled water just a little above 0.1° C. To obtain an isotonic solution corresponding to the freezing point of the blood, 0.8 per cent. of sodium chlorid must be added. Having thus prepared a cocain solution which is equal to the blood in its osmotic pressure upon the cell wall, it is necessary to aid the slightly vasoconstrictor power of the drug by the addition of a moderate quantity of epinephrin, thus increasing the confinement of the solution to the injected area by producing a deeper

anemia, for a two-fold purpose: (1) to act as a means of increasing the anesthetic effect of cocain, and (2) to lessen its toxicity upon the general system by slower absorption. As stated above, 1 drop of epinephrin solution added to 1 c.c. of the isotonic cocain solution is sufficient to produce the desired effect.

A suitable solution for dental purposes may be prepared as follows:

Cocain hydrochlorid	5 gr.	(0.30 gm.)
Sodium chlorid	4 gr.	(0.25 gm.)
Sterile water	1 fl. oz.	(30.00 c.c.)

To each syringeful (2 c.c.) add one drop of epinephrin chlorid solution when used.

Ready-made cocain solutions are sterilized with difficulty and will not keep when frequently exposed to the air. Ready-made anesthetic solutions as found in the market usually contain preservatives, such as phenol, naphthol, boric acid, iodin, essential oils, alcohol, etc., in variable quantities. Some of these solutions have a distinct acid reaction. While they may produce a serviceable degree of anesthesia, they usually damage the injected tissues sufficiently to retard the normal process of wound healing.

Substitutes of Cocain.—Ever since the introduction of cocain into materia medica for the purpose of producing local anesthesia, quite a number of substitutes have been placed before the profession, for which superiority in one respect or another is claimed over the original cocain. The more prominent members of this group are tropacocain, the eucains, acoin, nirvanin, alypin, stovain, novocain, quinin and urea hydrochlorid. None of these compounds, with the exception of novocain, now also known as procain, has proved satisfactory for the purpose in view. The classical researches of Braun have established certain facts which are essential to the value of a local anesthetic. These facts concern their relationship to the tissues in regard to their toxicity, irritation, solubility and penetration, and to the toleration of epinephrin.

It is not necessary to enter into a discussion of the pharmacologic action of the drugs usually classified as local anesthetics. Let it suffice to state how the above mentioned drugs fulfil the demands of Braun. Tropacocain is less poisonous, but also less active than cocain, and completely destroys the action of epinephrin; the eucains partially destroy the epinephrin action, and are, comparatively speaking, equally as poisonous as cocain; acoin is irritating to the tissues and more poisonous than cocain; nirvanin possesses little anesthetic value; alypin and stovain are closely related. Both are slightly acid in reaction, produce pain when injected, and occasionally necrosis.

According to Le Brocq, the toxicity of these chemicals may be expressed as follows: if the toxicity of cocain is taken as the standard and expressed as 1, then that of alypin will represent 1.25; nirvanin, 0.714; stovain, 0.625; tropacocain, 0.5; novocain, 0.49; eucain B, 0.414.

Novocain alone fully corresponds to every one of the above claims. Its toxicity is about six times less than cocain; it does not irritate in the slightest degree when injected, consequently no pain is felt from its injection *per se*; it is soluble in its own weight of water; it will combine with epinephrin in any proportion without interfering with the physiologic action of the latter, and it will be absorbed readily by the mucous membrane. The studies of Biberfield and Braun brought to light another extremely interesting fact concerning the novocain-epinephrin combination. Both experimenters, working independently of each other, observed that epinephrin anemia on the one hand, and the novocain anesthesia on the other hand were markedly increased in their total effects upon the tissues. Consequently, a smaller quantity of this most happy combination is required to produce the same therapeutic effect as a large dose of each individual drug would produce when injected separately.

Novocain.—Novocain (procain) is the hydrochloric salt of a synthetically prepared alkaloid, the methyl ester of a p-amino-benzoic acid. It is a white crystalline powder melting at 263° F. (150° C.). It may be heated to 200° F. (120° C.) without decomposition. It dissolves in an equal amount of cold water, the solution having a neutral character; in cold alcohol it dissolves in the proportion of 1 to 30. Caustic alkalies and alkaline carbonates precipitate the free base from the aqueous solution in the form of a colorless oil, which soon solidifies. It is incompatible with the alkalies and alkaline carbonates, with picric acid and the iodids. Its solutions may be sterilized by boiling without decomposition.

As stated above, the relative toxicity of a given quantity of cocain in solution depends upon its concentration; this same peculiarity is not shared by novocain. The dose of novocain may be fixed safely at one-third of a grain for a single injection. For dental purposes a $1\frac{1}{2}$ or 2 per cent. solution in combination with epinephrin has been injected without any ill results. On account of its powerful vasoconstrictor action, the addition of epinephrin in small doses is well suited to the purpose of confining the injected novocain to a given area. It is the important factor which prevents the ready absorption of both drugs, and consequently largely nullifies poisonous results. An injection of 10 drops of a 2 per cent. solution of novocain labially into the tissue produces a diffuse anesthesia lasting approximately twenty minutes; the same quantity, with the addition of one drop of epinephrin

chlorid solution, increases the anesthetic period to over one hour, and localizes the effect upon the injected area.

A suitable solution of novocain for dental purposes may be prepared as follows:

Novocain	10 gr.	(0.60 gm.)
Sodium chlorid	4 gr.	(0.25 gm.)
Distilled water	1 fl. oz.	(30.00 c.c.)
Boil.		

To each cubic centimeter add one drop of epinephrin solution when used.

A sterile solution may be made extemporaneously by dissolving the necessary amount of novocain-epinephrin in tablet form in a given quantity of boiling physiologic salt solution. A suitable tablet may be prepared as follows:

Novocain	$\frac{1}{4}$ gr.	(0.015 gm.)
Suprarenin hydrochlorid	$\frac{1}{1200}$ gr.	(0.000054 gm.)

One tablet dissolved in 20 minims (1 c.c.) of boiling physiologic salt solution makes a $1\frac{1}{2}$ per cent. solution of novocain ready for immediate use.

Solutions for hypodermic purposes should be made fresh when needed. A simple porcelain crucible or a graduated porcelain dissolving cup held by a suitable twisted aluminum tongue and a dropping bottle constitute a simple outfit for this work. The dropping bottle should hold about 4 ounces and should be provided with a dust cap. A groove on one side of the neck of the bottle, and a vent on the other connected with two grooves in the back of the stopper allow the contents to flow drop by drop. A quarter turn of the stopper closes the bottle tightly. The number of drops present in each cubic centimeter differs with the various sizes of the dropping bottle, hence each bottle has to be standardized with a tested minim graduate or a tested burette. The standardized number may be marked on the respective bottles with a carborundum stone.

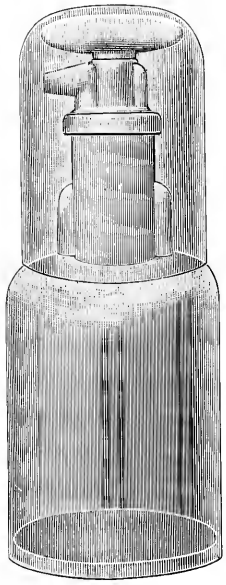

Fig. 409.—Dropping bottle.

Hypodermic Armamentarium.—A hypodermic syringe that answers all dental purposes equally well is an important factor in carrying out the correct technic of the injection. The injection into the dense gum tissue often requires 10 or more pounds of pressure as registered by an interposed dynamometer, while in pressure anesthesia even greater pressure is frequently applied.

The selection of a suitable hypodermic syringe is largely a matter of choice. All-glass syringes, glass-barrel syringes, and all-metal syringes are the usual types found in the market. An all-glass syringe that answers every reasonable demand regarding asepsis, durability, and perfect construction, and that is giving universal satisfaction, has been brought out recently by the S. S. White Dental Manufacturing Company. The syringe is constructed after the well known Luer pattern, holding $1\frac{1}{2}$ c.c. and it is marked with suitable divisions on the barrel. The piston and the barrel are ground so perfectly that no washers are required to make water-tight joints. An adjustable finger rest is easily slipped over the assembled parts which greatly assists in adjusting the needle-opening in any desired direction and in exerting pressure on the piston. The piston-rod, made of solid glass, is sufficiently long to allow about two inches of space between the finger rest and the piston top. This space is of importance, as it allows the last drop of fluid to be expelled under pressure without tiring the fingers. A removable cane-handle, made of metal, greatly facilitates the exertion of pressure on the piston. The needle-adapter carries a universal thread so as to accommodate the hub of the ordinary hypodermic needles. The various parts of the syringe may be detached in a few moments to allow sterilization by boiling.

Glass-barrel syringes are not to be recommended for dental purposes, as they are too troublesome to keep in order. After carefully testing most of the metal hypodermic syringes offered in the markets within the last ten years, by means of the pressure gauge and in clinical work subjecting them to a routine wear, the author has found that the syringes of the so-called "Imperial" type are to be preferred over other makes. They are usually made of nickel-plated brass which, however, is a disadvantage, as the nickel quickly wears off from the piston, and exposes easily corroded brass. The piston should preferably be made of pure German silver. An all-metal syringe as pictured in Fig. 410 gives good results in heavy pressure work and can be recommended. The syringe holds 40 minims (2 c.c.), is provided with a strong finger crossbar, and is extremely simple in construction. The piston consists of a plain metal rod, without a thickened or ground piston-end or packing. The packing consists of leather washers inserted at the screw-joint, and is quickly removed and replaced if necessary.

The hypodermic syringe requires careful attention. It is not necessary to sterilize it by boiling after each use, unless it should be contaminated with blood or pus. The simple repeated washings with a mixture of one part of glycerin and seven parts of alcohol and careful drying are sufficient. The cap should be readjusted, and the piston rod covered with a thin carbolated vaselin or surgical lubricating jelly

and placed in position. If the syringe be boiled, all the washers must be removed. The syringe is best kept in a covered glass or metal case; a large bacteriologic Petri dish is suitable for this purpose. Leather-lined or felt-lined boxes afford breeding places for bacteria, and should

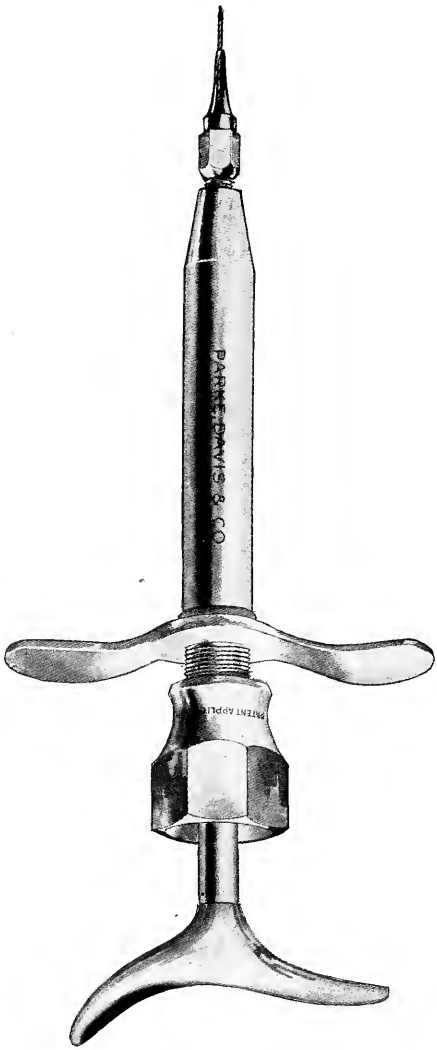

Fig. 410.—Metal syringe.

not be used. Some operators prefer to keep their syringes constantly in the above mentioned glycerin-alcohol solution when not in use, and others prefer to place them in a special sterilizing jar which may now be purchased in the market.

Dental hypodermic needles should be made preferably of seamless steel, or still better, of vanadium steel, 24 to 26 B and S gauge and provided with a short razor edge point. Thicker needles cause unnecessary pain, and thinner needles are liable to break. Iridio-platinum needles are preferred by some operators, as they may be readily sterilized in an open flame. The needle should measure from a half to one inch. For infiltration or conduction anesthesia one and a half-inch



FIG. 411.—Hood's sterilizing jar.

needles are necessary and curved attachments of various shapes are essential in reaching the posterior parts of the mouth. The "Schimmel" needles are excellent, but do not fit every syringe. For pressure anesthesia special needles are required, and may be bought or quickly prepared by grinding off the steel needle at its point of reinforcement. The sterile needle should be kept in well-protected glass containers. The needles are sterilized after each use by boiling in plain water, dried with the hot air syringe, and immediately transferred to a

covered sterile glass dish. The dried sterile needles should not be touched again with the fingers, and the customary wire insertion is unnecessary.

TECHNIC OF THE INJECTION.

Various methods of injecting solution about the teeth are in vogue. For the sake of convenience, we may be permitted to divide them as follows:

1. Terminal anesthesia:
   - Subperiosteal injection.
   - Peridental injection.
2. Conduction anesthesia.
   - Injection at the infra-orbital foramen.
   - Injection at the maxillary tuberosity.
   - Injection at the incisive foramen.
   - Injection at the posterior palatine foramen.
   - Injection at the mandibular foramen.
   - Injection at the mental foramen.
3. Pulp anesthesia.

Before starting any surgical interference in the mouth, the field of operation should be thoroughly cleansed and sterilized by painting with diluted tincture of iodin. A serviceable dilution of the tincture for such purposes is made as follows:

Tincture of iodin (U. S. P.)	½ oz.	(15 c.c.)
Aceton	1 oz.	(30 c.c.)

Keep in glass-stoppered bottles and apply with a cotton swab.

After the diagnosis is made the method of injection best suited for the case in hand is decided upon. The required quantity and concentration of the anesthetic solution is now prepared and the syringe and hypodermic needle fitted ready for the work. The correct position of the syringe in the hand of the operator and its proper manipulation are important factors which are acquired by practice. The hand holding the syringe is governed exclusively in its movement by the wrist, so as to allow delicate and steady movements, and the fingers must be trained to a highly developed sense of touch. The syringe is filled by drawing the solution up into it; it is held perpendicularly, point up, and the piston is pushed upward until the first drop appears at the needle point, which precaution prevents the injection of air into the tissues.

The Subperiosteal Injection.—The subperiosteal injection about the root of an anterior tooth is best started by inserting the needle midway between the gingival margin and the approximate location of the apex.

The pain of the first puncture may be obviated by using a fine, very sharp-pointed needle, by the simple compression of the gum tissue with the finger tip or by holding a pledget of cotton saturated with the prepared anesthetic solution on the gum tissue for a few moments. The needle opening faces the bone, the syringe is held in the right hand at an acute angle with the long axis of the tooth, while the fingers of the left hand hold the lip and cheek out of the way. After puncturing the mucosa, a drop of the liquid is at once deposited in the tissue, and the further injection is painless. Slowly and steadily the needle is forced through the gum tissue and periosteum along the alveolar bone toward the apex of the tooth, depositing the fluid under pressure close to the bone on its upward and return trip. The continuous slow moving of the needle prevents injecting into a vein. A second injection may be made by partially withdrawing the needle from the puncture and swinging the syringe anteriorly or posteriorly, as the case may be, from the first route of the injection. This latter method is especially indicated in injecting the upper molars. After removing the needle, place the finger tip over the puncture and slightly massage the injected area. A circular elevation outlines the injected field. The naturally pink color of the gum will shortly change to an anemic hue, indicating the physiologic action of the epinephrin on the circulation. No wheal should be raised by the fluid, as that would indicate superficial infiltration and consequently failure of the anesthetic.

As the liquid requires a definite length of time to pass through the lamina of bone so as to reach the nerves of the peridental membrane and the pulp, from five to ten minutes should be allowed before the extraction is started. The length of time depends on the density of the surrounding bony structure of the tooth. The progress of the anesthesia may be tested with a fine pointed probe, and its completeness indicates the time when the extraction should be started.

The upper eight anterior teeth usually require a labial and a lingual injection; the molars require both a buccal and a lingual injection. Buccally the injection should be made midway between the mesial and distal root, and on the lingual side over the lingual root.

The lower eight anterior teeth are comparatively easily reached by the injection. The needle is inserted near the apices of the teeth, the syringe is held in a horizontal position, and the injection may be made as previously outlined.

The lower molars require a buccal and a lingual injection. The needle is inserted into the gum margin, midway between the roots and the apices. The external and internal oblique line materially hinders the ready penetration of the injected fluid, and therefore ample time should be allowed for its absorption.

If two or more adjacent teeth are to be removed, the injection by means of infiltrating the area near the gum fold directly over the apices of the teeth is to be preferred. It is advisable to use a one inch needle for this purpose, holding the syringe in a horizontal position, so as to reach a large field with a single injection.

The injection into inflamed tissue, into an abscess, and into phlegmonous infiltration about the teeth is to be avoided. The injection into engorged tissue is very painful; the dilated vessels quickly absorb the anesthetic without producing complete anesthesia, and general poisoning may result. In purulent conditions an injection is decidedly dangerous, as it forces the existing infection beyond the line of demarcation. If the abscess presents a definite outline, the injection should be made into the sound tissue surrounding its focus. If a tooth is affected with acute diffuse or suppurating pericementitis, a distal and a mesial injection usually produce successful anesthesia by blocking the sensory nerve fibers in all directions.

PERIDENTAL ANESTHESIA.

Teeth or roots standing singly, or teeth affected by pyorrhea or similar chronic peridental disturbances, are frequently anesthetized quickly and satisfactorily by injecting the anesthetic solution directly into the peridental membrane. This method is known as peridental anesthesia and its technic is very simple. In single-rooted teeth the short hypodermic needle is inserted under the free margin of the gum, or through the interproximate papilla, into the pericemental membrane between the tooth and the alveolar process. At times the needle may be forced through the thin lamella of bone so as to reach the peridental membrane directly. To gain access to this membrane in teeth set close together, slight separation with an orange-wood stick or other suitable means is often found to be of advantage. Two and sometimes three injections are necessary. To force the liquid into the peridental membrane usually requires a higher pressure than that which is necessary for injecting the periosteum covering the alveolar process, but the quantity of the anesthetic liquid used is less than that which is required for the former injection. Acute inflammatory conditions of the peridental membrane and its sequelæ prohibit the use of this method. Peridental anesthesia is the purest form of local anesthesia, since the seat of the nerve supply of the tooth is very quickly reached, and as a consequence the results obtained are in the majority of cases extremely satisfactory, provided that general conditions justify its application.

Injection at the Infra-orbital Foramen.—To reach the nerve plexus which passes through the infra-orbital foramen and furnishes inner-

vation to the upper incisors and cuspids, an injection is readily made in this region and it is always followed by the desired results. The infra-orbital foramen is easily located about one-quarter inch below the middle of the inferior ridge of the orbit by palpating with the index finger of the left hand. The lip is drawn up with the thumb of the same hand and the one and a half inch needle is inserted into the gum fold between the cuspid and the first bicuspid teeth. Slowly the needle is forced upward along the surface of the bone, injecting a few drops of fluid on its way until the needle point is felt under the ball of the compressing finger resting over the foramen. The syringe is now slowly emptied and withdrawn.

After the injection, slight massage is advantageous in every case. To reach those branches of the anterior superior dental nerve which enter into the body of the maxillary bone, a good sized cotton tampon

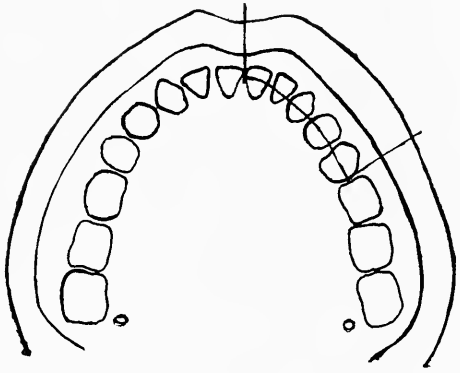

FIG. 412.—Average range of anesthesia after an injection about the infra-orbital foramen.

saturated with a 20 per cent. solution of novocain in distilled water is placed in the lower meatus of the nose and left there during the operation. A few drops of the anesthetic solution injected about the marginal gum tissues of the tooth or teeth under consideration will materially assist in obtaining complete anesthesia.

Injection at the Maxillary Tuberosity.—To reach the posterior superior dental nerves which pass through numerous small foramina at the surface of the tuberosity the syringe mounted with a long needle and held at an acute angle is introduced into the half-opened mouth and inserted high up near the reflection of the mucous membrane within the region of the second molar. The needle, lying close to the bone is pushed slowly backward, upward and inward and simultaneously about 1 to $1\frac{1}{2}$ c.c. of the solution is slowly injected.

In many instances the lower border of the spheno-maxillary fossa is reached which materially assists in the dissemination of the fluid

within the vicinity of the foramen rotundum through which the second division of the fifth nerve passes.

Injection at the Incisive Foramen.—The nasopalatine nerves pass through the foramina of Scarpa (incisive foramen) which are located

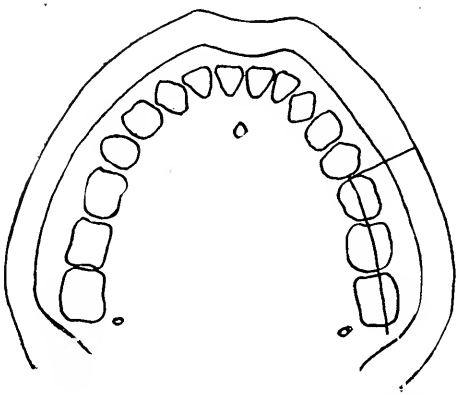

Fig. 413.—Average range of anesthesia after an injection about the posterior dental canal. (Maxillary tuberosity.)

within the suture of the maxillary bones. If an imaginary line passing over the hard palate is drawn from the distal borders of the two cuspids, the line will ordinarily pass through the foramina. If the needle is inserted into the papilla directly back of the two upper central incisors, on its upward course it will pass directly into the foramen. Eight to

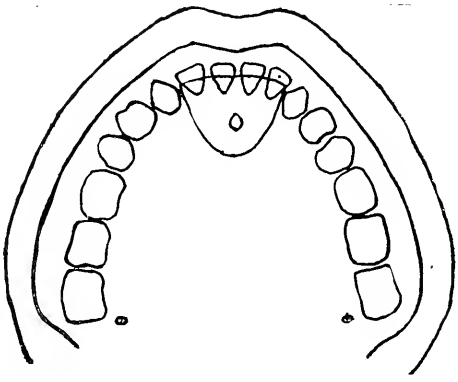

Fig. 414.—Average range of anesthesia after an injection about the incisive foramen.

ten drops of the solution slowly injected are usually followed by intense blanching of the anterior palate.

Injection at the Posterior Palatine Foramen.—The posterior palatine foramen is usually easily recognized by a slight depression in the

mucous membrane about one-half inch above the border of the alveolar process near the last erupted molar. The short needle is inserted in advance of the depression and gently pushed backward and upward; about eight to ten drops of the solution are injected.

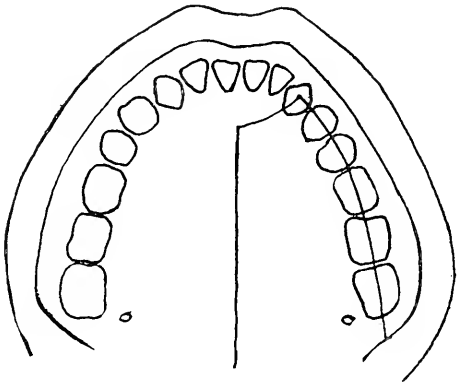

FIG. 415.—Average range of anesthesia after an injection about the posterior palatine foramen.

Injection at the Mandibular Foramen.—The successful anesthetization of the lower molars by the subperiosteal injection is frequently

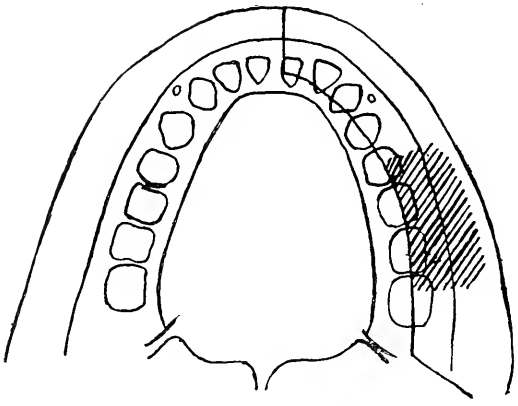

FIG. 416.—Average range of anesthesia after an injection about the mandibular foramen. The shaded area is innervated by fibers of the buccal nerve and requires an additional subperiosteal injection within that region.

fraught with many difficulties on account of the heavy bony ridges on both sides of the teeth, which form strong barriers to the ready penetration of the solution into the bone. To overcome these difficulties Braun, in 1905, introduced a method, originally suggested by Halstead,

in 1885, of centrally anesthetizing the mandibular and, incidentally, in many instances, the lingual nerve near the region of the mandibular foramen.

By palpating the surface of the ramus in the open mouth with the finger, the anterior sharp border of the coronoid process is easily felt about three-quarters of an inch posterior of the third molar. The process passes downward along the side of the last molar, and loses itself in the external oblique line. Mesially from this ridge is to be found a small triangular concave fossa, which faces downward and outward, bounded lingually by the internal oblique line and covered with mucous membrane. As there is no anatomic name attached to this space, Braun has called it the retromolar triangle. Immediately back of the lingual border of this triangle, directly beneath the mucous membrane, lies the lingual nerve, and about three-eighths of an inch farther back the mandibular nerve. This last nerve lies close to the bone, and enters into the mandibular foramen which is located at the lower border of the mandibular sulcus and is partially covered by the mandibular spine or lingula.

Before starting the injection the patient should be cautioned to rest his head quietly on the head-rest of the chair, as any sudden movement or interference with the hand of the operator may be the cause of breaking the needle in the tissues.

The syringe is provided with a one and a half inch needle, held in a horizontal position and placed in the half open mouth across the tongue in the direction of the internal oblique line of the ramus. The needle opening faces the bone. The body of the syringe should rest between the cuspid, lateral incisor, or bicuspid, as the case may be. The thumb or the index finger of the left hand should be employed for palpating the retromolar triangle and the nail edge should be placed directly over the border of the internal oblique line. This point marks the place for the insertion of the needle. The beginner usually selects a point too far mesially. At the moment of inserting the needle, the nail of the finger is withdrawn and the needle strikes the bone directly beneath the mucous membrane about one-half inch above the occluding surface of the last molar. The needle should be slowly advanced along the surface of the bone and at the same time the syringe should be swung gradually toward the other side of the mandible so as to rest upon the occluding surfaces of the teeth. The touch of the bony surface of the ramus which had been lost for a few moments, is again felt and the needle steadily advances in the direction of the mandibular spine. From now on, the touch with the bone must never be lost. About $\frac{1}{2}$ c.c. of the anesthetic solution should be injected on its way to the sulcus and about $1\frac{1}{2}$ c.c. deposited under steady backward

and forward motion of the needle within the region of the mandibular fossa. From fifteen to twenty minutes are usually required for the anesthetization of the mandibular nerve. A slight infiltration of the gum tissue about the teeth to be operated upon insures a painless operation. Injection at the mandibular foramen is possible only when the patient can open the mouth sufficiently to allow the ready introduction of the syringe. If the tissues about the third molar are infiltrated with inflammatory exudates, local anesthesia is absolutely prohibited.

Conduction anesthesia of the mandible is serviceable if a number of teeth are to be removed at one sitting. It should be borne in mind, however, that in general only one-half of either jaw should be anesthetized at one sitting, so as to keep the quantity of the injected anesthetic solution within the limits of ordinary dosage.

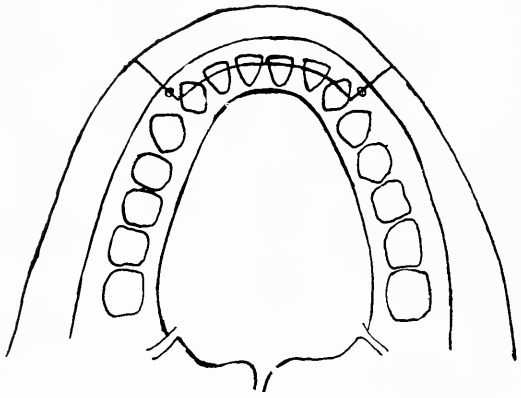

FIG. 417.—Average range of anesthesia after an injection about each of the mental foramina.

Injection at the Mental Foramen.—The mental foramen is usually easily located by exerting slight pressure near the apices of the first and second bicuspids upon the buccal surface of the mandible. The needle should be inserted in this region holding the syringe in a perpendicular position pointing downward. The finger tip should be placed over the foramen to act as a guide to the needle in its slightly forward and downward course. About ten to twelve drops should be injected and slight pressure exerted by the finger which will assist in the passage through the foramen into the mandible.

Pulp Anesthesia.[1]—By pressure anesthesia, pressure cataphoresis, pulp anesthesia, or contact anesthesia, as this process is variously termed, we understand the introduction of an anesthetizing agent in

[1] The omission of a discussion of the use of arsenic for pulp devitalization should not be interpreted to be a condemnation of this drug.

solution by mechanical or electric force through the dentin into the pulp or directly into the exposed pulp for the purpose of rendering this latter organ insensible to pain. Simple hand pressure with the finger or with a suitably shaped instrument, with the hypodermic syringe or with the so-called high pressure syringe, is recommended for such purposes.

Before describing the *modus operandi* of the various methods, the histologic structure of the dentin should be recalled briefly. Dentin is made up of about 72 per cent. inorganic salts, about 10 per cent. water and an organic matrix constituting the remaining per cent. The dentin is traversed by a large number of more or less wave-like tubuli, radiating from the pulp cavity toward the periphery, where they branch off, forming a deltoid network. Roemer has counted about 30,000 dentinal tubuli within the area of a square millimeter. These tubuli are filled with processes of the odontoblasts, known at present as "Tomes" fibers, and they are concerned with the metabolic changes occurring in the dentin. The dentinal fibrils are protoplasmic in their nature and normally do not carry physiologic sensation in the sense we understand this term. We can cut, file, or otherwise injure the sound dentin without much inconvenience to the patient. When the fibers have become highly irritated, a mere touch upon the dentin may at once call forth a paroxysm of pain.

1. *When the Pulp is Exposed or Covered with a Layer of Decalcified Dentin.*—Isolate the tooth with the rubber dam, and clean it with water. Excavate the cavity as much as possible, and, if the pulp is not fully exposed, wipe out the cavity with chloroform to remove fatty deposits from the cartilaginous layer of dentin, and dehydrate with absolute alcohol and warm air. Saturate a small pledget of cotton with a warm concentrated novocain solution in sterile water, carry it into the prepared cavity and cover it with a large pledget of cotton, and then, with a piece of slightly warmed unvulcanized rubber which should completely fill the cavity, and with a broad-faced amalgam plugger or some other suitably shaped instrument, apply slowly, increasing pressure from one to three minutes. The pulp may now be fully exposed and tested. If it is still sensitive, repeat the process. Loeffler states: "This pressure may be applied by taking a short piece of orange wood, fit it into the cavity as prepared, and direct the patient to bite down upon this with increasing force. In this way we can obtain a well-directed regulated force or pressure, and with less discomfort to the patient and the operator." Miller describes his method as follows: "After excavating the cavity as far as convenient and smoothing the borders of it, take an impression in modelling compound, endeavoring to get the margins of the cavity fairly well brought out; put a few threads of cotton into the cavity and saturate them thoroughly with

a 5 to 10 per cent. solution of novocain, cover this with a small bit of rubber dam, and then press the compound impression down upon it. A perfect closure of the margin may thereby be obtained, so that the liquid cannot escape, and one can then exert pressure with the thumb sufficient to press the solution into the dentin." Instead of novocain solution, a so-called novocain "pluglet" may be used. A pluglet is introduced into the cavity, covered with a wisp of cotton dipped in sterile water and the further procedure is precisely the same as described above.

2. *When the Pulp is Covered with a Thick Layer of Healthy Dentin.*— With a very small bibeveled drill bore through the enamel or directly into the exposed dentin at a convenient place, guiding the drill in the direction of the pulp chamber. Blow out the chips, dehydrate with

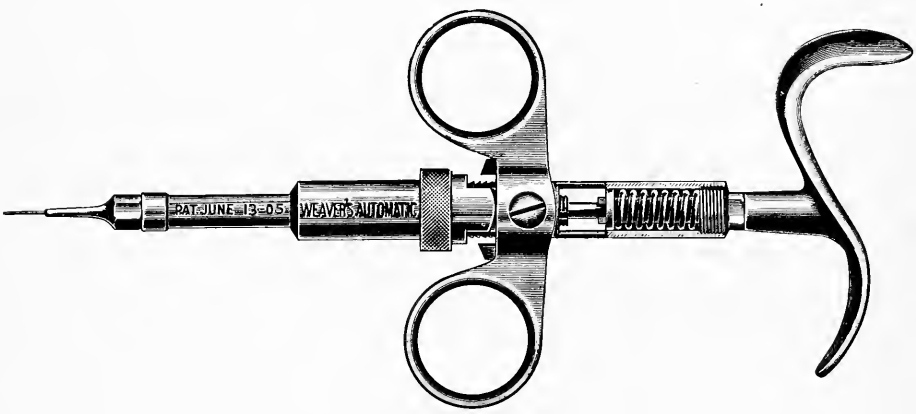

FIG. 418

alcohol and warm air and apply the hypodermic or high pressure syringe, provided with a special needle, making as nearly as possible a water-tight joint. Apply slow, continuous pressure for two or three minutes. With a bur the pulp should now be exposed, and, if still found sensitive, the process should be repeated. As an anesthetic for this purpose a 5 or 10 per cent. solution of novocain in sterile water is recommended. Or a wisp of cotton saturated with the same solution or a moistened novocain pluglet may be placed in the hole, and then covered with an instrument that will just about fit into the opening. Slight pressure should then be exerted.

Within recent years a number of complicated syringes, variously known as high pressure syringes or obtunders, have been advocated. Their mechanism is based upon the conception of forcing anesthetic solutions through sound tooth substance by high pressure. Close

contact of the anesthetic fluid with the dentinal fibers, plus the necessary time for conveying the absorbed anesthetic *via* the Tomes' fibers to the nerve endings in the pulp, explains the phenomenon very plausibly. A strong metal syringe, provided with an especially prepared needle to make as nearly as possible a water-tight joint, is all that is required. Those who prefer a special high pressure syringe for such purposes may purchase any one of the many devices that will suit their fancy. The Weaver obtunder and the Jewett-Willcox syringe are much lauded for such purposes.

Any one of the various methods for anesthetizing a tooth as outlined in the preceding discussion may also be used for anesthetizing the pulp.

In teeth not fully decalcified and in so-called "soft" teeth, pressure anesthesia produces most satisfactory results, while the process fails in teeth of old persons, teeth of inveterate tobacco chewers, worn, abraded, and eroded teeth with extensive secondary calcified deposits, teeth whose pulp canals are obstructed by pulp nodules, teeth with metallic oxids in tubuli, teeth with leaky old fillings, mainly from the same cause, namely, clogged tubuli. In most cases no amount of persistent pressure will prove successful. According to Hertwig the protoplasm of the cell primarily transfers irritation, and secondarily, transmits absorbed materials, and therefore the anesthetic solution has to pass through the entire length of the dentinal fiber before the nerve tissue of the pulp is reached. Consequently a certain period of time is required before the physiologic effect of the anesthetic is manifested, and this period of latency is dependent upon the thickness of the intermediate layer of dentin. The successful anesthetization of the pulp depends largely upon this most important factor of allowing sufficient time for the proper migration of the drug.

Other soluble local anesthetics, such as nervocidin, erythrophlein hydrochlorid, quinin and urea hydrochlorid, etc., have been advised at various times as reliable pulp anesthetics. Owing to numerous drawbacks, these drugs have never obtained popularity. Refrigerant local anesthetics have also been advised for the extirpation of the pulp. The application of this group of anesthetics for such purposes is usually accompanied by many disadvantages which materially limit its usefulness.

Local Anesthesia for Operations about the Mouth, Exclusive of the Extraction of Teeth.—In operating about the mouth for a cyst, a tumor, etc., the rhomboid infiltration of the affected tissue according to Hackenbruch affords the simplest means of producing a most satisfactory anesthesia.

The needle is inserted at (*a*), and at once slow pressure is exerted on the piston, moving the needle steadily along the external line of

the tumor. The needle is now partially withdrawn, without, however, leaving the original puncture, and a second injection or as many as may be needed are made in opposite directions. This maneuver is now repeated at (*b*), and thus a circumscribed infiltration of the whole tumor is obtained. If the tumor, etc., be very large, additional punctures and injections may be made as outlined in the schematic drawing. After waiting ten to fifteen minutes, the extirpation of the tumor may be begun.

The anesthetization of the soft and hard palate is accomplished comparatively easily. The injection on the hard palate is started at the gingival edge of the alveolar periosteum on both sides of the jaw toward the median line. As the gum tissue is extremely dense, great force is required for a complete infiltration in this region, and only small quantities of the solution are required. The soft palate is easily infiltrated by inserting the needle posteriorly to the third molar.

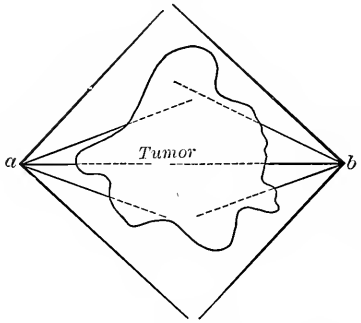

FIG. 419

Small tumors and cysts on the tongue or the floor of the mouth are best anesthetized by the rhomboid infiltration of Hackenbruch. For the complete extirpation of a ranula, the injection is made into the cyst wall near its periphery, after which the cyst is slit open and a small quantity of the anesthetic solution is injected into its inner surface. Large cysts, tumors, and major operations on the tongue require the anesthetization of both lingual nerves. In injecting and operating on the floor of the mouth, the index finger of the left hand should be placed on its external surface as a guide to the needle or the knife.

Local anesthesia is indicated in most minor and, relatively, in many major operations on the mucous surfaces, the skin, and the teeth. Local anesthesia is not a substitute for general anesthesia; its usefulness is materially increased by familiarizing one's self with the methods of its production and with a perfect mastery of its technic. The danger of poisoning has been eliminated by using an isotonic solution contain-

ing a relatively small percentage of the anesthetic in combination with epinephrin. Even if the danger of general narcosis is small under the very best conditions, the danger of local anesthesia is always less. The great majority of all dental operations can be safely carried out under local anesthesia, provided the operator has acquired a complete working knowledge of the various components, which, as a whole, constitute this important branch of dental therapeutics.

CHAPTER XIII.

PYORRHEA ALVEOLARIS.

By RUSSELL W. BUNTING, D.D.Sc.

The term pyorrhea alveolaris, meaning a flow of pus from the alveolus, has been given a very broad application. Strictly speaking, it should be applied only to the pyogenic forms of peridental infection by which the tissues about the teeth are broken down with a resultant formation of pus. But by common usage the term pyorrhea has been loosely applied to all peridental diseases which are related to the gingivæ, including infective, non-infective, purulent and non-purulent types. As a large number, if not the majority, of peridental infections are non-purulent in character, it follows that the term pyorrhea is very often a misnomer for the conditions to which it is applied. An effort therefore has been made to find a more suitable name by which the various peridental affections might be designated. Among other terms which have been suggested, periodontoclasia (*peri* about, *odon* tooth, *klasis* a breaking, literally a breaking about the tooth) has received the widest acceptance. This term for the sake of brevity and euphony may be shortened to dental periclasia of which several types may be differentiated, as suppurative, non-suppurative, gingival, alveolar, etc. Although these terms are in many respects commendable and are the most comprehensive so far suggested, their usage at the present time is very limited. In view of this fact, for the sake of clarity we will use in this discussion the following two terms: gingivitis, which will include all disturbances of the gingivæ in which little or no loss of attachment of the soft tissues to the teeth has been effected, and pyorrhea alveolaris, which will be applied to those forms of peridental disease in which the attachment of the hard and soft tissues has been destroyed an appreciable distance down the side of the root. It will be necessary, therefore, to use the anomalous term non-purulent pyorrhea, but in doing so it must be remembered that pyorrhea refers, in a generic sense, to a general class of peridental diseases.

The history[1] of the development of our knowledge of pyorrhea, like that of dental caries, is an interesting one. Examinations of the skulls of prehistoric man show that even these peoples were afflicted with

[1] The early history of pyorrhea is largely taken from the account by E. C. Kirk in the American System of Operative Dentistry, 1914.

peridental diseases, and early writings make frequent mention of mouth affections which caused the teeth to loosen and fall out. The earliest recorded treatise dealing with the disease is that of Pierre Fauchard in 1728 who described its most prominent clinical features. Following the work of Fauchard, sporadic writings appeared from various sources in which meager descriptions of the symptoms and course of pyorrhea were related. In 1867 E. Magitot made an important contribution to the subject in which he described the disease as a progressive inflammation which destroyed the periosteal membrane and cementum. He thought that these conditions originated deep in the tissues and were not necessarily preceded by gingival irritation or inflammation. He attributed their cause to constitutional changes and associated them with gout, diabetes, albuminuria, and rheumatism.

In 1880 Serran took exception to the views of Magitot, and stated as his opinion that all peridental diseases began in an inflammation of the gingival tissues due to the presence of infection or calculi about the teeth. He believed them to be manifestations of purely local conditions and not necessarily dependent upon general or systemic states. Because of the widely diverging views of these writers and the discussions which grew out of them, the Societé de Chirurgie of Paris appointed a commission of scientists to investigate the matter to determine which of the two theories was the more tenable. In the report[1] which they gave at the conclusion of their study of the problem the commission corroborated the views of Magitot. They stated that peridental diseases did not begin as gingival affections but rather that the primary lesion occurred deep in the pericementum and that the gingivæ were affected only secondarily. They held that the disease was not due therefore to local causes, but was rather a manifestation of constitutional disturbance.

In this country the first important contribution to the subject was made by John W. Riggs of Hartford, Conn., in 1875.[2] He emphatically denied that peridental disease arose from constitutional causes. On the contrary, he claimed that it began as a local inflammation of the gingival tissues which in turn was caused by the irritation of calculi and other accretions upon the teeth contiguous to or beneath the free margin of the gums. His views were based largely upon his practical observations that if in the treatment of pyorrhetic affections the accretions be completely removed from the teeth, the disease is usually arrested and permanently controlled. These views concerning the etiology of peridental diseases and the clinical demonstrations which he made setting forth the manner of their treatment aroused so much

[1] Bulletin et Memoirs de la Soc. de Chir., Tome vi, p. 411.
[2] Pennsylvania Journal of Dental Science, vol. iii, p. 99.

interest that for many years this condition was known as "Rigg's disease."

During the years that have followed, students of these affections have been divided into two classes: one, the localists who believe that the disease is purely a local disturbance arising from causes that are proximate in origin, while the other group might be called the constitutionalists who believe that pyorrhea occurs entirely independent of local conditions and that it is in reality an expression of constitutional disturbance or disease. Among the more important writings on the subject are those of G. V. Black[1] who treats pyorrhea alveolaris as a purely local disease. He considers it to be largely an inflammation and destruction of the peridental membrane by a process which is specific in character. He describes the initial lesion as an invasion of the peridental membrane by certain infectious organisms which penetrate deeply into the tissues along the so-called pericemental glands of Black. The infections which have thus gained entrance to the deeper tissues set up inflammations and degenerative changes which spread to the adjacent alveolar process and cause their destruction.

A somewhat different view was expressed by A. Witzel of Germany[2] who stated that peridental disease begins as an inflammation and caries of the alveolar border. As a result of the bone destruction a deposit of calculus is formed upon the teeth just beneath the free margin of the gum, which in turn constitutes a source of irritation to the gingival tissues producing gingivitis and disturbances in the surrounding tissues. Witzel claims that this process is wholly local and independent of constitutional states, but that it originates in the deeper bony structures about the teeth rather than at the gum margins.

As a result of his close microscopic study of peridental tissues in disease, Zamnesky[3] has given a very clear description of the process by which they are destroyed. He believes that pyorrhea begins as an inflammation of the gum margin destroying first the epithelial lining of the gingival crevice and gradually involving the deeper soft and hard tissues to produce necrotic changes in them. Therefore he considers the process to be a local necrotic disintegration of the alveolar process which begins with gingival inflammation.

Eugene S. Talbot who since 1896 has written voluminously on the subject,[4] takes a middle ground in the discussion. He recognizes the

[1] American System of Dentistry, vol. v, p. 953; Operative Dentistry, G. V. Black, 1908, and Special Dental Pathology, G. V. Black, 1915.

[2] British Journal of Dental Science, vol. xxv, p. 153.

[3] Journal of British Dental Association, vol. xxiii, p. 585.

[4] Talbot: Dental Cosmos, 1896, pp. 310, 660; ibid., 1905, p. 310; 1909, p. 1147; 1915, p. 485. Talbot: Dental Summary, 1903, pp. 435, 538; ibid., 1917, p. 282. Talbot: Dental Items of Interest, 1906, p. 837. Talbot, E. S.: Interstitial Gingivitis, 1899 and 1913.

importance of certain local causative factors such as infection, calculi, etc., but he believes that the most significant factor in the process is a preliminary degeneration of the alveolar process. He points out that because of evolutionary development of man a marked degeneration of the alveolar process has occurred with the result that in the present generation these bones are lightly built and are prone to degenerative changes under any stress or nutritional disturbance. He states that the initial lesion therefore consists in preliminary degeneration of the alveolar bone due to senility, constitutional fault, poisons, etc. If, then, local irritative factors be present, they acting in conjunction with the underlying degenerative changes, may produce the characteristic lesions of the disease. If, on the contrary, oral hygiene has been maintained and no local irritations are present the degeneration of the bone results in an atrophic shrinkage of the soft and hard tissues about the teeth rather than in true pyorrhea.

More recently, however, the great majority of writers and contributors have leaned toward the localist's point of view, giving special emphasis to the part played by the infectious organisms involved. Inasmuch as bacteria and other mouth organisms are present in every case of pyorrhea, it has always been a matter of speculation as to whether these organisms were primarily responsible for the disease or only secondary inhabitants of the lesions. Exhaustive studies of the bacteriology of pyorrhea have been made by various investigators each of whom has searched for some ever-present predominating organism which might prove to be the specific cause of the disease.

W. D. Miller[1] isolated from pyorrheal pockets the Staphylococcus aureus and albus and Streptococcus pyogenes, and described about sixteen other types of organisms which he did not isolate. He stated that pyorrhea is essentially an infective process in which the peridental tissues are destroyed by bacteria. These organisms he found thriving in the lesions in a mixed culture, several different forms usually being present in symbiotic relationship to each other. As he could determine no constant type or group of organisms which was uniformly present in every case, Miller concluded that pyorrhea may be produced by a wide group of organisms in varying combinations and is not caused by any specific type of bacteria.

Vaccine Therapy.—Kenneth Goadby[2] also studied the bacterial flora of pyorrhea and found that S. pyogenes, M. catarrhalis and S. albus and aureus are the most frequent organisms met with in this disease. He claimed he had succeeded in curing cases of pyorrhea by the use of autogenous vaccines made from the organisms present in

[1] Microörganisms of the Human Mouth, 1890, p. 329.
[2] British Medical Journal, 1905, vol. ii, p. 562.

the lesions. In his attempt to control pyorrhea by vaccines he was pioneer in the practice of vaccine therapy for that disease, a method which later came into considerable prominence and which for a time was very widely adopted.

Notable in this connection is the work of L. S. Medalia who, beginning with 1913[1] wrote several extensive articles on the bacteriology of pyorrhea and the treatment of the disease by vaccine therapy. He quotes Zamnesky[2] in support of his opinion that pyorrhea is essentially an affection of the bones and therefore should be known as chronic alveolar osteo-myelitis. He believes that these tissue degenerations are produced by local infections which are variable in character, no one organism being the specific cause. For the control of these infections he recommends the use of autogenous vaccines for the purpose of raising the opsonic index of the body against the particular strains of bacteria which happen to be present in the lesions. By vaccine therapy in conjunction with oral prophylactic measures Medalia claims to have had a high percentage of cures.

As a result of the statements made by Medalia and others regarding the benefits which were to be derived from the use of vaccines in the treatment of pyorrhea, many dental investigators and practitioners made practical application of the measures suggested, the reports of which show a varying degree of success. Very soon those who were most conversant with the disease and who had the widest experience in its treatment lost faith in vaccine therapy and discontinued its use. They arrived at the conclusion that[3] the promiscuous use of vaccines is dangerous, that vaccines when used for pyorrhea are not specific in their action, and that the disease might be successfully controlled by the more simple measures of surgical interference, without which the vaccine would be of no avail.

One of the most serious objections to the use of vaccines for the treatment of pyorrhea is the fact that they are misleading in their symptomatology. It is true that following the injection of autogenous and even stock vaccines a marked improvement of the case is frequently seen. The pus flow may cease and the peridental inflammation may rapidly decrease; so that from superficial observation it might appear that the case were permanently cured. But unless by careful instrumentation all accretions have been removed from the denuded roots and the root-surfaces carefully planed no permanent reattachment of the soft tissues to the root can take place. Many operators, therefore, who depend upon vaccine therapy in the treatment of

[1] Dental Cosmos, 1913, p. 24.
[2] Journal British Dental Association, vol. xxiii, p. 585.
[3] Merritt: Dental Cosmos, 1916, p. 62.

pyorrhea, being deceived by the clinical improvement of the case, fail to perform the necessary operative procedures with the result that the pockets still remain about the teeth to be reinfected at a subsequent time. Vaccines then are but temporary in their action and may be considered only in the light of questionable adjuncts to surgical procedures. Today vaccine therapy in the treatment of pyorrhea has largely fallen into disrepute and is only used in a limited way by a few of its most ardent supporters.

The Ameba Theory.—Perhaps no subject ever caused such widespread interest in the dental world in so short a time as did the announcement of Endameba buccalis as the specific cause of pyorrhea alveolaris by the simultaneous reports of three independent groups of men. In July, 1914, Angelo Chivaro[1] in a paper given before the American Dental Society of Europe in Paris, states that the Endameba buccalis is usually present in the "materia alba" of unclean mouths and is always found in pus from pyorrheal pockets. He advances the opinion that "the endameba has not a pathogenic action; on the contrary, as it feeds on bacteria, it is most probably an aid to autodisinfection of the mouth." It is evident, therefore, that he considered the endameba in the light of a mouth scavenger and not as a cause of pyorrhea.

During the same month M. T. Barrett[2] before the Pennsylvania State Dental Society in Philadelphia gave a preliminary report of the studies which he and A. J. Smith had made of the endameba in pyorrhea. In this and subsequent writings, Barrett and Smith place great stress on the supposed pathogenic action of oral amebæ, characterizing them as the specific cause of pyorrhea, although they admit that bacteria may have a part in the destructive process. Being confident of the validity of their claims they began the administration of emetin, a specific drug for ameba, which they gave in the form of subcutaneous injection, mouth washes, and by stomachic dosage. In the use of this amebacidic treatment, Barrett and Smith and their collaborators claim to have had many remarkable cures of pyorrhea.

In September, 1914, Bass and Johns of New Orleans read a paper[3] on the amebic theory of pyorrhea in which they hastened to publish the results of their investigations, which according to their own statement, had not been pursued more than one month. As the result of this brief consideration they announced as their opinion that amebæ are the specific cause of pyorrhea, that they are not to be found on

[1] Dental Review, 1914, p. 1122.
[2] Dental Cosmos, August, 1914, p. 948.
[3] Dental Summary, December, 1914, p. 994, and Jour. Amer. Med. Assn., February 13, 1915, p. 553.

open surfaces or in healthy mouths, and that the use of amebacides will cure pyorrhea. They later published a book entitled "Alveolo-dental Pyorrhea" in which they considered the various types of the disease as being produced by endameba buccalis.

From the extravagance of the claims made by the American exponents of this theory, a widespread interest was aroused and as a consequence, a wholesale use of emetin in the treatment of pyorrhea followed. At the same time careful studies of the theory were made by dental scientists and practitioners who sought to know the truth about the matter. Notable among these are the investigations of Price and Bensing[1] who describe the various types of amebæ which inhabit the mouth. They found, as did Chivaro, that the amebæ ingested bacteria, from which fact they inferred that these protozoa were beneficial to the tissues rather than harmful to them. Hartzell[2] made practical and clinical studies of the effect of emetin on cases of pyorrhea, the results of which convinced him that such medication was of doubtful value, and that proper surgical and prophylactic means would effect a cure without the aid of emetin. The views of Hartzell were corroborated by practically all practitioners who treated pyorrhea intensively. The great mass of evidence and opinion which was given out by those who studied the subject was largely contradictory to the theory while very little corroboratory evidence could be found. Cases in which emetin was used seemed to show a temporary improvement, but, as in the use of vaccines, the operator almost invariably relied so much upon the beneficial effects of the drug that he failed to perform properly the necessary operative and prophylactic measures. As a result, healing of the pockets was not attained and a relapse occurred within a very short time. Consequently the interest which was aroused by the amebic theory of pyorrhea and the use of emetin in its treatment was short lived, dying out almost as rapidly as it arose, and the treatment of pyorrhea by means of emetin is no longer practiced except by a very few enthusiasts.

Succinamide of Mercury.—During the year 1915 and later, the dental corps of the Navy reported the successful treatment of pyorrhea by deep muscular injections of succinamide of mercury. G. H. Reed,[3] Wright,[4] and White,[5] acting upon the supposition that mercury produces antibodies in the blood and thereby retards the action of parasites, made use of that drug in the form of a succinamide to control the growth of the microörganisms in pyorrhea. From its use they claimed

[1] Journal National Dental Association, 1915, p. 143.
[2] Emetin *vs.* Surgery, Hartzell, Journal Allied Dental Society, 1916, p. 7.
[3] Items of Interest, April, 1915, p. 241.
[4] Dental Cosmos, 1915, p. 1003, and the Journal Allied Dental Society, 1916, p. 305.
[5] Dental Cosmos, 1915, p. 405.

they had obtained pronounced beneficial results in which the pus ceased to flow from the pockets within twenty-four hours after the injection, the inflammation of the tissues subsided and a disappearance of the pyorrheal lesions ensued. It was suggested by them that this method be used in conjunction with careful operative procedures, but beneficial results were noted even when no instrumentation was performed. It is the opinion of Wright that the mercury has a two-fold parasitrophic action: first, the mercury unites directly with the organisms, that is, it forms a chemical combination with the bacterial proteins; and, second, the mercury stimulates in the tissues the formation of a specific antibody against the organisms of pyorrhea. In the treatments which they gave four or five doses of succinamide of mercury were administered one week apart, beginning with $\frac{6}{5}$ grain and reducing $\frac{1}{5}$ each week. The injections were made deep in the gluteal muscles alternating each week between the two sides of the buttocks. Only scanty reference has been made to this treatment in the literature, from which we infer that the method has not received any wide acceptance or adoption. There are good reasons to believe that in certain types of cases the administration of the drug in conjunction with careful operative and prophylactic procedures may be of benefit in controlling the infection. This is especially true when the organism present is of a virulent and persistent type which the surrounding tissues are not able to successfully combat. This form of treatment is, however, open to the same criticism as are vaccines and emetin in that when used to combat pyorrhea it affords a sense of false security by which many operators will be led to neglect or incompletely perform the necessary surgical procedures without which no drug or medicament can effect a cure of the disease.

More Recent Views of the Cause of Pyorrhea Alveolaris.—In addition to the amebic theory several hypotheses have been advanced as to the specificity of one or another type of mouth organism to produce pyorrhea. Of these the opinions of Noguchi, Kritchevsky and Seguin, and Hartzell are the most notable. Each of these investigators looks upon pyorrhea as a local infective process in which the peridental tissues are destroyed by a specific type of organism which they believe is responsible for the disease.

H. Noguchi,[1] of the Rockefeller Institute of Medical Research, isolated from pyorrheal pockets and grew in pure culture a new species of spirocheta which he has called the Treponema mucosum. This organism which is smaller than the Vincentini spirillum has regular convolutions similar to the organism of syphilis. They do not grow

[1] Treponema Mucosum, Journal of Experimental Medicine, 1912, xvi, 103.

on healthy tissues but thrive only on such as have been injured or impaired in their nutrition. They are purulent in type and occasionally stimulate a mucinous secretion. Noguchi recognizes the presence of streptococcus, staphylococcus and pneumococcus groups, of organisms in peridental disease, but he believes that the Spirocheta mucosum, together with the Spirocheta microdentinum, and the Vincentini spirillum, with the fusiform bacillus, constitute a class of organisms which are directly responsible for the disease.

In 1918, Kritchevsky and Seguin[1] of the Pasteur Institute reviewed the work of Noguchi on Spirochetæ and that of Wright, Kolle, and others who claimed to have successfully treated pyorrhea by arsenical and mercurial preparations which have a specific action against spirochetæ. The authors then reported a large series of pyorrhetic cases which they had treated by intravenous injection and by local application of salvarsan and neosalvarsan. They claimed that in this manner they had obtained very beneficial results consisting of a rapid disappearance of the spirochetæ from the pyorrheal pockets, and a remarkable improvement in the clinical appearance of the cases. They stated, however, that *this treatment alone gives but a temporary relief and that for a permanent cure it is necessary that a most careful scaling and polishing of the roots be performed and a thorough and unrelenting course of oral hygiene be established.*

In a discussion of the cause of pyorrhea, Hartzell in August, 1918,[2] stated emphatically as his belief that it was the streptococcal group of organisms which produced the initial lesion of the disease. As a result of the extensive investigation which he has made of this type of infection during the past five years, he believes that streptococci are necessary to true pyorrhea, and that they are the first to penetrate the tissue and create the initial lesion, thus preparing the way for the staphylococci and other purulent types of organisms which in turn dissolve the peridental tissues and create the pocket. He emphatically states that the streptococcal, staphylococcal, and pneumococcal group are the only organisms of any importance in pyorrhea, and of these the streptococci are the specific instigators of the process. For the control of these infections and the cure of the disease *he depends solely upon the thorough application of surgical and hygienic measures.*

It will be noted that practically all American students of pyorrhea consider it to be a local disease arising largely from local irritations and infections, with the exception of Talbot, who takes a middle ground, believing that both local and constitutional causes are involved. The

[1] La Presse Médicale, Paris, May 13, 1918, and the Dental Cosmos, September, 1918, p. 781.

[2] Items of Interest, January, 1919, p. 45.

majority of European students, however, have taken the opposite view of the question and regard pyorrhea as an expression of systemic disease. Their opinions were very clearly summed up by Maurice Roys[1] of Paris in a paper which he gave in London at the Sixth International Dental Congress in 1914. He reviewed the writings of Magitot, Galippe Julien Tellier, Mendell Joseph, Hopewell-Smith, Talbot and others, all of whom placed considerable stress on the early degenerative changes in the alveolar bone in cases of true pyorrhea. Roys then attempts to rule out all other causes of pyorrhea by a process of exclusion and formulates a theory in which he places the greatest emphasis on an initial degeneration of the bone due to what he terms, "precocious senility." He believes that local trauma and infection enter into the process of peridental destruction but considers them to be adjuvant causes and secondary to degenerations in the alveolar bone which are general and systemic in their origin. He asserts that local irritation, such as mechanical stress, infection and faulty oral hygiene, when acting alone, produce gingivitis but not pyorrhea unless a precocious senile degeneration of the alveolar border has taken place. In this manner he explains those cases in which the oral hygiene is poor and the gingivæ are inflamed but no pyorrhea is present. On the other hand, he believes that senile degenerations of the alveolar bone without local irritations produce only an atrophy of the peridental tissues, and *if a rigid oral hygiene be maintained no pyorrheal pockets will be formed.* This contribution of Roys is an excellent exposition of the constitutionalist's conception of pyorrhea and should be carefully studied by all those who are interested in the subject.

In all of the foregoing the reader will have seen that there are many phases of the problem of pyorrhea alveolaris which at the present time are not fully understood. The variance of opinions which have been expressed has caused considerable confusion in the minds of many as to the nature of the process and the basic principles which are involved, so that it stands today as the least widely understood and most neglected of all dental diseases. Having reviewed the various theories and opinions which have been suggested as to the cause and course of pyorrhea alveolaris, we will now consider the known facts regarding the process and point out definitely established principles relative to the practical control of the disease, irrespective of the theories and speculations which have been advanced thereto.

The Significance of Local Operative Procedures.—During all of the years in which the controversy regarding the cause and nature of pyorrhea has been carried on, a certain group of operators has been

[1] Dental Cosmos, August, 1918, p. 659.

successfully treating and controlling pyorrhea by local operative procedures. New theories came and went but these pyorrhea workers continued in the even tenor of their ways to cleanse surgically the affected root-surfaces, to remove all irritants, and to establish permanent mouth cleanliness, as a result of which an arrest of the destructive process and a subsequent healing of the lesions was secured in a large percentage of cases. So beneficial have been the results obtained by those operators who have become proficient in this form of treatment that there is no longer any room for doubt as to the efficacy of these measures to control many forms of pyorrhea. If constitutional factors are involved in their cases, these operators have considered them only in a general way, bending their greatest efforts toward the perfection of a careful technic of root-surgery and the establishment of thorough mouth cleanliness. In a great majority of cases in which the destructive process has not advanced too far an arrest of the disease is effected and a healing of the lesion is brought about while in beginning cases, practically without exception, the pyorrheal tendency is checked and the progress of the disease permanently prevented by local prophylactic measures and by the establishment of oral hygiene. By reason of the success which was obtained by these local procedures, many have been led to believe that pyorrhea is wholly a local disease and is entirely independent of systemic conditions. Even those who believe in the constitutional origin of pyorrhea admit that local measures, if thoroughly performed, are largely effective in checking the disease, and indeed there are few who have made a close study of the problem and have impartially adjudged the results of these operators who do not agree as to the efficacy of this method of treatment. The question then arises as to how the conception of pyorrhea as an expression of systemic or constitutional disease may be reconciled with the fact that it is amenable to local treatment. For a better understanding of this phase of the subject it will be necessary to consider more in detail the causes and course of pyorrhea alveolaris.

General Principles of Pyorrhea.—Pyorrhea alveolaris is a disease of the oral cavity which is confined to the tissues immediately surrounding the teeth and is characterized by infections, inflammatory changes and a progressive destruction of the attachment of the supporting tissues about the teeth. These degenerations consist in a disintegration of the pericemental membrane and a scission of its fibers beginning at the gingival crevice and proceeding apically along the root of the tooth. Concurrently, degenerative changes take place in the contiguous bony structures of the alveolar process by which they undergo molecular disintegration or metaplasia to fibrous tissue. As a result of these two degenerative processes a characteristic lesion or pocket is

formed along the lateral surface of the root and is progressively deepened as the disease advances. When the supporting structures have been sufficiently destroyed the tooth becomes loose and eventually is lost.

This destructive process is not constant or uniform but varies quite widely in its course and the pathologic picture which it presents. In some instances severe inflammation is set up with the production of an active flow of pus while in others the inflammatory reactions are slight and no pus is evident. Certain cases are associated with calculus formation both external and subgingival, while others are devoid of calcareous deposits. Pyorrhea, therefore, is not a definite or specific disease but rather is a variable complex of symptoms expressive of a combination of local and general factors which enter into the process. Of these a wide variety of local irritative and infective factors may be recognized which exercise an evident causal relationship to the disease. These local disturbances are augmented by many general constitutional states which predispose the tissues toward pyorrheal affections. The course of each case is determined by the particular type of local or general factor which is most prominent as a causative agent and the quality of the local tissue reactions. It is, therefore, possible to recognize certain definite forms of pyorrhea and to catalogue the various types according to the specific causative agents which are present and the type of tissue reactions to them. For a clear understanding of this complex disease, concerning which there is so much uncertainty and confusion, it is necessary that we learn to analyze each case by reasoning from cause to effect, that we search for all possible causes both local and systemic, and that we study and evaluate the type of bodily resistance as it is expressed in local tissue reactions. In this manner the course and clinical pictures of a large majority of these cases may be made clear to us so that we may truly appreciate the nature of the pathologic process which has taken place and determine the manner in which it may be checked.

In the study of pyorrhea alveolaris it is necessary that we consider the structure and peculiar qualities of the tissues which are involved by the disease. The tissues are those which immediately surround the teeth, namely, the alveolar bone, the peridental membrane and the overlying gum tissues (see Fig. 88). The alveolar process which affords support to the teeth and the soft tissues consists of cancellous bone, except on the periphery and the walls of the alveoli, where it is condensed and cribriform in type. Normally this alveolar bone surrounds the roots of the teeth nearly to the gingival line and in the interproximate region it projects crownward in a tapering wedge to support the

interproximate gingivæ. The peridental membrane lines the walls of each alveolus and by its dense white fibrous tissue gives firm attachment between the tooth and the surrounding bone. The peridental fibers also extend upward into the free margin of the gum on all sides of the tooth and by the pull which they exert upon these tissues they serve to draw them tightly about the neck of each tooth. The peridental membrane possesses a rich and free blood supply which is derived from vessels which enter the tissue from three sources, namely, at the apex from vessels which enter the pulp, on the lateral surfaces of the root from vessels which enter the membrane through the walls of the alveoli, and in the cervical region from the periosteal circulation. The vessels of the peridental circulation are arranged for the most part parallel with the long axis of the tooth and are accompanied by a system of lymphatics[1] which take the same general direction. Overlying the bony structure there is first a periosteal covering upon which is superimposed a dense connective tissue submucosa and a highly specialized stratified pavement epithelium, the mucous membrane. These mucous and submucous tissues are firmly attached to the bone by fibers of the periosteum and to the teeth by the fibers of the peridental membrane. Unlike the deeper structures the gingival tissues are supplied by bloodvessels which have no collateral communication, being endarterial in type.

Normally these tissues are highly resistant to infection and to traumatic injuries incident to the mastication of hard foods. In health, the overlying tissues are hard and firm and are not easily ruptured or torn from their positions. And when they have been injured the oral tissues show a remarkable recuperative power by which healing of even severe wounds is rapidly accomplished when the injury is not of long duration. But, on the other hand, injuries which are continued for a considerable space of time even though they be of low potential and seemingly insignificant may induce profound degenerative changes in these tissues and a lowering of normal resistive power. These low grade chronic irritations set up circulatory changes in the gingival tissues, namely, active and passive hyperemia which, because of the fact that these tissues possess little or no collateral circulation usually terminate in passive congestion and stasis. The vessels become engorged with stagnant or slowly moving blood, the tissues swell and are infiltrated with inflammatory exudates producing a marked disturbance of the overlying tissues which condition we designate as gingivitis. These circulatory disturbances vary according to the severity of the irritant

[1] Noyes and Dewey: The Lymphatics of the Dental Region, Jour. Am. Med. Assn., 1918, p. 179.

and the type of tissue reaction to them. In one individual a given local irritant will give rise to a profound inflammatory reaction and hypertrophy of the gingival tissues, while in another, in response to the same irritant the peridental tissues will degenerate rapidly because of the fact that the local protective reactions are weak.

If the tissue reactions are sufficiently active, severe inflammations of the gingivæ may continue for some time without any serious affection of the deeper tissues or disturbance of their attachment to the roots of the teeth. Gingival inflammation may exist, therefore, for years under these conditions without the production of true pyorrhea. But when the resistive powers of the tissues are not of good order or when a particularly virulent type of organism becomes implanted in a gingival crevice, especially when the gingival circulation has been disturbed by local irritation or by systemic fault, degenerations of the deeper tissues take place. The first step in this process consists in a metaplasia of the bony alveolar border about the tooth and a dissolution of the peridental fibers. The bony trabeculæ undergo halesteresis osseum by which they are decalcified and changed to fibrous tissue. At the same time the peridental fibers are progressively severed and a subgingival space or pocket is formed which is open to the gingival crevice, being bounded on one side by the root of the tooth and on the other by the inflamed and degenerating gingival, subgingival and alveolar tissues.

In this pyorrheal pocket various infectious and pathogenic organisms live and thrive, exerting their characteristic action upon the surrounding tissues, against which the tissues in turn seek to protect themselves. As in the case of periapical infection the type of protective reaction depends upon the type of organism which predominates in the lesion. When the infection is an actively purulent type, the reactions against the ı are acute and highly inflammatory. By a profuse diapedesis of leukocytes and lymphocytes a wall is built about the lesion which later becomes organized into a permanent granulation tissue similar to that of an abscess. It then virtually becomes, first an acute and later, a chronic abscess which may persist in *statu quo* for months or years. After the manner of an abscess, the organisms continually break down tissue, blood, and lymph cells with the production of pus, while the granulations about, either partially or completely replace the lost tissues by bringing in new blood and lymph cells and fibroblasts. When the condition becomes chronic there is a tendency on the part of the surrounding tissues to wall off the infectious process by the formation of a fibrous tissue capsule as in chronic abscesses. This is the purulent type of pyorrhea alveolaris.

But when the predominating organism is non-purulent in character like the streptococcus-pneumococcus group, a somewhat different

picture is presented. Against these organisms the tissue reactions are of low order and less protective than the former type. As a rule, the overlying gingival tissues are not highly inflamed or hypertrophied, and frequently show little pathologic change other than a slight retraction. Consequently, these may easily be overlooked, especially in their early stages. The deeper tissues undergo a mild form of

FIG. 420.—Pyorrhea, hypertrophic type; swelling of gum tissues; strong tissue reactions.

degeneration and are replaced by a fibrous tissue of new order. Deep peridental lesions are formed in which there is little or no pus, and in the adjacent tissues many lymphocytes and plasma cells are massed in an unorganized state. This form of pyorrhea corresponds in type, therefore, to the periapical granulomata, in which the infectious

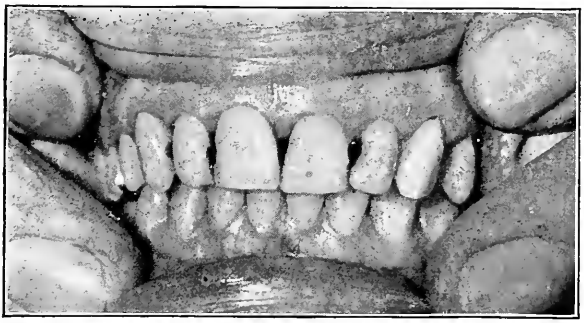

FIG. 421.—Pyorrhea, passive type; deep pockets about practically all teeth but no outward signs present. No swelling; gums nearly normal in color; no inflammatory reaction.

organisms tend to penetrate the tissues and produce in them proliferative degenerations. It is undoubtedly in these non-purulent types of peridental infection that the danger of metastatic focal infection is the greatest.

The characteristic action of the different types of infection and the varying local and general reactions to them are reflected in the clinical

appearances of pyorrhea which are presented. In case the reactions are of a good order, the tissue changes are clearly evident, often livid in appearance, and are readily recognized (Fig. 420). While in other cases, either because of the presence of a streptococcal organism of low virulence or a low state of general bodily activity the tissue reactions are mild, the clinical disturbances are slight and little evidence of the process is given other than a hidden and obscure pyorrheal pocket (Fig. 421). It follows that cases of pyorrhea in which the most dangerous types of infection are involved and the most severe tissue destruction is accomplished often escape clinical observation and no effort is made to check them. In every clinical examination, careful search should be made for the characteristic pyorrheal pocket and only when it is determined that the gingivæ are firmly attached about each tooth and that no sub-gingival pockets have been formed may it safely be said that pyorrhea does not exist.

Causes of Pyorrhea Alveolaris.—In a consideration of the causes of pyorrhea, it is very essential that we keep clearly in mind that the seat of the primary lesion is unquestionably located in the investing tissues about the teeth, which, in the course of the disease, are progressively destroyed or changed in their character. Irrespective of all the conflicting theories which have been held thereto, it must be admitted that as long as the normal attachment of the gingival tissue remains intact about the teeth, there can be no characteristic lesion of pyorrhea. It is only by the breaking of this close union of gingival tissue to the neck of the tooth, that a pyorrheal pocket may be effected. If, therefore, these gingival tissues could be kept in health and normal relationship to the teeth which they surround, true pyorrhea would not occur.

Inasmuch as the perfection of the attachment of the gingival tissues to the tooth and their resistance to infectious organisms depends upon the healthy tone or pull of the peridental fibers which support them, it follows that, whenever disturbances occur in the gingival circulation, either from local or constitutional causes, the tissues suffer from malnutrition, the tone of the fibers is lowered and the gingival tissues fall away from the neck of the tooth. Thus, by reason of local circulatory disturbances, the gingival crevice becomes widened and patent, affording an easy access by which the oral microörganisms may invade and attack the deeper tissues. Following the initial invasion, the future course of the infectious process depends upon the type of local tissue reactions which oppose it. In one case active hyperemia will be set up which may effectually protect the deeper tissues from invasion, and confine the infection to the superficial tissues, while in another case when the tissue reactions are not of good order a similar injury may give rise to a rapid degeneration

and deep infection of the underlying peridental tissues. Because of the complex nature of this process it is often difficult to determine whether the various types of local disturbances to the peridental circulation act as primary and exciting causes of the disease or merely predispose to it by preparing the way for some other factor. But clinical observation has definitely determined that when in the treatment of these disturbances all local irritants have been completely removed and the normal peridental circulation has been reëstablished, the course of the disease is checked, and in the majority of cases is permanently arrested. In the treatment of these conditions by local operative measures the relationship between cause and effect, namely, the local irritants and the peridental disturbance, is so evident that we are led to view the local disturbances of circulation as highly important factors in the inception of pyorrhea. The causes of these disturbances may be enumerated as follows:

Local Causes—*Trauma of Foods.*—The oral tissues are constantly subjected to various forms of traumatic injury. A certain amount of friction and buffeting of the teeth and surrounding tissues by the mastication of hard foods seems to be beneficial to them, as it assists in cleaning the mouth and stimulates the peridental circulation. But when excessive and repeated pressures are brought to bear upon the hard or soft tissues of the mouth, irritation and circulatory disturbances are set up which result either in a hypertrophy or a degeneration of the tissues depending upon the type of their reaction to the injury. Traumata frequently occur in interproximate spaces, when the normal contact has been lost and food is crowded upon the interproximate gum septa during mastication. An example of the hypertrophic type may be seen in Fig. 422 in which the interproximate gum is swollen as a result of the crowding of food between the teeth. In Fig. 423 a similar case is shown in which the gum tissue has been destroyed and deep pyorrheal pockets have been formed along the roots of the adjacent teeth.

A single pyorrheal pocket may be established on the labial, buccal, or lingual surface of a tooth as the result of injury by the excessive excursions of food against it when the corresponding enamel surface is flat or lacks normal contour. As has been pointed out (see p. 165) these flat tooth surfaces usually result in a simple retraction of the gum contour at that point, but it not infrequently occurs that a specific rupture is made in the tissues and by subsequent infection a deep pyorrheal lesion is effected (Fig. 424).

Operative Traumata.—In the performance of various operative procedures the gum tissues are frequently injured. As a rule, wounds of the mucous membrane heal readily, but when the resistance is low

infectious organisms may become implanted on the site of such injuries to form a deeper lesion. For example, cutting of the gingival tissues by saws, files, ligatures, bands, etc., may be followed by an infection of the wound leading to the establishment of a pyorrheal lesion. Gold shell crowns which are poorly fitted to the roots and extend down deep

FIG. 422.—Interproximate trauma of food between molar and bicuspid, producing hypertrophy of gum tissues.[1]

FIG. 423.—Interproximate trauma of food between molars, producing shrinkage of tissue and loss of gum septum.[1]

into the pericementum, overhanging proximate fillings and ill-fitting clasps on dentures are common offenders of this type. These injuries set up circulatory disturbances in the surrounding tissues by the irritations which they produce and if the protective reactions are not of high order, infection and tissue destruction will ensue.

FIG. 424.—Retraction of gingivæ on labial surface of upper and lower left centrals resulting from traumata of food excursions over teeth having no labial contour. Upper right central is a porcelain crown having a prominent labial contour which has effectually protected the gum tissues about it.

Traumatic Occlusion.—Pyorrheal lesions may be established about one or more teeth as the result of excessive or abnormal occlusion. Not every case of mal-occlusion will produce such lesions, but in cases in which the general health and metabolism are of low order, the irritation of excessive occlusion frequently acts as a predisposing cause of peridental infection. In the treatment of all cases of pyorrhea it

[1] Whinney, M. A.: Dental Review, 1907, p. 611.

has been found necessary, therefore, to correct, as far as is possible, all faults of occlusion for the reason that they act as a contributory cause of irritation which must be corrected before healing of the lesion may be effected (see p. 168).

Trauma of Calculi.—It is a matter of common observation that the great majority of cases of pyorrhea are associated with a deposition of calculi on the teeth. Considerable speculation has been made as to the part which these deposits play in the process. It is not clear whether they are active exciting causes of the peridental disturbance or are secondary depositions laid down as a result of the tissue degeneration. Certain it is that they do act as important factors in the process whenever they are present. If they impinge upon the soft tissue, either externally or beneath the gum margin, they will produce injury to them as the teeth move in mastication. By the rough surface which they present they interfere with the cleansing of the mouth and tend to harbor food and infectious materials about the teeth. They are actively irritant in the peridental tissues and constitute a contributory factor to peridental disease.

FIG. 425. — Subgingival calculus formed artificially on root imbedded in modeling compound with a pocket-like crevice about. Labial portion of modeling compound broken away to show calculi.

Several different varieties of calculi may be distinguished, which have been divided by the majority of writers into two classes, salivary and serumal or sanguinary. It is not clear where the dividing line between these two varieties of calculi may be placed since all pyorrheal pockets are more or less open to the saliva and there is always a possibility that even deposits which are formed deep down on the lateral surface of the roots may be salivary in origin. This we have shown experimentally to be possible[1] by producing outside of the mouth deep calculi on teeth which were covered with modeling compound to simulate the gums leaving narrow crevices along the lateral surfaces of the roots to form deep pockets. When immersed for several weeks in a solution of calcium salts, the concretions shown in Fig. 425 were produced.

Calculi vary in color, form, hardness, brittleness and the rapidity with which they are built. Accumulations on the surface of the teeth occur most frequently on the buccal surfaces of upper molars and bicuspids opposite the opening of Stenson's duct and on the lingual

[1] Bunting and Rickert: Journal National Dental Association, August, 1915, p. 256.

surfaces of the lower incisors. These deposits are self-evident and easily recognized but those which are formed beneath the gum are not so easily discovered. The subgingival types consist of small granules, plates or scale-like rings (Fig. 90) which may encircle the necks of the teeth or extend along the lateral surface of the root in a deep pyorrheal pocket. They are frequently hidden from view and offer considerable difficulty in removal (Fig. 426).

Fig. 426.—Pyorrhea with heavy subgingival calculus about roots of all teeth.

Nature and Origin of Calculi.—The salivary calculi on analysis are found to be composed of masses of calcium phosphate and carbonate built upon a mucinous or colloidal matrix and arranged in concentric layers about a central nidus. The findings of Rainey and Ord[1] relative to the origin of biliary and urinary calculi have shed considerable light on the method by which salivary calculi are formed. They found that in a medium containing colloid, earthy salts were precipitated in spheroidal masses which in time coalesced to form large concretions. They proved that urinary and biliary calculi are formed by the precipitation of urinary and biliary salts in colloidal materials as mucin, albumin, etc. In the same manner the formation of salivary calculi may be explained as a precipitation of calcium salts from the saliva in the mucin and colloids present in the mouth. It has been observed[2] that the first step in the formation of calculi consisted in the deposition upon the teeth of calco-globulin in the form of a flaky white precipitate. This deposit when first laid down is soft and viscous, insoluble in water but may be removed easily by the brush or finger. In time it becomes hard and brittle and takes on the general characteristics of dental calculi. A copious flow of this calco-globulin follows the ingestion of a full meal of highly nutritious foods and is also more abundant during

[1] On the Influence of Colloids upon Crystalline Forms and Cohesion, London, 1879.

[2] Black, G. V.: Dental Review, 1912, p. 337, and in his Special Dental Pathology. 1915.

illness. The statement has also been made[1] that salivary calculi are formed as the result of fermentation processes in the oral cavity giving rise to acids, notably lactic acid. The acid thus formed supposedly precipitates the mucin from the saliva which in turn drags down the phosphates and carbonates of calcium to form a mass upon the teeth which in time hardens to form calculi.

It is evident that calculi when first laid down are soft and mucinous in character, in which form they may be removed easily by the tooth brush and other mechanical measures. Later they become hard and firmly attached to the surface of the teeth from which they may only be dislodged by considerable force. The rate of tartar formation in the mouth is not dependent upon the amount of calcium in the saliva, for we have found that the calcium content of the saliva is no higher in individuals who have considerable dental calculus than in those who have little. The process seems to be dependent upon the amount of mucinous and colloidal matter in the saliva which when deposited upon the teeth constitutes a matrix in which inorganic salts from the saliva and possibly the blood are precipitated. The control of calculus formation therefore may be accomplished by the limitation of calcoglobulin in the salivary secretion by regulation of the diet and by the removal of the deposits from the teeth daily while they are soft, at which time their removal may be accomplished readily by the tooth brush and dental floss. Furthermore, it is a common observation that when a mouth is put under a strict regime of oral prophylaxis by which oral fermentations are largely decreased, the tendency to form calculi is greatly diminished.

Bacteria.—As we have related in the section on History, every pyorrhetic lesion is infested with a variety of microörganisms of which the most common forms are streptococci, staphylococci, B. fusiformis, spirochete, and types of amebæ. These organisms doubtless play an active part in tissue destruction and in the formation of the characteristic lesions of the disease. It is usual, however, that upon close study of the case some other predisposing cause, either local or general, may be found which prepared the way for the bacterial invasion and without which the infection would not have occurred. But occasionally a case is presented in which no predisposing cause is apparent; no calculi or other traumata are present and no constitutional fault is evident. In them the active causative factor is a particularly virulent type of organism which seemingly has the ability to penetrate the peridental tissues unaided by any other factor. Beginning cases of this type may be seen in mouths that are comparatively clean and

[1] Burchard, H. H.: Dental Cosmos, 1895, p. 821, and 1898, p. 1. Also E. C. Kirk and others.

hygienic, their only fault being a narrow plaque of bacterial growth about the cervix of each tooth (Fig. 427). As a result of this growth a marked gingivitis is seen about all the teeth (Fig. 428), which disappears after careful and thorough prophylactic measures have been performed.

FIG. 427.—Location of bacterial plaque with disclosing solution. Highly infective organisms present producing gingivitis.

These cases are relatively rare and are seemingly due to the presence of a highly infective type of organism, although it is possible that if our clinical vision were keen enough we might discover some predisposing and determining factor which inaugurates the process other than the microörganisms.

FIG. 428.—Severe gingivitis, infective type, no calculus being present.

Cigarette Smoking.—We have observed a limited number of cases of pyorrhea in which the lesions were confined to the labial surface of the upper anterior teeth, the remainder of the mouth not being affected (Fig. 429). In each of these cases a history of inveterate cigarette smoking was obtained. The nature and location of the lesions coupled with the history led us to suspect that the resistance of the labial mucous tissues had been lowered by the direct action of the smoke from cigarettes held in the lips. This view was supported by the fact that when the cigarettes were held in a mouth-piece by which the smoke was directed beyond the teeth to the interior of the mouth and prophy-

lactic measures were instituted, the inflammation subsided and the tissues healed.

Although the local causes of pyorrhea just enumerated in many cases seem to be active and potential factors in the disease, the local disturbances which they produce are profoundly modified by the general and constitutional status of the body as a whole. As has been previously stated, a most prominent characteristic of peridental disease is the inflammatory reaction by which the tissues oppose the invading process. When these reactions are of high order, local irritations excite strong circulatory reactions which are hypertrophic in type and are strongly resistive to invading organisms. In this manner the tissues successfully withstand continued indignities from local injury without undergoing degeneration or disintegration. On the other hand, when the local reactive powers of the affected tissues are low, rapid destruction and deep pyorrheal involvement may take place as the result of a

FIG. 429.—Severe pyorrhea on anterior teeth, associated with heavy cigarette smoking.

mild local injury. The significance of the local causes, and their ability to produce peridental disease is directly dependent therefore upon the protective powers of the tissues affected. As the quality of protective reaction which the local tissues possess is, in turn, largely determined by the general health and bodily metabolism of the individual, the inception and progress of every case of pyorrhea is influenced and often dominated by general and constitutional states. Abundant illustrations of this fact may be seen in the differing types of cases which are presented, on the one hand, in individuals who are weak, debilitated, and mal-nourished, and on the other, in those who are strong, robust and full blooded. Those who are constitutionally weak are frequently predisposed to pyorrheal infections which run a rapid course and produce deep involvement and destruction of tissues. The stronger type of individual is more often affected by gingivitis of a hypertrophic and proliferative order and, as a rule, shows a marked immunity toward

pyorrheal invasion. When pyorrhea does occur in this latter class, some other metabolic fault may often be found by reason of which the natural resistance of the local tissues has been lowered. These nutritional disturbances may be so slight that they escape clinical observation or they may be manifest derangements which are severe in type. It has been observed frequently that pyorrhea may be associated with various systemic diseases, as arthritis, diabetes mellitus, syphilis, tuberculosis and other debilitating affections. These systemic disturbances undoubtedly act as predisposing causes to peridental disease by lowering the general bodily resistance against infection and certain of them have a more direct causative relationship by virtue of the fact that during the course of the disease various foreign and irritative substances from the altered salivary secretions are laid down in or upon the peridental tissues.

Systemic Causes.—*Gout and Arthritis.*—Among the systemic diseases which are associated with pyorrhea, gout and arthritic affections are very commonly recognized. In the course of these diseases the body suffers from an excessive retention of uric acid in the blood and tissues as a result of which serious nutritional and metabolic disturbances are produced in all bodily tissues. As a further characteristic of these affections, salts of uric acid may be deposited in certain tissues in the form of crystals of sodium biurate. These deposits usually occur in the articulatory joints producing gout and arthritis and may also be laid down in the gingival capillaries and in the peridental membrane, where they act as irritants and mechanical obstructors of the circulation. In cases of severe arthritis, the resistance of the peridental tissues to pyorrhetic infections may be potentially lowered with the result that individuals so affected are definitely predisposed to peridental diseases.

Diabetes Mellitus.—It has been noted that diabetic patients are prone to pyorrhea. The marked debility and nutritional disturbances attendant upon the disease are sufficient to account for the lowered resistance of the oral tissues. Furthermore, as a prominent characteristic of the disease there is a tendency of all tissues toward infection and these infections when once begun run a rapid and virulent course. The mouths of diabetics are usually in a poor state of oral hygiene and bacterial growth is prolific. About all the teeth there is found a pasty mucous colloidal material which interferes with oral cleanliness and in which the microörganisms thrive. In diabetes, therefore, the oral fermentations are high, the resistance of the tissues is lowered and pyorrheal invasion is common.

Systemic Poisons.—Predisposition to pyorrhea may arise from systemic intoxication. The source of these poisons may be the

introduction of drugs through stomachic or subcutaneous routes, the elaboration of toxins from bacterial invasion, and the production of poisonous substances as the result of faulty body metabolism. In the first group, perhaps the most spectacular example is that of mercurial poisoning which has long been associated with oral disease and salivation. After a continued dosage of mercury the gum tissues take on a characteristic bluish color which is diagnostic of mercurialization. In the circulation of this drug through the body there is a tendency for it to become lodged in the gingival capillaries where it mechanically occludes the vessels and produces passive congestion and thrombosis. The blue color of the gums is indicative of venous congestion in the vessels which lie immediately beneath the mucous membrane. As a result of profound circulatory and nutritional disturbances the resistance of the peridental tissues is lowered and they frequently succumb to pyorrhetic invasion. It has been noted, however, that if in cases of mercurialization the mouth be kept clean and in a hygienic state, these congestive and inflammatory conditions of the gingival tissues do not occur. In explanation of this phenomenon it is claimed that the deposition of mercurial salts in the gingivæ is dependent upon the presence in the mouth of certain products of fermentation (probably sulphides), arising from the decomposition of foods. When the mercuric compounds in the gingival circulation come into contact with these sulphides which may diffuse through the mucous membrane an insoluble compound of mercury is formed which is lodged in the capillaries of the peridental tissues. When no oral fermentations exist the mercury remains in solution in the blood stream and is not deposited. The rationality of this premise is well supported by the fact that in many syphilitic clinics in which a rigid regime of oral prophylaxis is instituted for every patient large quantities of mercury are given without producing any serious disturbance in the peridental tissues. In many instances dentifrices containing potassium chlorate are used. This ingredient supposedly assists in maintaining the mercury in the soluble chlorid form.

A similar relationship is noted in regard to lead and other forms of metal poisoning. In each case they disturb the gingival circulation and lower the resistance of these tissues against infection. As a rule it may be said that their deposition is largely favored by faulty oral hygiene.

Auto-intoxication.—During the course of many diseases and disturbances of metabolism poisonous substances are produced by the body and are given off to the general circulation. These may consist of waste products which the body has failed to eliminate or in abnormal and harmful products of cell metabolism. Examples of this class have

already been cited in the cases of arthritis and gout. The condition known as *acidosis* also should be included in this class of poisons. Normally, the reaction of the blood is alkaline and the maintenance of this alkalinity is of great importance to body metabolism. When by disturbances of function an excess of acids is present in the blood and tissues all enzyme and chemical changes in the body are disturbed. Severe acidosis occurs in diabetes, cancer, after anesthetics and in certain periods of pregnancy. A milder form arises from excessive acid ingestion or from incomplete oxidation of foods by the body. These hyperacid states are usually obscure and not easily recognized but there are strong evidences that they often act as predisposing factors in peridental disease and unless corrected, militate against the successful treatment of the case. Under the direction of a competent internist acidosis may often be relieved by prescribing a balanced diet and by the administration of alkalies.

Intestinal Intoxication.—It has been noted by many writers and practitioners that pyorrhea is frequently associated with constipation. In addition to the ingested food and drug poisons which may be absorbed from the intestine there is a class of poisonous products which are formed in the intestine by the bacterial fermentation of ingested food. This latter form of intoxication is, as a rule, much less acute than that of drugs and food poisons. They constitute a mild subacute or chronic intoxication producing changes in metabolism which are not easily traced to their ultimate source. The elaboration of these poisonous products and their absorption from the intestine are favored by chronic constipation and obstruction or dilatation of the bowel. The most significant intestinal poisons are the various split products of protein decomposition, indol, skatol, phenol, ptomaines, etc., which when absorbed into the system act either as active poisons or as disturbers of cell metabolism. In many cases when the individual has followed an ill-balanced diet which is overloaded with proteins and when because of sedentary occupation, lack of exercise or digestive faults, the foods undergo putrefaction in the intestinal tract, rather than digestion, the products of this decomposition and retained fecal matter may enter the circulation to produce systemic poisoning. The frequency with which pyorrhea is associated with constipation, excessive meat ingestion and lack of exercise strongly suggests that intestinal intoxication may play an active part in the inception and continuation of peridental disease.

Age.—Pyorrhea seldom occurs in the young and vigorous individuals but is limited almost solely to those of middle or advanced age. The great predominence of its occurrence in the later years of life indicates that predisposition to peridental disease increases with age.

This tendency may arise from a physiologic decadence of the peridental tissues, from a general lowering of metabolic efficiency and resistance of the body as a whole, or to a change in the oral secretions as a result of which calculi and viscous materials are laid down upon the tissues to act as local irritants or to interfere with oral hygiene.

In a consideration of the etiology of pyorrhea it must be admitted that constitutional factors play a more or less important part in every case of the disease; in certain instances it is only a subordinate one and in others it constitutes the dominant and determining factor. As we have stated previously, many operators who are successful in the treatment of peridental disease have failed to observe the relationship of general bodily states to the affections which they treat because of the fact that by the performance of local operative and prophylactic measures alone they are able to arrest and control a great majority of pyorrheal cases. Since the disease frequently yields to local operative procedures, they conclude that it is essentially a local disturbance and independent of constitutional causes. In the explanation of this situation and in answer to the question which was asked in the section on the Significance of Local Operative Procedures, as to the manner in which pyorrhea, a systemic disease, might be controlled by local measures alone, the following statements may be made:

If, as has been pointed out, pyorrhea is essentially a destruction of peridental tissues by infectious organisms arising from a lowering of the resistance of these tissues, it follows that any procedure which will decrease the causative factors and increase the resistance and combative power of the tissues will tend to arrest the progress of the disease and may effect a cure. It is to this end that practically all operative and oral prophylactic measures are directed. Upon the removal of all traumatic and mechanical irritants, the disturbances which they have produced in the peridental circulation will cease. As a rule, in these cases excessively high fermentative processes predominate throughout the oral cavity and the bacterial life is vastly increased over the normal. When prophylactic measures are completely performed these abnormal bacterial growths are reduced to the point at which they are no longer significant and the general infective picture of the oral cavity disappears. A similar process occurs in the pyorrhetic lesion. In the act of removing the sub-gingival calculi from the roots by operative measures and by planing their surfaces a considerable amount of infective material is mechanically removed from the tissues. In this manner the tissues are relieved by mechanical irritation and the bacterial flora both oral and sub-gingival are greatly reduced. Furthermore, in the performance of these operative procedures more or less bleeding occurs as a result of which the stagnant and congested blood is drained from the tissues and an active circulation is stimulated.

The immediate effect of local operative measures consists in the removal of mechanical irritants, a marked decrease of infectious organisms, and a stimulation of the peridental circulation. If the infectious organisms be sufficiently decreased to the point where the invaded tissues with their quickened and renewed circulation may successfully combat the remaining organisms (complete sterility not being practicable in oral tissues) the peridental disease may be arrested and healing take place as the direct result of local procedures alone. And in fact, this is frequently accomplished even in cases in which general and constitutional factors have been largely concerned in the process. In them the decrease of the attacking force and the increase of resistance and recuperative power of the local tissues are able to control the disease notwithstanding the general predisposing factors which may exist. It is very evident that the treatment of such cases will be facilitated and the chances of success greatly enhanced if the general and constitutional factors involved be recognized and corrected, concurrent with the local treatment. A neglect of the systemic causes which lie behind these local degenerative processes frequently results in the failure and inability of local measures to control the disease.

In view of this wide range of local and constitutional factors which may enter into the various cases of pyorrhea it will be recognized that this disease is an extraordinarily complicated and involved process. As each may be the product of any or all of these causative factors, it follows that almost an infinite number of combinations may be formed which may militate against the health and integrity of the peridental tissues. Pyorrhea, as has been previously stated, is not uniform nor constant in its manifestations but presents many phases and variations in its course. Success in treating and controlling these conditions is dependent upon the recognition of the most predominating factors in each case, and the institution of measures which will either remove these determining causes or reduce them to a state of inefficiency. To accomplish this a close study of the various cases which are presented must be made and methods of diagnosis must be established by which the various types of pyorrhea may be recognized and classified to the end that intelligent treatment may be instituted to control the disease.

Diagnosis.—The means by which the type and severity of various cases of pyorrhea may be determined consist of certain local symptoms and disease manifestations associated with the state of general health of the patient. The primary symptoms may be classified into four definite groups namely, changes in color, form, and density of the gums and their attachment to the necks of the teeth. These are supplemented by secondary or more advanced local symptoms such as the

loosening of the teeth, the presence of pus and roentgenographic evidence, together with a consideration of the general systemic conditions. It is by the proper interpretation of these symptomatic changes that the various types of pyorrhetic affection may be analyzed and classified.

Changes in Color.—The color of the normal gum tissues varies in different individuals from light to dark shades of pink, but in all cases the color is uniform throughout (Fig. 430). This color is the reflection of the hemoglobin of the blood in the capillaries which lie immediately beneath the mucous membranes while the depth of the color is determined by the amount and quality of the blood in the vessels. In full blooded individuals the submucous circulation is filled with red blood which gives a deep pink or dark red color to the gum tissues. In contrast to these the anemic and undernourished types have a less amount

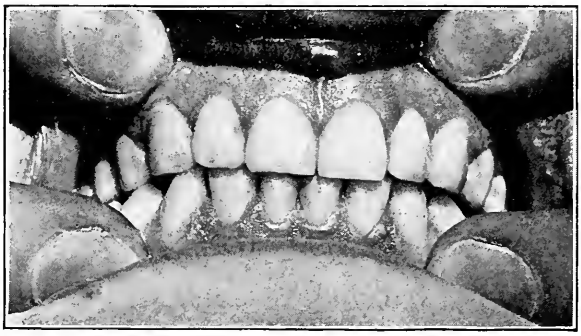

FIG. 430.—Normal, healthy gums.

of blood in the peripheral circulation, the hemoglobin content is usually low and the color of the gum tissues is normally a light shade of pink (Fig. 431). Thus we may read in the general gum color many interesting and important facts concerning the general health and the character of the general circulation.

Any localized deviation from that uniform color which is typical to an individual is indicative of local changes in the circulation. Darker shades of red usually denote hyperemia, the depth of the color depending upon the severity of the circulatory disturbance. Deep red and blue (Fig. 432) are indicative of stasis and passive congestion and an engorgement of the submucous circulation with venous blood. These localized changes in the gum color should be to the operator a signal of danger for, as a result of the circulatory derangement, these tissues will suffer from a lack of nourishment and will lose their normal tone and resistive power. It may also be noted that in the vicinity of these

color changes some form of irritant, either chemical, bacterial or mechanical, may be found which is producing an active injury, upon the removal of which the color of the tissues, as a rule, promptly returns

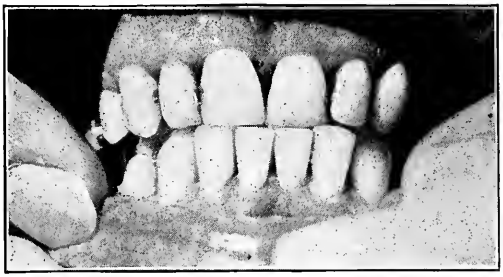

FIG. 431.—Pale anemic gums, evidence of poor circulation.

FIG. 432.—Localized change of color between upper central incisors, deep red to purple, indicative of localized irritation at that point.

FIG. 433.—Gingivæ highly inflamed and congested in response to some form of localized irritation. Indicative of strong protective tissue reaction and as a rule responds readily to treatment.

to normal. By experience one may also read in these gum colors the types of protective reaction which are put forth by the tissues to combat the injury. In those cases in which the tissues are red and give evidence of strong inflammatory reaction (Fig. 433) it will be found

that the pyorrheal invasion advances slowly and that when the irritations have been removed the tissues show a rapid recuperative power. Conversely, when the gum colors are pale or dark blue (Fig. 421) the reactions are less complete, the invasion is more rapid and a cure more difficult to obtain. Color changes, therefore, constitute a very important diagnostic factor in the discovery of pyorrhea and in the evaluation of the local tissue reactions.

Changes in Form.—Normally the gum contour about the teeth follows that of the edge of the enamel at the neck of the tooth which it slightly overlaps. In the interproximate it extends up to the point of contact completely filling the space between the adjacent teeth. Deviations from the normal are of two types, namely, shrinkage or retraction of the gum line, and swelling or hypertrophy of these tissues. Examples of the former may be seen in the retraction of the buccal or lingual

FIG. 434.—Loss of interproximate bone and gum tissues in beginning pyorrhea. Reaction poor.

contours due to tooth brush abrasions or to the atrophy of old age. So also, the gingival tissues are retracted as a result of deep pyorrheal involvement. A slight retraction of the interproximate tissues is shown in Fig. 434, and a more severe involvement in Fig. 435. Swelling of the gum tissues about the teeth frequently occurs (Fig. 436) in the early stages of gingivitis and pyorrhea. It is indicative of strong inflammatory reaction and usually denotes a high degree of resistance and recuperative power. As in the case of color changes one may also read in the behavior of the gum contours the type of tissue reactions to various irritations. When their tendency is to shrink and retract it may be inferred that the resistance of the tissues is low and that degenerative changes are easily induced. But when in response to injury the tissues swell, especially if the color is bright red, the local tissue reactions are usually of good order and highly resistant to pyorrhetic invasion.

Changes in Density.—The normal gum tissues are hard, firm and resistant to mechanical injuries. The mucous membrane is tightly stretched over an underlying dense connective tissue which is supported by the alveolar process. This epithelium is so tough that in the act of vigorous mastication and brushing of the teeth no abrasion

FIG. 435.—Extensive loss of alveolar bone and retraction of gingivæ in advanced pyorrhea (case treated and under control at time picture was taken).

or hemorrhage of the soft tissues will occur. But when the gum tissues are soft, spongy, and bleed easily as the result of slight injuries they are no longer normal or in health. This latter condition is indicative of chronic inflammation or general bodily disturbance and tissues so affected are often highly susceptible to pyorrhetic infection.

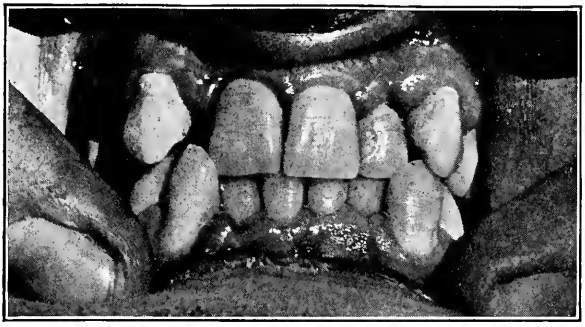

FIG. 436.—Gingivitis, hypertrophic type, indicative of strong tissue reactions.

The Line of Attachment.—Normally the gum tissues are firmly attached about each tooth to the peridental membrane at the bottom of a shallow gingival crevice. When by exploration it is determined that this normal attachment has been disturbed and that a space exists between the root and the surrounding peridental tissues, it is evident that the tissues have suffered some form of injury which in the

great majority of cases is pyorrheal in type. No matter how much inflammation and swelling may be present in the superficial and gingival tissues true pyorrhea does not exist as long as the line of attachment of the soft tissues about the root remains normal. The crucial test of pyorrhea consists, therefore, in the careful exploration of all gingival crevices to determine whether or not definite breaks in the normal line of attachment have been effected. This is the most important and the most certain method of diagnosing pyorrhea.

Loosening of the Teeth.—It is only in the more advanced and severe cases of pyorrhea that the teeth become loosened. Because pyorrheal lesions, as a rule, are confined to but one or two sides of the teeth and tend to extend apically along the sides of the roots rather than about them, deep lesions may be produced about teeth which still possess sufficient peridental attachment to hold them securely in position. When by reason of extension of the disease one or more of the teeth becomes loose, it may be inferred that the condition is very serious and the possibility of successful treatment of these teeth is doubtful. The loss of stability on the part of a tooth may arise either from a rapid and extensive destruction of the peridental membrane by which the attachment of the root is cut off from the surrounding alveolar bone, or from a disintegration, or a metaplasia of the bone to fibrous tissue by which the attachment of the tooth becomes wholly fibrous and unfirm. The prognosis in case of a loosened tooth depends upon the type of degenerative process which has occurred. When there is only a moderate degree of movement and by roentgenographic evidence it is determined that at least the apical half of the root is embedded in bone, if other conditions permit, treatment may be attempted. But when on percussion the tooth plays up and down or may be rotated in its socket, and the roentgenographic findings show that the surrounding bone has been destroyed, treatment, as a rule, is contra-indicated. In this latter case the successful cure of the disease would involve not only the healing of the lesions and a reattachment of the tissues to the teeth, but also a regeneration of sufficient bone to give stability to the root. This result may be obtained occasionally in young and healthy individuals under most favorable circumstances, but should never be hoped for when systemic derangement exists or in patients past middle life.

Pus.—The presence of pus has been used by many as an important and specific means of diagnosing pyorrhea. But as we have previously pointed out, pus is not a specific feature of pyorrhea inasmuch as a large majority of pyorrheal lesions have no visible purulent discharge. The only information that may be derived from pus is that the predominating organisms are of the purulent type and that against them the tissue reactions are of good order. Instead of being a symptom of

grave significance, pus is an indication that the tissues are combating the infection and perhaps controlling it and that in view of the active local reaction the prognosis of treatment of such a case is favorable.

Roentgenographic Findings.—There are many roentgenographers who claim that they are able to diagnose all stages of pyorrhea by the roentgenogram, but in our experience this form of diagnosis is accurate and valuable for only one phase of the process, namely, the extent of bone destruction. In all other questions regarding a pyorrheal involvement one may be easily misled by roentgenographic evidence; as for instance, it is difficult and often impossible by these means alone to differentiate between an active pyorrheal state and a healed lesion of the disease. An opinion, therefore, regarding a case of pyorrhea, should never be formulated from the evidence of a roentgenographic film alone, but rather should all other means of diagnosis be employed in which the roentgenogram is but one factor. From the roentgenogram a more or less accurate idea of the amount of bone destruction may be obtained. In this also there is a possible source of error in that destruction of the interproximate bone may take place to produce a hole or cup-shaped depression between two adjacent teeth, while the labial and lingual plates are still intact, in which case the exact status of the osseous lesion is not easily determined by the roentgenogram. So also the destruction of bone on either the labial or lingual aspects of the tooth may not be apparent when the opposite bony walls are unaffected, as the shadow of the healthy portion obscures the outline of that which is diseased. Too much dependence should not be placed on the roentgenogram in the diagnosis of pyorrhea, but rather should it be employed only as an auxiliary and a subordinate factor in the whole chain of evidence.

General Considerations.—In every case that is presented the first question to be determined is whether treatment should be attempted or extraction prescribed. By means of the foregoing methods of diagnosis accurate information may be obtained regarding the local conditions, but this alone will not suffice. As we have previously attempted to point out, no disease should be considered as a local process independent of general and bodily states. The diagnosis and treatment of pyorrheal affections should not be made without a careful and thorough consideration of the general health, age, temperament, occupation, environment and personal characteristics of the patient. This is especially true in those cases in which the systemic health is an active factor in the disease. As a rule, treatment is contra-indicated in patients who are in ill health, especially if their disabilities are of an infective type. Whenever treatment is attempted in such cases the possibility of the pyorrheal infections being foci of general infection should always be

clearly borne in mind and if a prompt improvement of the local and general disturbances is not obtained, all suspected teeth should immediately be extracted. On the other hand, if the general health is good and all other conditions are favorable, many severe and advanced cases of pyorrhea may be treated and the lesions successfully healed. The decision concerning the expediency of treatment of any individual case of pyorrhea should be determined very largely by the general systemic status of the patient and all contributing influences which may help or hinder the favorable outcome of such treatment. To this end many operators insist that all patients submit to a complete physical diagnosis before treatment is attempted, and in many instances such a course is highly desirable but in a large number of cases a fairly accurate opinion of the general health may be obtained by a few well directed questions and the general appearance of the patient.

Treatment.—Any consideration of the treatment of pyorrhea should be preceded by a clear conception of what benefits may reasonably be expected to result from such remedial measures. The statement frequently has been made by many writers that pyorrhea cannot be cured and this opinion still obtains in the minds of many practitioners today. If by cure is meant the healing of the lesions of the disease and the complete restoration of all lost tissues by structures that are identical with the original tissues, it is true that severe and advanced cases of pyorrhea in which a considerable portion of the alveolar process and the overlying tissues are lost, cannot be cured. But if a permanent arrest of the disease, and a healing of the lesions by a reattachment of the soft tissues about the teeth at a lower level on the roots be considered a cure, then a large percentage of cases of pyorrhea may be cured. The condition is quite similar to that of a deep ulceration in any part of the body which by treatment is checked but in the process of healing a defect is left because of an incomplete restoration of the lost tissues. In either case the disease is stopped and the lesions have healed but in case the conditions which caused the first appearance of the disease shall subsequently obtain, the lesions may reappear. If on the contrary, ordinary hygienic measures be established by which the causative factors are continuously removed or made ineffective, the cure of the disease is permanent.

This is actually what does happen in a large majority of cases of pyorrhea, when a rational treatment has been employed followed by a regime of oral prophylaxis. By the complete removal of all local irritants a prompt reduction of circulatory disturbances such as hyperemia, congestion and inflammation, is usually obtained. When, by further operative procedures, all denuded root surfaces are planed smooth to the bottom of the pockets the surrounding tissues usually

may be made to reattach themselves to the cementum, thereby completely obliterating the pocket. In time the soft tissues about the teeth become hard, firm and highly resistant to infection and traumatic injuries and as long as this state of oral hygiene is maintained the likelihood of a return of the pyorrheal infection is very remote.

Considerable skepticism has been voiced by a number of writers concerning the possibility of a reattachment of the soft tissues about a pyorrheal pocket to the "pus-soaked cementum" of the root. Many of these writers have emphatically stated their unqualified opinion that this has never occurred and that it is impossible of accomplishment. The actual histologic proof that healing of this order has taken place in a pyorrheal pocket is difficult to obtain, as patients are unwilling to part with a tooth that has been successfully treated in this manner. But clinically there is an abundance of evidence to convince any fair minded and unprejudiced observer. Personally we have seen cases without number, under our own care and in the hands of many others, in which deep pockets freely exuding pus and extending two-thirds and even three-quarters of the length of the root, in response to operative measures gradually became more shallow, filling in at the bottom day by day until the tissues were fully attached up to the free edge of the gum margin, save a gingival crevice of normal depth. It is argued by the oppositionists that this is not a true attachment but merely a close coaption of the hard and soft tissues without a physical union. To this we may reply that in cases in which healing has taken place, if an exploration be made with a smooth nerve broach in a gingival crevice at which point a pyorrheal lesion previously existed, no entrance can be effected and if pressure be exerted, blood flows and the patient winces from pain. There is, indeed, no example to be found in any other part of the body in which the hard and soft tissues have so closely coapted without physical union. Furthermore, in case of implanted porcelain roots we see excellent examples of coaption of tissues without physical union but in all of these an instrument may be readily passed between the tooth and soft tissues at any point. We recognize the fact that this perfect healing of pyorrheal lesions may not always be obtained since in many cases it is not possible to completely prepare all affected root surfaces or the vitality of the surrounding tissues may be so low that regeneration does not take place. But we are confident that when conditions are favorable and the operative procedures have been completely performed, a physical reattachment of the soft tissues to the root to obliterate the pyorrheal pocket does take place in a large percentage of cases. When, by severe involvement, the interproximate gum tissues and the buccal and lingual contours have been considerably deflected, it must not be expected that

these tissues will regenerate along the root, crownwise, to assume their old positions except in young individuals when the recuperative power is high. As a rule, all that may be obtained is a healing of these tissues and an attachment to the roots of the teeth at their present position. Indeed, during the treatment, the gums may shrink down about the teeth to a lower level on the roots because of a reduction of swellings and circulatory disturbances (Fig. 437).

It will be recognized that the greatest success in the treatment of pyorrhea is to be obtained in the early stages of the disease. At this time the destruction has not been severe and if the remedial measures are properly applied the disease may be checked promptly and the tissues restored to approximate normality. Could all cases of pyorrhea be treated in their incipient stages the handling of this disease would be a simple matter. But when the process has advanced to the point

FIG. 437.—Before and after treatment of case of advanced pyorrhea, showing retraction of gingival line after reduction of peridental inflammation.

where deep lesions are effected in the peridental tissues and the alveolar bone has degenerated, the treatment is much more complicated and the chances of success greatly reduced. In the treatment of these more advanced cases care should be taken not to attempt the impossible. When the general health and bodily resistance are low or indications of severe general infections are present all seriously affected teeth should be extracted at the outset. Seldom is it advisable to attempt treatment of lesions which extend more than two-thirds of the distance to the apex of the root. Treatment is also ill-advised when the tooth plays up and down in its socket or may be rotated by pressure. So also, when by roentgenographic evidence it is determined that there is not sufficient bone remaining about the apex of the root to support the tooth, successful treatment cannot be hoped for except in very young and favorable individuals.

Treatment of pyorrhea, therefore, should be attempted only after a

careful prognosis has been made, taking into account the extent of the local destruction, the type of local reaction, and the age, general health and the probable coöperation of the patient in carrying out the oral hygienic measures. When conditions are favorable, highly satisfactory results may be obtained by proper operative and prophylactic measures; but when the attending conditions are unfavorable or the disease is too far advanced, attempted treatment is certain to result in disappointment and failure.

The method of treatment of those cases of pyorrhea which in the light of careful diagnosis show promise of a satisfactory result, is largely that of the application of the principles set forth in Chapter III and the extension of these procedures to include the surfaces of the roots which have been denuded of their normal pericemental attachments. It must be recognized that in all cases of pyorrhea the general bacterial flora of the mouth is abnormal and the first step in the process is to decrease and change the type of oral fermentations. To this end thorough and rigorous prophylactic measures should be employed to rid the mouth of all foreign and harmful agencies. All calculi and foodstuffs should be removed from the crowns of the teeth and between the teeth, and all rough enamel surfaces should be smoothed so that they may be kept clean. It is advisable to remove all ill-fitting crowns and bridges which irritate the soft tissues or tend to harbor food materials beneath them. All fillings which overhang their margins should be trimmed down until they are flush with the enamel surfaces. In case of proximate fillings which do not have proper contacts with the adjacent teeth the defect should be remedied or the filling replaced. All open cavities should be filled, if not permanently at least with a temporary stopping.

When these general prophylactic measures have been carefully performed, the next step should be that of equalizing occlusal stresses of all the teeth. By the use of carbon paper the points of greatest stress may be located and by judicious grinding with stones any undue and excessive stress of one tooth upon another may be relieved. In this manner teeth which are severely affected by pyorrhea may be lightened of their occlusal load and the stress of mastication shifted back to other teeth which are more able to bear the burden. This feature of the process is highly important to the successful treatment of the disease. When all of the foregoing procedures have been carried out the mouth and teeth are ready for the special treatment of the pyorrheal lesions.

This treatment should consist in suitable operative procedures by which the denuded cemental surfaces may be completely cleansed of all calculi and foreign materials and subsequently planed to a smooth

homogeneous surface. It must be remembered that the outer surface of the cementum is rough and pitted by reason of the apertures in which are embedded the broken ends of the peridental fibers. If the outer cemental surface be allowed to remain, its pitted surface offers an admirable retention for bacterial growths, the organisms, thriving like cave dwellers in the side of a cliff from which they come forth at a future time to attack the surrounding tissues. If by careful planing this outer pitted surface be slightly reduced, a deeper and more homogeneous layer is reached which offers little retention to infectious organisms. But in the reduction of this surface great care must be exercised not to cut too deeply, for the cementum on the lateral surface of the root is thin and with little effort a sharp instrument improperly

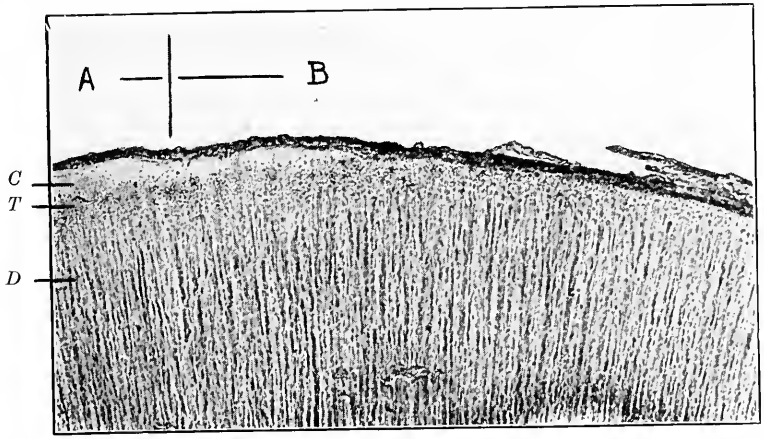

FIG. 438.—Cross-section of root carefully smoothed with files. *D*, dentin; *T*, granular layer of Tomes; *C*, cementum; *A*, portion of cementum not touched with files; *B*, portion of root filed, showing removal of cementum and cutting into the dentin.

applied will cut through the cementum and the homogeneous layer which lies below into the granular layer of Tomes on the periphery of the dentin (Figs. 438, 439 and 440). When this unfortunate result has occurred the surface so cut can never be made smooth but will be deeply pitted by spaces opening directly into the dentinal tubuli in which the pyorrheal infections may find a permanent habitation to prevent the successful healing of the lesion. It is therefore of the highest importance that in the operation of preparing the root surfaces too much cementum should not be removed, but rather should these surfaces be carefully and evenly smoothed until by the sense of touch transmitted through the instrument it is determined that a homogeneous surface has been obtained and then all further reduction at that point should cease.

This operation may be accomplished by the various types of instru-

ments described on p. 153 which should be used in the manner outlined for preventive dentistry. In each case an instrument should be selected

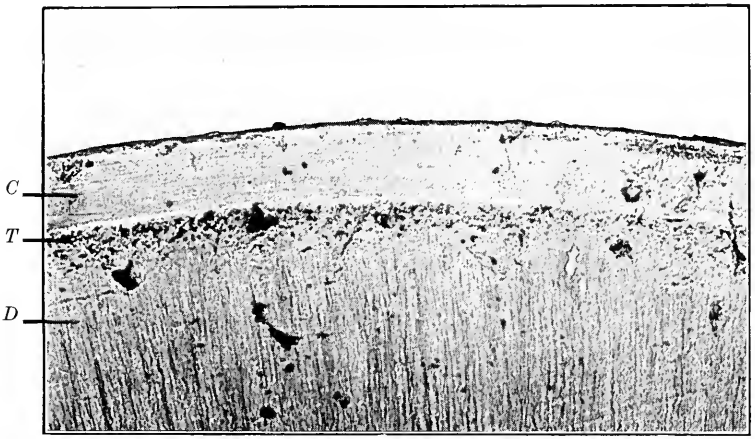

FIG. 439.—Cross-section of root smoothed with Younger type of instrument. *D*, dentin; *T*, granular layer of Tomes; *C*, cementum which has not been appreciably reduced by the instrumentation.

which best adapts itself to the position upon the root it is desired to reach and then the blade should be carefully introduced beneath the

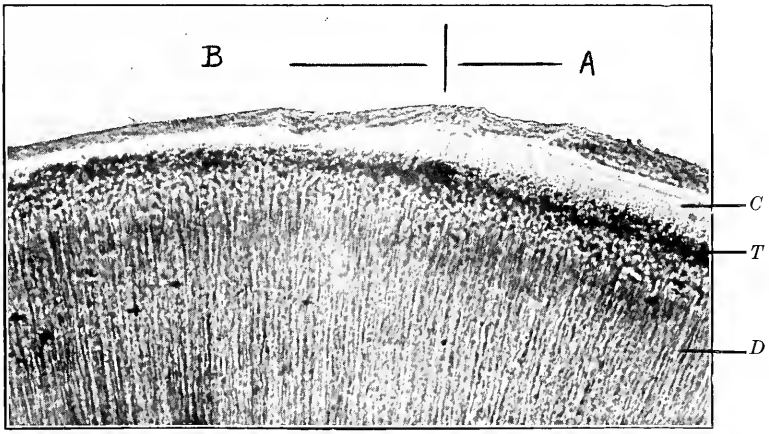

FIG. 440.—Cross-section of root smoothed with planing instruments. *D*, dentin; *T*, granular layer of Tomes; *C*, cementum; *A*, portion of root not touched with the planers; *B*, portion of root planed, showing reduction of cementum nearly to cemento-dental junction.

gum to the bottom of the pocket to plane the surface of the root with a draw motion, crownwise, until the root is smooth.

The operative treatment of pyorrhea should not be done in a hit or miss manner but should follow a consecutive plan of procedure which is directed toward a definite object to be attained. This object is the surgical cleansing and smoothing of every surface of each denuded root and the reduction of the infective organisms to the point that the resistance of the tissues may gain ascendency over them. To this end the operative procedures should begin in one corner of the mouth, for instance the last upper right molar, and progress tooth by tooth about the mouth until all are surgically clean. Each tooth should be finished before another is attempted and if the surfaces are properly prepared it should not be necessary to do any further instrumentation upon them other than the cleansing of the pockets as will be described later.

In view of the fact that this form of treatment is a careful exacting operation and is more or less painful to the patient it is always wise to make the appointments short, not more than thirty to forty-five minutes to be repeated each successive day, treating but two or three teeth at each sitting until all have been covered. In cases of highly infective type in which the tissue resistance is low the treatment of only a few teeth is a distinct advantage. It is noted that operation upon these highly infective types of pyorrhea frequently is followed by a distinct shock. As a result of the operative procedures the protective tissue wall about the infection is broken down and through the surgical wounds that are produced a quantity of infectious organisms and their products are introduced directly into the circulation. Consequently, fever and general bodily disturbances may follow drastic treatment of too many pyorrheal lesions at any one sitting. When only a few such lesions are operated upon, the general effects are usually less marked or are insignificant.

When a surgeon operates in a sterile field he closes the wound and does not disturb it unless infection subsequently sets in. But when the wound is on a surface that necessarily must be reinfected and cannot be kept sterile, he washes and dresses the wound daily until healing has taken place. Operations on pyorrheal tissues are of this second type, in that the wound is constantly open to oral infections, food materials, and other foreign substances which irritate the tissues and militate against their healing.

Of special significance in this regard are the fine subgingival calculi which are laid down upon the roots of teeth in a pyorrheal lesion subsequent to operation upon them. It is frequently noted that although the root-surfaces may have been thoroughly planed and smoothed at one sitting, the next day a new deposition of calculi may be found beneath the gum line which will continue the irritation to the surrounding soft tissues and prevent their healing. The source of

these rapidly forming calculi is not definitely known, but it is probable that they are an inflammatory exudate of the diseased tissues. When by prophylactic measures the peridental inflammation has been reduced and the tissues have assumed their normal color and density this tendency to form subgingival calculi is terminated. It is therefore necessary at each daily sitting to go about the teeth which have previously been treated and carefully enter the pockets to remove any foreign materials and infectious matter from them, extreme caution being taken not to tear down the new peridental attachments which have been formed in the process of healing. This may be done with a small Younger type instrument or with dull files, after which the pocket should be flushed with a bland solution. When this procedure is carried out daily it will be seen that day by day the instrument may be introduced a shorter and shorter distance beneath the gum until finally no pocket remains, healing having been completely accomplished from the base of the lesion up to the gingival line.

Thus as the result of instrumentation alone in favorable cases the pus flow may cease after one treatment and by daily cleansing and washing a complete attachment may be effected between the teeth and the peridental tissues. As an adjuvant to these measures the pockets may be flushed out with a weak iodin or a saline solution. The following iodin lotion is admirable for this purpose as it is antiseptic, sedative, astringent and stimulative in its action. The formula is as follows:

Phenol (5 per cent.)	1 part
Aconite (tinct.)	2 parts
Iodin (tinct.)	3 "
Glycerin	4 "

This may be introduced into the pockets with a glass barreled syringe having a platinum point which may be sterilized readily in the flame (Fig. 441). In many cases a 5 per cent. sodium chlorid solution will give equally beneficial results. This strength is to be preferred over the bland physiologic salt solution for the reason that the hypertonic salt in contact with the tissues produces in them an exosmosis and exudations which tend to wash the mucous surfaces. Furthermore, the lymph and blood fluids are in this manner attracted to the spot bringing many germicidal and immune principles to aid in the reduction of infection.

It is the opinion of the author that no other drugs are necessary in the treatment of pyorrhea except in rare cases. Occasionally an old tough granulation tissue will be found about a chronic pyorrheal pocket and when such a tissue obstinately refuses to heal after proper instrumentation, it may be treated with phenol-sulphonic acid (Merck).

This may be introduced into the pocket by means of a thin wedge made of bamboo held in a porte-polisher.

As healing takes place, the patient may be seen less and less frequently. During this time he should be instructed in the proper method of caring for his mouth, encouraged to keep the tissues continuously clean, and to massage the gums with the brush until they are hard, firm and highly resistant. When the case is finally under control and the pockets healed, the patient should be required to report at intervals of from one to three months, depending upon the case, in order that he may be assisted in the care of his mouth and that all incipient gum lesions may be noted early in their course. Usually these lesions may be easily aborted in their incipiency by the removal of the irritation which has caused them and as a result, the tissues are readily restored to normal health. In certain types of cases when the lesions have healed and the infections have been eradicated, the

FIG. 441.—Syringe for washing out pyorrheal pockets.

tissues remain permanently in health and no tendency to recurrence is evident. But in other types, especially when the saliva is thick and mucinous, the mouth hygiene is not easily maintained, infections are high and the tissue resistance is low. There is in them a constant tendency toward a recurrence of the pyorrheal invasion, for the prevention of which it is necessary to combat continuously the predisposing factors which are present.

Thus we see that the successful treatment of a given case of pyorrhea depends upon the severity of the case, the reaction of the local tissues, the general health, and the thoroughness with which the operative procedures are performed. Provided that the first three of these considerations are favorable the degree of success is largely determined by the perfection of technic which is employed in the surgical procedures. Half way measures are worse than none, for they cause pain and discomfort to the patient and result only in failure. But

careful and conscientious study of these conditions and the technic involved to relieve them will enable the operator to obtain a permanent healing and a potential cure of a large majority of such favorable cases.

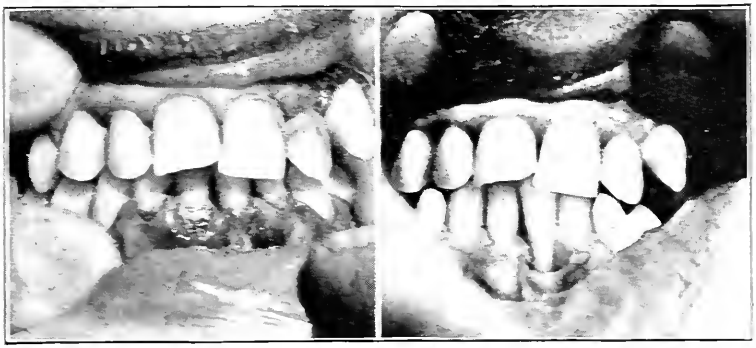

FIG. 442.—Before and after treatment. A severe pyorrheal involvement with deep pockets about practically all teeth: denuded roots covered with thin scales of hard, dime-like subgingival calculus: reactions poor. Case rapidly recovered after complete removal of all subgingival calculi.

FIG. 443.—Before and after treatment. Case of pyorrhea of long standing: heavy subgingival calculi: reactions good. Promptly recovered after thorough operative procedures and establishment of oral hygiene.

FIG. 444.—Before and after treatment. Extensive pyorrhea with heavy subgingival calculi. Reaction good and case made prompt recovery following operative treatment.

A series of cases which have been treated in the manner which has been outlined, is shown in Figs. 442 to 451 inclusive. These cases have been selected from the college clinic and from private practice, the

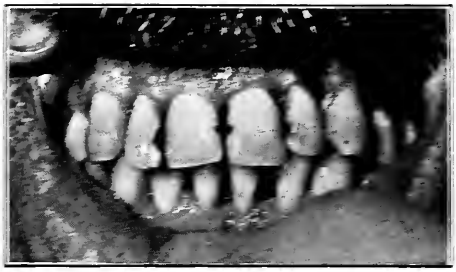

FIG. 443.—Case of severe pyorrhea about two years after treatment. No evidence of recurrence.

FIG. 444.—Mild case of pyorrhea three years after treatment. At time of treatment the interproximate gum tissue between the right upper cuspid and lateral incisor was deeply retracted and inverted. This tissue has since completely regenerated as shown in cut.

FIG. 447.—Case of severe pyorrhea associated with pronounced malocclusion. Five years after treatment. Equalization of bite with fixed bridgework and operative treatment has resulted in complete cure of the disease.

former group being handled largely by students assisted by the instructor in charge. Certain of the "before and after" pictures were taken within a few weeks of each other so that sufficient time had not elapsed to effect a complete cure but in each case there was a marked improve-

ment in the clinical appearance of the case, the pyorrheal invasion had been stopped, the lesions were healing and the case was evidently under

FIG. 448.—The Ht. Family—Father. Before and after treatment. Severe involvement, upper central incisor extracted, case under control one year later. Pictures taken one month apart.

FIG. 449.—The Ht. Family—Mother. Before and after treatment. Severe pyorrhea with mal-occlusion. Case under control one year later. Pictures taken one month apart.

FIG. 450.—The Ht. Family—Daughter, aged twenty-one. Before and after treatment. Incipient pyorrhea which promptly yielded to treatment. Pictures taken one month apart.

control. Many of them when kept under prophylactic supervision for some time continued to improve and much of the tissue which had been

lost in the course of the disease was restored by the healing process. Other cases which passed out of supervision for over one year were still in good condition and showed little or no evidence of active pyorrheal invasion. Figs. 445, 446 and 447 are pictures of finished cases of some five or six years' standing which originally had suffered from severe pyorrhea but which had shown no recurrence of that disease since the original operative treatment. Figs. 448, 449, 450 and 451 are interesting as they were taken from the members of one family, namely, father, mother and two daughters, aged twenty-one and fourteen respectively. Both father and mother had severe cases of pyorrhea, although not of the same type and both daughters showed beginning pyorrheal involvement of a type like that of the mother.

FIG. 451.—The Ht. Family—Daughter, aged fourteen. Tendency toward peridental disease similar to elder sister.

PERICEMENTAL ABSCESS.

In comparatively rare cases, abscesses are formed on the lateral surfaces of the roots of teeth which are seemingly unrelated to the apical or gingival areas. They occur on teeth in which the pulps and periapical areas are normal and may or may not be associated with pyorrhea. Two general classes of pericemental abscesses may be distinguished: first, those which are situated on roots of teeth which have been attacked by pyorrhea and which are virtually deep extensions of pyorrheal lesions some distance down the side of the root, and second, those which apparently are unaccompanied by any other peridental disease. In their course they may be marked by extensive inflammatory changes and swelling or they may develop in a gradual insidious manner without pain or other outward evidence of their presence. When they are purulent in type, the pus may burrow its way to the surface along the peridental membrane and be evacuated in the gingival crevice or a pyorrheal pocket, or it may penetrate the overlying submucous and mucous tissues to form a fistula on the lateral surface

of the gum after the manner of periapical abscesses. It is difficult to differentiate abscesses of the first type from true pyorrheal lesions and the latter type may be easily confused with true periapical abscess. On the surface of the root corresponding with the initial point of abscess formation the pericementum is denuded and usually a deposit of thin plate-like calculus may be found firmly adherent to the cementum. The source of these deposits and the deep infection in these peridental tissues is not clear. Pierce[1] found that many of the calculi answered to the murexid test for urates from which he concluded that they were laid down by the general circulation as the result of a uric acid diathesis. Kirk[2] found that in a number of cases which he examined the infection involved was a pure culture of pneumococcus. In many cases pericemental abscesses seem to be deep and penetrating forms of pyorrheal invasion in which the infection having burrowed into the tissues some distance beyond the apparent lesion, has produced at its farthest extension an acute exacerbation of tissue destruction accompanied by calcareous deposit. In other cases they occur on the roots of vital teeth about which there is no evidence of pyorrheal involvement. This latter form has been thought to arise from systemic or constitutional cause which may be associated with various local traumatic injuries such as malocclusion, excessive stress, accidents, etc. Indeed they seem to occur with greater frequency in individuals who suffer from certain systemic disturbances as gout, diabetes, Bright's disease, and other like affections. More recently it has been found[3] in cases of faulty oral hygiene when oral fermentations are high that microorganisms, especially the streptococcal type may penetrate deep into the pericementum without producing an apparent lesion. In view of this fact, it is possible to conceive that all pericemental abscesses may arise as the result of invasion of infectious organisms from the gingival crevice when the resistance of the peridental tissues against them is of a low order.[4]

The lesions formed by pericemental abscesses may be extensive, involving a considerable portion of the peridental membrane. The prognosis of these affections is extremely unfavorable especially in individuals who are suffering from constitutional or nutritional disturbances. In the favorable case, if the root be freed of calculi and carefully planed, slow healing may take place. The author has in

[1] International Dental Journal, 1894, p. 1.

[2] Dental Cosmos, 1900, p. 1149.

[3] Collins and Lyle, in the Journal National Dental Association, April, 1919, p. 370, state that they have found abundant evidence that periapical infection may arise from an extension of infected organisms from diseased gingival tissues.

[4] Roys claims that every case of pericemental abscess has a twisting, serpigenous tract by which it communicates with the gingival crevice and that it is along this tract that the infection enters the deep pericemental tissues.—Dental Cosmos, 1918, p. 659.

mind a case of pericemental abscess situated at the bifurcation of the roots of a lower first molar, in which healing was successfully accomplished in this manner and the bone which was involved largely regenerated as was shown by roentgenograms taken one year apart (Figs. 452 and 453). But many cases are presented which do not respond to the most careful operative technic and which persist in a state of active infection and suppuration as long as the tooth remains in position. For them the only remedy is extraction.

FIG. 452.—Roentgenogram of pericemental abscess at bifurcation of roots of lower molar, showing destruction of alveolar bone.

FIG. 453.—Roentgenogram of case shown in Fig. 452, one year after treatment by curettage, showing bone regeneration. Lesion healed.

VINCENT'S ANGINA.

Certain ulcerative affections of the oral tissues frequently may be confused with, and often erroneously diagnosed as, pyorrhea. Of these perhaps the most common type is a spreading diphtheria-like lesion which usually begins in the pharynx from which it spreads to the oral tissues. The specific organisms of this affection were identified by W. D. Miller in 1883 as the fusiform bacillus and an accompanying spirochete. Later Vincent more fully described the disease since which time it has been known as Vincent's Angina. He classified the lesions as belonging to two groups as follows:

A. "The superficial, pseudo-membraneous or diphtheroid form in which a thin grayish white film usually starts over one tonsil and gradually spreads, often over a wide area. Usually the membrane is easily removed, though not *en masse*, leaving a red bleeding base and a shallow ulceration. There is generally an associated diffused pharyngitis.

B. "The ulcerative, and more common form, in which there is deep tissue necrosis, covered by a thick, creamy, yellowish or gray exudate, which comes away easily and again leaves a raw, granular, bleeding base. This leads to the formation of crater-like ulcers with irregular, somewhat indurated and undermined edges."

This description is fairly comprehensive with the exception that the ulceration is not confined to the pharynx but rather does it frequently spread to the tissues of the oral cavity on which it produces its characteristic lesions. During the late war it occurred as an epidemic among the troops in a highly infective and contagious form, spreading throughout the camps and hospitals with great rapidity. Here it was known as "trench mouth" or "trench gums."[1]

Vincent's angina usually begins with a sore-throat and a diffused pharyngitis following which a thin white membrane spreads over the surface of the fauces which may or may not be accompanied by definite ulcerative lesions of the pharyngeal tissues. From this region the white film is extended toward the oral cavity which it encompasses by spreading along the buccal gums and gingival areas toward the anterior part of the mouth. In various locations ulcers may occur which form a creamy exudate, upon the removal of which a raw bleeding surface is revealed. These affections light up rapidly and exhibit a high degree of bacterial overgrowth so that within a few days all the tissues of the mouth may be involved by the inflammatory and ulcerative process. It is noted, however, that the patient is never as ill as the condition of the mouth might seem to warrant. Seldom does the temperature rise over 101° but in severe cases the patient suffers from extreme depression, pain in joints and loss of appetite. The author observed one case, that of a soldier, who refused to eat for two weeks. As the result of his fasting, combined with the severe Vincent infection, the patient became extremely emaciated and was for sometime in a very precarious condition.

In the mouth Vincent's angina may be recognized by a general inflammation of all the oral mucous membranes, accompanied by a characteristic white, pseudo-membrane on the gum tissues and deep ulcerations filled with white creamy exudate. The bacteriologic findings of material taken from the lesions reveal a mixed culture of organisms in which the fusiform bacillus and its accompanying spirochete greatly predominate (Fig. 454). Two forms of the B. fusiformis have been described, one a Gram-negative organism which has flagellæ and is motile, the other Gram-positive and non-motile, having a tendency to clump.[2] The bacilli appear thickened in the middle and pointed at both ends. They are always associated with a large spirochete with which they live in symbiotic relationship. These fusiform-spirochete cultures are anaërobic in type under which conditions they have been isolated and grown on artificial media. On the tissues they are associated with extensive ulcerations, but show no tendency to infiltration

[1] Barker and Miller: Jour. Am. Med. Assn., September 7, 1918.
[2] Hartzell: Journal National Dental Association, 1917, p. 477.

or metastasis. The relationship of these two organisms to Vincent's angina is not clear. Although they are always present in its lesions and disappear as they are healed, artificial production of the disease by inoculation of fusiform bacillus and spirochete cultures has never been accomplished. Moreover these organisms are frequent inhabitants of healthy mouths in which no evidence of Vincent's disease is apparent. This is especially true when the oral hygiene is poor and fermentations are high. But although accurate proof of the specificity of these organisms has not been forthcoming, the consensus of opinion today is in support of the view that the fusiform bacillus and its accompanying spirochete are at least essential factors in the production of Vincent's disease.

FIG. 454.—Fusiform bacillus aud spirochete from case of Vincent's angina.[1]

Although these conditions are severe in their course and present clinical pictures which are startling and alarming, they usually may be controlled and promptly arrested by the employment of relatively simple remedial agencies. In the great majority of cases the mouth hygiene has been faulty and quantities of food and other deposits are lodged about the teeth in which the infectious organisms are thriving in a high state of virulence. By simple prophylactic measures alone the infective process may be greatly reduced and many times it may be completely eradicated in this manner, no other treatment being necessary. To be effective, however, these prophylactic measures must be completely and carefully executed. All foreign matter must

[1] Simon in Adami and McCrae's Text-book of Pathology.

be removed from about the teeth and the gingival crevices. Special attention should be given to those localities which, by mechanical retention, offer breeding places for the Vincent organisms. In pyorrheal pockets and beneath the gum flap about partially erupted third molars, the organism may be retained to reinfect the mouth and bring on a recurrence of oral infection unless special attention is given to these areas. In addition to prophylactic measures a variety of therapeutic agents have been suggested for the control of the infection. Local applications of iodin, silver nitrate (10 per cent.), chromic acid (5 per cent.), zinc sulphate, hydrogen peroxid, wine of ipecac, Fowler's solution, salvarsan and arsphenamin, are recommended by various authorities as well as the systemic administration of arsphenamin and fusiform-spirochete inoculations. All writers agree that mercury in all forms is contra-indicated in these conditions as the drug tends to increase the virulence of Vincent's angina and actively interferes with its control.

The following method has been used successfully by the author in a large number of cases:

Swab the mucous membrane of the mouth and pharynx with cotton saturated with H_2O_2, in this manner mechanically remove the white pseudo-membrane.

Superficial oral prophylaxis, care being taken not to injure the soft tissues.

Cleanse ulcerative lesions and remove slough with cotton swab saturated with silver nitrate (10 per cent.), or argyrol (25 per cent.).

Swab the mouth with iodin lotion (p. 161).

Instruct the patient to rinse the mouth every three hours with hydrogen peroxide (1 per cent.) followed by potassium permanganate 0.5 per cent. and swab mucous membrane with cotton to remove the infective film.

If the lips are cracked and peeling they may be painted with tincture of iodin.

At subsequent sittings the oral prophylaxis should be completed as soon as the condition of the soft tissues will allow. Swab with iodin lotion.

These measures should be continued until all evidences of inflammation have disappeared.

Finally, all residual nests of organisms should be eradicated. Diseased tonsils and impacted or partially erupted third molars are favorite breeding grounds, which frequently must be removed to permanently control the infection.

In a great majority of the cases a careful performance of these measures will result in the immediate improvement of the diseased

tissues and a rapid return to health, complete recovery even of severe cases frequently occurring in a few days or a week (Fig. 455). When the infection still persists for some time after treatment, or periodically recurs after a temporary abatement, it is very probable that either the prophylactic measures have been incompletely performed or some hidden breeding ground exists from which the mouth is continually being reinfected. When Vincent's disease is associated with pyorrhea the treatment is not so simple a matter and complete eradication of the specific organism cannot be accomplished without concurrent treatment and obliteration of the pyorrheal lesions.

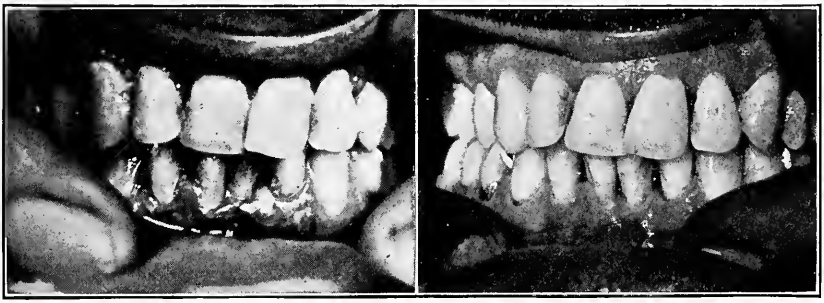

FIG. 455.—Before and after treatment of a case of severe Vincent's angina. Pictures taken six weeks apart.

RETRACTION OF THE GUMS.

In this connection we should consider certain conditions which result in the shrinkage and retraction of the gum tissues about the teeth and which are often erroneously considered as pyorrhea alveolaris. It is a matter of common observation that the gingival margins about the teeth may be retracted exposing more or less of their roots without the formation of subgingival pockets. The process is essentially that of a deflection of the gingivæ, apically, along the roots of the teeth, the remaining peridental tissues appearing quite like the normal. This retraction of the gum may take place about one tooth, or may occur about several or all of the teeth in the mouth. These changes in the gingival contour are not due solely to shrinkage of the gum tissues, but are associated with degenerative changes in the alveolar crest of bone by which the bone is reduced in size and the overlying gum tissue and gingivæ sink down with it exposing the cementum of the root to which the free border of the gum is firmly attached. Since no subgingival pockets are formed these lesions are not pyorrheal in type and should not be confused with that condition. They occur in several different forms which may be grouped as follows:

Senile Atrophy.—In individuals past middle age the gum margins frequently are retracted from the normal positions on the tooth and a portion of the cementum is exposed. In these cases the crest of alveolar bone has undergone senile atrophy, and as a result, the gums and gingivæ on all sides of the teeth gradually settle down to lower and lower levels about the roots. A very similar condition may arise in earlier years from a premature or precocious senility of the individual. If the mouth and teeth are kept clean and free from irritating agents senile degeneration of the peridental tissue takes place slowly and is of little significance other than that it may be followed by sensitivity of the root surfaces and an unsightly appearance of the teeth.

Traumatism.—A similar retraction of the gum tissues on the buccal and labial surfaces of the teeth frequently occurs as the result of excessive and improper tooth-brushing. When the teeth are brushed

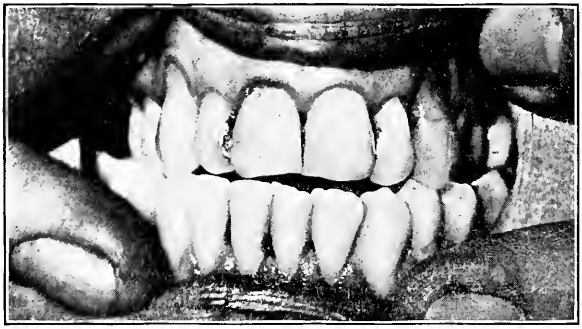

FIG. 456.—Severe labial recession from tooth brush abrasion.

vigorously in a cross-wise manner undue stress is placed upon the gingivæ with the result that degenerations may take place in the underlying tissues and the gingival border is retracted. These lesions occur at the site of the irritation and are usually associated with a lesion in the enamel of the tooth due to tooth brush abrasion (Fig. 456).

Traumatic retraction of the gum tissues about the teeth may be produced also by the encroachment of calculi on the gingivæ by operative procedures, crowns, fillings, etc., and by the abnormal excursions of food in mastication. Examples of the latter are seen in cases in which the normal proximate contact of the teeth is lost by reason of which food is habitually crowded between them in mastication and the interproximate gum tissues are severely injured (Fig. 106). So also in those cases in which the teeth do not have a proper buccal or lingual contour the gingivæ may be accidentally torn in the act of biting some hard substance and future irritations of food may continue

the retraction for a considerable distance down the side of the root (p. 167). If the oral hygiene be poor, these forms of traumatic gum retraction may develop into true pyorrheal lesions at the site of injury and they should always be considered as factors predisposing to that disease (Fig. 457). In the case of tooth-brush abrasion, a correction

FIG. 457.—Severe labial recession on lower right cuspid from the traumata of food and pyorrheal involvement.

of the manner of brushing the teeth will usually suffice to prevent further recession of the gum. Retractions from the traumatism of calculi and irritations of food, fillings, etc., may be arrested in their progress by a careful and complete removal of the irritant or a correction of faulty tooth contours, but the lesion which has already been

FIG. 458.—Before and after treatment of case of Vincent's angina showing regeneration of interproximate gum tissues in bicuspid region. Two pictures six months apart.

accomplished usually remains as a permanent defect. In acute cases in which the alveolar bone is not seriously affected, a removal of the irritant may result in a regeneration of the interproximate gum tissues, but rarely are they replaced on the buccal or lingual surfaces of the teeth.

Ulcerative Gingivitis.—Occasionally a rapidly growing superficial type of infection may produce an ulceration of the free margins of the gums by which they are eroded and retracted. The fusiform bacillus in Vincent's angina frequently produces lesions of this type. The interproximate tissues suffer most severely, becoming inverted while the labial and lingual borders are retracted to expose the cementum. By careful prophylactic measures and the establishment of oral hygiene these ulcerations may be promptly arrested and if they have not progressed far enough to seriously affect the alveolar bone the eroded gum tissues usually will be regenerated and restored to their normal form (Fig. 458).

Healed Lesions of Pyorrhea.—Following the successful treatment of pyorrhea it will be found that, as a rule, the gum tissues have shrunken about the teeth. This is due to the fact that in the removal of the peridental irritations the gingival circulation is stimulated, congestion and inflammatory derangements are abated, and the swollen tissues shrink to their normal thickness. Since in the process of the disease the underlying bone tissues have degenerated and decreased in size the overlying gum tissues which cover them will consequently fall away from the neck of the teeth and attach themselves to the roots at a line farther apically than is normal. It follows, therefore, that in all cases of severe pyorrhea, when as the result of successful treatment the peridental tissues have become attached to the roots and the subgingival pockets obliterated, a new gingival line will be formed which will be retracted from the normal position (Figs. 435, 437, 447 and 448). These post-pyorrheal gum retractions if properly cared for and kept free from excessive irritations form permanent attachments to the cementum and constitute the most effectual approach to healing of pyorrheal lesions.

CHAPTER XIV.

EXTRACTION OF TEETH AND OTHER SURGICAL PROCEDURES.

By CHALMERS J. LYONS, D.D.Sc.

Surgical Anatomy.—To extract teeth successfully, the operator should be in possession of a thorough knowledge of the anatomy of the teeth and surrounding parts in order that the forces in the line of least resistance may be applied intelligently. The relation of the teeth to the maxillary sinus, the character of the bone, the importance of the canine eminence, the canine fossa, and the surfaces of the bone in the upper jaw, as well as the relation of the teeth to the inferior dental canal, the positions of the mental and mandibular foramina, together with the study of the character of bone and the relation of the teeth to the coronoid process in the lower jaw, are all matters which will be great aids in the success of the operation of extraction of teeth.

The Relation of the Teeth to the Maxillary Sinus.—"Because of the close anatomical relation of the maxillary sinus with the tooth germs and the roots of the permanent teeth, it is evident that the sinus must be more or less influenced by them. As the teeth develop and descend into their normal position, the sinus increases in size. If a tooth situated near the sinus be retarded in its eruption, the development of the sinus is interfered with at that particular point."[1] Fig. 459 shows how closely the apices of the teeth may be associated with the maxillary sinus. Particularly is this true with the first and second bicuspids and first molars. In rare cases the apical end of the root of the cuspid and the second and even the third molar may encroach upon the antral cavity. Infection about the roots of these teeth may, and frequently does, give rise to morbid conditions in the maxillary sinus.

In the extraction of the upper first molar, care should be exercised that a portion of the floor of the antrum is not fractured away during the operation. The roots of this tooth passing up on both sides of the antral cavity predispose to such an accident. In the extraction of the roots of the upper bicuspids the same care should be exercised that they are not forced through the floor of the maxillary sinus in the endeavor to engage them in the forceps.

[1] Cryer: Internal Anatomy of the Face.

Character of the Bone of the Maxillæ.—The alveolar process of both upper and lower jaws consists of an outer and inner plate of dense cortical bone. Between these two plates are the sockets for the roots of the teeth. The sockets are surrounded by a very thin layer of cortical bone, and the remaining portion of the alveolar process between the outer and inner plates is filled in with cancellated or spongy bone. Running through this cancellated or spongy bone are fine canals for nerves and bloodvessels, the remaining portion of it being connective tissues. The surfaces of the outer and inner plates have no definite line of demarcation between the maxillæ proper and the alveolar

Fig. 459.—(Cryer.)

process, but continue from the cervical margin over on the maxillæ and are lost on the outer and inner surfaces of these bones. The alveolar process is covered with muco-periosteum, which is thick and dense and contains mucous glands. This covering is commonly known as gum tissue. The bone proper is covered with true periosteum. Fig. 460 shows the anterior view of a normally articulated skull. It may be seen that the central incisors are in close proximity to the suture which unites the right and left maxillæ. This is important knowledge for the operator when extracting under local anesthesia. (See Chapter XII.) The outer plate covering the lateral incisors is very heavy because the labio-lingual diameter of the lateral incisors is less than

that of the teeth on either side. The outer plate of the alveolar process is deflected from the cuspid tooth over on the central incisor tooth. A depression results from this deflection and forms the incisive fossa.

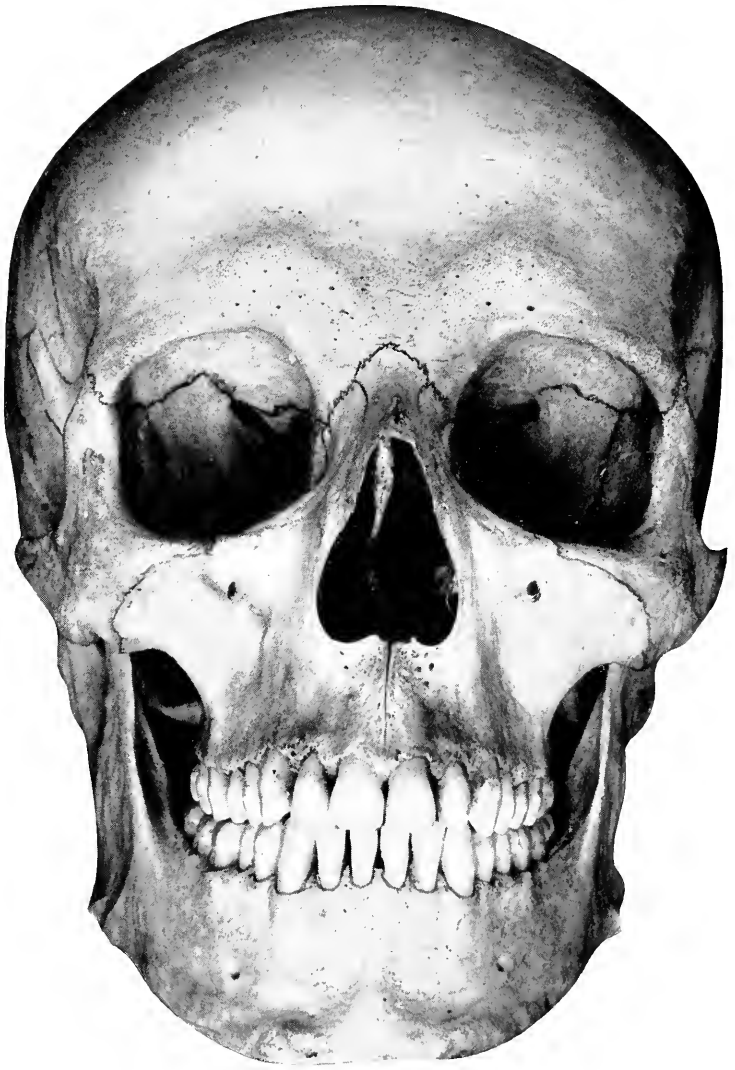

FIG. 460.—Anterior view of the typical skull. (Cryer.)

The Canine Eminence.—In viewing the anterior surface of the skull we may observe a heavy bony structure extending over the cuspid teeth (the canine eminence). This varies in thickness in individuals

and must be taken into consideration in the extraction of the cuspid teeth.

The Canine Fossa.—The canine fossa marks the thinnest part of the outer plate of the superior maxilla and forms the outer wall to the maxillary sinus. This plate is extremely thin in old age and in such a case great care should be exercised in the extraction of the bicuspids and molars, that this surface be not injured and the antral cavity exposed.

The Infra-orbital Foramen.—This foramen, through which the infra-orbital nerve emerges on the face, lies above the canine fossa. It becomes an important landmark in the use of conduction anesthesia for the extraction of the anterior teeth. (See Chapter XII.)

FIG. 461.—Zygomatic surface of superior maxilla.

The alveolar process of the superior maxilla is less dense than that of the inferior maxilla, which condition usually renders extraction of teeth less difficult than in the inferior maxilla.

The posterior or zygomatic surface of the superior maxilla assists in the formation of the spheno-maxillary fossa and presents the tuberosity, which is a rounded prominence above the third molar tooth (Fig. 461). This part of the superior maxilla contains innumerable fine canals for the accommodation of the nerve and bloodvessels. The tuberosity varies in size in each individual and may vary on the two sides of the jaw in the same individual.

Palatine Surface.—The landmarks on the palatine surface of the superior maxilla which should be observed in the extraction of teeth, are the foramina of scarpa which are located one centimeter distal to the central incisor teeth and the posterior palatine foramina which are located about one centimeter toward the median line from the upper

third molar teeth (Fig. 462). The nerves and vessels supplying the hard and soft palates emerge at these points.

FIG. 462.—Anterior portion of the base of a typical skull. (Cryer.)

Inferior Maxilla.—The exterior of the bone and landmarks of the inferior maxilla or mandible should be studied by the operator. The alveolar process of this bone being more dense than that of the superior maxilla, extraction of the teeth will be more difficult.

Mental Foramen.—About five millimeters below the bicuspids and two millimeters in front of the second bicuspid the mental foramen may be found (Fig. 463). This point is considered the weakest point in the mandible and fractures of the jaw through this area are more common than at any other point. Posterior to the mental foramen the alveolar process becomes very dense and heavy, consequently the lower molars are usually more difficult to extract than any of the

other teeth. Also, on account of the density of the alveolar process, infiltration anesthesia for extraction of teeth in this region becomes less satisfactory. (See Chapter XII.)

Fig. 463.—The right side of the lower portion of face. (Cryer.)

Mandibular Foramen.—On the inner surfaces of the mandible on a line with the occluding surfaces of the teeth and about half-way between the coronoid and condyloid processes, there is an important foramen (the mandibular) (Fig. 464). This foramen marks the entrance of the inferior dental nerve and vessels into the mandible. Arising from the body of the mandible are two processes, the one in front being the coronoid, and the one behind, the condyloid process. Arrested development of the inferior maxilla will result in the crowding and impaction of the teeth. In the process of development of the mandible, room for the normal eruption of the first, second, and third molars is provided by the physiologic absorption of the anterior surface of the coronoid process. Not infrequently a pathologic condition arises which interferes with this process of development and this knowledge is necessary for the operator in determining the degree of force and direction of the application of it in the extraction of the inferior teeth.

Indication and Contra-indication for Extraction.—The conditions which should govern the practitioner in determining the indication and contra-indication for the extraction of teeth are so varied that it is not practicable to formulate any hard and fast rules that will apply in all cases. Not only the local conditions but the general systemic conditions of the patient must be considered in determining whether or not the teeth should be extracted. There seems to be quite a diversity of opinion at this time as to the exact status of pulpless teeth. Some operators go so far as to state that all pulpless teeth are a menace to the welfare of the patient and that such teeth should be extracted; others believe that under certain conditions pulpless teeth can be made safe if properly treated and that the patient will be able to retain them indefinitely. In view of the recorded data on this subject, it would

FIG. 464.—Inner surface of the inferior maxilla. (Cryer.)

seem that in determining the indication or contra-indication for the extraction of such teeth the physical condition of the patient and the strategical importance of the teeth, respectively, should be the deciding factors. Some of the most important causes which demand extraction of the teeth are as follows:

1. Molar teeth which have lost their occluding teeth in the opposite jaw and are partially exfoliated from their alveoli and are becoming a source of annoyance. When such a condition occurs in the bicuspid region, the vacant space in the opposite jaw should often be filled with an artificial tooth to prevent the exfoliation of the natural tooth.

2. Multi-rooted teeth with chronic alveolar abscesses, when Roentgenographic evidence shows disease and death of the pericemental membrane in the apical area. In single-rooted teeth this condition may be

taken care of by apicoectomy,[1] provided the physical resistance of the patient indicates it. Extraction is indicated in any single-rooted tooth wherein there is evidence of disease or death of the pericemental membrane extending over more than the apical third of the root. Such a condition would preclude the possibility of saving the tooth by apicoectomy.

3. Malposed teeth which cannot be corrected by orthodontic measures so as to become useful.

4. Pulpless teeth with constricted or crooked canals which will prevent their proper treatment.

5. Teeth in which the pulps are encroached upon by pulp stones and cannot be properly treated.

6. Unerupted teeth which are apparently lying dormant in the jaws or where they are causing a dental cyst. The possibility of these teeth giving rise to morbid conditions always makes their removal desirable.

7. Lower third molars which are partially erupted and are causing the surrounding tissues to be impinged upon by the occluding teeth, so that inflammation results periodically.

8. A tooth that is partially or completely impacted and is impinging upon another tooth may be the seat of extreme nervous disturbances with manifestations remote from the impacted tooth; an impacted tooth that is causing partial resorption of the tooth upon which it is impinging; and an impacted tooth that is the seat of a periodical inflammatory process.

9. When preparing a mouth for an artificial denture, the removal of sound healthy teeth may be indicated for the purpose of making a more efficient denture.

10. Teeth which have become loosened by any inflammatory process to such an extent that a considerable portion of the alveolar process has been lost. This condition may be applied to roots that have supporting crowns and bridges that have become loosened due to some pathologic condition.

11. Deciduous teeth which are retained after the time of their normal exfoliation and are preventing the eruption of the permanent teeth.

12. Abscessed deciduous teeth which will not respond to treatment and are a menace to the health of the patient. It will sometimes tax the judgment of the operator to choose the right method of procedure in these cases. If the tooth be extracted before the normal time for the eruption of the permanent tooth, mal-occlusion may result; if not extracted, the patient's health may be impaired.

13. Supernumerary teeth that are of no particular value and are interfering with the normal eruption of the permanent teeth.

[1] This subject is treated fully at the end of the chapter.

Contra-indications for the Extraction of Teeth.—A careful examination of the whole mouth should be made before extraction of any of the teeth is begun so that a needless sacrifice of tooth function will not be made. The demand that a tooth be extracted should not be taken into consideration, because a patient's knowledge of mouth conditions is necessarily limited, and the patient is not capable of judging the value of the tooth in question. The operator's judgment should always prevail. Many times a small cavity in an otherwise perfectly normal tooth may be causing the patient considerable pain, and the patient, not placing the proper importance on the tooth, may request its removal. It should be considered bad practice to accede to the patient's wishes in these matters unless by so doing the patient's future welfare will be better taken care of. The operator should decline to remove a tooth that is of any value to the patient. The patient's future welfare must always be uppermost in the operator's mind when determining the indications and contra-indications for the extraction of teeth. Some of the most important contra-indications for the extraction of teeth are as follows:

1. Often when preparing a mouth for an upper or lower denture, certain teeth, such as upper or lower cuspids that are in good alignment, will help to retain the artificial denture and should not be extracted.

2. With patients of advanced age who have lost bicuspids and molars, where there has been marked resorption of the alveolar processes and the remaining teeth are worn down by mechanical abrasion, it is sometimes a debatable question whether the patient's welfare will be better taken care of by extraction, or by leaving the teeth in the mouth and depending upon the abraded surfaces for mastication. In such cases, artificial dentures are not usually very satisfactory.

3. The extraction of a tooth is contra-indicated in patients who have organic heart lesions such as valvular insufficiency, hypertrophy, and fatty degeneration. The shock from extractions in such cases may result fatally to the patient. When it is necessary to extract teeth under such conditions, the patient's physician should be present.

4. In cases of abscessed teeth, which are to be extracted when the operator is assured that the abscess can be evacuated by the removal of the tooth, extraction is always a safe procedure. But in certain other cases of acute alveolar abscess where there is extreme cellulitis and the patient is suffering from septic intoxication, when the probabilities are that the extraction of a tooth will not evacuate the abscess, and the possibilities are that the extraction of a tooth will turn septic intoxication into septicemia, extraction is contra-indicated. In these cases palliative treatment should be instigated and continued until normal conditions are reëstablished.

5. Often in partially unerupted third molars the gum tissue overlying the occluding surface of the third molar will become bruised as a result of mastication, and an irritation will be set up which will later cause an inflammatory process followed by trismus. It is good practice to treat the condition and allay the inflammatory process before extracting the tooth.

6. When a patient with a history of profound bleeding presents for extraction, great care should be exercised against extracting too many teeth at one time. Whenever possible a general treatment should be instituted. The administration of calcium lactate in ten-grain doses, three times per day for three or four weeks preceding the operation will sometimes yield good results. These patients should be put under the care of a physician before extraction of the teeth.

7. In all cases of pregnancy the operation should be postponed, if possible. In cases when it is necessary to remove one or more teeth for the comfort of the patient, it should be done under the order, and if possible, in the presence of the family physician.

8. The shock of extraction of teeth for epileptics may bring on an attack. When it is necessary to extract teeth for these patients, they should be watched following the operation. Should an attack follow, the patient should be laid in a comfortable position with plenty of fresh air, and the condition should not be considered alarming.

Other conditions may arise where the judgment of the operator may be taxed to the utmost in order to determine the right course to pursue. The present general health of the patient, the resistance of the patient to disease, the question of the patient's future welfare following the sacrifice of a tooth are all factors that must govern the operator in determining the operative procedure. The operator should endeavor to make a judicious diagnosis in every case. In many cases a complete physical diagnosis by a physician may be necessary to complete the chain of factors which must be considered in determining the indications and contra-indications for the extraction of certain teeth.

Management of the Patient During the Extraction of Teeth.—There is probably no minor operation in surgery that the average patient looks upon with so much fear and dread as that of the extraction of a tooth. The patient comes into the office in a nervous condition and the first duty of the operator is to get the patient's mind in a condition for the operation. With young children it is bad practice to promise a painless operation when the operator knows that he cannot do it. These children will be the future patients, and once their confidence in the dentist is lost, it is sometimes hard to regain. The operator should never manifest nervousness before his patient. If the

operator feels absolute confidence in his own ability, this will be imparted to the patient.

Position of Patient.—The patient should be made as comfortable in the chair as possible, and should then be placed in a position with the principal object of securing a good view of the affected tooth and the surrounding parts. The position of the patient and operator will vary slightly for the extraction of each tooth. The tooth to be operated upon should be in full view of the operator, and the head of the patient in such a position that it can be steadied and controlled by the left arm and hand of the operator. The modern dental chair is the best apparatus obtainable upon which the operation can be made. At times it may be necessary to extract teeth while the patient is in bed or on an operating table. In such cases, the position of the patient may not always be the most desirable one, and the operator will have to adjust his position to meet the requirements. When operating on a table, the best position for the operator is at the head and a little to the right side. The position of the patient and operator will be taken up in detail in the description of extracting individual teeth.

Extraction of Individual Teeth.—We will first consider extraction of the superior teeth. As a rule, this operation is not so difficult as the extraction of the inferior teeth, for the reason that the superior teeth are more accessible and the alveolar process is not so dense. The forceps are the principal instruments used in the extraction of superior teeth. Occasionally chisels, elevators and drills may be used to advantage in the removal of roots and unerupted and impacted teeth.

The position of the operator when operating on the superior teeth is to the side and slightly to the front of the patient's head when extracting on the right side, and a little in front of this position when extracting those on the left side. The order of extraction may be made a matter of preference with the operator. Usually the field of operation can be kept in sight better if he proceeds from the anterior to the posterior, first on the left, then on the right side. The position of the patient for operating on the superior teeth should be erect and the patient raised in the chair to such a height that the patient's head comes just below the shoulder of the operator after the chair has been tilted slightly back. The head may be turned from one side to the other as conditions will require. Usually all of the teeth can be extracted without changing the adjustment of the chair after it is once made.

Extraction of Superior Central Incisor.—Fig. 465 shows position of operator and patient for the removal of superior central incisors. The left arm of the operator is placed upon the head of the patient with the palm of the hand over the left cheek. The upper lip is raised to show the field of operation with the index finger. The second finger

is used as a retractor for the purpose of retracting the cheek. The palm of the hand and remaining fingers support the jaws. This position of the hand and arm enables the operator to hold the patient's head securely during the operation. The forceps usually employed in the extraction of superior incisors are those shown in Fig. 479. The forceps are adjusted to the labial and lingual surfaces of the central incisor and forced upward under the free margin of the gum to the edge of the alveolar process. The handles of the forceps are then

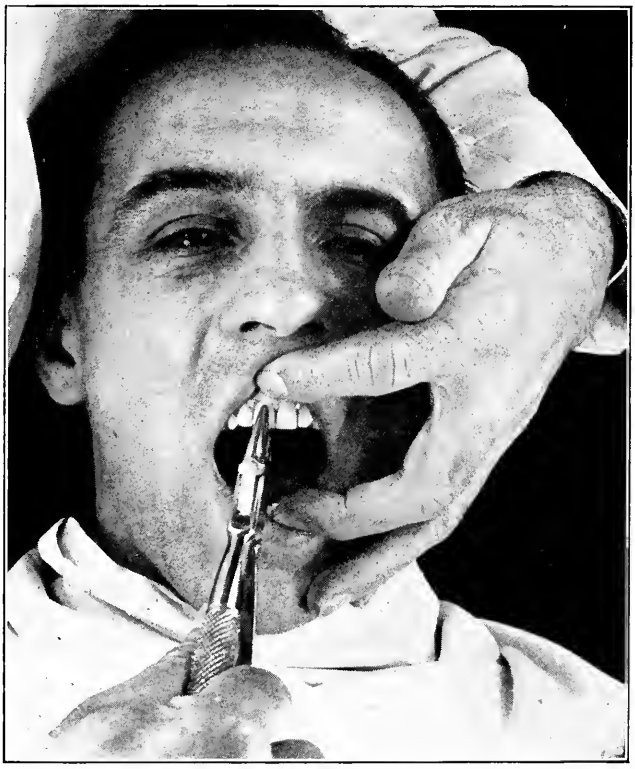

FIG. 465

gripped firmly and by the force of rotation slightly to the left, then to the right, the tooth is loosened from its attachment and by a slight force of traction the tooth is lifted from the socket. The forceps should be adjusted in a direct line with the long axis of the tooth. If this is not done, fracture of the tooth may result.

Extraction of Superior Lateral Incisor.—This tooth is much smaller than the central. Its root is somewhat more flattened and sometimes curved. The apex of the tooth often curves distinctly toward the

cuspid. The position of the patient and operator is practically the same as for the extraction of the central incisor. The same forceps may be used, and should be adjusted in the same manner as that described in the extraction of the central incisor. The forces used are slight rotation, a little pressure labially and lingually, and slight traction. The neck of this tooth is sometimes restricted to such an extent that some precaution must be exercised that it is not fractured.

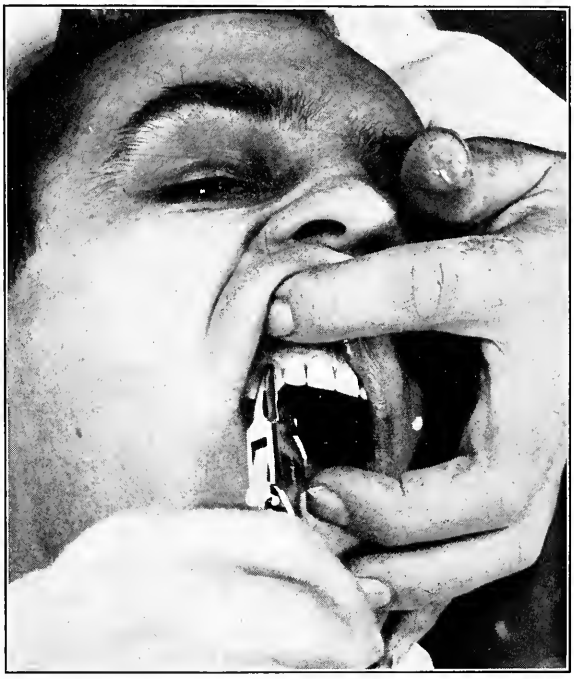

FIG. 466

Extraction of Superior Cuspid.—Fig. 466 shows the position of the patient and the operator for the extraction of the superior cuspid on the right side. Fig. 467 shows the position of the patient and the operator for the extraction of the superior cuspid on the left side. This tooth is one of the most difficult teeth in the upper jaw to extract on account of its thickness labio-lingually and the length of its root, and considerable force is often required to break up its attachment on account of the density and thickness of the alveolar process surrounding it. The position of the patient is the same as for the extraction of the central and lateral incisors. The position of the operator when extracting on the right side is slightly back of the position for the central and lateral, and when extracting on the left side it is slightly in front of

this position. The same forceps are used for the extraction of the cuspids as for the lateral and central incisors, and are applied to the tooth in a similar manner, care always being taken to force the forceps well up under the gingival margin. The forceps should be grasped with much more firmness than is required for the extraction of the central or lateral incisor. Pressure labio-lingually applied with an out-and-in motion and at the same time slightly rotating will usually break up the attachments. Slight force of traction is then used to remove it from its socket. The cuspid next to the lower third molar is more often

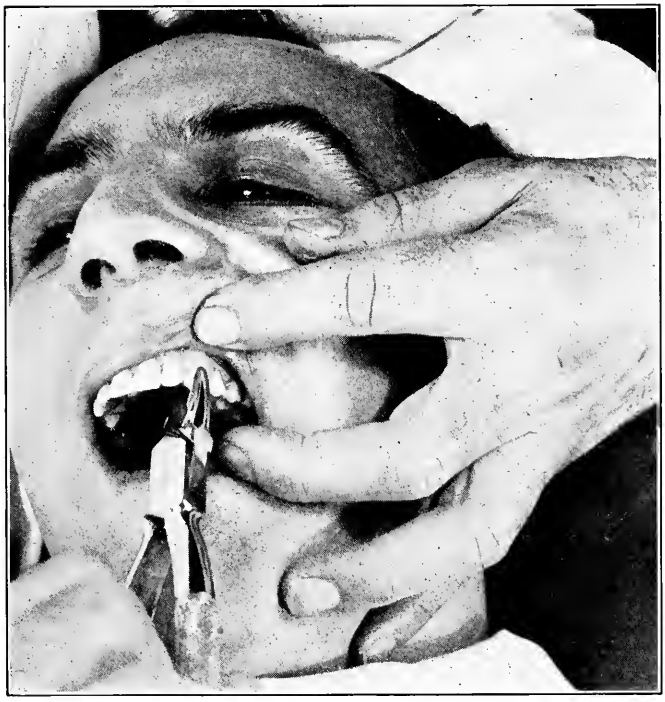

FIG. 467

impacted or unerupted than any other. The details of the operation for the removal of unerupted and impacted cuspids will be taken up under the subject of unerupted and impacted teeth.

Extraction of Bicuspids.—Superior first and second bicuspids. Fig. 468 shows the position of the patient and the operator for the extraction of superior bicuspids on the right side. Fig. 469 shows the position of the patient and the operator for the extraction of superior bicuspids on the left side. The technic of the operation for the extraction of the first and second superior bicuspids is practically the same.

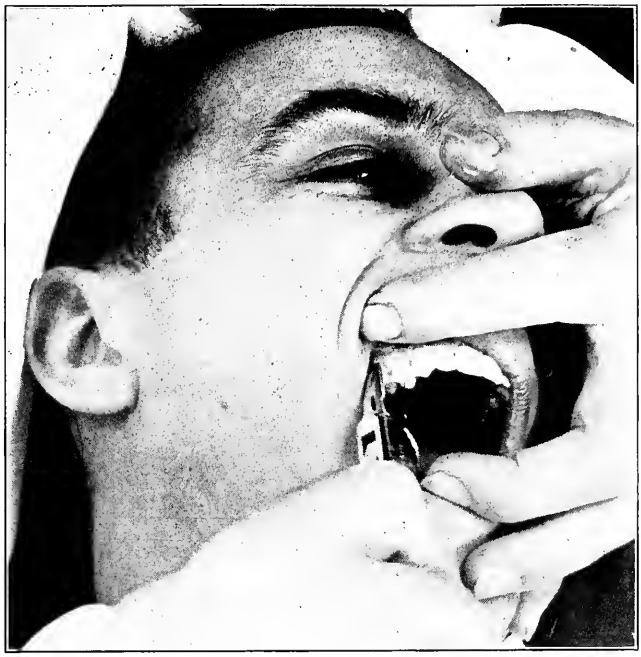

FIG. 468

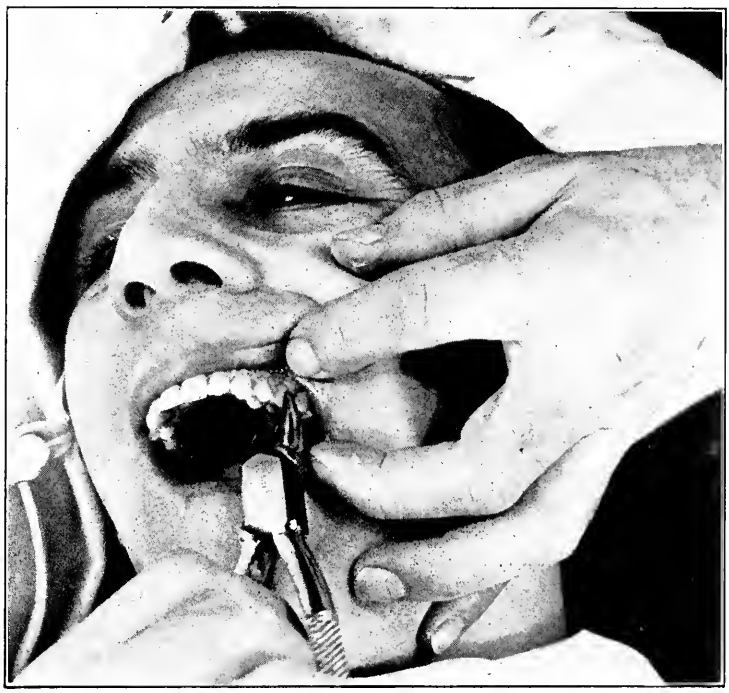

FIG. 469

The position of the patient in the chair, and that of the operator is practically the same as that described for the extraction of the cuspid tooth. The main difference is in the position of the patient's head; when operating on the right side, the patient's head should be turned to the left, and when operating on the left side, the patient's head should be turned slightly toward the operator. The forceps used for this operation are those shown in Fig. 479. The movements used in the extraction of the bicuspids are to the buccal and lingual, for the purpose of loosening its attachment. In exerting such force more

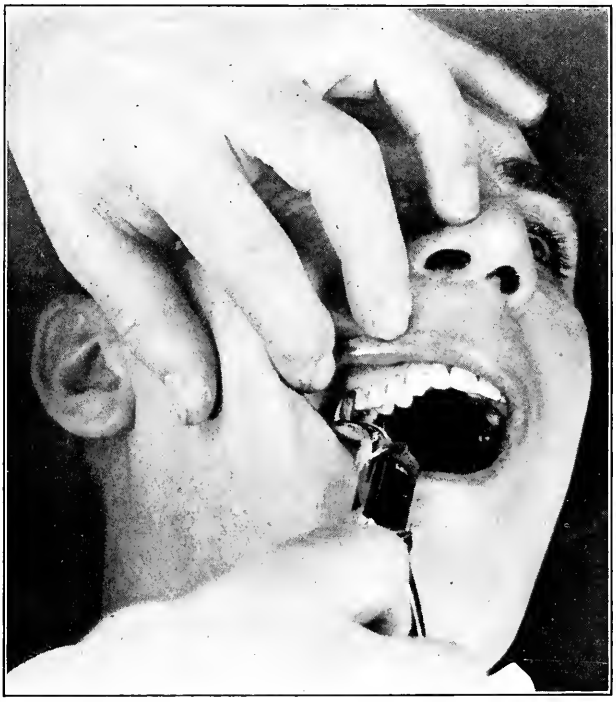

FIG. 470

pressure should be exerted to the buccal than to the lingual for the purpose of springing the external plate of the alveolar process. After the attachments are loosened the force of traction should be used. On account of the shape of the roots of the first and second bicuspids, the force of rotation should never be used because it may result in fracture of the roots.

Extraction of Superior First and Second Molars.—Fig. 470 shows the position of the patient and the operator for the extraction of superior molars on the right side. Fig. 471 shows the position of the patient and

the operator for the extraction of superior molars on the left side. The technic for the operation of extracting the first and second molars, is practically the same and will be given together. For extraction of superior molars the relative position of patient and operator is similar to that for extraction of superior biscuspids. The forceps used are two in number, one for the right side, and the other for the left side. These are shown in Figs. 480 and 481.

The beaks of the forceps should be adjusted to the tooth in line with its long axis and forced well up under the free margin of the gum,

FIG. 471

sufficiently so that the point of the buccal beak passes between the buccal roots. The force used in this operation is pressure first to the buccal, then to the lingual then with an in-and-out motion the tooth may be loosened from its attachment. Here again greater pressure should be brought to bear on the buccal so that the buccal plate may be sprung slightly outward, thus loosening the tooth from its attachment. Then again because of the shape of the roots of the molar teeth, it is not practicable to bring a great deal of pressure to the lingual on account of the long lingual root which would oppose pressure in that direction. After loosening the tooth from its attachment,

slight force of traction is used to dislodge it. On account of the shape and number of the roots, the force of rotation should never be used since there is danger of fracturing one or more roots.

Extraction of Superior Third Molars.—The position of the patient and the operator will be the same as that for the extraction of the first and second molars. The forceps used may be the same or may be especially designed for superior third molars as shown in Fig. 482. The normal superior third molar is usually not a difficult tooth to extract on account of the porosity of the alveolar process surrounding it. The roots are usually fused together. The forceps should be adjusted well up under

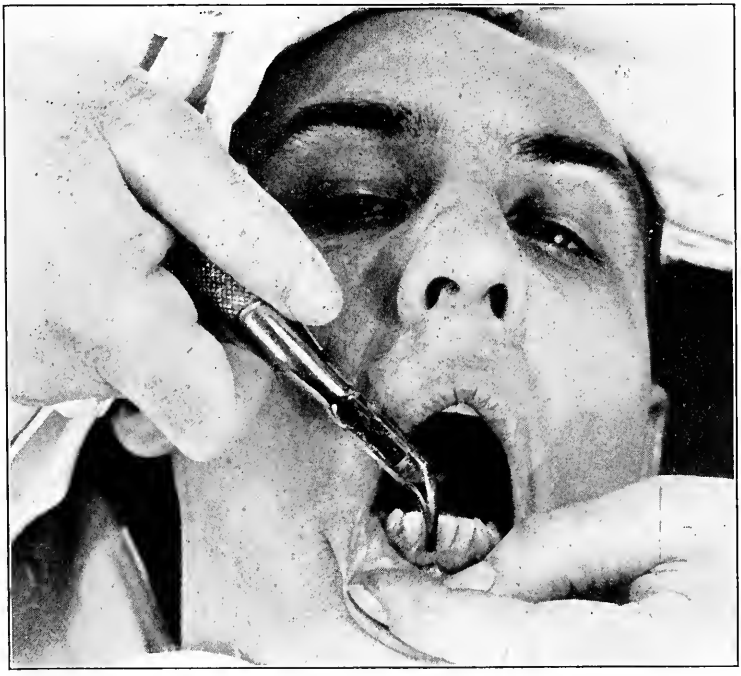

Fig. 472

the gingival margin and the forces used should be pressure buccally and lingually applied with an in-and-out motion, and with a slight rotation to the buccal with more pressure brought to bear on the buccal than the lingual, the force of traction being used for the purpose of removing the tooth. Occasionally the roots of these teeth are spread widely apart and in these cases extraction becomes more difficult. In some cases the gum tissue is very adherent to the distal surface of the upper third molar and great care should be used not to lacerate the soft tissues when extracting this tooth.

Extraction of Inferior Teeth.—As a general rule, the extraction of the inferior teeth is attended with more difficulties than that of the superior teeth, since they are less accessible to the operator, and their surrounding tissues are more dense. The tongue also may sometimes interfere with the operation. The position of the patient is different from that for the extraction of the superior teeth. Fig. 472 shows the position of the patient and the operator for the operation of extracting the inferior incisors. The head of the patient should be much lower than

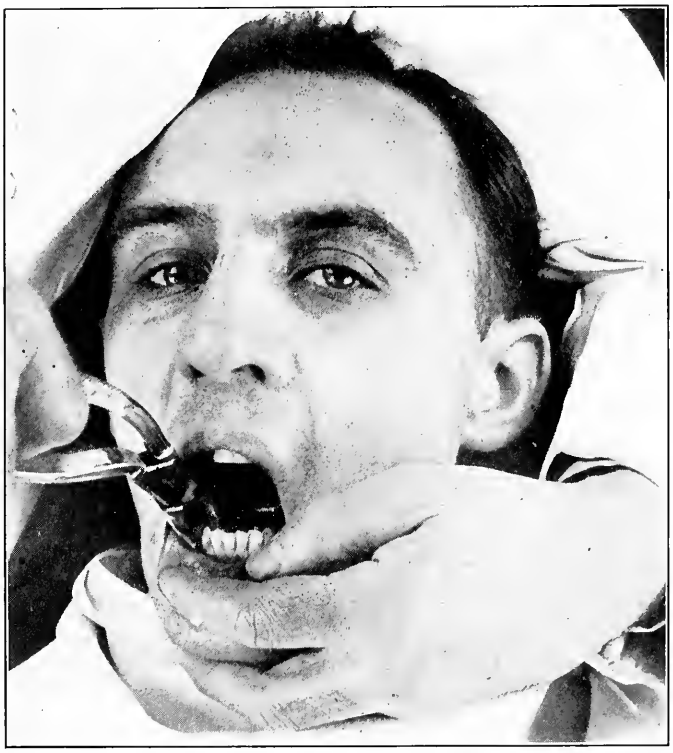

FIG. 473

for the extraction of the superior teeth. The operator should stand at the back and slightly to the right of the patient. The patient's head should be straight in the head-rest. The left arm of the operator is placed around the patient's head with the palm of the hand supporting the lower jaw. The fingers of the left hand are used to retract the lips. In the application of the forceps to the tooth, the same general principles should govern the extraction of an inferior tooth as those governing the extraction of a superior tooth. The beaks should be in line with the

long axis of the tooth at all times. When all of the inferior teeth are to be extracted, the central incisor should be extracted first, then all of the teeth on the left side distally to the molars, and then beginning at the right lateral incisor, all the teeth distally to the molars on the right side. Then the molars first on the right, then on the left should be taken in their order. The lower jaw should have firm support by the left hand of the operator. The jaw itself being movable, some difficulty may be experienced in holding it rigid while the operation is in progress.

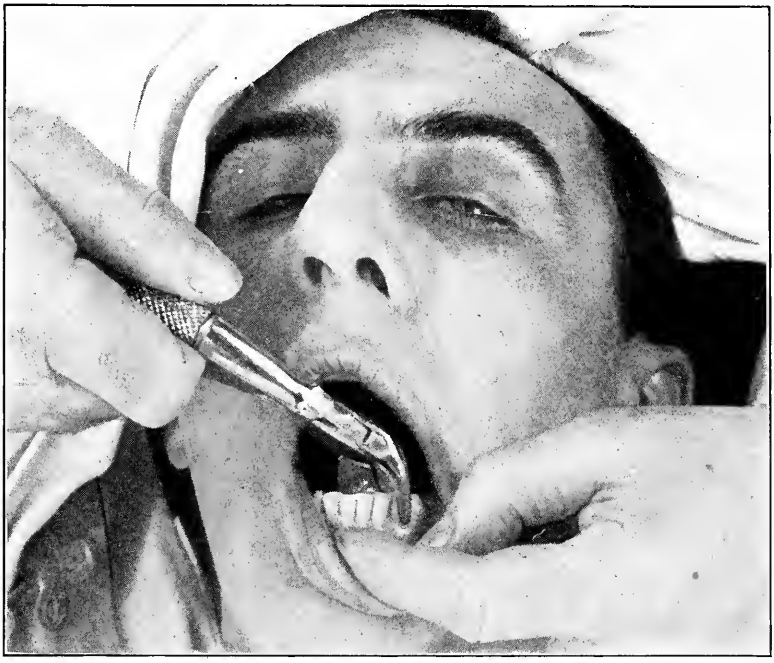

FIG. 474

Extraction of Individual Teeth.—Extraction of inferior lateral and central incisors. As the inferior central and lateral incisors are very similar in shape and size, the technic for their removal will be described together. Usually these teeth are not very difficult to extract, their roots being slightly conical in shape. Slight rotation may be indicated combined with pressure to the labial. These movements will loosen the attachments. Then by the force of traction the tooth may be removed from the socket. Occasionally the root of the lateral incisor may be curved slightly to the distal, in which case much rotation would have a tendency to fracture it. Such a tooth is removed in the line of least resistance, and pressure toward the cuspid may be used. The forceps used are those shown in Fig. 484.

Extraction of Inferior Cuspid.—This tooth is usually more firmly set in the jaw than the incisors. The process surrounding the tooth is heavier, the roots of the tooth are longer and heavier than the lateral or central incisors. The position of the patient and operator is practically the same as for the extraction of the lateral and central incisors. Fig. 473 shows the position of the patient and the operator for extracting the inferior cuspid on the right side. Fig. 474 shows the

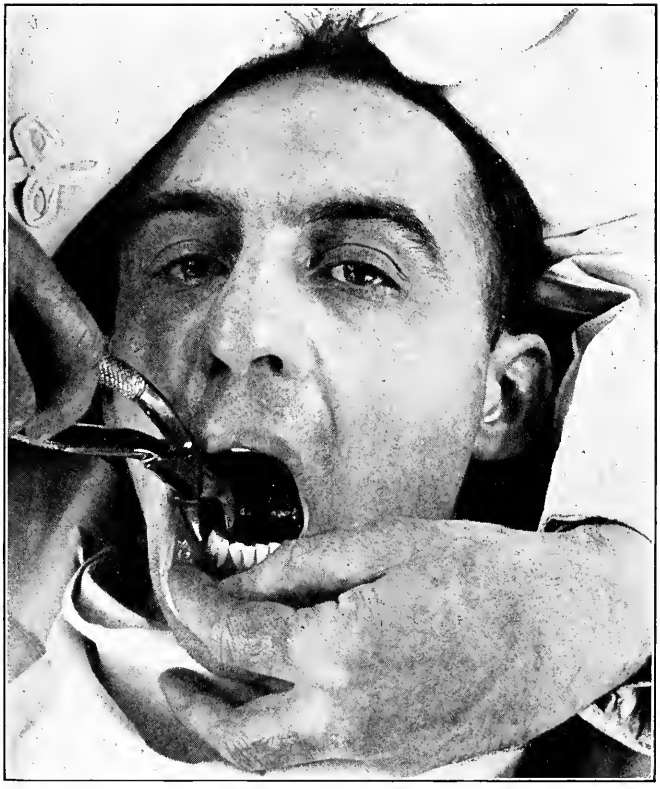

FIG. 475

position of the patient and the operator for extraction of the inferior cuspid on the left side. The application of the forceps is the same as for the lateral and central incisors. The tooth is loosened from its attachments by the application of pressure to the buccal with slight rotation. It is then removed from the socket by the force of traction. The forceps used are those shown in Fig. 484.

Extraction of Inferior Bicuspids.—Fig. 475 shows the position of the patient and the operator for the extraction of inferior bicuspids on the

right side. Fig. 476 shows the position of the patient and the operator for the extraction of inferior bicuspids on the left side. The forceps used are those shown in Fig. 484. The technic for the extraction of the first and second bicuspids is practically the same. The roots of these teeth are somewhat flattened and sometimes bifurcated. The same forceps are used for the extraction of the lower bicuspids as for the six anterior teeth. The position of the patient and the operator is similar to that for the six anterior teeth. The force of pressure to the buccal is usually sufficient to break up the attachments, after which the force of traction may be used to remove the tooth from its socket.

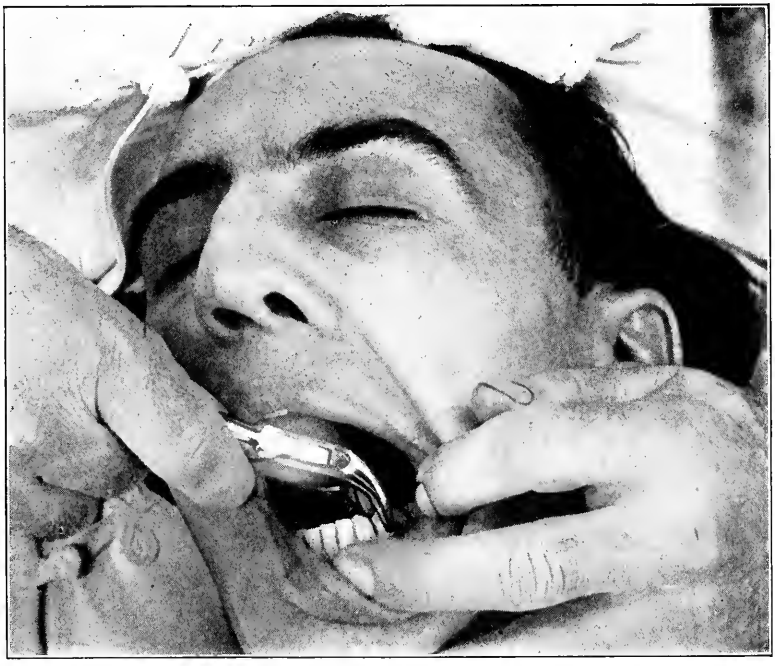

FIG. 476

Molars.—Extraction of inferior first molar. Fig. 477 shows the position of the patient and the operator for the extraction of inferior molars on the right side. Fig. 478 shows the position of the patient and the operator for the extraction of inferior molars on the left side. When all the teeth are in position, the first molar is a somewhat difficult tooth to extract on account of the widely diverging roots. When operating on the left side, the patient's head should be turned slightly to the right, and when operating on the right side, the patient's head should be turned slightly toward the operator. The forceps used are

those shown in Fig. 485. These forceps are universal and can be used on either side. The beaks of the forceps should be adjusted to the tooth in the same manner as in the extraction of the anterior teeth, with the points of the beaks well down under the free margin of the gum and resting between the mesial and distal roots. The forces used are considerable pressure to the buccal, and traction to remove the tooth from its socket. These forces will usually break up the attachments. Great care should be exercised in the extraction of the first molar so

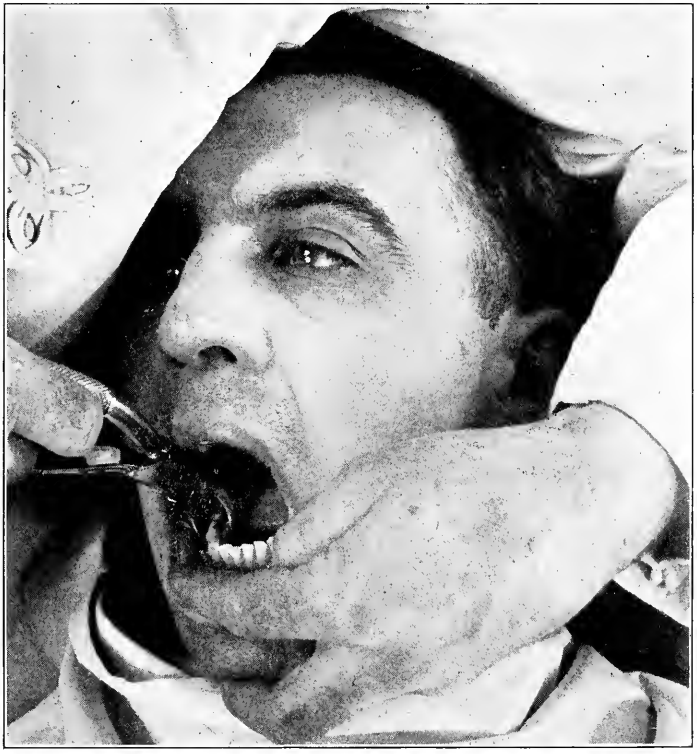

FIG. 477

that the mesial root does not engage the second bicuspid and thus remove this tooth at the same time.

Extraction of Inferior Second Molar.—The inferior second molar is not so difficult to extract as the inferior first molar since the roots are not so diverging. The position of the operator and the patient is the same, and the application of the forceps and forces used in extraction are similar.

Extraction of Inferior Third Molar.—The conditions involving the inferior third molars are so varied that a definite technic for their

removal cannot be given readily. The roots of a normal third molar are usually curved slightly to the distal, and for such teeth the Leclues elevator (Fig. 487) is a very satisfactory instrument to use for their removal. The point of the elevator should be inserted into the interproximate space between the second and third molars, using the alveolar process at the cervical line as a fulcrum, and by a rotary force break up the attachment. The removal of the abnormal lower third molar will be taken up under a separate heading and the technic will be described.

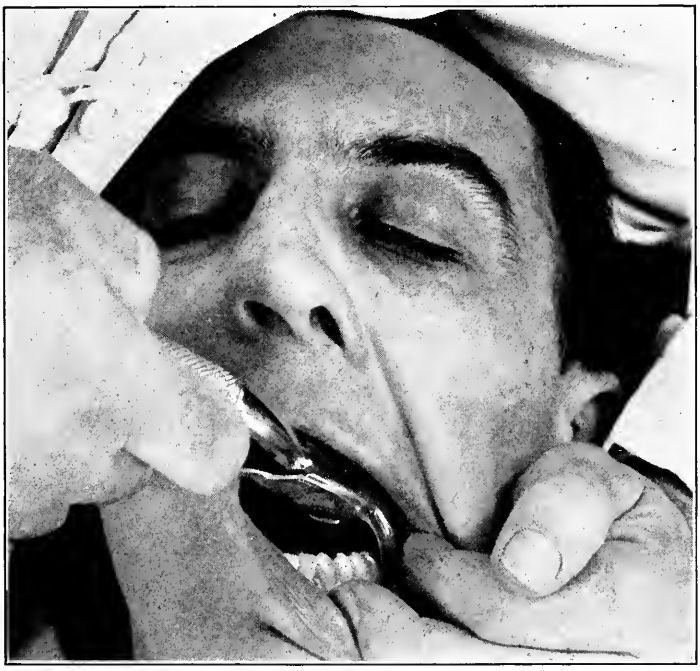

FIG. 478

Extraction of Deciduous Teeth.—In the extraction of deciduous teeth, the principles involved are the same as those applied in the extraction of the permanent teeth. One of the principal features to observe in the extraction of deciduous teeth is that the developing permanent teeth be not injured in the operation. This is particularly true in the removal of deciduous molars whereby the oncoming permanent bicuspid teeth may be injured or may be removed in the operation of extraction of the deciduous molars. Usually, if the deciduous teeth are extracted at the proper time, there will be little or no difficulty in their removal as at this time the roots should be completely decalcified so that the crowns are held in position only by the soft tissues. The instruments

for the extraction of deciduous teeth are practically the same as those described in the extraction of the permanent teeth. In the handling of these little patients no deception should be practiced. The patients should be made acquainted with the fact that there will be some pain. If they are deceived, subsequent operations will be performed with much difficulty after the little patient has once lost confidence in the operator. Frequently the roots of the deciduous teeth which have not resorbed in the process of exfoliation of the deciduous teeth, will remain in the jaws and will become wedged between the permanent teeth. All such roots should be extracted when observed. Frequently the employment of an elevator for this purpose will be more satisfactory than the employment of forceps.

Extraction of Supernumerary Teeth.—When supernumerary teeth are present, they are usually located in the region of the anterior teeth. Occasionally they may be found distally to the third molar. When these teeth are of no permanent value to the patient, they should be removed. Frequently these teeth will prevent the eruption of the permanent teeth, particularly in the region of the central incisors. The early removal of them, therefore, should always be indicated. The technic for extraction will not vary perceptibly from that for the extraction of permanent teeth.

Extraction of Roots of Teeth.—One of the most common accidents in the extraction of teeth is the fracture of a tooth, thus leaving certain portions of the root in the alveolus. These fragments of the root should always be removed because of the danger of future infection. They may be removed by alveolar forceps or by elevators. The alveolar forceps may sometimes be used very satisfactorily on roots in either the superior or inferior maxilla. The forceps for superior roots are those illustrated in Fig. 483. They consist of long narrow beaks and sharp edges for the purpose of cutting through the alveolar process. The technic for the extraction of these roots is to insert the beaks of these forceps well up under the free margin of the gum until the operator is sure that solid tooth structure will be encountered, and with the sharp edges of the beaks to cut through the alveolar process, until the forceps come into contact with the root to be extracted. Then by the force of rotation and traction the root is removed from the socket. This same technic should be used for the extraction of teeth that have decayed under the free margin of the gum. In the inferior maxilla the technic is similar, using the lower alveolar forceps as illustrated in Fig. 484. On account of the density of the alveolar process, elevators may be used more advantageously than the forceps when one is operating distally to the cuspid teeth. The elevators for the removal of roots which are very satisfactory are those illustrated in Fig. 486 known as the

Cryer elevators. The method of procedure is to engage a portion of the root with the point of the elevator, using the alveolar process as a fulcrum and rotating the root out. In the multi-rooted teeth sometimes the socket of one root may be used as point of access to the fractured root. In roots which have been exostosed it may sometimes be necessary to cut away the alveolar plate with a drill in order to remove the root. This is best done by drills illustrated in Fig. 492.

Instruments.—The instruments used in the extraction of teeth are forceps, elevators, chisels, drills, lancets, gum scissors, and mouth gags and curettes. The proper selection of suitable instruments is a matter of considerable importance and, since much depends upon the instruments in this operation, a judicious selection of them should be made. The mastery of the application of a few instruments is better than a little knowledge of the application of many. The principal instruments for the extraction of teeth are the forceps. The operator should have a well selected set so that he may become thoroughly familiar with every detail in their application. The principal features of the forceps which should be taken into consideration in selecting them are the beaks, joints, and handles. The beaks should be so constructed that they will fit the tooth for which they are intended. The ends of the beaks should be thin so that they may be inserted under the free margin of the gum with ease. The beaks should be bent at an angle with the handle so that the tooth may be grasped in line with its long axis and permit of the extraction of the tooth without the interference of the handles of the forceps with the cheeks and lips of the patient. To allow for an easy opening and closing of the beaks, the joints of the forceps should have free play. The edges of the joints should be rounded to avoid engaging the soft tissues in them while operating. The handles should conform in so far as possible, to the hand of the operator. By constant use of the forceps the operator soon becomes accustomed to the feeling of them in his hands. All of the forceps for the superior teeth should have full-ended handles (Figs. 479 to 485) to assist the operator in forcing the beaks of the forceps up under the free margin of the gums. For the inferior teeth the handles should be curved so as to fit the hand. One of the handles should be shorter with a curved end to the handle which fits over the little finger when the forceps are put into application. The following forceps have been selected for the extraction of teeth because of the broad range of usefulness. It is not possible nor practicable to give a complete description of all of the forceps that might be used in the extraction of teeth. It is believed that if the operator will perfect his technic with a few well selected forceps he will become more proficient.

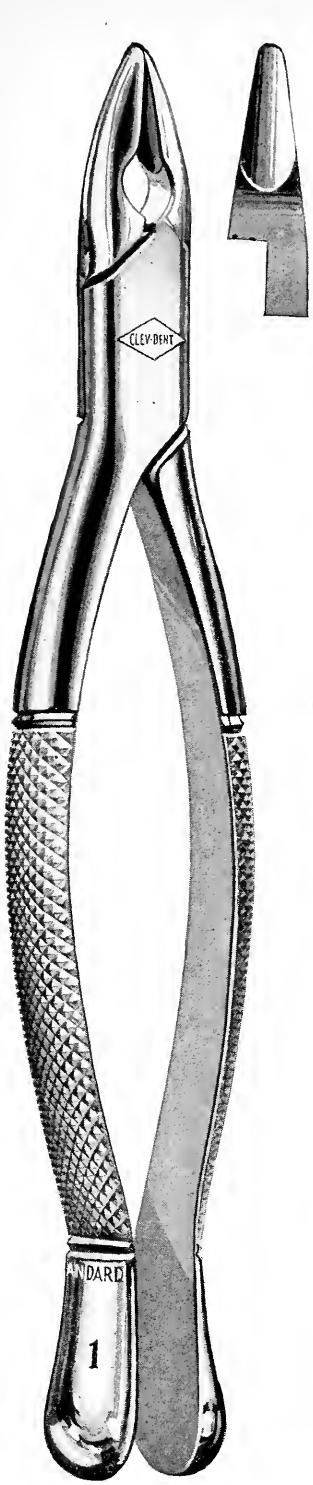

Fig. 479

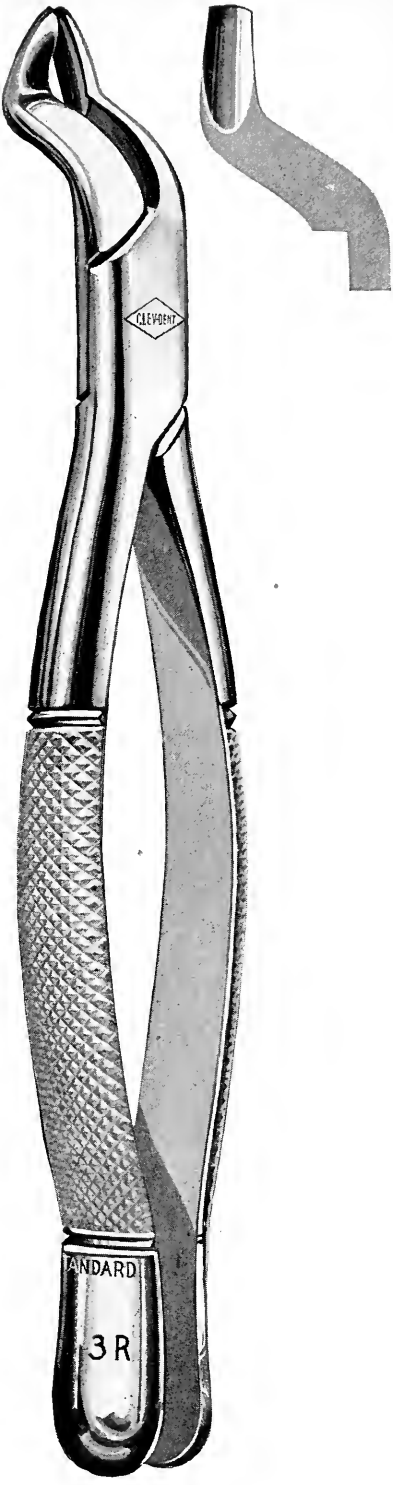

Fig. 480

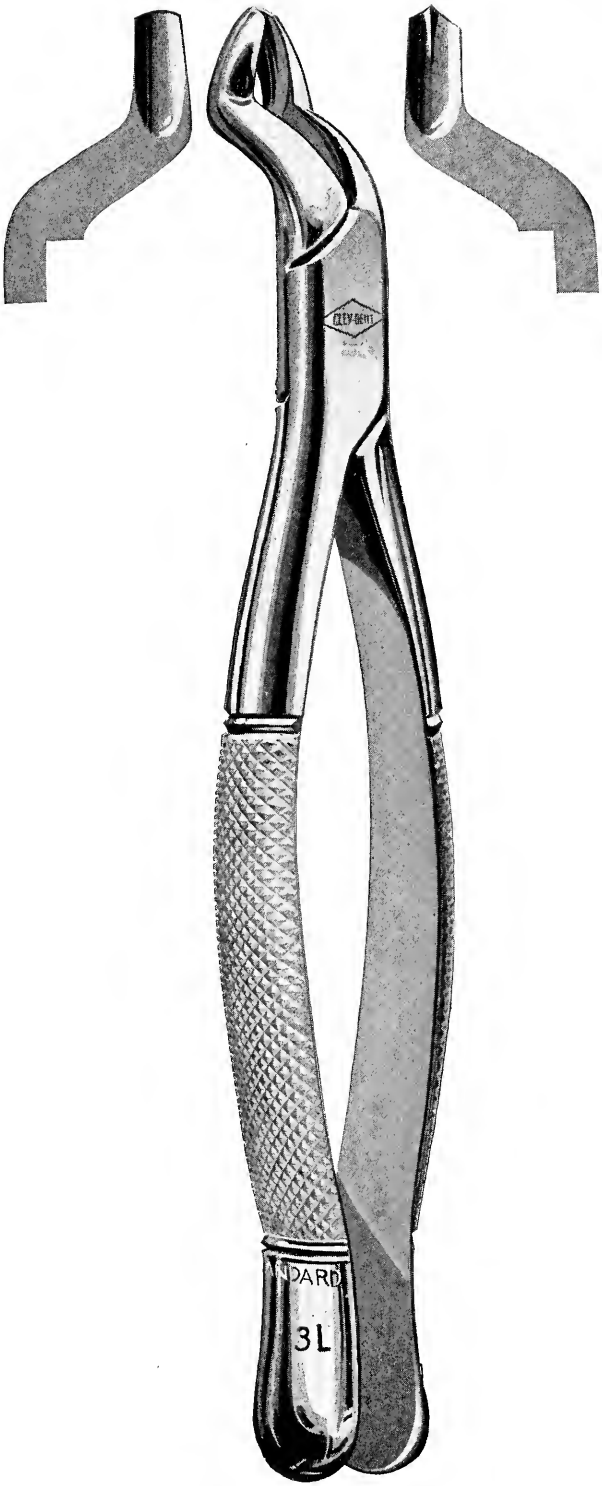

Fig. 481

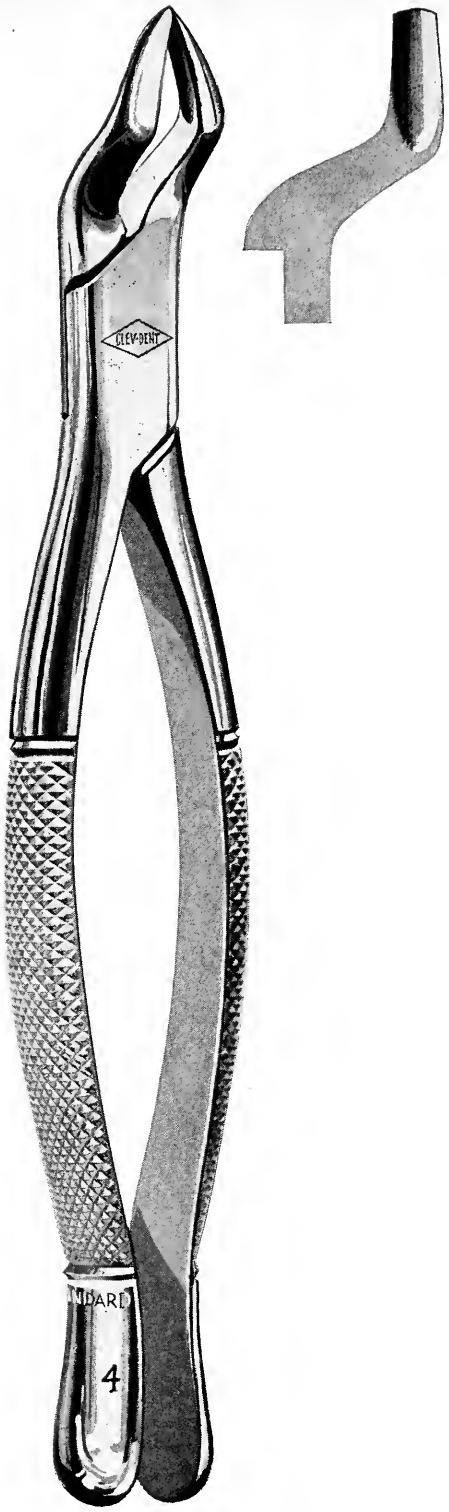

FIG. 482

Fig. 483

Forceps for Superior Teeth.—For the superior teeth the following forceps are essential:

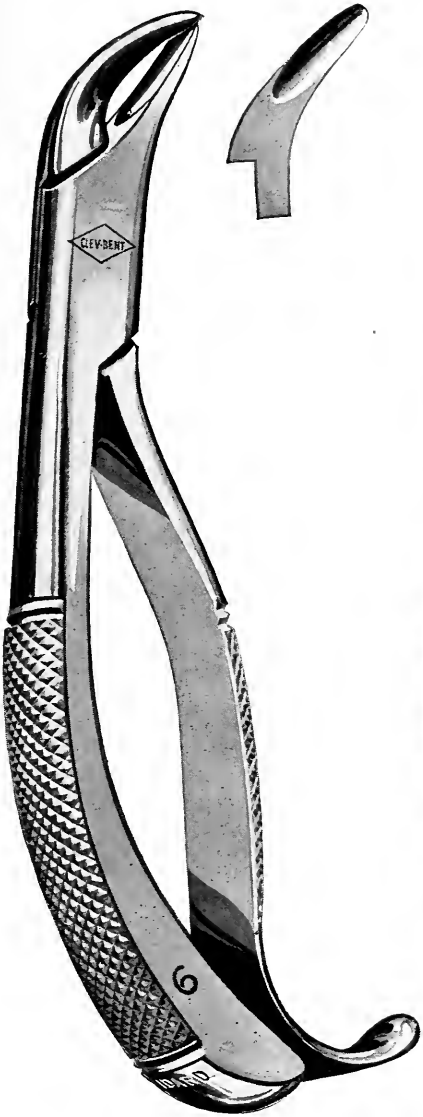

Fig. 484

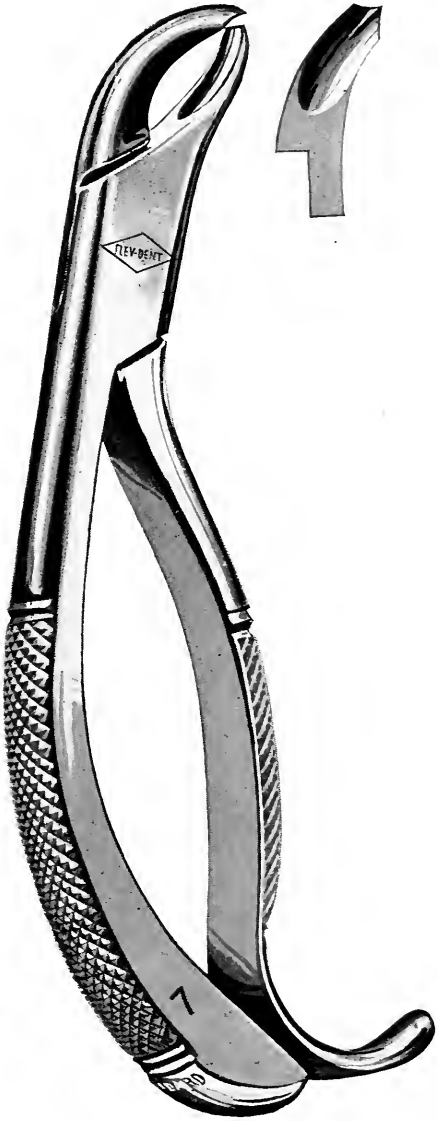

Fig. 485

Standard forceps No. 1, Fig. 479 for central lateral incisors, cuspids and biscuspids. Both beaks are alike and set in line with the axis of the handles.

Standard forceps No. 3R and 3L, right and left (Figs. 480 and 481), for first and second molars. These forceps may be used also for the third molars. The end of the buccal beak comes to a point so as to fit between the mesial and distal buccal roots. The lingual beak is oval. The beaks are set about two centimeters out of line with the axis of the handle.

Standard forceps No. 4 for third molars (Fig. 482), which are applicable to both sides of the arch. Both beaks are alike and set about two centimeters out of line with the axis of the handles.

Standard forceps No. 2 and Standard forceps No. 5 (Fig. 483), for roots of all of the upper teeth. Standard forceps No. 2 may also be used for the extracting of the upper bicuspids. Both beaks are alike and set about two centimeters out of line with the axis of the handles. Standard forceps No. 5, has long and narrow beaks which are slightly curved in their mesio-distal axis.

Forceps for the Inferior Teeth.—Standard forceps No. 6 for central lateral incisors, cuspids, and bicuspids (Fig. 484). These may also be used as alveolar forceps in the extraction of all of the roots of the inferior teeth. Both beaks are alike and set at an obtuse angle with the handles.

Standard forceps No. 7 universal, for lower molars on both sides of the jaws (Fig. 485). Both beaks are alike and set at an obtuse angle with the handles.

Elevators.—Elevators may be used to advantage in the removal of lower third molars, roots, and impacted teeth. Fig. 486 shows the Cryer elevator. All elevators should have metal handles so that they may be sterilized by boiling. This elevator is used in the extraction of roots; the operator using the point to engage the side of the root and with the alveolar process as a fulcrum rotates them out. The Lecluse or spade elevator (Fig. 487), is useful in the extraction of the lower third molar and for rotating out impacted teeth. The point and straight side of the elevator are used to engage the side of the root or tooth allowing the rounded surface to rotate on the alveolar process while the tooth or root is being forced out of the socket. The shank of this elevator may be straight or it may be canted at an angle to conform with the position of the mouth in which it is used. Fig. 488 shows the Jones elevator. It is designed somewhat after the Lecluse elevator. It has a long narrow shank with a thin blade. This elevator is used in the removal of lower third molars. The blade is inserted between the second and third molars with the flat surface toward the third molar, then by a rotary motion the third molar is loosened from its attachments. This elevator may also be used in the dislodgement of roots of teeth by placing the point of the elevator between the alveolar

process and the tooth, engaging the tooth root with the point of the elevator, and forcing the root from its socket. Fig. 489 shows the



FIG. 486

Heidbrink elevator. This is designed especially for roots in the anterior part of the mouth when the decay has so far progressed that the

use of a forcep cannot be satisfactorily employed. It is used by inserting the blade in the interproximate space and forcing it between the alveolar process and the root, or it may be used between the buccal plate of the alveolar process and the root for the purpose of loosening



Fig. 487

Fig. 488

the root. Fig. 490 shows the Crane elevator. This elevator has the shape of an ice pick and can be used advantageously in the removal of

Fig. 489

Fig. 490

upper third molars by forcing the point of the elevator through the alveolar process, engaging the third molar with its point, and with a prying motion loosening the tooth from its attachment.

Chisels.—Fig. 491 shows the Lyons chisel-elevators. These instruments may be employed in the removal of impacted third molars. These are the carpenter's edge chisels and are so designed that they

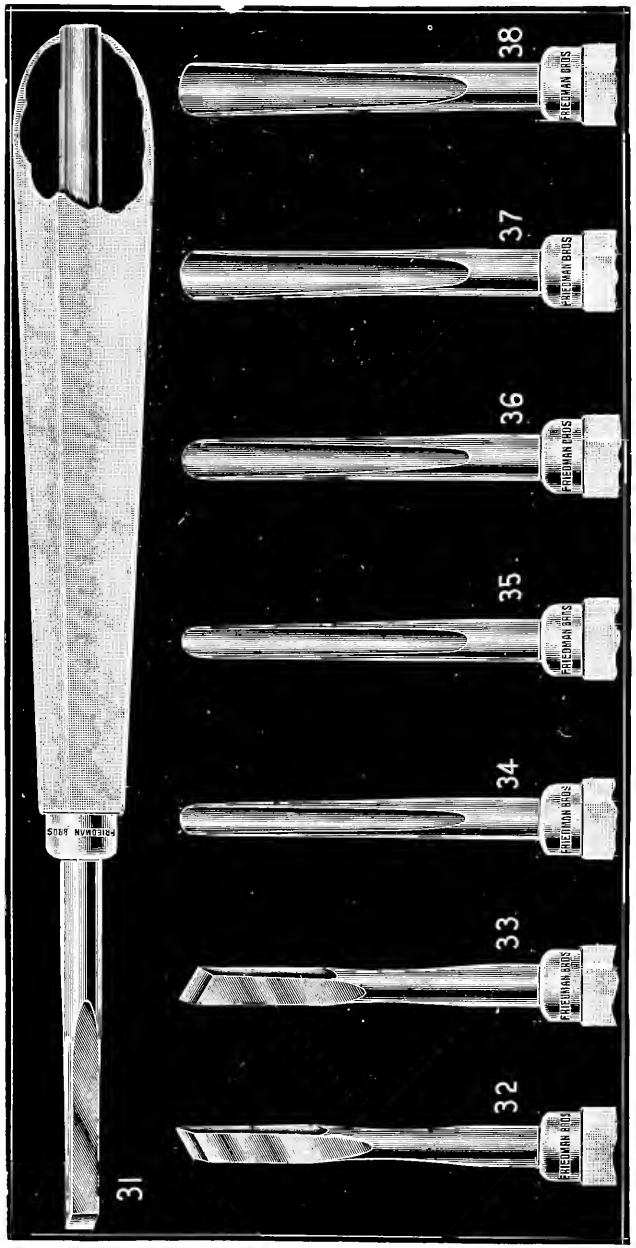

FIG. 491

may be used as elevators as well as chisels. They may be used as hand chisels or with the mallet.

Drills.—Fig. 492 shows the Henahan surgical bone drill. This may be used for the purpose of cutting away the alveolar process around tooth roots or cutting away the buccal plate around the alveolar process surrounding impacted third molars.

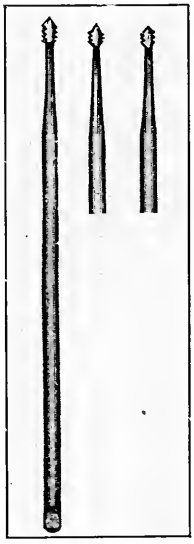

FIG. 492

Lancets.—Fig. 493 shows a gum lancet. It should be of all-metal construction so that it can be sterilized. The lancet is used to sever the soft tissues around the teeth so as to prevent laceration of the tissues in the process of extraction by the soft tissues adhering to the tooth. Unless we have reason to believe that the soft tissues are

FIG. 493

adhering to the tooth, the lancet should rarely be employed previous to the extraction, because hemorrhage from the incision of the lancet might interfere with the operation.

Gum Scissors.—Fig. 494 shows curved scissors. This instrument may be used advantageously in trimming gum tissues around the alveolar socket following extraction. It may also be used in severing

the soft tissues from the tooth to prevent laceration. The scissors may be used to advantage in trimming the soft tissues following the operation of alveolectomy.

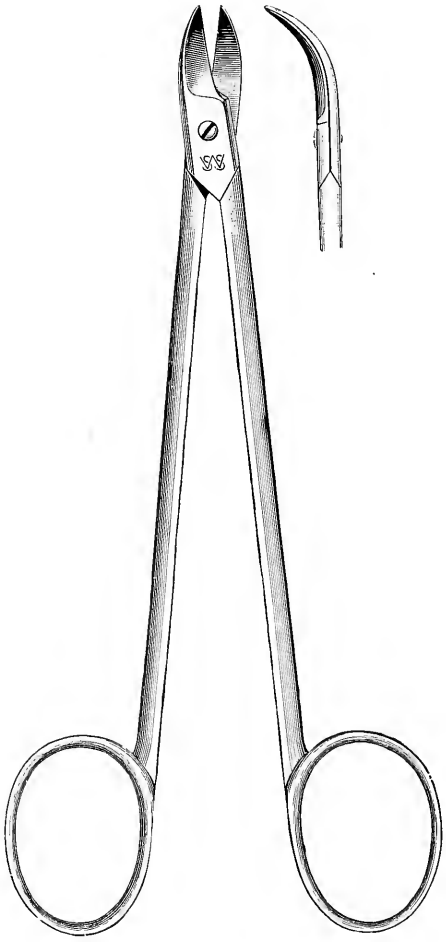

Fig. 494

Mouth Gags.—The mouth gag is a very valuable and indispensable instrument for the dentist to have when extracting under a general anesthetic. Fig. 495 shows a soft rubber mouth gag which is very efficient for retaining the mouth open during the process of anesthesia. When using a metal mouth gag, it is advisable to have a rubber protection over the jaws of it, so as to prevent injury to the tooth surfaces. Fig. 496 shows a metal mouth gag which is very satisfactory when operating around the mouth. The handles are away from the field of

operation, and will not interfere with the mask or face-piece in the administration of a general anesthetic. The gag should be applied always on the side opposite the field of operation.

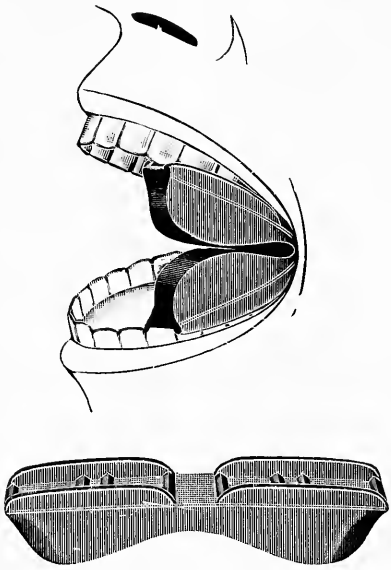

FIG. 495

Fig. 497 shows the Bogle curettes. These instruments may be used following the extraction of abscessed teeth and the operation of apicoectomy for mechanically eliminating infected areas. They may be used also in any place where diseased tissue should be removed. The handles are large and will permit of considerable pressure upon the blades of the instruments. The blades are spoon shaped with sharp cutting edges.

Accidents During the Process of Extracting Teeth.—Accidents will happen frequently during the process of extracting teeth, and the operator should be familiar with all of the features of such accidents and should aim to prevent them whenever possible. There are many accidents which are wholly unavoidable in the operation of extracting teeth. There are many more which are avoidable but which frequently happen to the beginner. When these accidents occur, the operator should not become confused, but should remain composed so as not to excite the patient. When it is necessary the patient should be made acquainted with all the facts concerning the accident; this procedure will instill assurance and confidence in the patient. One of the most common accidents which occurs in the extraction of teeth is the

fracture of a root. Such accidents may be avoided by making a careful survey of not only the tooth, but the anatomic structures surrounding the tooth before proceeding with the operation; then by the selection of instruments adapted to the operation, many of these fractures may be avoided. Much will depend upon the proper application of the

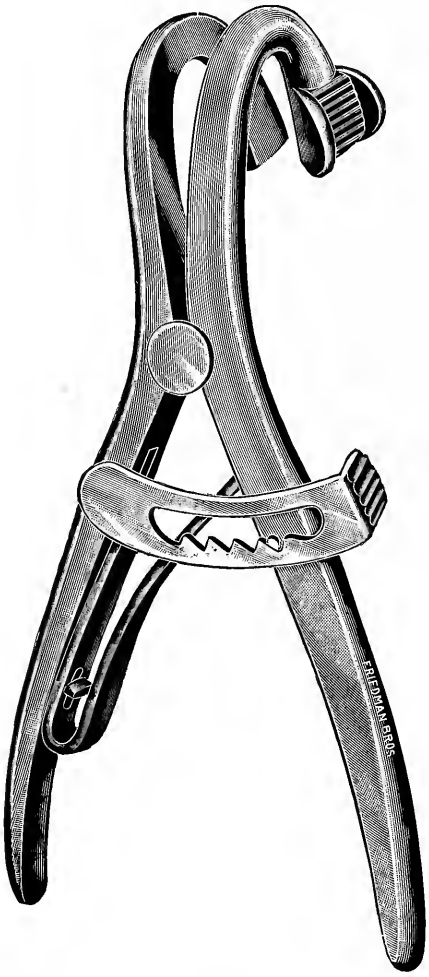

Fig. 496

forceps, and the movements which are required to loosen the tooth from its attachments. Much will also depend upon the correct position of the patient in the chair. In all cases of extraction, the operation should not be done too rapidly because that is one of the causes of many fractured roots. The patient may interfere with the proper

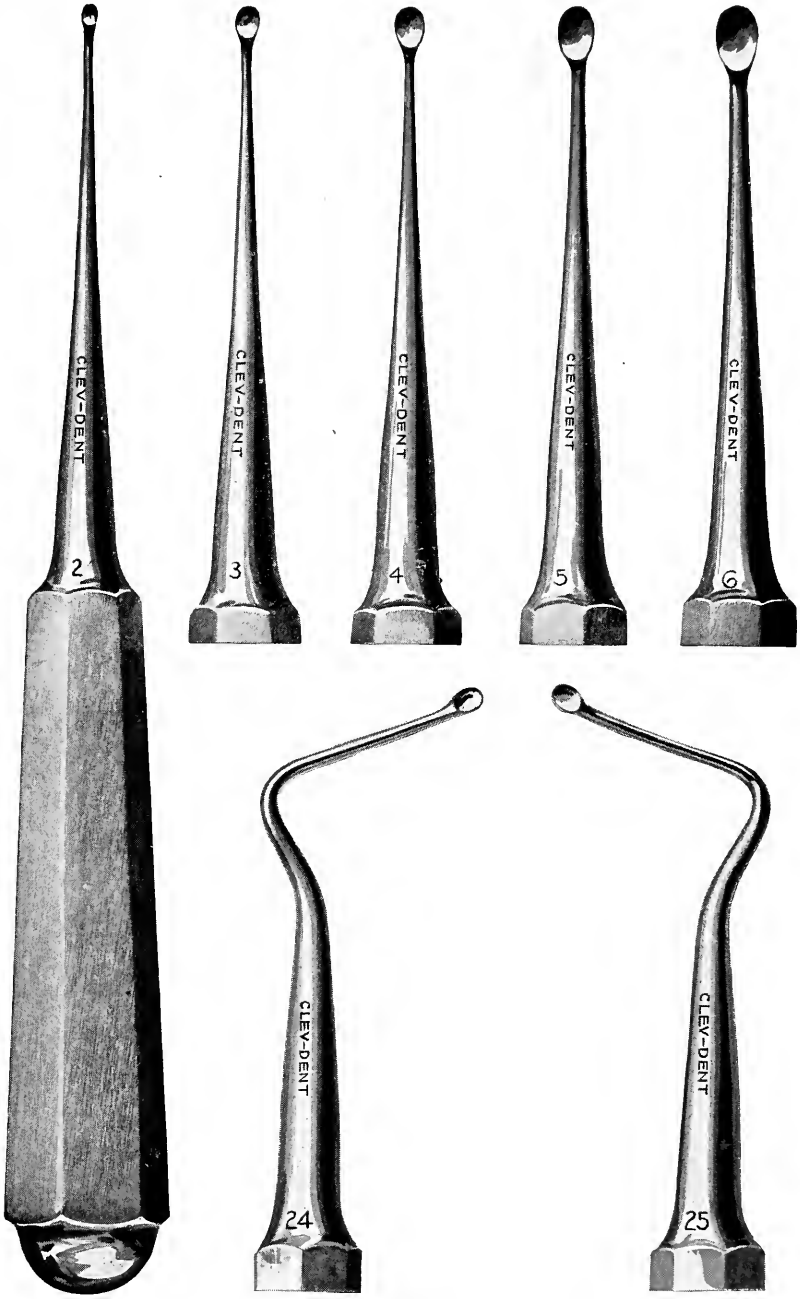
CLEV-DENT
2
CLEV-DENT
3
CLEV-DENT
4
CLEV-DENT
5
CLEV-DENT
6
CLEV-DENT
24
CLEV-DENT
25

FIG. 497

application of forces by the operator, by grasping the operator's hands or arms and this might predispose to fracture of the tooth. The roots of the teeth may be abnormal in shape which fact may result in fracture of the roots during the operation. Whenever a fracture of a tooth occurs, the roots should always be removed. It is not permissible to leave a portion of the tooth root in the socket, on account of the probable chances of infection following later.

Fracture of the Alveolar Process.—A fracture of the external plate of the alveolar process is not an infrequent accident following the extraction of upper molar teeth. This fracture may be so extensive that the antral cavity will be opened. When such an accident occurs the patient should be made aware of the fact, and the muco-periosteum covering the walls of the antrum should be sutured back in normal position. The posterior portion of the alveolar process and the maxillary tuberosity may be fractured in the removal of an upper third molar tooth. This may occur from two causes: first, if the beaks of the forceps are improperly applied to the tooth so that the beaks grasp the alveolar plate instead of the tooth, fracture may result when the forces of extraction are applied; second, in some individuals the alveolar plate is so thin that when there is a calcification of the pericemental membrane and adhesion of the membrane to the alveolar process, the force required to remove the tooth may fracture the tuberosity. These injuries should not be considered serious as complete repair will take place almost as rapidly as if no fracture had been made. Such a fracture can easily happen under a general anesthetic when the operator may be operating with undue haste.

Another accident which may occur on account of a hasty operation is that of extracting the wrong tooth. An accident of this kind is wholly unwarranted. The operator should be very careful especially when extracting under a general anesthetic, to see that the beaks of the forceps are placed upon the proper tooth before using the forces of extraction. Even when this has been done, the removal of a tooth adjacent to the tooth to be extracted may occur. The roots of these teeth may be partially fused together or the roots of one may be so shaped that they will engage the other, thus making the extraction of one without the other extremely difficult. When an adjacent tooth is removed accidentally, it should be immediately replanted and ligated to approximating teeth. Following this procedure, the pulp of the tooth should be removed and the canal filled. The injury of unerupted permanent teeth may occur when extracting deciduous teeth. This may occur by the beaks of the forceps being inserted too deeply and engaging the crown of the permanent tooth. In rare cases the roots of the deciduous teeth may be attached or engaged to the crowns of

the permanent teeth, such as the deciduous molar tooth root being attached to the permanent bicuspid, and the removal of the molar might loosen the bicuspid attachment to such an extent that both teeth might be removed together. In the removal of a superior bicuspid or molar, there is a possibility of forcing a part or whole of the tooth into the antral cavity by permitting the forceps to slip from the tooth or root in the process of extracting, and forcing the tooth through the thin wall of the antrum. It should always be removed even though a radical antral operation be performed. It is never permissible to leave such a foreign body in the maxillary sinus. This accident may occur in forcing the root into an abscessed cavity which has been formed in either upper or lower jaws. In these casss the ends of the roots should always be accounted for, and the cavity should be sufficiently opened to permit exploration of all its walls. In the removal of an upper third molar, the operator may force it up into the sphenomaxillary fossa where it may become lodged so that the position of it can be ascertained only by the use of the roentgen ray. When such an accident occurs, the patient should be apprised of the conditions, and the tooth should be removed. In either the upper or lower jaws it is always possible to force a tooth between the soft tissues and alveolar process. In the lower jaw the tooth may be forced as deep as the submaxillary fossa. In these cases, an explorer should be used to locate the tooth, then by a properly shaped hemostatic forcep and curved instruments, the tooth should be teased out. In those accidents where the soft tissues are lacerated, it is good practice after sterilizing the wound, to suture the mucous membrane as repair will take place much more rapidly.

A quite common accident which occurs, is the loosening of an adjacent tooth or teeth. This is not serious, and by pressing back the tooth into its position, rapid repair will take place. A crown or inlay may be removed easily in the extraction of teeth. By close examination previous to the operation, the operator may see the possibility of such an accident, and he should acquaint the patient with the possibility so that if it occurs, the patient will not censure the operator. A porcelain crown may be fractured easily by the instruments being forcibly brought in contact with it during the operation. During the administration of general anesthesia, when a mouth gag is used, the instrument should not come in contact with porcelain facings on account of the possibility of fracture. Injury to the lips and adjacent tissues by mouth gags should always be avoided.

The breaking of a point of an elevator or other instrument in the process of extraction is an accident that occasionally occurs, and when it does, the point of the elevator or other instrument should be removed

entirely. The wounding of the tongue, cheeks or floor of the mouth is an accident that may occur during the extraction under a general anesthetic. Such accidents occur for the reason that the mouth is filled with blood and the field of operation is obscured so that the forceps are improperly applied. When operating under a general anesthetic the operator should always have a clear field before him. This can be accomplished by the use of sponges. When such an accident occurs sutures should be used to restore the parts to normal condition.

Another accident that may occur is the dislocation of the mandible. This may happen to those patients who are subject to habitual dislocation of the jaws, or it may occur with any other patient where undue force is exerted in the endeavor to remove a lower molar tooth. When this occurs a reduction of the dislocation should be made immediately. This can be accomplished by placing a block of wood between the molars, and by pressing upward on the symphysis, and at the same time causing considerable backward pressure, the head of the condyle thus being forced back into the glenoid fossa.

Another accident that may sometimes occur in the removal of lower third molars is a fracture of the mandible at the angle of the jaw. This usually occurs on account of too much force being applied in the attempt to dislodge the tooth. Such an accident may also occur by cutting away so much of the mandible in an endeavor to release the tooth that it becomes weakened. It will occur more frequently in older than in the younger patients. When this accident occurs, the mandible should be immobilized by interdental ligation. The lower jaw should be immobilized for a period of four or five weeks.

Another accident that may occur particularly in the administration of general anesthesia is that of a tooth slipping from the beaks of the forceps in the process of the operation and passing into the pharynx. This accident may be avoided by operating slowly and in those cases where there is not good access to the field of operation, a sponge should be placed back in the pharynx during the operation so that no foreign body may drop into it. In the extraction of teeth under a general anesthetic, when there is considerable hemorrhage, it is best to use an aspirator for the purpose of keeping the blood out of the pharynx. Pneumonia may be avoided by so doing.

Hemorrhage Following Extraction.—Hemorrhage following extraction may be arterial, venous, or capillary in character, depending upon the vessel from which the blood escapes. When arterial, it is usually located in the socket of the tooth and may be stopped by packing firmly the socket with medicated gauze or absorbent cotton. Before inserting the cotton or gauze, it is good practice to roll the cotton in

Monsel's solution or in tannic acid, or use it in connection with adrenalin chlorid for the purpose of contracting the arterial walls. Adrenalin chlorid is a powerful vasomotor constrictor, and one of the most powerful hemostatics known. Although its effects do not last long after the hemorrhage has once ceased, it is not difficult to keep it under control. A pledget of cotton rolled to the shape of the tooth socket and dipped in sterile sandarac varnish is very efficient in blocking off the hemorrhage. A modeling compound impression of the socket may be made and after it hardens it is withdrawn and coated with soft plaster of paris and again inserted and held until the plaster of paris hardens. This packing will completely adapt itself to any part of the socket and block off any vessel. It will also remain in the socket without retention of any kind. In those cases in which it is necessary to cause pressure upon the wound in order to control the hemorrhage, gauze or absorbent cotton should be placed between the jaws over the wound, using a figure-of-eight or Barton's bandage to bind the jaws together.

In the removal of several teeth there may be considerable hemorrhage following, particularly in anemic individuals, and it may test the ingenuity of the operator to ascertain the best means of control. If the hemorrhage is coming from more than one tooth socket, that fact should be ascertained, and each socket treated separately until the hemorrhage has subsided. In cases of hemorrhagic diathesis the treatment should be begun before extracting. If the patient presents with a history of bleeding, then he should be placed under the care of a physician for two or three weeks previous to the extraction of the teeth. In such a case, the blood does not coagulate normally and will be very slow in forming a clot. It is also possible in such a case that the walls of the vessels have lost their tone so that the severed vessels do not contract normally to close the lumen. When the patient is in good health a hemorrhage will cease usually by a proper coagulation and the normal contraction of the vessels. This abnormal condition of hemorrhagic diathesis is brought about by certain diseases, and an early examination should be made in these cases by a physician before operating on many teeth.

Whenever it is necessary to operate, the administration of calcium lactate 10 to 15 grains, three or four times per day before the operation will sometimes be of aid in the forming of prompt coagulation. When the patient presents with such a history, it is not best to open too much tissue at once; extraction of a single tooth at a time is always best.

If the hemorrhage is severe, it may be controlled by the injection of horse serum in 10 c.c. doses. This promotes coagulation. Death rarely follows as a result of hemorrhage after the extraction of a tooth.

However, there may be marked constitutional symptoms as the result of the loss of blood. In these cases the general appearance of the patient is changed from the normal. The lips, ears, conjunctiva, as well as the general integument are of a yellow color. The general appearance of the patient is pinched or shriveled. The body is bathed in a general sweat, the pupils dilated. Because the brain is anemic, humming or roaring sounds are heard. The general sensibility is benumbed, and if the loss of blood is severe, unconsciousness follows. In these cases, the first thing to do is to control the hemorrhage, after which stimulants are to be given the patient such as strong whisky or brandy. When the patient has not been anesthetized, ether is a good stimulant to ward off syncope. Atropia, $\frac{1}{100}$ grain doses act as a respiratory. External heat by hot water bottles should be used diligently. Normal salt solution 100° to 105° F. as it emerges from the needle should be injected into a vein or the soft tissue of the breast, the abdomen, or the rectum. Injection into the breast or abdomen requires no special apparatus but a large size hypodermic needle. A great loss of blood may bring on a condition commonly known as shock.

Pre-operative Treatment in the Extraction of Teeth.—Bacteria, as a rule, gain entrance into the human system through rupture of the tissues. A wound, an abrasion, and an inflamed or injured part prepare the way for bacteria by lowering the local resistance. After this, if followed by a profound constitutional depression, due to exposure, excesses or disease, the growth of bacteria will be rapid and destructive. The extraction of a tooth necessarily opens the tissues and prepares the way for the entrance and propagation of microörganisms. In order to limit the number of microörganisms which may enter the system through a wound, prophylactic measures should be instituted previous to the extraction of a tooth. These prophylactic measures should consist of spraying out the mouth with a normal salt solution just previous to the operation. This should be followed by painting the field of operation with a 7 per cent. solution of tincture of iodin to remove the gross sepsis. It should be understood that all instruments connected with extraction of teeth should be sterilized on the same plan as instruments are sterilized for any other surgical operation. The instruments should be boiled for at least fifteen minutes previous to using them. The aim should be to reduce the number of microorganisms that might possibly enter the system through the wound.

Post-operative Treatment.—Any accident that may have occurred during the operation of extraction should be recognized at once by the operator and treatment instituted as circumstances warrant. All loose portions of the processes or loose pieces of the gum tissues should be removed following the extraction. When there has been no patho-

logic condition present, when the gum tissue has not been contused or lacerated, and when there have been no overhanging ragged edges of the alveolar process, irrigating immediately with a 5 per cent. salt solution will usually yield good results. This irrigation will flush out any debris that may have entered and lodged in the tooth socket. The primary hemorrhage which follows the extraction will usually cease in a few minutes and a blood clot will be formed, which acts as a scaffolding, through which normal repair will take place. The blood clot will protect the wound during the process of repair so that in these simple cases further dressing will not be indicated.

The patient should be instructed to irrigate the mouth daily with a 5 per cent. salt solution. Simple cases of extraction which are treated in this manner will usually cause no further trouble. In cases of difficult extraction when there has been considerable traumatism to the tissues, a condition of alveolitis may follow the operation. Immediately following such an operation, the socket should be irrigated with a 5 per cent. salt solution and counter-irritants such as aconite and iodin or iodized phenol used to allay the inflammation. The patient should return every day for treatment until the inflammatory condition subsides. In these cases, it is necessary to keep the field scrupulously clean. All of the body eliminating processes should be made active.

When there has been a stripping off of the muco-periosteum to any great extent over the alveolar process, it should be sutured back into normal position, using horse hair or dermal suture for this purpose. In cases of extraction of teeth with alveolar abscess, the sockets should be thoroughly curetted following the operation. Spoon shaped hand curettes are the most desirable for this procedure.

In a case of extraction of a tooth with a granuloma at the apical end, the same procedure should be instituted. In many cases it will be necessary to remove the buccal plate over the sockets of the teeth in curetting, so that every surface of the abscess cavity may be explored. Following the curettage, the cavity should be irrigated and the treatment instituted as for all other extractions. In case pus is present following extraction of an abscessed tooth, packing the socket for twenty-four hours with iodoform gauze for the purpose of maintaining drainage is good procedure, after which the same treatment as in other extractions will yield good results. All precautions should be used in the extraction of teeth to prevent infection following the operation, but if infection occurs, it should be treated in the same manner as an infection that is present at the time of extraction.

Post-operative Pains.—The patients should be acquainted with the fact that in all probability there will be some pain following the operation of extracting a tooth. They should be informed that a

wound in any part of the body as great as that made in the extraction of a tooth will cause considerable pain, and the mouth will be no exception. Usually pain from simple extractions will not endure for any great length of time. There are several conditions that will bring about post-operative pain:

1. Extensive traumatism which results in alveolitis.
2. Infection either present at the time of the operation or following the operation.
3. A fractured root with a portion of the pulp exposed that was not removed.
4. Lack of normal blood supply to the parts, which results in the formation of the so-called dry socket.

In the first and second instances, the treatment should be instituted as indicated above for alveolitis. In the third instance all particles of the tooth root should be removed even though greater traumatism is produced. In the fourth instance where there is a dry socket formed, a curettage of the tooth socket is indicated and an effort made to promote a flow of blood so that a clot may be formed in the tooth socket, and the normal process of repair permitted to proceed. In all cases of untoward sequelæ following the operation of extraction of teeth, the patient should be kept under observation by the operator until normal conditions have become reëstablished.

Remedies for post-operative pain following extraction are given under "Post-Operative Treatment for Impacted and Unerupted Teeth."

IMPACTED AND UNERUPTED TEETH.

The Impacted Lower Third Molar.—This condition is in a large percentage of cases caused either by lack of normal development, or by arrested development of the inferior maxilla. The second molar immediately in front and the coronoid process behind bound the space allotted to the third molar. Each tooth which has no deciduous predecessor is developed beneath the base of the coronoid process. This is true of the first, second, and third permanent molars. The only manner in which these teeth are able to take their places in the normal arrangement of the teeth in the jaw is by the physiologic resorption of the anterior surface of the coronoid process. While this process of resorption is going on, on the anterior surface of the coronoid process, through the laws of compensation, nature has provided for a deposition of bone on the posterior surface of the condyloid process. Through these two physiologic processes, resorption and deposition of bone respectively, all of the molars are able to erupt into their proper

positions. Figs. 498, 499 and 500 show developmental stages of first, second, and third molars.

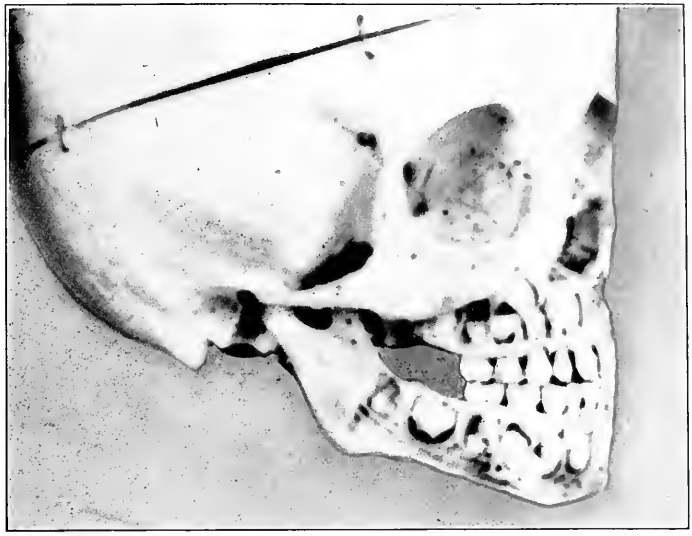

FIG. 498

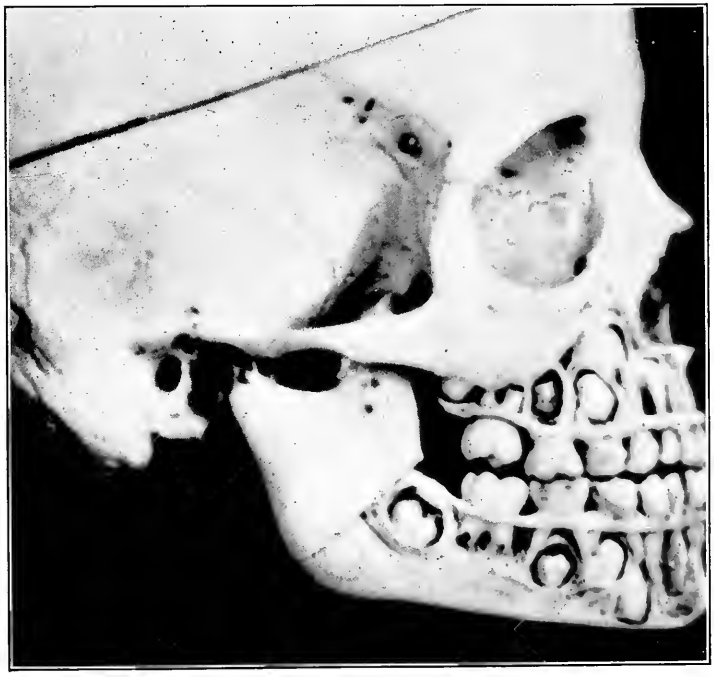

FIG. 499

However, when either or both of these physiologic phenomena in the process of development of the mandible are arrested, the interval between the anterior surface of the coronoid process and the last erupted tooth which is usually the second molar, will be insufficient for the normal arrangement of the presenting third molar. Under these conditions, the tooth in pressing forward, takes a direction in which the least resistance to its progress is offered and a condition becomes manifest which is termed impaction.

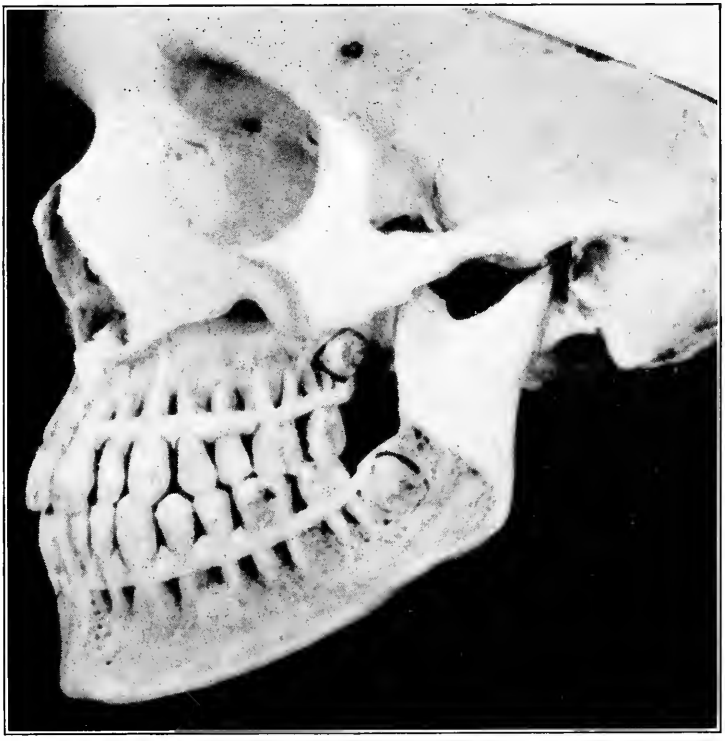

FIG. 500

Another condition which must be recognized in accounting for the mal-position caused by the impaction, is that the tooth has been directed from its course at a comparatively early period of development, irrespective of resistance offered at the time of eruption. This condition may be accounted for by a change in the character of the cancellous bone immediately adjacent to the developing tooth. If, through some inflammatory process, peculiar to the individual, or by the same process set up through some pathologic disturbance, or trauma, a secondary deposit of dense bone is laid down, around the developing tooth, a

change in the direction of eruption of the tooth may take place or there may be a prevention of its eruption. This retarded condition is also due to the fact that at the points where all of the other teeth are located, soft spongy bone or alveolar process is found and resorption of tissue takes place more readily at these points than at the points of eruption of the third molars which is made up of dense cortical or true bone. Frequently the third molar will erupt until it comes in contact with the second and then stop on account of insufficient space, in which case only a small part of the tooth will be presented. An upper third molar presents an entirely different condition on account of the difference in the character of the bones in the superior and inferior maxillæ. When, for any reason there is a retarded development of the superior maxilla which makes it shorter in its anterior posterior diameter, so that there is not sufficient room for the normal eruption of the third molar, the crown of this tooth will point toward the cheek, taking the direction of least resistance in its course. It slides out to the side, being guided by the second molar, which is already in place. If there were sufficient room, both upper and lower third molars would erupt without pain, but this is rarely the case.

The cuspids are the next in the series most likely to be impacted. The etiology of this condition is the same as that of the impacted molars, namely, insufficient spaces for the normal presentation of the teeth in the process of eruption. The cuspid teeth make their appearance long after the eruption of the lateral incisors and sometime after the eruption of the first bicuspids. In case of retarded development of the maxillæ, there may not be sufficient room between the lateral incisors and first bicuspids for normal eruption of the cuspids and as a result impaction occurs.

On account of the tendency of erupting teeth to follow the course of least resistance, they will slide out to the buccal or into the lingual surfaces of the maxillæ. It is also true that at an early period of development of these teeth, a secondary deposit of bone in the maxillæ, due to an inflammatory process, may influence a change of direction in the developing teeth so as to change their position entirely when they erupt.

While the third molars and cuspids are predisposed to impaction more frequently than any others, yet any tooth in either maxilla may become impacted if the environment is not such that normal eruption can be made possible.

The next anomaly which may be considered is the unerupted or aberrant tooth. This condition may be present in any part of either maxilla and any tooth may be the offending member.

There is always a reason for such teeth being unable to erupt norm-

ally. The developing teeth meet some obstruction in their normal course, such as supernumerary teeth or normal teeth which have previously erupted and already occupy the space belonging to the erupting teeth. Again, a previous inflammatory condition in the cancellous bone may have set up secondary deposits of dense bone which will prove an obstruction to the developing teeth and deflect them out of normal alignment.

Pathologic Possibilities.—Some of the pathologic conditions which are induced by these dental anomalies will now be considered. The impacted lower third molars will be taken up first.

Perhaps the most common disturbance to be encountered is local infection of the soft tissues surrounding the teeth. This condition is usually present in the partially erupted teeth when the gum tissue which should occupy the space between the anterior surface of the coronoid process and third molar has been forced out over the disto-occlusal surface of the tooth and becomes contused in mastication. Bacteria-laden saliva and food particles are forced into the interstice between the tooth, and swollen tissue and infection take place. Inflammation is set up and maintained, which is not limited to the injured parts, but more commonly extends to the adjacent structures involving the soft textures about the ascending ramus and frequently involving the paratonsilar region.

Deglutition becomes painful and trismus is set up. Many times the patient is unable to open the jaws more than two or three millimeters. After a time suppuration takes place and the movements of the jaws become less constrained.

In these acute conditions immediate surgical procedure is contra-indicated. The treatment indicated is to apply counter-irritants, the application of cold compresses or ice to the face, and to have all of the body eliminating processes active.

After the inflammation has subsided and the jaws have become less constrained, conditions should be restored to normal by surgical procedure to obviate repeated attacks. This condition will rarely be found around other impacted teeth than the lower third molars.

A pathologic condition which may occur as a result of an impacted tooth is pressure resorption. When the crown of one of these teeth is lodged or impacted against the root of an adjacent tooth, the hard enamel surface of the impacted tooth will cause a resorption of the tissues of lesser resistance of the other one. This may go on to such an extent that the pulp of the adjacent tooth will be encroached upon.

A very serious condition may arise from an impacted lower third molar by pressure being exerted upon the inferior dental nerve. The position of this tooth in the maxilla predisposes to impingement upon

the inferior dental canal. In such cases a reflected pain may be set up which will be expressed in any part of the head which has its sensory nerve supply from the fifth or trigiminal nerve.

Neuralgia may have its etiology in such conditions. The late Dr. Henry S. Upson, former professor of Neurology in the Western Reserve University, ascribed many of the nervous disorders which "mankind is heir to" to impacted teeth. He stated that "certain types of nervous disturbances caused by dental impactions have almost the clearness of a laboratory experiment, as in them the severest symptoms are set up by the simplest irritant. Pain may be from the beginning to the end quite lacking." It is the constant though mild irritation, perhaps not sufficient to produce pain, that sets up some of these nervous disturbances which may of themselves take on a violent form.

Alopecia areata, or baldness occurring in sharply defined patches, leaving the scalp smooth and white, is a condition due to a nervous disturbance. An impacted tooth must be considered an etiological factor in this affection.

During the last few years, the author has had several cases of this nature that showed marked improvement after the removal of impacted teeth.

Another abnormal condition that is quite frequently found associated with the presence of impacted lower third molars is a tendency for these teeth in their effort to erupt to force all of the lower teeth forward. Orthodontists have found it almost impossible to retain normal occlusion following orthodontic treatment with these teeth present in the jaws. Many fine orthodontic results have been ruined by the presence and activity of impacted teeth.

What are the pathologic possibilities of unerupted teeth? It is a remarkable fact, and one which has not been fully explained, that unerupted teeth having lain dormant for years in the jaws suddenly become the seat of purulent inflammation with sometimes serious symptoms. Such cases are by no means rare. Some writers are of the opinion that under certain conditions such teeth may act as foreign bodies and may even fall prey to resorption. Under these conditions where an irritation has been set up and purulent inflammation has become seated, a bone abscess may form around the region of an unerupted tooth. This abscess may develop until a large portion of the maxilla becomes involved.

Another condition which is seen frequently in the mouths of men and women under thirty years, is the cystic growths connected with these teeth whose eruption is retarded. In the light of our present knowledge the explanation for the formation of these cysts is largely

theoretical. Tomes has suggested the most plausible theory. He states that when the development of the enamel of a tooth is completed, its outer surface becomes perfectly detached from the investing soft tissue and a small quantity of transparent fluid not uncommonly collects in the interval so formed. This fluid ordinarily is discharged when the tooth is erupted, but when from some cause the eruption of the tooth is prevented, it increases in quantity and gradually distends the surrounding tissues, causing a resorption and disintegration of the osseous structures. These cysts may go on developing until a large portion of the maxilla is involved.

Again, an unerupted tooth may, by coming in contact with the roots of the normal erupted teeth, cause pressure resorption and thus produce a permanent injury to them. When this tooth lies in close proximity to a nerve trunk, it may cause undue pressure and set up the same obscure nervous disturbances which have been attributed to impacted teeth.

Treatment.—We have considered briefly the etiology and pathology of some of these dental anomalies. We will now consider the treatment.

An unerupted tooth should be removed when it is suspected of any disturbance. Successful diagnosis is made only by a process of elimination and when such a tooth is present in the jaws and the patient is suffering from obscure nervous disturbance, the removal of it is indicated in order to eliminate a possible source of trouble. Its removal, together with the entire cystic lining must be accomplished in cases of dental cysts. This should not be attempted without a good roentgenogram, which should point out the location of the tooth and the dimensions of the cyst.

In fact, the removal of any unerupted tooth should not be attempted without a good roentgenogram for the reason that any unnecessary cutting or laceration of the tissues is not permissible in these operations. In the removal of these teeth the author prefers to uncover them by means of a chisel and mallet, thus the landmarks are not destroyed which otherwise might be the case in the use of the bur and engine. After the location of the tooth and the character of its environment have been determined, the use of the bur or drill is permissible in the further removal of the osseous tissues and in the dislodgment of the tooth.

In the removal of an impacted tooth other than the lower third molar, no definite technic can be followed since each case will usually present entirely different conditions.

In the removal of the impacted lower third molar, however, the author believes that it is possible to follow a definite technic in practically every case. In other words, the operator should have a clear

conception of the whole situation and know exactly what has to be accomplished in order to remove the tooth with the least amount of traumatism. In a large percentage of cases no more traumatic injuries should be made upon the osseous tissue than in the extraction of the first or second molars.

The difference in the character of the process of repair of the two wounds is due largely to the extent of the pre-operative inflammatory process present, which is usually very much greater in the case of an impacted molar.

Technic for Removal of Impacted Lower Third Molars.—After the field of operation has been sterilized of its gross sepsis and anesthetized, an incision 1 centimeter long is made through the soft tissues over the tooth. Then a vertical incision is made about 2 millimeters distal to the second molar and extended to a point half way between the gingival margin and the root of the second molar (Fig. 501). The triangular flap is then raised, exposing the osseous tissue surrounding the tooth (Fig. 502).

The next step is to remove by the chisel and mallet a section of the process overlying the tooth to an extent that there will be sufficient space between the second molar and the osseous structure covering the tooth to permit it to be displaced (Fig. 503). A surgical drill is then used to remove a section of the cortical bone 2 mm. in width contiguous to the buccal surface of the tooth (Fig. 504). The wedge of cancellous bone between this surface and the tooth socket is readily removed with the chisel. Then the chisel is driven between the buccal surface of the tooth and buccal plate of the alveolar process with the bevel of the chisel next to the buccal plate, and by a prying motion the buccal and lingual plates are sprung apart sufficiently to loosen the tooth (Fig. 505). Fig. 506 is a cross-section of an impacted third molar, showing the thin lingual plate. Then, by means of an elevator (preferably the Lecluse) the tooth is rotated backward and out (Figs. 507 and 508). At the stage in the operation necessitating the use of the elevator, the chisel may be used as an elevator and the tooth removed. The elevator should never be used until the tooth is seen to rotate slightly in its socket under the stress of the chisel. Until this time, the impaction has not been relieved, and any attempt to use the elevator might result in fracture of the tooth or of the alveolar process, or even of the mandible.

The same principle is followed with any degree of impaction and also with a tooth that is not only impacted but unerupted as well. The cutting should all be done from the buccal surface, as there are no vulnerable tissues at this point, while on the lingual surface the lingual nerve and artery might be injured if much cutting were attempted.

Under novocain anesthesia there is very little hemorrhage and this is controlled by a gauze sponge inserted on the buccal surface adjacent

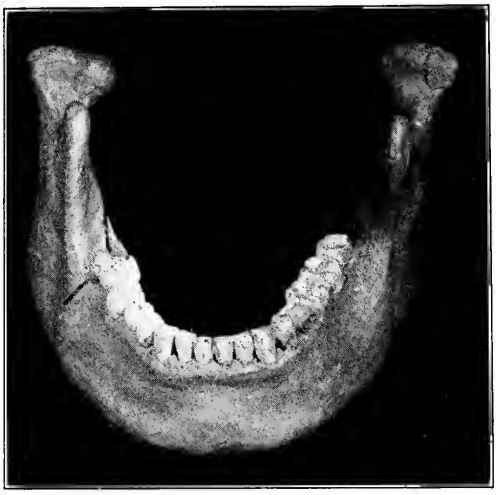

FIG. 501

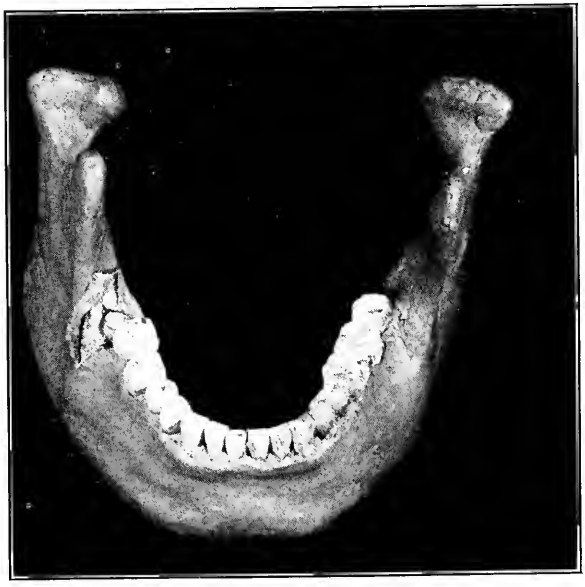

FIG. 502

to the operative field. There is one point for the operator to keep in mind and that is that the impacted tooth is wedged into the jaw and the impaction has to be relieved before the tooth can be removed.

This may be done with burs, drills, stones, cutting forceps or chisels. The wound made from the chisel is a clean sharp one and not rough

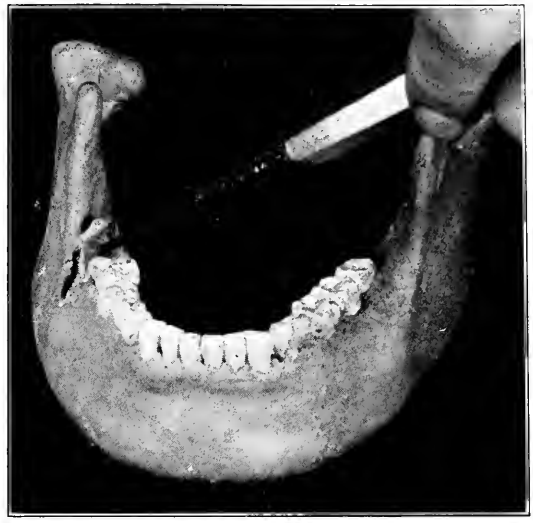

FIG. 503

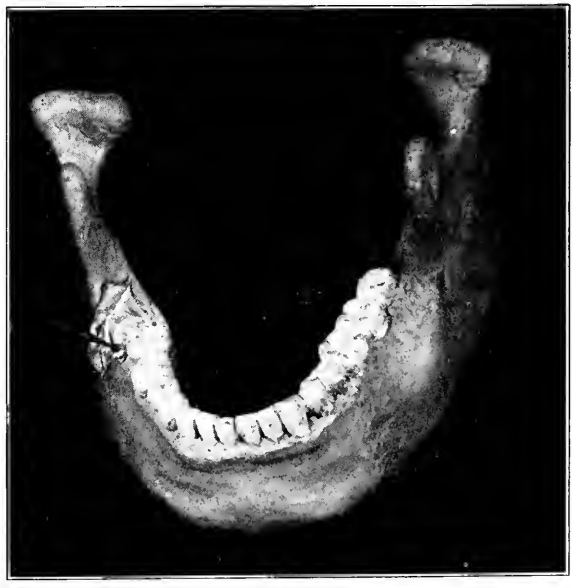

FIG. 504

and ragged such as those made by burs. Consequently repair will take place around a wound made with a chisel much more quickly than if the tissues are lacerated by burs.

Post-operative Treatment.—The procedure which has been very satisfactory in the author's hands is to saturate plain or iodoform gauze with euroform paste and pack the socket with it for twenty-four hours immediately after the operation. This preparation is antiseptic

Fig. 505

and its sedative action is most beneficial. At the end of twenty-four hours the dressing is removed and the patient instructed to use a warm 5 per cent. salt solution as a mouth wash. Dentalone on absorbent cotton rolls inserted into the socket may be used to advantage.

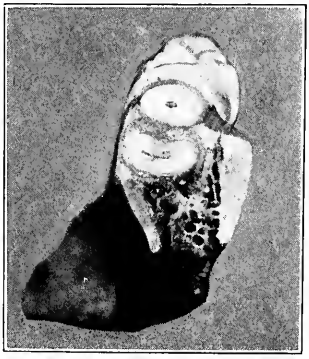

Fig. 506

The wound should be kept free from all food deposits and debris by the use of sprays of 5 per cent. salt solution, until repair takes place. No curettage is necessary in these cases unless an abscessed condition

is present, in which case curettage of the socket is indicated. In cases of post-operative pain, asperin 15 grains may be given as a nerve sedative. Pyramidon in 5-grain doses acts as an antipyretic and an

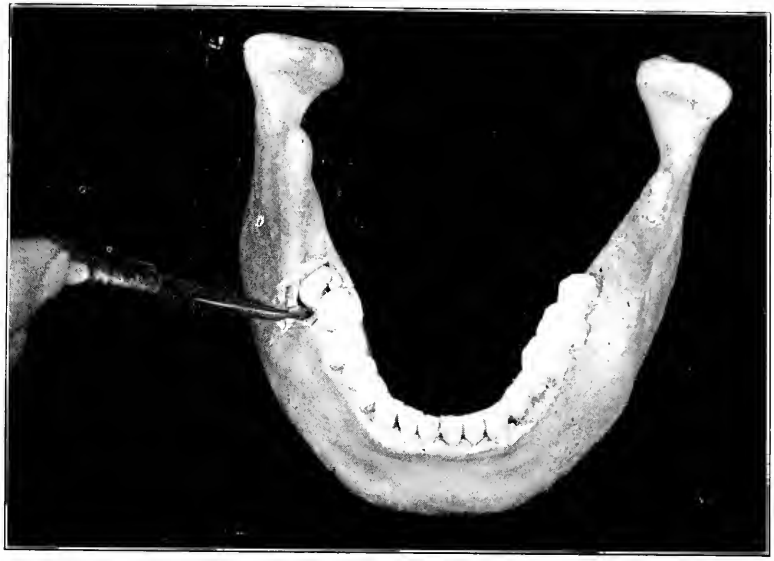

FIG. 507

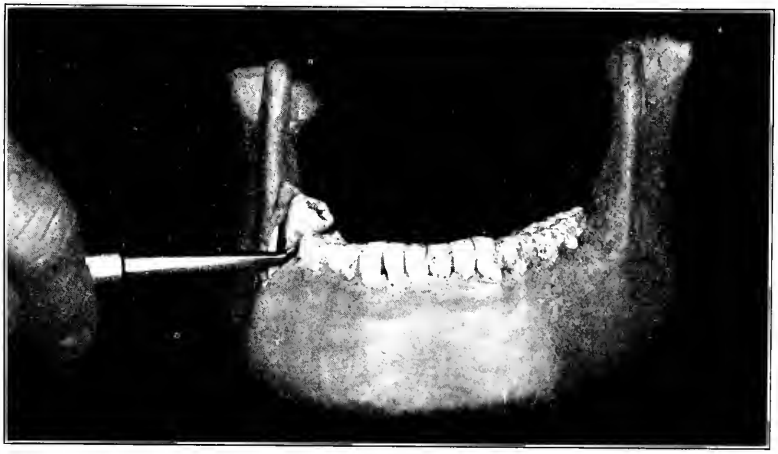

FIG. 508

analgesic and will yield good results. Dusting of anesthetic powder such as novocain powder, novoesthene or parathesen into the socket will be an aid in controlling post-operative pain.

A thorough knowledge of the pathologic possibilities of these dental anomalies, a definite technic for their elimination, and a scientific treatment for pre-operative and post-operative conditions are all essential for success. The personal ability of the operator will be the predominating factor in the success or failure in their diagnosis and treatment.

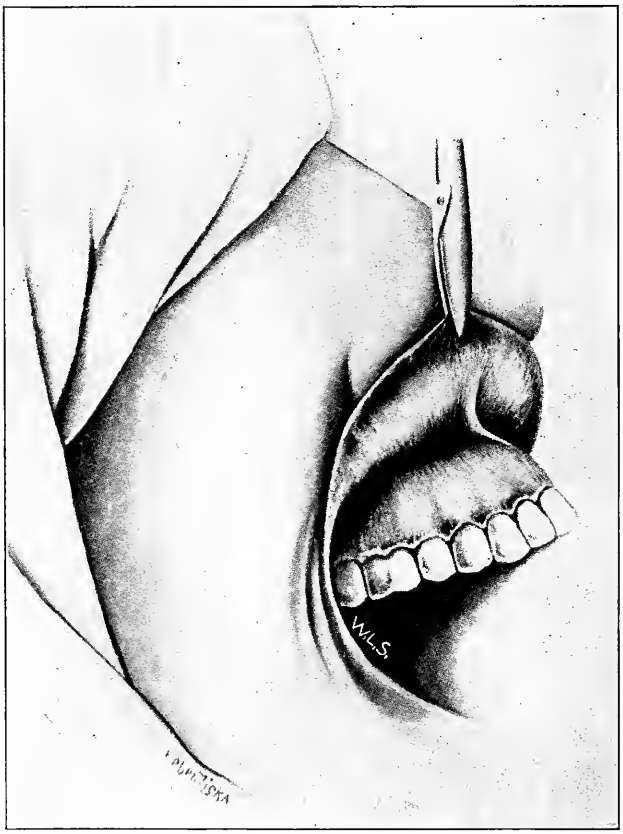

FIG. 509

External Alveolectomy.[1]—In cases of prognathism it is sometimes very desirable to remove the external alveolar plate in either the upper or lower jaws, or both, following the operation for the extraction of teeth. By so doing, a more efficient denture can be obtained. This operation can be done either under local or general anesthesia, and should be done immediately following the operation for the extraction of teeth when indicated. Fig. 509 shows a case in which such an

[1] The author is indebted to Dr. Wm. L. Shearer, of Omaha, Nebraska, for the valuable illustrations in the external alveolectomy and the modified external alveolectomy.

operation is indicated. After the extraction of the teeth the muco-periosteum is reflected back by means of a flat periosteal elevator to a point opposite the apices of the tooth sockets. This is shown in Fig. 510. Then by Rongeur forceps (Fig. 511) the external plate of the alveolar process is entirely removed. At the same time the border of the internal plate is made straight and smooth (Fig. 512). Following this, the internal and external margins of the periosteal flaps are trimmed so that even margins are obtained. The flaps are then brought together and sutured, bringing the outer and inner muco-periosteal flaps into normal position over the exposed bone, as illustrated in Fig. 513. The sutures should be left in for a period of

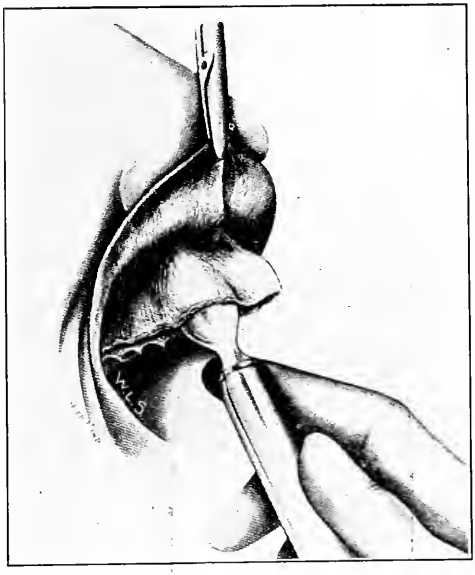

Fig. 510

about eight days. This operation can be used advantageously in any case following extraction of all the teeth. The operator can so shape the ridge of the mouth as to make an artificial denture more efficient.

Modified External Alveolectomy.—Modification of the operation of external alveolectomy may be made successfully in cases where extensive curettage is indicated. Fig. 514 illustrates a case where the buccal plate of the alveolar process is involved through to the muco-periosteum. Such a case usually represents an infectious process of long standing, or what is termed chronic dento-alveolar abscess. In some of these cases by raising the muco-periosteal flap, as illustrated, the granuloma will be raised with the flap and it is sometimes very adherent

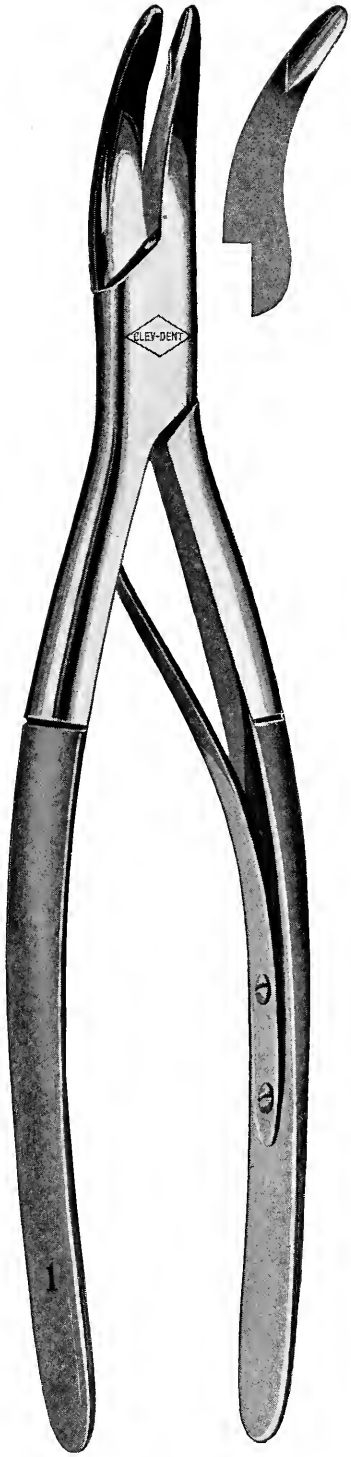

Fig. 511

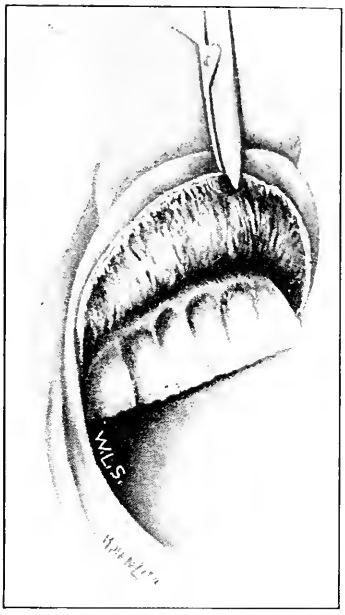

FIG. 512

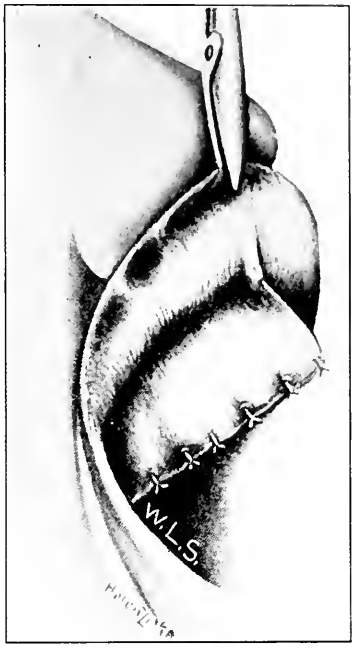

FIG. 513

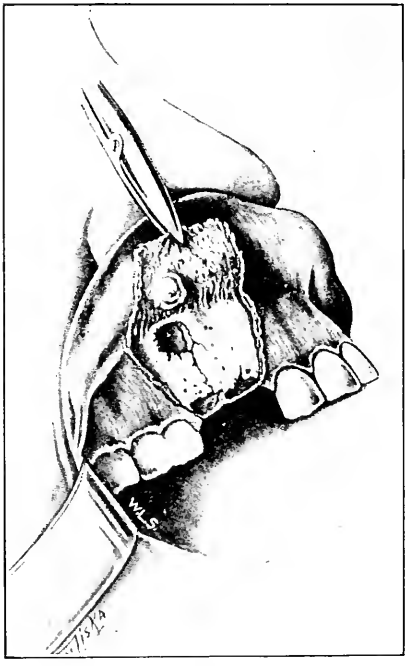

FIG. 514

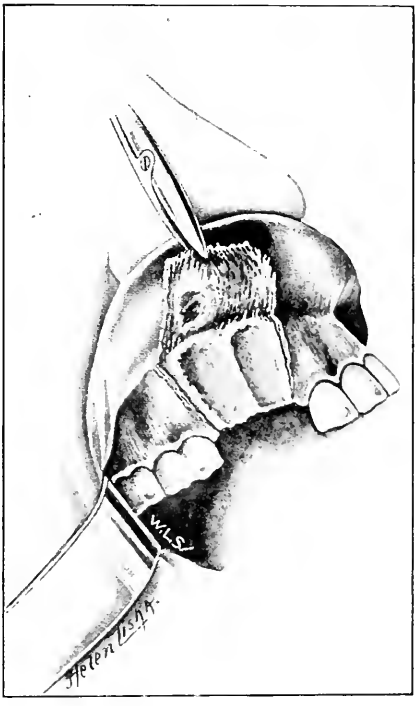

FIG. 515

by a tough fibrous tissue attachment. After raising the muco-periosteal flap, all diseased areas should be curetted thoroughly as shown in Fig. 515. This procedure is of advantage to the operator since he can see when he has curetted down to healthy tissue. The muco-periosteal flap is then returned to normal position and sutured as shown in Fig. 516. These sutures should be removed after six or eight days.

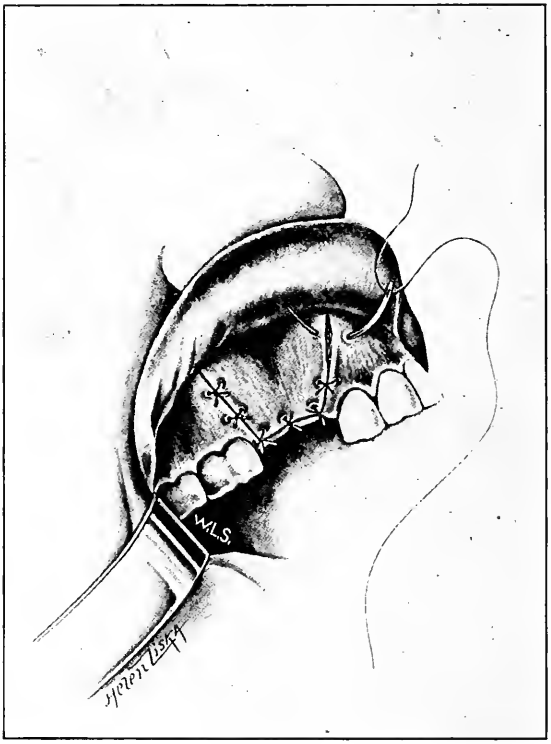

FIG. 516

The post-operative treatment for both the external alveolectomy, and the modified external alveolectomy consists of keeping the surfaces absolutely clean with sprays of 5 per cent. salt solution and painting the surfaces with 20 per cent. solution of argyrol.

Apicoectomy.—The author has previously referred to apicoectomy as a means of eradicating infection around certain teeth. It has seemed advisable to treat this subject following that of extraction of teeth.

Indication and Contra-indication for Apicoectomy.—For many years ends of roots of teeth have been excised under the names of root amputation, root excision, maxillotomy, apiectomy, apicoectomy, and root resection. As early as 1884 the technic of the operation was

described by Farrar. Many writers since that time have written on one phase or another of the subject until today it would seem that this is an operation that should become an important one in every well conducted dental practice.

Dental and medical science have made it clear that pathologic conditions of the pericemental membrane and diseased ends of the roots of the teeth are a contributing factor to, and frequently the primary cause of, general systemic disturbances. Dentistry must now assume the tremendous responsibility of eliminating these morbid conditions, either by the extraction of the teeth followed by a curettage or by some other surgical or therapeutic procedure.

It is a well known fact that with the present methods of root canal therapy few of these morbid conditions can be eliminated. Assuming then that our deductions are correct, there is only one course left open, namely, surgical procedure.

The surgical procedure can be accomplished in one of two ways—either by the extraction of the tooth and curettage, or by opening through the alveolar process, excising the diseased root end, and thoroughly curetting the diseased area.

The question now arises, how are we to make a correct diagnosis of the case so as to govern our surgical procedure?

No hard and fast lines can be drawn as to just where apicoectomy is indicated and where extraction of the tooth should be the operation of choice.

Apicoectomy is by no means a "cure all" for all conditions of chronic alveolar abscess when medicinal therapy has failed. Indeed it is the opinion of the author that in many of these cases the patient's welfare will be better taken care of if extraction of the tooth followed by curettage is resorted to.

What then are to be the signs and symptoms which will govern in the selection of the operation that is indicated?

A correct diagnosis of each case is not at all a simple matter. The first thing to take into consideration is the present state of health, past illness, and the possible recuperative or reserve force of the patient. The lowering of the vitality through chronic alcoholism or such diseases as tuberculosis, syphilis, and diabetes which lead to a state of constitutional dyscrasia will have a profound influence in preventing repair after these operations. In such cases the operation of choice in eliminating the pathologic conditions around root ends is extraction of the offending tooth followed by thorough curettage of the bone. Age may be a factor which should be considered in determining the indications and contra-indications for apicoectomy. In the aged the process of repair is slow and the prognosis for bone repair is

not so good as in the young or in the middle-aged. In a patient of advanced years it would be a question whether the cavity following this operation would be filled in with normal tissue. Particularly would this be true if there were much involvement of the apical area, consequently the operation would be undertaken with considerable hazard.

The normal or abnormal circulation of the blood is another factor that plays a very important role in the success or failure of the operation. It is an established surgical fact that without a certain definite blood supply to a part, repair of tissue will not take place. Notwithstanding the fact that the teeth and surrounding tissues have a very rich blood supply, in certain types of individuals and under certain pathologic disturbances such as in the anemic and poorly nourished, there is not sufficient blood supply to the apical area to insure repair of the parts after the operation. This condition is found in the young as well as in the aged, and the clever diagnostician will discover it before making his decision as to whether apicoectomy or extraction is indicated.

It is unfortunate that many men are depending entirely upon the roentgenogram in diagnosing mouth infection and are governing their whole course of treatment on this knowledge alone. They seem to overlook the fact that the roentgenogram is merely the shadow of conditions in the bone and does not show a picture of the pathology involving the parts.

In making the diagnosis which will lead to an operation such as apicoectomy, the roentgenogram must be used as only one of our means of forming our conclusions. The roentgenogram may show the appearance of greater pathology than is actually present and again the tooth root may be interposed between the ray and the morbid area in such a way that it may appear that little or no pathology is present; therefore the extent of the pathologic involvement that will appear to be present will depend upon the angle from which the roentgenogram is taken. This you will readily conceive is not sufficiently definite to rely upon wholly in forming a judicious and conservative diagnosis. The roentgenogram then should be considered only one link in the chain of evidence upon which we must base our decision. Then again, there may have been some involvement and rarefaction of the tissues before therapeutic measures were resorted to, which the patient's natural power of immunity and resistance will clear up after the infection has been eliminated from the canal and tubuli of the tooth.

If we can be satisfied that the end of the root is not denuded of its pericemental membrane, then, in the author's opinion, the case may be watched and a series of roentgenograms taken at stated intervals and

compared. The patient should be apprised of the fact that this particular tooth is under suspicion. Here again the general state of health of the patient must be considered, and the technic of sterilizing and filling the root canal must be a part of the chain of evidence which governs our procedure.

If the case be an alveolar abscess of long standing or an imperfectly filled root canal with granuloma where all the evidence points to disease and death of the pericemental membrane in the apical area, it is the opinion of the author that surgical procedure rather than dental therapy is indicated.

The character of the surgical procedure may be apicoectomy in favorable teeth and extraction of the teeth in unfavorable cases. What are to be considered favorable cases for apicoectomy?

The operation is often done with the view of saving a nice piece of bridge work and no attempt is made to eliminate the source of the infection. It should be a matter of routine that the canals and tubuli be sterilized and filled just previous to the operation. We are not doing good surgery when this is not done.

The most favorable teeth for this operation are single rooted teeth. This limitation has been made for two reasons. First, because of the accessibility of these teeth, a clean surgical operation can be performed. Second, sterilization and filling of the root canals can be made more accurate.

In multi-rooted teeth the patient's welfare will be better taken care of by extraction of the tooth followed by curettage of the bone. In no case should this operation be resorted to when the tissues are diseased beyond the apical third of the root of the tooth.

The success of the operation will depend upon whether or not the diagnosis has been correct. The welfare of the patient should be the first consideration and a hasty diagnosis may lead to an operation rather than a successful treatment of the condition.

Surgical Technic of Apicoectomy.—The foundation upon which the success or failure of this operation rests, is the condition of the root canals and tubuli, and the extent of pathologic involvement. It is imperative that the canals and tubuli be sterilized and the canals filled just preceding the operation. The possibilities[1] of reduced silver in the preparation of roots for resections, seem most encouraging.

The silver solution used for rapid reduction is made up as follows: silver oxid is precipitated from a silver nitrate solution with KOH or NaOH. This is carefully washed to remove all impurities and kept moist in a small amber-colored bottle. In this condition reduction is

[1] This is a modification of a method advocated by Howe for silver reduction.

so slight that it can be kept for a long time without much change. If a small amount is insoluble in excess of ammonia, there has been too much reduction and the silver oxid should be freshly prepared. This is the stock solution and it will be seen that it is more desirable than the ammoniacal solution made from silver nitrate, because it is free from nitric acid and other impurities.

When rapid reduction is desired as for apicoectomy, the silver oxid is added to a drop or two of ammonium hydroxid to the point of saturation. This forms silver ammonium oxid. In this state the ammoniacal solution is reduced easily. The case in which reduction takes place with this solution is so marked that burnishing with a warm glass rod is sufficient to reduce it to the lustrous metallic silver. A precaution that should be mentioned is that after a few hours, fulminates of silver may be formed from the ammoniacal solutions, which are very explosive. Serious accidents are possible from even wet solutions. Only very small amounts of ammoniacal solutions should be made and the unused portion discarded immediately after treatment. After complete reduction there is no danger and only old ammoniacal solutions, especially after drying, are to be avoided.

The following technic is the one used preparatory to resection: the canals are opened, using the rubber dam, and the silver solution is introduced to the very apex. Five or ten minutes are allowed for penetration before the reducing agent is applied. This treatment is applied several times. The canals are then very carefully filled by packing with small pieces of gutta-percha points softened by gently heating or other acceptable material.

Assuming now that the root canals and dental tubuli have been sterilized and the root canals properly filled, what is the modus operandi of apicoectomy?

In the first place, this operation consists of invading the soft tissues as well as the alveolar process, and a recognition of the difference between surgical and dental cleanliness must be made. If this operation is to take a place in conservative practice, the same surgical asepsis must be maintained not only in the field of operation, but with the operator as well, as would be necessary in any surgical work in the same or a similar field.

Local anesthesia, either conduction or infiltration, is the anesthetic of choice for this operation on account of the ability to secure the coöperation of the patient and to control the hemorrhage. These are factors not to be ignored. Clinical experience has demonstrated that an isotonic anesthetic solution if properly used does not interfere with the process of repair.

After the field has been anesthetized, the first step in the operation

is to remove the gross sepsis from the field of operation. This is accomplished by the use of alcohol to dry the surface over the field of operation, followed by swabbing with 7 per cent. tincture of iodin.

A curved incision is then made over the point where the tooth is to be resected, about 2 centimeters in length with the convexity toward the cervical line. The incision should be made through the muco-periosteum to the alveolar plate. The muco-periosteum is then raised by blunt periosteal elevators to form a muco-periosteal flap. By so doing, the outer plate of the alveolar process over the infected area is exposed. In some cases the outer plate will have become disintegrated so that the raising of the periosteal flap will expose the apical end of the tooth root. In other cases, when the outer plate of the alveolar process is intact, the apical end of the tooth root may be exposed by the use of sharp hand chisels, using them to cut away the outer plate until the root end is exposed. The author prefers the chisels for exposing the root end on account of the ability to preserve the landmarks during the entire operation.

A sufficient area of the outer plate should be removed so that the infected crypt and the apical end of the tooth root are exposed. The resection of the apical end of the root is made at the floor of the crypt and the root of the tooth is cut down to healthy tissue.

The Henahan surgical drill No. 4 is a very efficient instrument for the purpose of resecting the root. The resected end is now lifted out of the crypt and the pocket thoroughly curetted with spoon-shaped bone curettes. A large round bur is next used to smooth off the sharp edges of the alveolar plate and to cut the end of the root and base of the crypt down to healthy tissue. The cavity and root end is then polished with a gold finishing bur or stone.

Many procedures have been resorted to in the past to secure a protection for the exposed root end. Amalgam has been used with more or less success. Encapsulation with gutta percha has been used. Filling the apical end of the canal with gold has been tried. Filling the whole canal with lead canal points and, after resecting, burnishing the lead over the end has been practiced. All of these methods have met with objections. None has accomplished the full requirement of completely sealing over the exposed root end.

Silver reduced over the exposed ends of the root seems to meet the requirements of completely sealing the end of the root and does not seem to interfere in any way with the process of repair.

The technic for reducing silver over the resected end is as follows: the silver ammonium oxid is applied by suitable pipettes to the dry resected end of the root. It is left there for from three to five minutes after which a small amount of some reducing agent such as eugenol is

added and left for one minute. The excess is removed and the resected end burnished with a warm burnisher. The treatment may be repeated until there is a dense black layer of silver deposited over the root end.

After the process of reducing silver over the exposed end of the root is completed, the next question to decide upon is whether it is better to bring the edges of the flaps together and suture or to pack the wound and let the process of repair take place by granulation. Clinical experience has shown that when the crypt has not been too extensive, repair will take place more rapidly and with less pain when the wound has been sutured than when left open, Horse hair or fine dermal suture seems to be preferable to other materials for this purpose. Twenty per cent solution argyrol used as a spray over the wound immediately afterward and every twenty-four hours is indicated for postoperative treatment.

In extensive cases when it is deemed best not to close the wound, but to depend upon granulation for repair, iodoform gauze packed lightly into the crypt for twenty-four to forty-eight hours and then removed and the wound irrigated every twenty-four hours thereafter with 5 per cent. salt solution until repair is complete has been the treatment that has been followed in the author's clinics.

In checking up with the roentgenogram following the operation of apicoectomy, the fact must not be overlooked that the roentgenogram is merely the shadow of conditions present. In some cases it is not at all probable that the regeneration of the new tissue will have the same density as the original, consequently there may be for sometime a difference in the density of the shadow and to the inexperienced this may be misleading.

If this operation is to take its place in conservative dental practice, the diagnosis of the case will play a greater role in the success or failure than will the technic of the operation. In the final analysis, methods of procedure in the operation play only a small part, and the methods which are successful in one man's practice might be a failure in another's.

After all, the final results are the determining factors. There are four cardinal points to keep in mind: (1) a correct diagnosis of the case; (2) recognition and maintenance of surgical asepsis; (3) elimination of the infection; (4) complete sealing of the end of the exposed root.

If these principles are carried out in every case, the results will take care of themselves.

CHAPTER XV.

PRINCIPLES OF ORTHODONTIA FOR THE GENERAL PRACTITIONER.

By FREDERICK B. NOYES, B.A., D.D.S.

The author's purpose in the preparation of this chapter is to make as clear a statement as possible of the fundamental principles upon which the development of modern orthodontia has been based. It is not expected that it will furnish a sufficient basis for the practice of orthodontia, but that it will give the general practitioner a sufficiently clear grasp of the subject for him to coöperate intelligently with the specialist to the very great advantage of his patient. The general practitioner usually has the opportunity to see cases in their early stages, at the time when treatment should be begun and before so marked a deformity has developed as to attract the attention of the laity. It becomes a most important duty of the general practitioner to recognize deviations from the normal developmental mechanism, so that during the period of dentition normal occlusion may construct a normal denture and a balanced face. It is also hoped that it may give a sufficient statement of principles for the beginning of his study if he is attracted to this field of dental science.

The development of modern orthodontia from the chaotic condition of fifty years ago may fairly be said to have begun with the recognition of normal occlusion as the basis of the science. For this the dental profession is indebted to Dr. Edward H. Angle. Dr. Angle has defined orthodontia as "that science which has for its object the correction of mal-occlusion of the teeth," and he follows the definition immediately by the statement that "occlusion is the basis of the science of orthodontia." To combine these statements in one definition, orthodontia might be defined as the science of occlusion and the art of correcting mal-occlusion. One of the most important phases of the science of occlusion is the study of the relation of the teeth to the development of the face.

Occlusion.—Occlusion has been defined as the relation of the occlusal inclined planes of the teeth when the jaws are closed. Normal occlusion is the normal relation of these planes (Figs. 517, 518 and 519); mal-occlusion is any deviation from the normal relation. The study

of normal occlusion from the orthodontic standpoint has led to a very great development of our understanding of the meaning and importance of the relation of the occlusal inclined planes of the teeth. This is

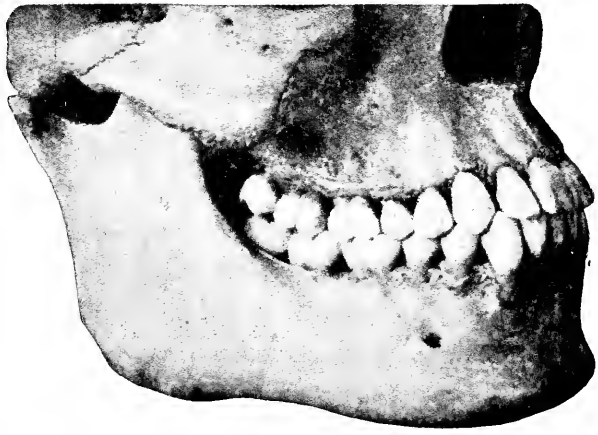

FIG. 517.—Typical occlusion. (Broomell.)

FIG. 518.—Typical occlusion; lingual view. (Cryer.)

seen to be not merely the relation of cusps for the purpose of the mastication of food, but a mechanism for the development of the denture as a whole and the maintenance of it in perfect function. Occlusion becomes therefore not simply a means of mastication but a developmental mechanism, through which all of the forces of function are distributed in perfect balance, bringing about the normal development of the bones of the face, the development of the denture as a unit and the maintenance of each tooth in its perfect position.

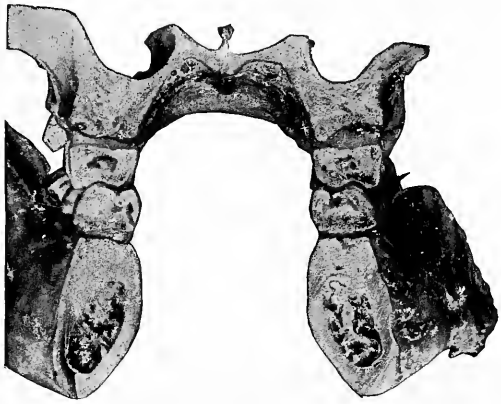

FIG. 519.—Typical occlusion of molars; transverse view. (Cryer.)

OCCLUSION. THE DEVELOPMENTAL MECHANISM.

In considering occlusion as a developmental mechanism there are two phases to be studied: first, the relation of the occlusal inclined planes of the teeth, which receive and distribute the forces of function; second, the forces of function, which are distributed through the occlusal inclined planes of the teeth and bring about the normal development of the supporting bones. A perfect denture and a normal face therefore can only be developed by a perfect mechanism and normal functional forces. If the relation of the inclined planes is abnormal the forces of function will drive that tooth farther and farther from its normal position and unless the forces of function are normal in amount and in proper balance the supporting bones will not be developed so as to carry the teeth to their proper relation to the skull as a whole.

From the orthodontic standpoint the unit of the mechanism is a single cusp. Each cusp may be represented as a four-sided pyramid, presenting four inclined planes: (*a*) mesio-buccal; (*b*) disto-buccal; (*c*) mesio-lingual; (*d*) disto-lingual.

For instance, the buccal cusp of the lower second bicuspid occludes

with the four cusps of the upper bicuspids, its mesio-buccal slope antagonizing the disto-lingual slope of the buccal cusp of the upper first; its mesio-lingual slope antagonizing the disto-buccal slope of the lingual cusp of the upper first; its disto-buccal slope meeting the mesio-lingual slope of the buccal cusp of the upper second bicuspid; and its disto-lingual slope, the mesio-buccal slope of the lingual cusp of the second bicuspid. It is therefore wedged in position both mesio-distally and bucco-lingually. The more powerful the forces of function the more perfectly the tooth is held in position. In the entire denture, therefore, each cusp is the unit upon the perfect relationship of which is dependent the perfect development and maintenance of the denture. No single slope can be lacking without producing its modification in the support of the entire machine. The problem of orthodontia becomes that of establishing and maintaining the normal relation of these inclined planes and the development of the normal forces which, distributed in perfect balance, bring about the normal development of the features, the perfect development of the masticating apparatus, the health of the supporting tissues and constitute the most important factor in nature's method of cleansing the surfaces of the teeth by the mastication of food, and consequently the prevention of caries. The beginning of the study of orthodontia, therefore, must be the thorough and detailed study of the relation of the inclined planes of the cusps of the teeth in the fully developed and ideal denture. This is just as important for the general practitioner as for the orthodontist, for the preservation of the denture, the health of the supporting tissues and the prevention of caries depend upon the preservation or restoration of the cusps of the teeth and all their inclined planes. In the past the dental profession has been too prone to be satisfied with "having teeth meet" without regard to their cusp relationship.

The Development of the Denture.—Every practitioner of dentistry should have as clear an idea as possible of the development of the normal denture and a grasp of the complicated and interrelated forces which are at work throughout this whole period of growth. The most important factors in this process can best be studied from a series of skulls from infancy to adult life. At birth the maxillary bones contain the germs for all of the temporary teeth and all the permanent ones except the second and third molars. The growth of these teeth in their crypts exerts forces which are most important factors in the development of the bones. Fig. 520 shows the maxillary bone of a child of about one year, with the outer plate removed so as to expose the developing teeth. Fig. 521 shows one at about one and a half years. The incisors have erupted and the growth of the unerupted cuspid and molars exerts forces which tend to carry them in an occlusal and outward

direction. The multiplication of cells in the formation of the roots is a very important source of force which is transmitted from the

FIG. 520.—Maxillæ at about one year.

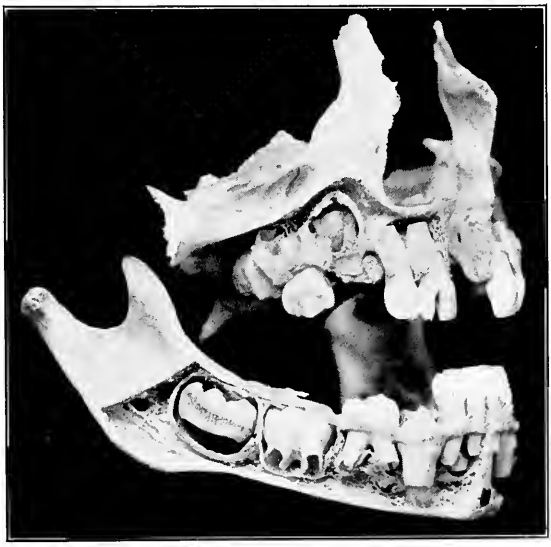

FIG. 521.—Maxillæ at one and one-half years.

erupting teeth to the teeth already in position. In Fig. 522 from the skull of a child in the second year the second temporary molars are seen

to be exerting forces which carry the incisors and cuspids occlusally and outwardly. In this process the entire bone is undergoing rapid transformations, increasing the distance from the floor of the nose to the incisal edges of the teeth and the thickness of the mandible from the lower border upward. In all of this period the action of all of the muscles attached to and surrounding the bones exerts pressures which help to mold this growth. At about three years the temporary denture is complete. A comparison of Fig. 523 with the previous figures shows the changes in the bone. During the period of the function of the

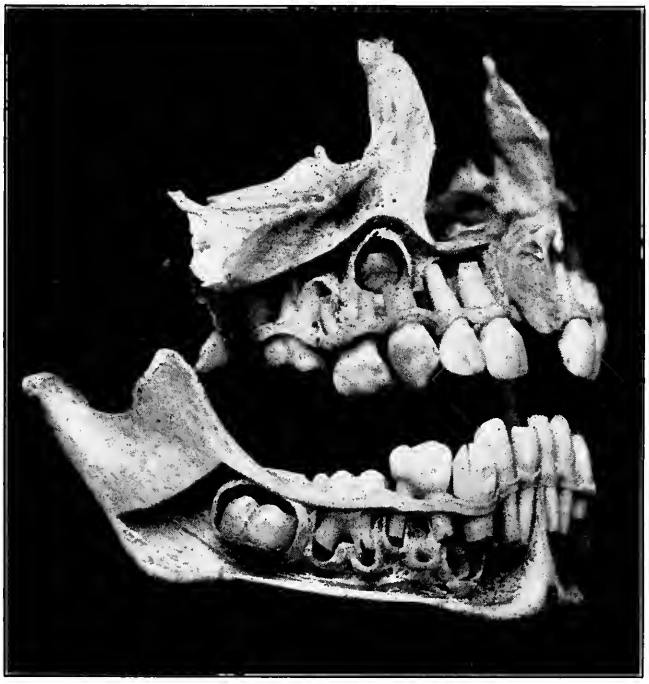

FIG. 522.—Maxillæ in the second year, showing the relation of the erupting teeth. Note the relation of the crypt of the second molar to the inferior dental canal.

temporary denture, from three to six years of age, while the teeth retain their same relation to each other, they do not retain the same relation to the skull. During this entire period they are constantly moving in three dimensions of space, under the influence of muscular pressures and forces exerted by the development of the permanent teeth. For the present we shall consider only the forces exerted by the developing teeth. Each permanent tooth is enclosed in a bony wall or crypt. The multiplication of cells within this crypt pushes the wall back until the resistance below is greater than the resistance above. Between

five and six years of age the first permanent molars in their crypts exert forces at the distal of the temporary denture, carrying all of the temporary teeth forward and occlusally until room has been made for their eruption. The second temporary molars guide them into relation with their antagonists, but there is a period when they are coming into occlusal relation, during which comparatively slight variations from normal muscular pressures and action may cause their cusps to lock abnormally and pervert the whole future development. The first permanent molars should erupt and lock their cusps in normal relation before the first temporary tooth is shed, and during the whole period in

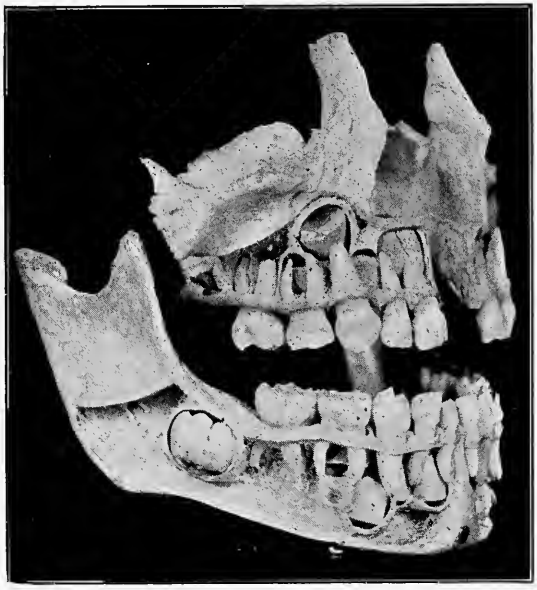

FIG. 523.—The complete temporary dentition (about three years), showing the relation of the developing permanent teeth.

which the permanent teeth are being substituted for the temporary ones the first molars maintain the relation of the maxilla and mandible. The importance of the normal locking of these teeth will therefore be recognized at once. The abnormal relation not only shifts the position of the mandible with reference to the maxilla but changes the balance of muscular forces, which modify the development of the entire mandible. Every child should be examined when the first molars are erupted to see that they lock their cusps in normal relation.

Between the ages of five and seven the most active growth is in the region of the incisors, increasing the arc from cuspid to cuspid and

making the room required for the increased size of the permanent incisors. While at four years the temporary incisors should be in contact with each other on their mesial and distal surfaces, before they are shed they should be standing wide apart with large spaces between them. This is brought about by the development of the permanent incisors and cuspids, and the relationship of the root of

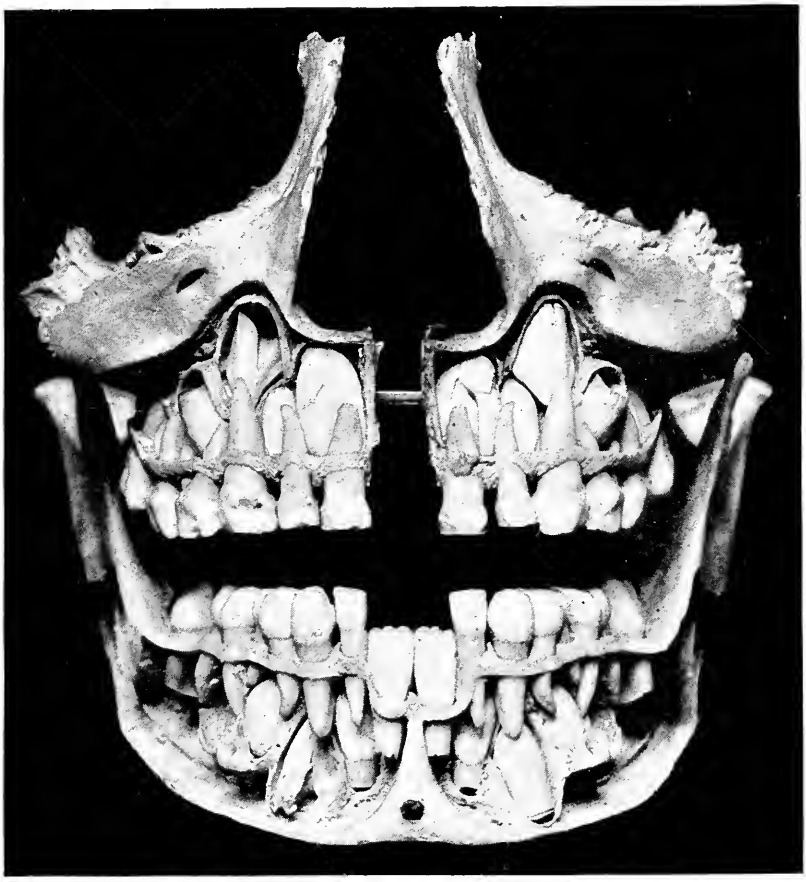

FIG. 524.—Front view of the skull. Note the relation of the permanent incisors and cuspids to each other and the roots of the temporary teeth.

the temporary cuspid to the tip of the developing permanent cuspid is a most important factor. The normal relationship is shown in Fig. 524. As the permanent teeth develop they carry the temporary teeth, alveolar process and all, in an occlusal and outward direction. The loss of any factor in the relationship will result in the failure of the proper distribution of forces. For instance a slight shifting of the

temporary cuspid distally because of the loss of temporary molars, in whole or in part, will cause its root to lose the normal relation to the permanent cuspid and the growth of the long cuspid root will not bring about the normal development of bone in this region (Fig. 525).

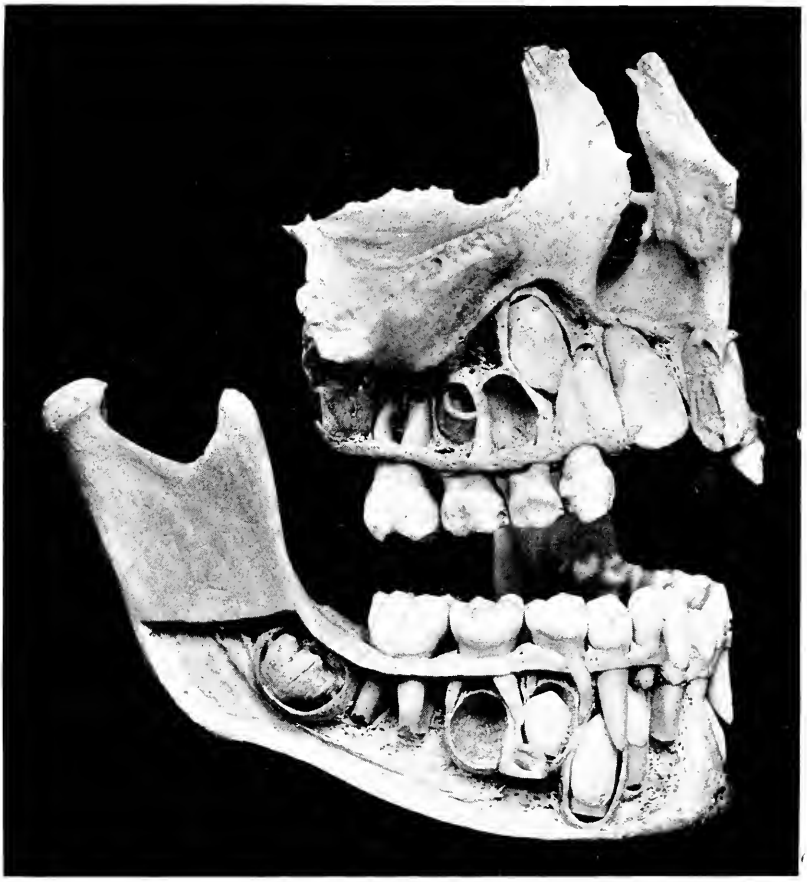

FIG. 525.—Dentition in the eighth year. Note the position of the cuspids and compare with Fig. 526.

Between the ages of six and eight the permanent incisors come into place and take their normal relationship. Between the ages of eight and eleven growth is most active in the region from the cuspid to the second molar and is largely dependent on the development of the bicuspids, which force the temporary molars occlusally, and on the development of the second molars, pushing at the distal of the first (Figs. 526, 527, 528 and 529). It is important to emphasize that dur-

ing the entire period of development the teeth are moving under the influence of developmental forces and are being carried into new positions with relation to the skull by the growth of bone. The process is dependent upon the maintenance of each tooth until the normal time for its loss, and the extraction of a tooth does not make more space but

FIG. 526.—Dentition in the eleventh year. Note the growth of the cuspids and bicuspids. The second molar is about to erupt.

less. It would seem unnecessary to emphasize the importance of the temporary molars. Nature provides a slightly greater mesio-distal diameter of the temporary molars as compared with the bicuspids so as to allow space for their eruption. If the temporary molar is prematurely lost the second permanent molar will crowd the first molar mesially before the bicuspid can take its place.

After the eruption of the second molars and bicuspids the movement of all of the teeth in the denture should continue under the influence of muscular pressure and the growth of the third molars. Compare in Figs. 527 and 529 the distance from the tip of the upper incisor root to the floor of the nose and of the lower incisors and cuspids to the lower border of the mandible, between the ages of thirteen and a fully developed adult. This growth seems to be dependent upon the vigor of muscular action which stimulates cell activity in the bone not only by mechanical influence but by the increase of blood circulation.

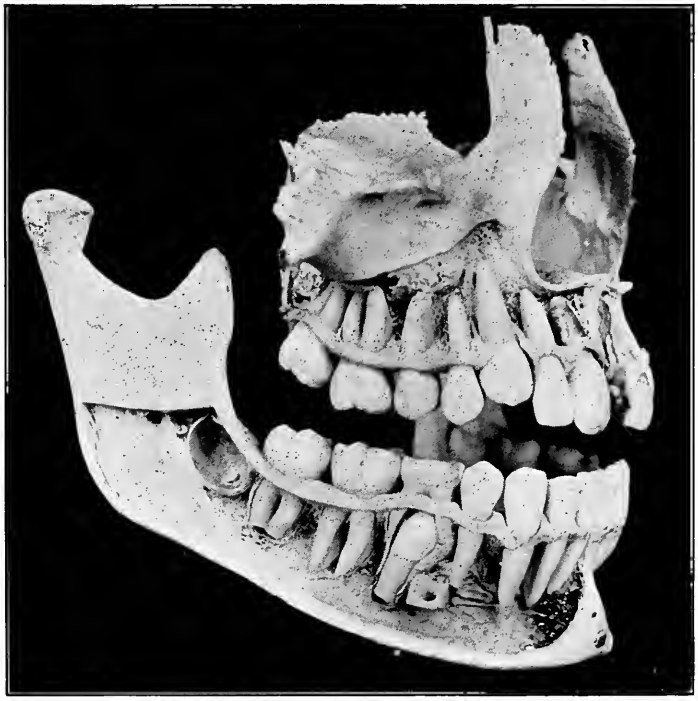

FIG. 527.—Dentition in the thirteenth year. Note the relation of the bicuspid crown to the roots of the lower temporary molar.

The Forces Governing Occlusion.—The forces governing occlusion are defined as those forces which tend to guide the teeth into their normal relation to each other and their normal position with reference to the skull. They may be divided into two classes—potential forces and dynamic forces. The potential forces are: (1) the occlusal inclined planes of the teeth, which distribute through the opposing planes the forces of function and growth; (2) the contact of approximating surfaces of the teeth, which distribute through the entire denture the forces of developing and unerupted teeth; (3) the resultant

harmony in the size and relation of the arches. Through these potential agencies the dynamic forces are distributed.

The dynamic forces are: (*a*) cell activity; (*b*) muscular action and pressure: (1) respiration; (2) deglutition; (3) mastication; (4) speech; (5) expression; (6) atmospheric pressure; (7) attention and muscular tone.

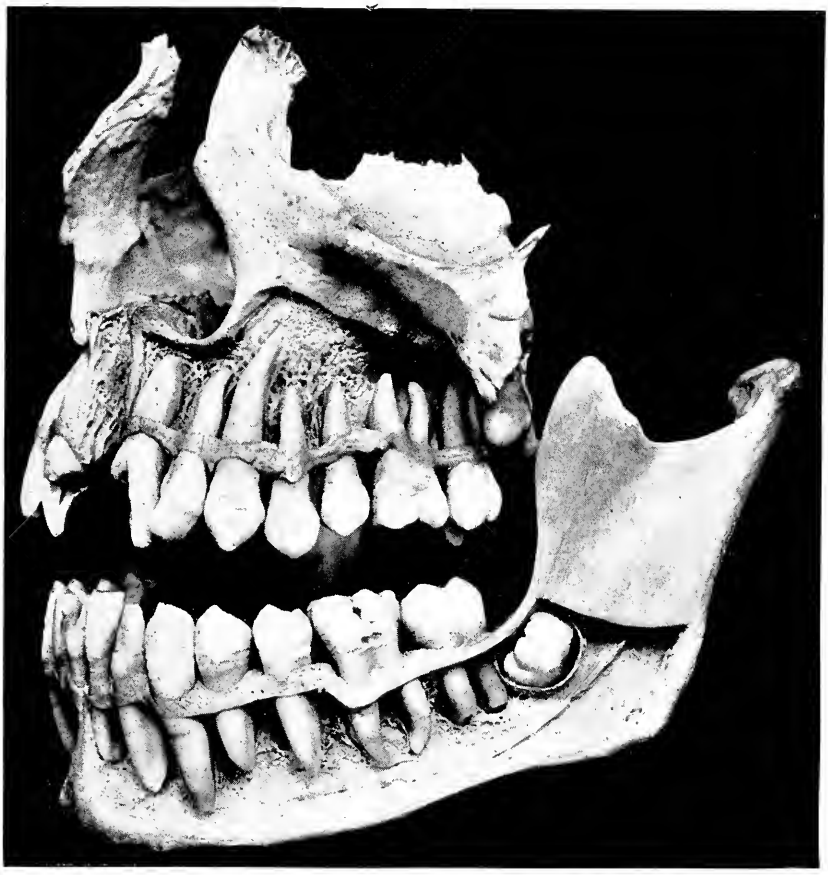

FIG. 528.—The dentition of a young adult. The third molars have not erupted. (About fifteen years.)

(*a*) **Cell Activity.**—It has long been known that in the multiplication of cells very considerable forces are generated. The sprouting seed forces its way through the earth; growing rootlets, entering between stones, force them apart. The forces generated by the multiplication of plant cells have been studied and more or less accurately measured

by botanists. The same forces in the multiplication of cells in the growth of the tooth germ and in the development of the tooth roots are important sources of dynamic energy in the development of the denture. Not much is known of their nature, but they are evidently dependent upon general nutrition and vital energy. We see many instances, especially in frail individuals, in which the cellular activities do not manifest sufficient energy to exert their normal forces.

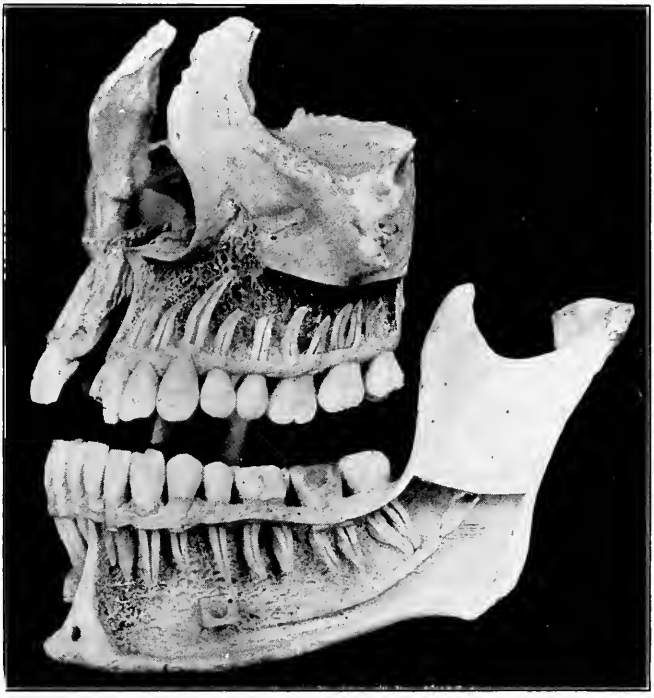

FIG. 529.—Adult dentition. Note the distance from the apices of the incisors to the lowest border of the mandible and the floor of the nose.

(*b*) **Muscular Action and Pressure.**—All of the forces generated by muscular action in the performance of function are distributed through the potential forces and the growth of the supporting bones is a response to these mechanical stimuli. The positions which the teeth come to occupy are dependent upon the vigor and balance of these functions. Failure of normal action or abnormal balance of action results in proportional underdevelopment of bone and modification of the denture, and may lead to the perversion of the potential forces. It may be worth while to examine somewhat in detail the action of the individual functions.

1. *Respiration.*—Respiration is probably the most important function with reference to the development of the denture, for it is in constant action. Nature intended man to breathe through the nose. In order to exert its normal influence respiration must be not only normal in performance but sufficiently vigorous in action. In forced respiration the muscles attached to the hyoid bone are vigorously contracted, drawing the tongue upward and forward, forcing it against the lingual surfaces of the teeth and the supporting bones. This is one of the most important factors in the development of the dental arches. The author has been amazed at the instruction given by physical directors in high schools in training boys for track teams to have them breathe through the mouth.

2. *Deglutition.*—The normal individual who breathes through the nose swallows about once in two minutes, night and day. In this act the muscles attached to the hyoid bone are also contracted, and pressures are exerted as in forced respiration. One need only to close the lips and swallow voluntarily to be conscious of the pressures exerted. When breathing is carried on normally the secretions collect in the mouth and are expelled by swallowing, so that this impulse to growth is repeated at frequent intervals, night and day, and becomes an important factor in development. If respiration is carried on through the mouth the secretions are evaporated by the air, swallowing is omitted and this impulse to growth is lost, with consequent lack of development in the dental arches.

3. *Mastication.*—While mastication is the first functional force to be thought of in connection with the development of the dental arches it is undoubtedly not the most important, for it is most intermittent in action. On the other hand its action has the most direct influence upon the bone of the alveolar process, stimulating both its blood supply and its cell activity. It is the grinding motions of the teeth which exert the most influence in modifying the form of the dental arches. In this action the lower teeth are forced against the lingual slopes of the buccal cusps of the upper teeth in such a way as to tend to widen and round the dental arches. This is markedly seen in the study of the relation of the diet to the form of the denture in different races. The meat-eater tends to have a long narrow arch; the vegetable-eater, a broad, round arch. Many cases of mal-occlusion would never develop if the child ate the shredded wheat biscuit and drank the cream instead of soaking the cereal and swallowing it without mastication.

4. *Speech.*—Space will not permit the detailed examination of the influence of speech on the development of the denture and the bones of the face, but it exerts an important influence, especially in the forces

acting upon the labial and buccal surfaces of the teeth and bones. It is interesting to note that anthropologists have long since pointed out that the development of the chin begins with the power of speech, and all forceful speakers have a well-developed chin. Training in elocution sometimes becomes a help in the correction of mal-occlusion.

5. *Expression.*—Most mental states are accompanied by action of the facial muscles, which react through the potential forces in the molding of the bones. Certain mal-occlusions are undoubtedly related to habitual mental states, and in a very literal way every thought molds not only the expression but the framework of the face.

6. *Atmospheric Pressure.*—Atmospheric pressure is closely related to the function of deglutition and nasal breathing. In swallowing with the lips closed the air and liquid contents of the mouth cavity are expelled, the soft palate is brought into contact with the posterior portion of the tongue, and, as the muscular action relaxes, a partial vacuum is produced, which exerts a downward pressure upon the roof of the mouth, a pressure of the lips against the labial surfaces of the incisors, and pressure against the lingual surfaces of the buccal teeth. In nasal respiration, inhalation and exhalation, in proportion to their vigor, produce alterations of atmospheric pressure in the nasal spaces and their accessory sinuses, which, exerted against the walls of these cavities, bring about their normal development.

7. *Attention and Muscular Tone.*—In recent literature we have often seen the statement that the occlusal surfaces of the teeth are not held in contact. This statement is literally true of the idiot but not of the normal individual. In proportion as the attention is directed and concentrated the teeth are brought firmly in contact. To demonstrate this, one need only see a child sitting in a dreamy state with the lips parted and jaw dropped, and speak to him quickly or sharply and see the lips tighten and the teeth come together with a click. The lack of concentration and attention as a general state is responsible for a lowering of muscular tone, not only in the muscles of the face, but of the entire body. It is important to remember that we cannot expect to have the normal muscular tone in the muscles which mold the denture if it is absent in the general muscular system.

In the consideration of the forces governing occlusion, therefore, we see in the potential forces a machine which, actuated by the power generated by the dynamic forces, molds the entire development of the features. In order that the face may become the expression of the individual and an index of his personality, we must maintain through the developmental period the perfect action of the machine and the normal balance of the forces.

ETIOLOGY OF MAL-OCCLUSION.

1. Mechanical.
   (*a*) Loss or perversion of the potential forces governing occlusion.
   (*b*) Premature loss of temporary teeth in whole or in part.
   (*c*) Prolonged retention of temporary teeth.
   (*d*) Loss or absence of permanent teeth.
   (*e*) Improper or imperfect restorations.
2. Abnormal functional habits.
   (*a*) Abnormal breathing and lack of sufficient vigor of breathing.
   (*b*) Loss of normal swallowing.
   (*c*) Snuffles and similar habits.
3. Abnormal nervous habits.
   (*a*) Thumb sucking.
   (*b*) Lip and tongue habits.
4. Psychological.
   (*a*) Associated with mouth-breathing.
   (*b*) Mental states.
5. Pathologic conditions.
   (*a*) Destruction of supporting tissues.
   (*b*) Pathologic growths.
6. Accidents and injuries.
   (*a*) Mutilations.
   (*b*) Burns.
7. Freaks and deformities.

From the study of the development of the normal denture it is apparent that the causes of mal-occlusion are but the perversion of nature's plan. The purposes of this chapter do not allow for the elaboration of these in detail.

NOMENCLATURE AND CLASSIFICATION.

Seven words and their combinations will describe accurately any position that a tooth out of harmony with the line of occlusion may occupy. These terms are generally accepted and used in the literature of orthodontia.

1. Labial or buccal occlusion.
2. Lingual occlusion.
3. Mesial occlusion.
4. Distal occlusion.
5. Infra occlusion.
6. Supra occlusion.
7. Torso occlusion.

Two or even three of them may be combined in the description of the position of a single tooth. For instance, a canine nearer the median line and farther to the labial than normal, and at the same time turned on its axis, would be said to be in mesio-labio-torso occlusion.

Classification.—The Angle classification has undoubtedly been one of the very important factors in the development of orthodontia, since for the first time in the history of the subject it gave a scientific grouping of cases upon which the procedures in treatment could be based. The Angle classification is great because it is not an arbitrary grouping of cases by the mesio-distal relation of two teeth, but the mesio-distal relation of the first permanent molars is recognized as the most important single factor in the development of the denture, and therefore it is made the basis of the grouping. Whatever modification there may be in it in the future it will undoubtedly remain fundamentally unchanged.

Before giving the classification of mal-occlusion I want to quote this paragraph from Dr. Angle's book, stating the basis of classification. He says:

"These classes are based on the mesio-distal relations of the teeth, dental arches and jaws, which depend primarily upon the positions mesio-distally assumed by the first permanent molars on their erupting and locking. Hence, in diagnosing cases of mal-occlusion we must consider, first, the mesio-distal relations of the jaws and dental arches as indicated by the relation of the lower first molars with the upper first molars—the keys to occlusion; and second, the positions of the individual teeth, carefully noting their relations to the line of occlusion.

Class I.—Arches in normal mesio-distal relations, as indicated by the first molars.

Class II.—Lower arch distal to normal in its relation to the upper arch, as indicated by the first molars.

Division II.—Bilaterally distal, protruding upper incisors. Primarily, at least, associated with mouth-breathing.

Subdivision.—Unilaterally distal, protruding upper incisors. Primarily, at least, associated with mouth-breathing.

Division.—Bilaterally distal, retruding upper incisors. Normal breathers.

Subdivision.—Unilaterally distal, retruding upper incisors. Normal breathers.

Class III.—Lower arch mesial to normal in its relation to upper arch, as indicated by the first molars.

Division.—Bilaterally mesial.

Subdivision.—Unilaterally mesial.

Every practitioner of dentistry should be thoroughly familiar with this classification and able to recognize any mal-occlusion at once, and

name the divisions or subdivisions to which it belongs. It is so simple and so easily grasped that a very little consideration will enable anyone to do this.

FUNDAMENTAL PRINCIPLES OF TREATMENT.

Growth Not Tooth Movement.—The first great fundamental principle that must be clearly grasped in considering treatment is that during the entire period of growth the teeth are moving in three dimensions of space by the development of bone under the influence of natural forces. This movement in no way differs from ideal movement by artificial force, and the tissue changes in the two are identical. The author could show in sections identical reactions of bone to natural forces and to properly controlled and directed artificial forces exerted upon the teeth by mechanical appliances. The teeth are not, or should not be, *pushed through the tissues,* but are carried by tissue activity into their normal positions and relations.

Treatment must force, or, better, enable nature to carry out her ideal or intention, and so teeth should move in the direction and the manner of the normal process. To illustrate, a dental arch is to be widened at the first bicuspids. While the teeth are moving buccally they are also moving occlusally. Incisors are to be moved labially, but while they are moving in that direction they are also moving incisally, increasing the distance from the floor of the nose. It has been the tendency to think of tooth movement in terms of two dimensions. It should be thought of in three dimensions. The tissues respond better and more easily to stimulation to growth in their normal directions than to forces opposed to them.

In natural processes growth is intermittent. A period of rapid advance is followed by one of organization and the gathering of forces for a new advance. In the stimulation of growth by artificial forces the stimulus should not be repeated more rapidly than the tissue can organize and prepare for a new growth. Time was when orthodontic appliances were tightened every day or two. No tissue could maintain such a pace.

Whatever the form of appliance used to generate the force the force must be *positive in character, constant in direction, moderate in amount and limited in range of action.* Inflammation is at once set up in the tissue if the tooth is allowed to move back and forth or if the force is constantly changing direction. It is surprising how quickly soreness can be set up when these conditions occur.

Time of Treatment.—As soon as a definite fault in the mechanism of development which makes its further normal action impossible is

discovered it should be corrected, so that the natural forces may continue normal development. Mal-occlusion in the temporary denture is comparatively rare, but if it occurs it should be corrected at once and every effort made to establish and maintain the normal developmental mechanism. While the author is heartily in favor of early treatment the most common mistake that is being made at present is the wearing of inefficient appliances continuously for long periods. There are definite periods in which certain things should be done. The work should be accomplished rapidly with a positive and efficient appliance, the results maintained, and then nature given a chance to carry on her work under the normal influences of growth.

Periods of Active Treatment.—In the development of the denture there are certain periods of danger, and especially active growth. These should be the periods of active treatment.

1. *The Eruption of the First Permanent Molars.*—If when these teeth erupt they do not lock normally, appliances should be placed on the teeth and the necessary movements accomplished to lock them normally. They should then be retained in their normal relation until their cusps have been firmly locked, when all appliances should be removed and nature allowed to proceed.

2. *When the Permanent Incisors Erupt.*—If the development in this region is deficient appliances should be placed, the necessary development accomplished and retained for a comparatively short time and nature allowed to proceed again.

3. *While the Bicuspids and Second Molars are Erupting.*—This should be the final period of treatment. Very often work during this period is commenced too soon and as a result it is necessary to wear appliances for a long time, waiting for the eruption of some tooth.

Time of Completion of Treatment.—All orthodontic treatment should be completed by the time the second molars are in full occlusion, but because of the deficiency of the forces which should cause the development in the width of the arches it is often necessary to use some simple method of maintaining the width for a long time.

Means of Treatment.—There are two means of treatment at the command of the orthodontist:

1. The use of artificial forces derived from mechanical appliances.

2. The development and stimulation of natural forces of function.

In the past it is certainly true that too much attention and reliance have been placed on the first and too little on the latter. It is much easier to make an appliance to replace or supplement a deficient natural function than to develop it to normal power. During active treatment positive and efficient appliances should accomplish definite results as rapidly as possible. During retention and between periods of active

treatment attention should be given to the development of the natural forces, for it must be remembered that throughout life the teeth remain only in the position in which all of the forces to which they are subjected are balanced.

Complications of Treatment.—*Caries.*—Caries during orthodontic treatment is a serious matter and requires the coöperation of the orthodontist, the dentist, the parents and the patient. With reasonable coöperation of all there is no reason for damage to the teeth. With the modern appliance the teeth can be kept clean with reasonable effort. Three things are most important:

1. The care of the teeth by the dentist before treatment and in intervals between active treatments.
2. The systematic instruction and training of the patient in cleansing the mouth.
3. The insistence upon carrying out of the instruction.

Loss of Dental Pulps.—Pulps may be destroyed by unreasonable and improper application of force through orthodontic appliances, but it seems equally certain that reasonable use of appliances will not endanger the life and activity of the pulp. Many cases of pulp destruction during treatment are in no way related to the treatment. In the last few years the author has seen several instances in which pulp destruction occurred during treatment in teeth that had never had any artificial force applied to them and the occurrence could not possibly be referred to the treatment.

Inflammation of the Gums.—Hypertrophic inflammation of the gum margins caused by filth is not uncommon in children from eight to twelve years of age. The same condition sometimes occurs during orthodontic treatment. It is caused by lack of proper mouth hygiene, but may be augmented by sloven technic in the application of bands. When it occurs the bands must be removed and the conditions reduced. If it cannot be prevented when the appliances are replaced the treatment should be abandoned until the patient can be made to keep the mouth clean.

Absorption of Permanent Tooth Roots.—This is probably due to improper application of force, the attempt to move teeth in an impossible direction or improper control of force. Such absorptions occur, however, in rare instances when there has been no orthodontic treatment, and caution should be used in blaming the treatment for it without good evidence. When it is caused by the orthodontic appliance the author believes that it is usually the result of lack of constancy in the direction of the force, or by forcing the root against some such impossible resistance as the root of another tooth.

PRINCIPLES OF ORTHODONTIC TECHNIC.

The first requirements in orthodontic procedure or examination are:

1. Perfect models from accurate plaster impressions which show not only the teeth and their occlusal relations but the details of bone structure as far as the attachments of the soft tissues will permit.

2. Photographs of the face showing correctly the features in repose, both front view and profile, and

3. Roentgenograms showing the roots of the teeth and unerupted teeth. Instruction in technical methods is beyond the scope of this chapter. For such instruction those interested are referred to the standard text-books.

The record of the original conditions is the foundation of all treatment, and no adjustment should ever be made without first determining the distance and direction in which the tooth has been moved and exactly what is to be accomplished by the adjustment contemplated. If fewer adjustments were made and each were studied more carefully orthodontic treatment would be accomplished faster and better.

Soldering.—Orthodontia has developed a soldering technic which is fundamentally different from that used generally in dentistry. In dentistry large masses of solder are used to unite masses of metal often widely separated. The principles of orthodontic soldering are:

1. Perfect contact of the metal surfaces to be united.

2. Perfect union with the smallest amount of solder. Strength depends upon perfection of contact and area of surface united.

Sloppiness in soldering is a common cause of inefficiency in an appliance. For instruction in soldering technic the student is referred to text-books on orthodontia, but the beginner must realize that he is to master a new set of principles not generally used in dentistry.

Appliances.—It is not the appliance but the intelligence with which it is used that accomplishes results in orthodontia. Undoubtedly results may be obtained with very clumsy and inefficient appliances used with skill and knowledge. The rational method is to find the appliance that will furnish the most positive and efficient force under the most perfect control and then learn to apply it with knowledge, judgment and skill. Satisfactory results will never be attained by using a different appliance in each case.

In the author's opinion the ribbon arch and bracket band appliance possesses the above requirements to a greater degree than any instrument yet devised, but it will never be used with success except by those who exercise the most painstaking accuracy and skill in its adjustment and the highest degree of knowledge and judgment in its application. An inefficient appliance is less dangerous in careless and inexperienced

hands than an efficient one, for it will produce results so slowly that undesirable results may be noted before serious damage has been done while improper adjustment of an efficient instrument produces bad results with the same precision that proper adjustment does in bringing about the desired end.

Retention.—There are three periods in retention:

1. Fixation.
2. Antagonizing tendency to return to old position.
3. Establishment of the normal balance of forces.

After teeth have been moved from a position of mal-occlusion into harmony with the line of occlusion they must be fixed in the new position for a very brief period—just long enough for the primary readjustment and reorganization of the supporting tissues. This is best accomplished by allowing the working appliance to remain in a state of rest for a short time.

If appliances are removed the teeth will rapidly return to their original positions. The retaining device should antagonize this tendency to return, but limit the freedom of the teeth in no other way, leaving them exposed to all the action of the normal forces. If in the new position the forces are balanced the supporting tissue will rapidly be completely reorganized. The obtaining of the normal balance of force is often the most difficult problem, especially when it involves the breaking up of old and long-established abnormal functional habits and the establishment of new and normal ones.

In concluding this chapter, which has sought to give the general practitioner an elementary statement of the fundamental principles of orthodontia, it may be said that orthodontia is a part of dentistry only in the sense that it has to do with the teeth and mouth. Dentistry is the study and treatment of the diseases of the mouth and their relation to the health of the individual. Orthodontia is the study of the development of the denture and the correction of deviations from normal. Dentistry has to do with pathologic processes, orthodontia with normal developmental processes. Orthodontia is in no sense a part of prosthetic dentistry, and the fundamental principles upon which its practice is based are not involved in the practice of dentistry. If the general practitioner can grasp this idea there will be better coöperation between the dentist and the orthodontist for the good of the patient and humanity.

CHAPTER XVI.

ROENTGEN DIAGNOSIS IN OPERATIVE DENTISTRY.

By KURT H. THOMA, D.M.D.

One of the greatest aids in examination of the mouth and teeth, in diagnosis of oral lesions and in the discovery of obscure defects and abnormalities, is the roentgen method. Its usefulness has increased to such an extent that today it is a necessary part of modern dental practice, not only for the purpose of examination but also to check up the result of mechanical procedures and surgical treatment. The diagnosis from a roentgen picture alone, however, should not be relied upon; it does not replace any of the other means of examination, but should be considered in conjunction with other methods of diagnosis.

The value of the diagnosis made from a roentgen picture depends of course, entirely upon correct interpretation and, therefore, on the experience and skill of the roentgenologist. It would seem advisable, on this account, for the general practitioner to refer his patient to the roentgen specialist, who would naturally have a much wider experience and a specialized training in this branch of dentistry. On the other hand the specialist cannot always have a full knowledge of the problem which is referred to him, and he cannot, therefore, always produce the picture best suited to the case in question. There is no doubt whatever that the patient, as a rule, will receive greater benefit if the dentist, for routine work, makes his own roentgen pictures, except in cases of an extensive nature and for unusual conditions requiring extraoral exposures. A roentgen machine large enough to take good dental films in from three to five seconds would therefore be sufficient for his needs and, being close at hand, would lead to more frequent use than if the patient had to be sent to someone else. The possibility of taking roentgenograms promptly when the need arises and of getting the result in a short time enables the dentist to use this method extensively for routine work.

ROENTGEN NOMENCLATURE.

There are a great many roentgen terms in use, and there has, so far, been no standardization in dental literature. In this book the

terms employed are those which have been adopted by the American Roentgen-ray Society, October 1, 1913, and accepted by the *Journal of the American Medical Association.* The Committee on Nomenclature of the American Institute of Dental Teachers also recommends their use:

Roentgen Ray.—A ray discovered and described by Wilhelm Conrad Roentgen.

Roentgenology.—The study and practice of the roentgen ray, as applied to medical science.

Roentgenologist.—One skilled in roentgenology.

Roentgenogram.—A shadow picture produced by the roentgen ray on a sensitive plate or film.

Roentgenograph (verb).—To make a roentgenogram.

Roentgenography.—The art of making roentgenograms.

Roentgen Diagnosis.—A diagnosis made by means of roentgenograms. In addition to these terms the following words have been made use of, the three latter having been supplied by Dr. Ottolengui to meet a long felt need adequately to express certain properties:

Radiability.—The property of an object to transmit the roentgen ray.

Radioparent (*Radioparency*).—Offering no barrier to the roentgen ray.

Radiolucent (*Radiolucency*).—Offering slight resistance to the roentgen ray.

Radiopaque (*Radiopacity*).—Impervious to the roentgen ray.

THE PRODUCTION OF ROENTGEN RAYS.

It needs but little practice to manipulate a roentgen machine, detailed instructions being always furnished by the manufacturers. The way to produce suitable roentgen rays for the best results is soon learned, once the principle is thoroughly understood. The first requirement is to produce the most suitable type of ray. The quality of the rays varies according to the vacuum in the gas tube and according to the temperature of the filament in a Coolidge tube. The more perfect the vacuum in a gas tube and the colder the filament in a Coolidge tube the greater the resistance offered to the current passing through them. A tube with high resistance emits "hard rays" while a tube with low resistance generally gives what is called "soft rays." The quality of the rays, therefore, can be altered at will by changing the resistance of the tube. In the gas tube (Fig. 530) this is accomplished by letting a very weak current pass through the regulating chambers. The heat generated produces gases from the chemicals

contained therein, which pass into the tube, lowering the vacuum and decreasing the resistance. When at rest the vacuum returns to its normal state. New tubes have recently been constructed which, together with other improvements, "come back" in a comparatively

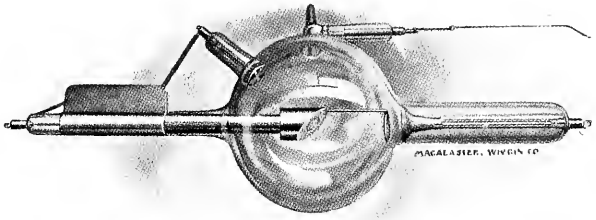

FIG. 530.—Gas tube.

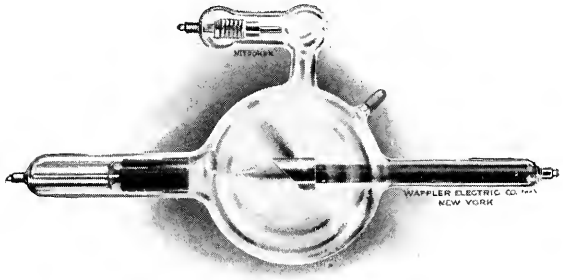

FIG. 531.—Nitroken tube.

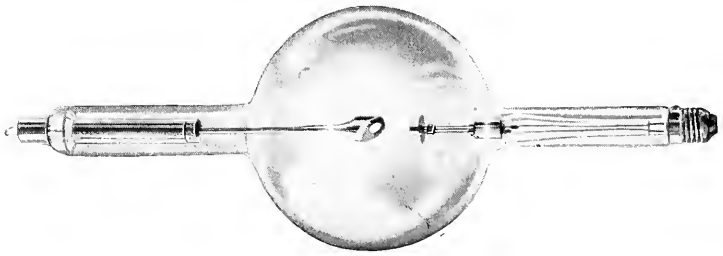

FIG. 532.—Coolidge tube.

short time to their original vacuum, which is very much higher than in the old-style gas tube. The advantage of this is that the same tube, by proper adjustment before each exposure, can be used for the production of either hard or soft rays. The regulator is said to be

designed so that overreduction is impossible. An example of this tube is the Nitroken tube shown in Fig. 531. In the Coolidge tube (Fig. 532) the resistance is changed by heating the filament in the cathode by means of a low-tension current. A rheostat is used to produce the change which affects the temperature. At a certain temperature of the filament not more than a certain number of milliampères can pass through the tube, regardless of how high the output of the machine. The penetration of the rays increases as the voltage is increased above that needed for the current value.

Soft rays are of a bluish-green color and have little penetrating quality. The hard rays, which have a much greater penetrating power, are suitable for bone and dental work. Too much penetration, however, gives a picture with very little contrast, a fault which renders it worthless for making a diagnosis of pathological conditions, which often cause only a slight difference in the radiability of the tissues.

METHOD OF TAKING ROENTGEN PICTURES OF THE TEETH.

Roentgenograms of the teeth may be taken by either the extra-oral or the intra-oral methods. The former is used in making a general survey, so as to get an idea of the relation of the neighboring structures to the teeth and pathological conditions which may affect them. Malposed teeth, extensive bone infection, cysts and fractures are not infrequently overlooked when only small dental films are used. The latter, however, show details of the teeth and alveolar structures with much greater accuracy for the simple reason that they can be placed closer to the tissue which is to be investigated and because there is less distortion and fewer superimposed shadows. The large size ($2\frac{1}{2}$ x 3″) intra-oral films are very useful for more extensive pictures of the tissues of the upper jaw, especially in the anterior region, which cannot be clearly reproduced in an extra-oral plate or film. The film is placed between the teeth, as far back as possible, with the sensitive side directed against the upper jaw. The same method is sometimes useful for the lower jaw, especially to locate calculi or foreign bodies in the floor of the mouth. For the latter the head-rest of the chair must be so adapted that the patient can tip the head way back, allowing sufficient space to get the right position of the tube in front of the patient. The sensitive side of the film is placed downward toward the part to be roentgenographed. The small dental films are most generally used in operative dentistry. A new dental film put on the market recently by the Buck X-Ograph Company, St. Louis, Missouri can be recommended very highly. It is far superior to

the original Eastman films on account of its improved method of packing. The rounded corners make it possible to get the film much closer to the tissue, and when once placed they are less liable to slip from their original position than the Eastman films.

For taking the roentgen picture the patient is seated in the chair. The position of the head makes no great difference, although it is advisable to have all patients in the same position, as this makes it possible to develop a routine and so get uniform results. The author always has the patient placed so that the lower border of the mandible lies in a horizontal plane.

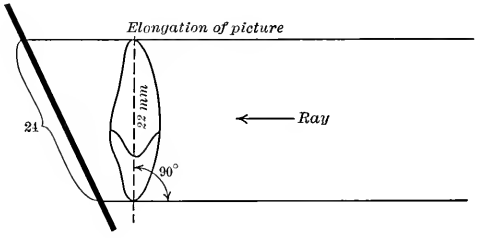

FIG. 533

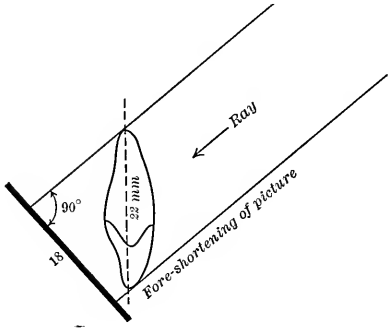

FIG. 534

Finding the Correct Angle.—The angle at which the rays are directed toward the object is of the greatest importance and varies considerably, not only for different teeth but for different patients. The anatomic make-up of the inside of the mouth shows many variations, which govern the placing of the film. If the patient has a high vault and a long alveolar process the film can be placed almost parallel with the teeth in the upper jaw, while in a mouth with a flat palate the film may be at a decided angle to the teeth. The question then arises whether the rays should be directed vertically to the teeth or to the film. Fig. 533 shows the result of directing the rays vertically to the

object (22 mm.), producing an elongation (24 mm.). Fig. 534 shows the rays directed vertically to the *film*, which foreshortens the picture (18 mm.). The rays should be directed vertically to an imaginary plane lying exactly half-way between the plane of the object and the plane of the film. This gives a picture of natural size (22 mm.) (Fig. 535).

This principle applies to all single-rooted teeth, both in the upper and lower jaws. Multi-rooted teeth present a more complex problem. If it is necessary to get a picture showing the exact condition and correct length of all the roots it is often necessary to take two or three pictures from different points of view. A picture is taken of each root, the angle being calculated as if a single rooted tooth were being roentgenographed. In addition one must choose a direction which prevents overlapping. The teeth which present the greatest diffi-

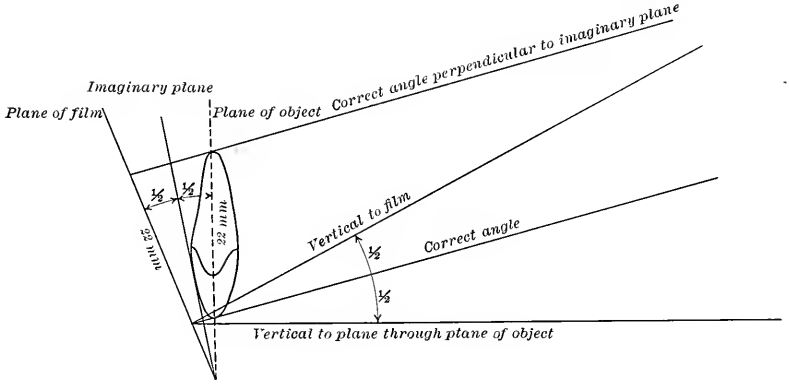

FIG. 535

culties are the upper molars, especially the first and second molars. An entirely different angle is necessary for the palatal root and the buccal roots. For the former the rays are directed from a high position of the tube, which gives a foreshortening of the buccal roots and a clear picture of almost the entire palatal roots (Figs. 536 and 537). The buccal roots are taken with a more horizontal direction of the rays, Figs. 538 and 539, and as there is nearly always superimposition of the palatal over one of the buccal roots, it is necessary to take one picture from a mesial aspect to isolate the disto-buccal root, and one from a distal point of view bringing out the mesio-buccal root, in case it is not fused to the palatal one (Figs. 540 and 541). This method also overcomes another anatomic difficulty, which often occurs. This is the zygomatic process, which may, at a certain angle, obscure the picture (Fig. 542).

The upper bicuspids frequently present special problems. If roentgenographed from a straight buccal aspect it frequently appears as if there were but one root canal and in first bicuspids only one root, even when there are two quite distinct and divergent ones. Generally it is only necessary to take one exposure of these teeth if a slightly mesial direction is chosen (Fig. 543). Should the tooth, however, be twisted so as to face buccally to a slight extent with its distal surface it will be found that a disto-buccal view gives a better picture.

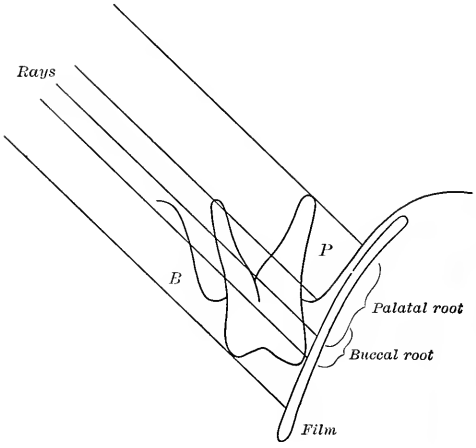

FIG. 536

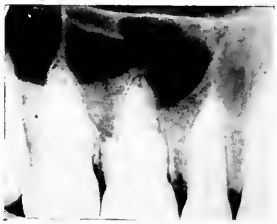

FIG. 537

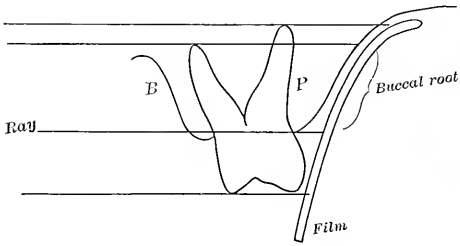

FIG. 538

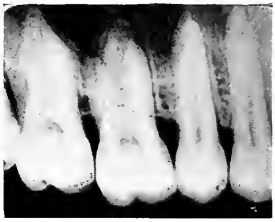

FIG. 539

In root-canal work the operator may want to know which is the buccal and which the lingual root. This can be easily determined. If the picture is taken from a mesial aspect the buccal root is projected distally, that is, nearer the second bicuspid, the lingual root mesially, or next to the cuspid. The same holds true for the root canals in both teeth (Fig. 544). In the lower jaw the technic is less complicated. If there be two canals in a molar root they can be identified by means of a slightly mesio-buccal or disto-buccal direction of the rays exactly as has been explained for the upper bicuspids.

FIG. 540

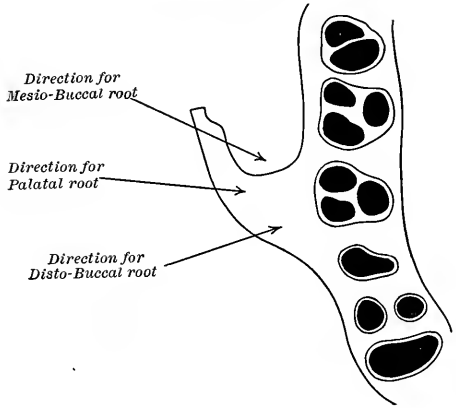

FIG. 541

FIG. 542

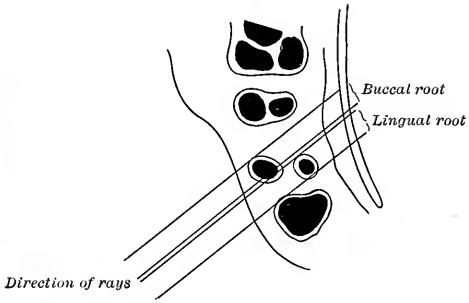

FIG. 543

FIG. 544

Length of Exposure.—Various factors govern the time of exposure. The greatest variations are due to the type and output of the machine and the make of tube. It is therefore a matter which will have to be ascertained in the individual case and may be determined after a little experimentation. It will be found, however, that after a while a slight increase in time is needed unless the output of the machine can be increased to overcome a decrease of the efficiency, which comes with the use of the induction coil and the aging of the tube.

The milliampèrage of the current passed into the tube is, perhaps, the most important factor. The time of exposure can be decreased in proportion to the increase of the milliampèrage. If the milliampèrage is doubled the time of exposure is cut down one-half.

A variation in the distance of the target from the plate also changes the length of the exposure, the change being in proportion to the square of the distance. If, for example, the target distance should be doubled it would be necessary to make the exposure four times as long. If with a known exposure time of T seconds and a target distance of Da inches a new target distance (Db) be chosen, the new exposure time (X) can be calculated by the following equation:

$$X = \frac{T}{\left(\frac{Da}{Db}\right)^2}.$$

Variations in the object to be roentgenographed have to be considered both in regard to changing the penetrating quality of the rays as well as the length of the exposure. Thick and dense bone needs greater penetration, a higher vacuum in the tube and a longer exposure. It should be remembered that bone varies not only in different parts of the jaws but also according to the build of the bony frame of the individual. In old people, again, we find a higher degree of calcification than in a child.

Further factors are the sensitiveness of the roentgen film or plate. The different makes vary and there are both fast and slow films on the market. The latter usually give better results because slight mistakes will not result in poor pictures. The fast films permit only slight variations. A slow film, if overexposed, can be saved in the developing process. The length of exposure can also be greatly decreased by the use of intensifying screens. These are most useful for extra-oral exposures, especially for sinus pictures. The new Eastman double-coated films, which are used for head work in the sizes 6 x 8 or 8 x 10 give splendid pictures when used with double screens in special screen holders or cassettes, the purpose of which is to bring the film into close contact with the screens. The action

of the intensifying screen depends upon a fluorescence, which is produced on the surface of the screen when the roentgen rays pass through. The actinic light, which the screens emit, will continue to act on the emulsion even after the exposure is completed. With double screens the length of exposure can be decreased to at least one-fourth of the normal time.

The effect of the developing must also be considered sometimes when viewing a thin picture. It may appear to have been underexposed when the real fault lay in the development. If the developer is too weak or too cold the picture will not be as good as could be expected.

TABLE GIVING TIME OF EXPOSURE.

Object.	Target distance in inches.	Resistance of tube back up in inches.	Milliampères.	Time of exposure.	Milliampères, seconds.	For change in target distance Db	Coolidge tubes figure milliampère seconds.
Letters used in equation . .	Da	V	A	T	A x T	$\frac{A \times T}{\left(\frac{Da}{Db}\right)^2}$	
Teeth intra-oral .	15	4	30	5	150	$\frac{150}{\left(\frac{15}{Db}\right)^2}$	$\frac{1}{5}$ A x T
Jaws intra-oral .	18	4	35	6	210	$\frac{210}{\left(\frac{18}{Db}\right)^2}$	$\frac{1}{5}$ A x T
Jaws extra-oral .	20	4	35	7	260	$\frac{260}{\left(\frac{20}{Db}\right)^2}$	$\frac{1}{5}$ A x T
Sinuses, anterior-posterior . .	22	4½	40	8	320	$\frac{320}{\left(\frac{22}{Db}\right)^2}$	$\frac{1}{5}$ A x T

Development of Roentgen Films.—The films are developed in a darkroom or developing cabinet. Three porcelain bowls, approximately five inches wide, are used to contain the developer, the fixing-bath and the rinsing water. Special clips (Fig. 545) are designed to use with such bowls. They facilitate the management of the films and make it possible to do the developing without immersing the fingers in staining chemicals. A clip is attached to each film, and care should be taken to wash the clips well after use. The developing fluid is best prepared from powders, which are manufactured by concerns like the Eastman Company. After using it should be poured back into a bottle or covered over to prevent free access of air which causes oxidation. It is a good plan to add a certain amount

of new developer when it is used again, as the chemicals become less active with age and use. The fixing fluid can be used for a considerable length of time and may safely be kept in an open bowl. The films must be well rinsed after they are taken from the developer before being transferred to the fixing-bath. The temperature of the developing fluid affects the picture considerably, and in winter it is often necessary to heat it slightly. The proper temperature is about 65° F. In hot weather the films are often spoiled because the emulsion becomes too warm and melts or causes blisters to appear on the surface of the film or frills on the margin. It is often advisable to use ice water for the washing and to cool the solution. The author prefers to add a teaspoonful of alum to the bowl of fixative, as well as into the washing water. The astringent action preserves the film.

FIG. 545

Roentgen films are developed in the same manner as photographic negatives, and one who has some experience in photography will be able to save a good many pictures which have not been quite properly exposed. The inexperienced operator will probably at first get most satisfactory results if he times the developing. With the Eastman developer for dental films the time is five minutes, after which the film is rinsed in clear water and placed in the fixing-bath until it is entirely transparent when held to the light. A film may be left in the fixing-bath any length of time without spoiling it. After being fixed the film should be washed in running water for about fifteen

minutes or in standing water for an hour, during which time the water should be changed several times. It should be finally hung up by the hook of the clip until dry, when it is finished. The drying process may be hastened by putting the film into alcohol for a few seconds after washing it.

There are various opinions as to the appearance of a perfect roentgen negative. Some roentgenologists like them very dark, so as to necessitate holding in front of a strong light, while others prefer light, but contrasting pictures, which may be examined in ordinary daylight, as, for example, in front of a window. The author prefers the latter type, which are made with a fairly high penetration, but backed up by enough milliampère seconds to give, if properly developed, an entirely black picture of the radioparent parts and a very translucent picture of the parts which are radiopaque.

Recognition of the Cause of Poor Results.—It is generally difficult for the student to determine the cause of a poor picture and to find the reason for his failure to get as good results as someone else. Quite frequently he blames the machine, when the fault is clearly a matter of technic. When trying to trace the cause of the failure it is best to think the matter over carefully and to consider first the roentgen machine. It can be easily and quickly tested by attaching it to a tube with a certain back-up and taking the reading of the milliampèremeter. If the reading is less than usual it is a sign that the output of the machine has been decreased. This may be due to a drop in the incoming street current or improper functioning of the interrupter or induction coil, of the transformer or commutator, or other parts, according to the type of machine.

The tube may not be working properly. Gas tubes often become freakish, flitter and become soft during the exposure. If the tube is too high the picture will not show enough contrast and will appear flat (Fig. 546). If the tube is too low in vacuum there is not enough penetration of the hard tissue and the resulting picture will be thin (Fig. 547). In Fig. 548 the patient moved and the picture therefore is not very clear.

The result of overexposing or underexposing can often be corrected by proper development. Such errors are due to exposing the film too long or for too short a time or to the use of too large or too small a milliampèrage. If too many milliampère seconds are employed and the picture is developed the normal length of time it becomes very black and may be so dense as to make it impossible to read it, even by a very strong artificial light (Fig. 549). An overexposed picture develops almost instantly and can only be saved by immediately diluting the developer and removing the film as soon as it is

FIG. 546

FIG. 547

FIG. 548

FIG. 549

FIG. 550

FIG. 551

FIG. 552

FIG. 553

FIG. 554



FIG. 555

FIG. 556

FIG. 557

finished. Overexposed pictures may also be improved by the use of a reducing fluid, such as can be bought from any photographic supply house. If too few milliampère seconds are used the picture develops very slowly, the radioparent parts fail to become black enough and if the development is forced, that is, if it is continued much longer than usual, the negative becomes fogged and, after being fixed, often has a yellowish color (Fig. 551). Fig. 550 shows a normal roentgenogram for comparison.

The effects of development have already been described. When the developer is too cold the result is a very thin picture, as shown in Fig. 552. A similar condition may be produced by a developer which is too old or by underdevelopment of the negative (Fig. 553). An overdeveloped picture looks about the same as an overexposed one (Fig. 554).

Other poor results may be produced by movement of the patient, vibrating of the tube or slipping of the film, which cause the picture to become indistinct, losing in sharpness. If the supply of films is not properly stored they may become fogged (Fig. 555). Films should be kept in a lead box so as to protect them from the rays when exposures are being made. Daylight will not affect them so long as the packing is intact, but if the packing becomes torn, or if light is allowed to strike the film through carelessness before or during the development the picture may be partly defective, fogged or entirely spoiled (Fig. 556). Hot weather often causes the emulsion on the film to melt as seen in Fig. 557.

INTERPRETING ROENTGEN PICTURES.

To interpret a roentgen picture correctly is the most important work of the roentgenologist. It is absolutely necessary that he should have careful training and special knowledge in the anatomy, histology and pathology of the parts he is to examine. If he is a dental roentgenologist he should also be familiar at least with the various dental procedures and problems of dentistry or he will not be able to coöperate with the general practitioner sufficiently to give him the greatest possible benefit from his services. The author cannot forego this opportunity to lament the fact that, on account of inefficient laws, roentgen laboratories have been established in most of the larger cities by laymen who not only make roentgen pictures but also supply most elaborate reports. Through advertising they attract patients and, worse still, otherwise reputable dentists who refer their own patients to them. Such practitioners lower the

standard of this important specialty and of the dental profession in general, to say nothing of exposing their patients to false advice, based upon the opinion of an ignorant person.

The value of roentgen diagnosis depends upon correct interpretation of the picture, and such interpretation can only be made from a good roentgenogram. When reading a picture, however, one should not forget the history of the case and the clinical findings. The roentgenogram does not picture disease. It only records changes in the radiability of the tissues, which have been brought about by pathologic processes as well as surgical and medicinal treatment. Such changes in the outlines, or radiability, are correct and accurate pictures of grosser structural abnormalities; finer pathologic conditions, such as those seen under microscope, cannot be recognized. A roentgen diagnosis is, therefore, made by drawing deductions from the records made by the roentgen examination and the roentgenologist must become proficient in associating roentgen signs with corresponding diseased conditions. In a roentgenogram of a tooth, for example, the picture of the pulp is the same, whether diseased or normal; but if a dark area, indicating decay, is shown in the crown of the tooth, and if this area comes close to the pulp, one may suspect pulp disease. If there be symptoms, or clinical evidence of pulp disease, the diagnosis is fairly certain. If, in addition to the above, the picture shows changes around the apex of the tooth which are associated with infection the roentgenologist can, from this evidence alone, without clinical indications, draw conclusions which lead to the diagnosis of pulp disease.

With advances in technic and improvement in the quality of the pictures it is possible to demonstrate finer changes, while experience, careful observation and systematic study of a large number of similar cases, as well as comparison of roentgen diagnosis with post-operative findings, or results of pathologic examinations, will make it possible to carry the roentgen diagnosis to a finer and finer point. As an example, take the differentiation between granulating ostitis and a radicular cyst. In both cases a large dark area may be shown in the film, due to the increased radiability of the area where loss of bone has occurred. Granulating ostitis is distinguished from the cyst by the appearance of the outline of the diseased part in the picture. An irregular margin and gradual change from the diseased to the healthy part indicates ostitis, while a clear demarcation of definite outline indicates that the bone itself has not become infected, but that pressure absorption has occurred, the bone cavity having been reinforced by a dense layer of normal cortical bone.

A roentgen picture is a record upon a photographic plate or film

of the radiability of tissues through which the rays are passed. Soft tissue is very radiolucent and, if not too thick, transmits the rays almost as well as air. Bone containing a large percentage of calcium salts is very much less radiolucent and enamel, containing almost no organic matter, is the most opaque tissue in the body. Gold, silver, lead and other metals are almost entirely radiopaque. Figs. 558, 559 and 560 illustrate changes in radiability. Fig. 558 shows the normal molars in the lower jaw. A cavity drilled into the buccal surface of the second molar increases the radiability and, since the obstruction to the passage of the rays is decreased, a dark shadow, corresponding to the size and outline of the hole, appears on the film (Fig. 559). Metal placed into this cavity renders the area impervious to the roentgen rays and a light area is shown in the picture (Fig. 560).

When examining a roentgenogram look first for any departure from the normal, such as irregularity in size or outline of the object or any change in its normal radiability. It is of great advantage to compare the part under observation with the corresponding part on the other side of the individual, especially when there is any doubt when the appearance of the condition in the picture is not pronounced and not readily recognizable. The age of the patient should also be considered. An unerupted tooth, for example, is a normal condition in a child, while in the adult it deserves serious consideration.

Misconceptions may arise from distortion of the angle at which the picture is taken, from faulty technic in the development, lack of sufficient knowledge to recognize pictures of anatomic structures, such as the mental foramen, the incisive foramen and the maxillary sinuses, or shadows of interposing parts, such as the coronoid process of the ramus in the upper third molar region or the nose and nostrils in front of the upper jaw. The picture of the mental foramen may be projected so that it comes exactly over the apex of a bicuspid root, appearing the same as would an apical abscess. The mandibular canal, however, may usually be traced to it, which helps in the identification. The incisive foramen will often give a picture superimposed over that of the apex of the central incisor, especially if the exposure is made from a slightly lateral angle. A new film, taken from a different viewpoint, will usually clear up all doubt. Beginners often mistake parts of the maxillary sinuses for extensive diseased conditions. Occasionally a case is referred to the author for extraction of an upper third molar tooth root, which is only the shadow of part of the ramus, taken from a fairly vertical direction and an extremely distal point of view.

FIG. 558

FIG. 559

FIG. 560

GENERAL ROENTGEN EXAMINATION OF THE TEETH.

The method of examination of the mouth, as practiced by the average dentist in the past, is thoroughly inadequate. As a rule, little care is taken to consider the mouth as a whole, and even in localized conditions there is a tendency to try various methods of treatment before ascertaining the cause and the exact nature of the trouble. In a general way we may say that we have two kinds of patients to examine, those who come with a definite complaint and those who want a general examination of the mouth. It is with the first class that most of our mistakes are made. Take, for instance the patient who wants to have one particular tooth extracted because he thinks it is the cause of some systemic disturbance; the folly of extracting this one tooth, even if it were an infectious focus, without thoroughly investigating the condition of the rest of the teeth is obvious. It is extremely unwise to jump at conclusions. The most proficient diagnosticians seldom depart from a systemic plan of examination, and it is always well to adopt a certain routine and follow it in every case.

It is advisable to inquire into the patient's general health, for it must be borne in mind that the teeth are not isolated organs but are in immediate relation to other important structures and closely associated with the rest of the body. The mouth may be the seat of secondary lesions of general diseases, such as the eruptive fevers, tuberculosis and syphilis, and, on the other hand, infectious lesions in the mouth may be the primary or contributory cause of somatic disturbances. If there be some special local condition of which the patient complains an exact history should be taken. The mouth should then be inspected, the condition of the teeth being noted first to see whether they are healthy or neglected or whether they show signs of dental work, either good or poor. The lips, cheeks, palate and gums should be examined next. Inflammatory changes, swellings and fistulæ are also noted.

Unless it is evident that the teeth are perfectly healthy, that there are no large fillings, crowns or bridges, a roentgen examination is indicated. A patient seen for the first time, or an old patient whose teeth have never been roentgenographed, should have a routine examination—that is, pictures of all the teeth (Figs. 561 to 577). If this is systematically carried out one will often be surprised to find definite diseased conditions on teeth which would have passed by in a superficial examination. Indications of decay under fillings or of cavities concealed under the gums are frequently discernible; unerupted teeth may be discovered and the conditions of root canal

FIG. 561

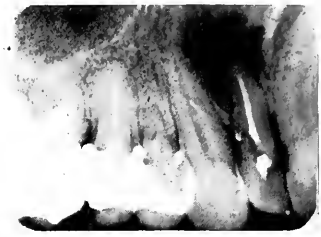

FIG. 562

FIG. 563

FIG. 564

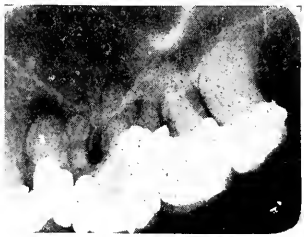

FIG. 565

FIG. 566

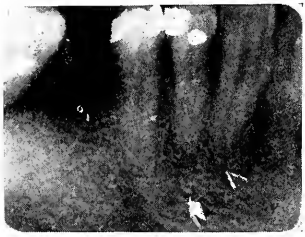

FIG. 567

FIG. 568

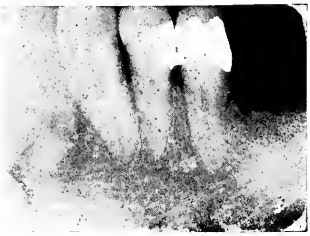

FIG. 569

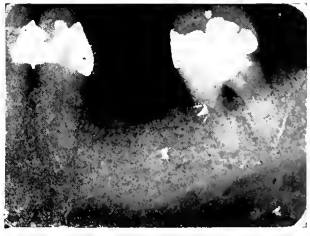

FIG. 570

fillings and status of devitalized teeth are disclosed. Pus pockets due to faulty contact points, overhanging fillings and other mechanical irritations become clearly visible, together with their cause, and in

FIG. 573

FIG. 572

FIG. 571

FIG. 577

FIG. 576

FIG. 575

FIG. 574

pyorrheal conditions, valuable information can be gathered as to the amount of bone destruction and deposit of serumal calculus in the pockets. The roentgen examination is of further value in leading to the discovery of other conditions which cannot be definitely demonstrated in the picture, but the appearance of which arouses suspicion and indicates the necessity of further clinical study.

The pictures, after completion, should be mounted on a film mount designed to hold the entire set, so that the views of the whole mouth can be seen at once and carefully studied before the patient comes

Original Copy } for the { Dentist / Physician / File

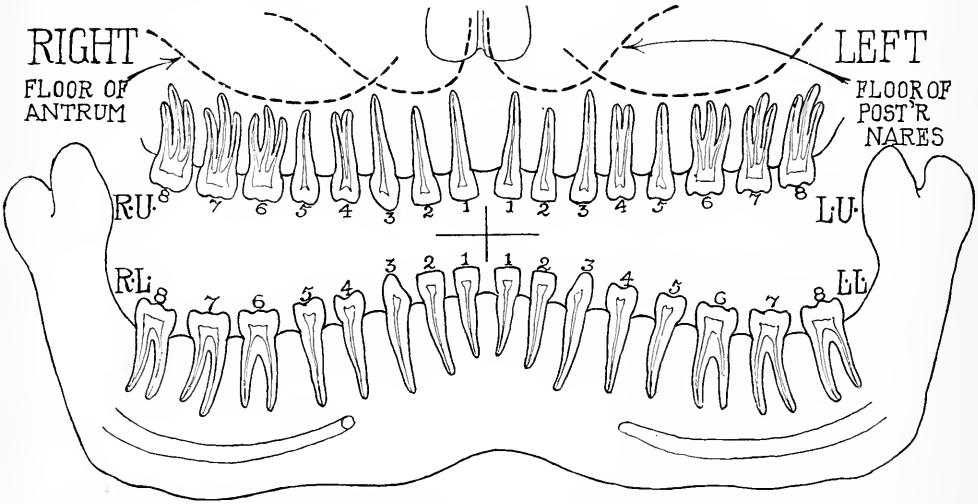

1. Periapical-Alveolar abscess
2. Canal not filled
3. Absorption of apex
4. Apex not filled
5. Apex filling projects
6. Wire-Broach in canal
7. Perforation of canal
8. Irritation, shell crown
9. Irritation, filling
10. Pericementitis (Lame tooth)
11. Alveolar Absorption—pyorrhea
12. Gingivitis
13. Cavity
14. Unextracted root
15. Fracture of root
16. Unerupted tooth
17. Supernumerary tooth
18. Impacted tooth
19. Fracture of jaw
20. Process fractured
21. Cementoma
22. Pulp stone
23. Bone "whorl"
24. Bone cyst
25. Bone tumor
26. Root in antrum
27. Antral empyema
28. Apex amputated
29. Test vitality
30. Amputate root
31. Extraction indicated
32. Contact point.

(Dr. Bryon C. Darling Dental Chart.) Copyrighted, 1918. The Peck Press, New York.

FIG. 578

in again. Records should then be made on an examination chart. The trouble with the majority of dental examination charts is that they are designed to indicate only the condition of the crowns of the teeth. Darling's dental chart, seen in Fig. 578, may be used by the roentgenologist. For the general practitioner of dentistry this chart does not give enough room for the recording of cavities and fillings in all the tooth surfaces. The Potter chart (Fig. 579), which is more elaborate, makes it possible to include a record of all dental conditions. This chart has been carefully worked out by Professor

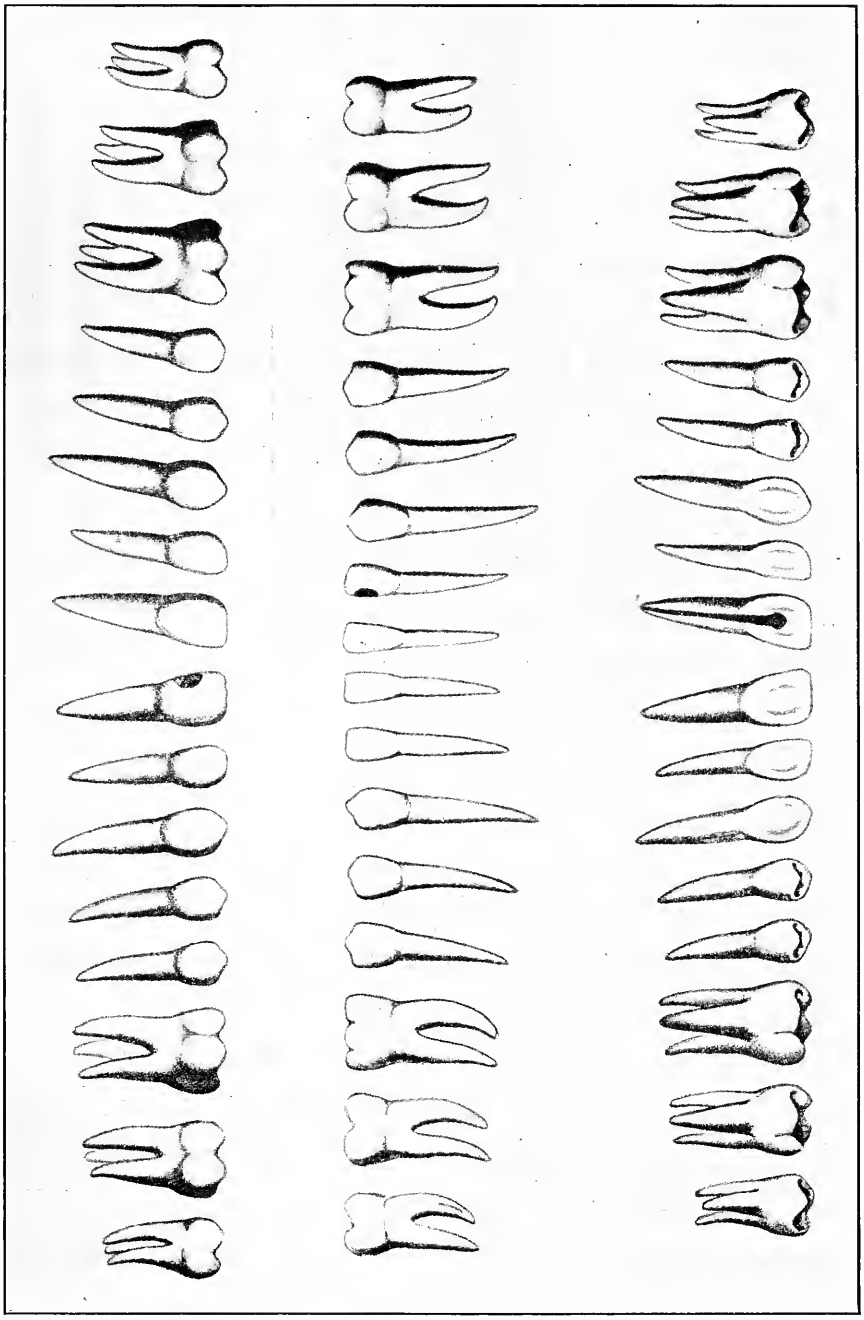

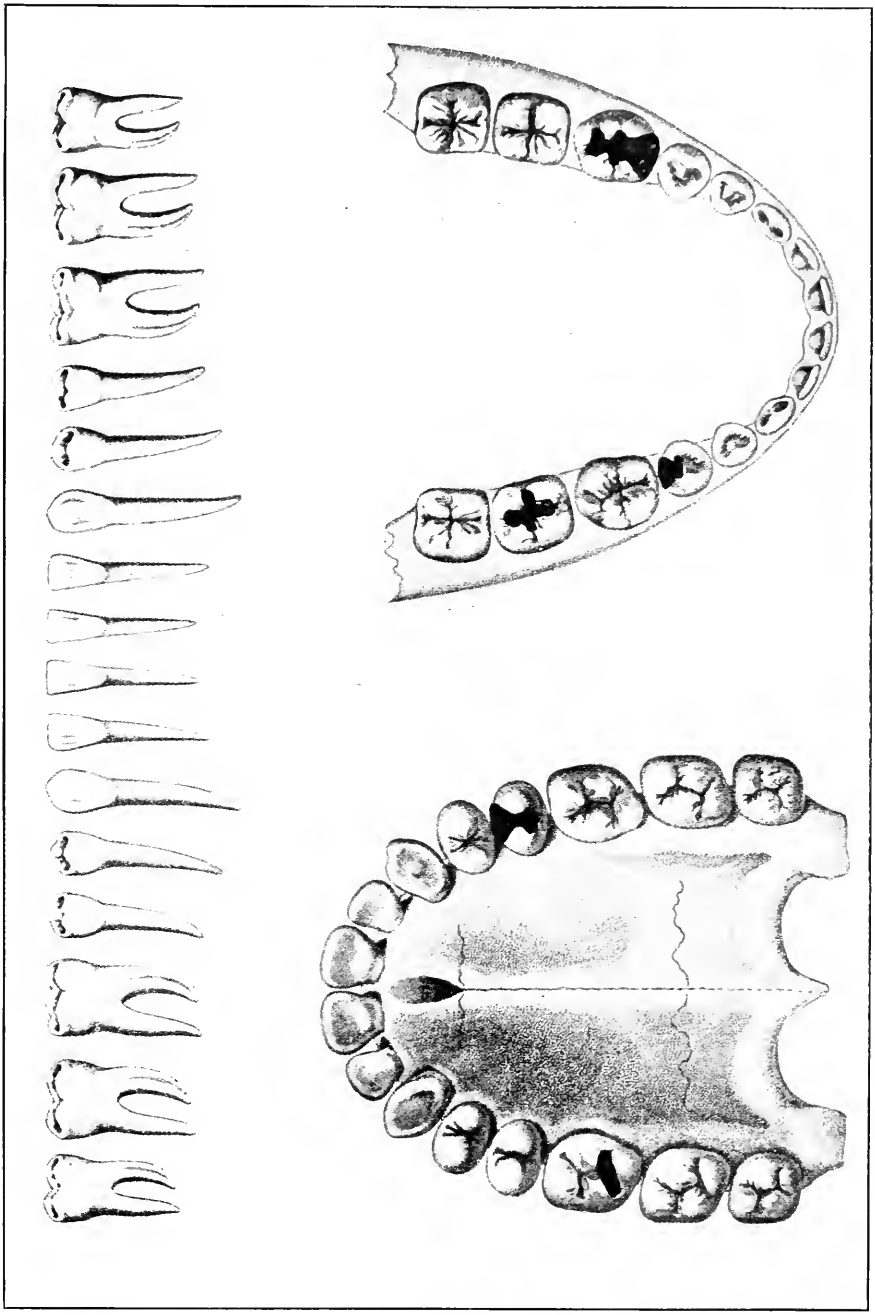

FIG. 579.—Arranged by Dr. William H. Potter from Carabelli.

William H. Potter from originals of historical interest by Carabelli. The back of the chart is arranged for bookkeeping. The films should be kept mounted on file until the patient is finally dismissed, and at each visit the pictures should be before the operator. After the work is completed the film may be dismounted and filed in envelopes with the patient's record.

ROENTGEN EXAMINATION OF THE JAWS IN SOMATIC DISEASE.

It is not within the scope of this contribution to discuss the relation of oral infections to somatic disease. There is no reason why dental diseases are not as likely to be the cause of focal infection as diseased tonsils, infected sinuses or gastro-intestinal disturbances. With the roentgen method it is possible to discover infections in the jaws which cause no symptoms and cannot be diagnosed by any other means, but whether such infectious lesions in the mouth are the original foci, or one of several from which bacteria have migrated to other organs; whether it is only absorption of toxins from these foci which cause the secondary disease, or whether the dental infections and the systemic conditions are simply coexistent and not directly related to each other, are questions which must be considered separately for every case. Also positive statements cannot be made with absolute certainty as to the probable benefit from removing the focus, since the secondary lesion or disease may be of such long standing that the removal of the original focus has but little effect, the secondary lesion not having received proper attention, or the tissue changes may be so extensive that restoration to the normal can no longer be expected. The best results are obtained in cases of short duration and especially in those in which the secondary disease is due to a toxemia rather than to bacterial migration. After finding oral lesions in a patient who complains of symptoms caused by diseases conceded to be due to focal infection the patient should first be carefully examined by an internist. It is for him to decide the nature of a given case and whether focal absorption of toxins or bacteria may be an etiological factor.

Another aspect of this problem is the question as to whether it is perfectly safe for an otherwise healthy patient to retain teeth which on account of their chronic character, give no local disturbance, but which show infectious processes at the ends of the roots when roentgenographed. While there is little doubt in most cases as to what should be done with badly infected teeth, there are, nevertheless, cases in which we should like to recommend and try more conservative methods if we could be sure that no absorption was taking place. In cases of

long standing, in which apical necrosis and absorption are discovered in the roentgen picture, indicating clearly that Nature wants to eliminate such an obnoxious foreign body, extraction is indicated from a purely dental point of view. No one who has studied the tooth and bone pathology of old pus-soaked teeth, or who has experienced the odor of one which has been removed, would ever hesitate to recommend extraction simply for the sake of cleanliness. But in cases of short standing, especially in younger patients, treatment and retention of the tooth would seem advisable if the roentgenographic indications are favorable to root-canal work. Two tests have recently been used by the author, with the kind coöperation of Dr. Cotton, of the New Jersey State Hospital, and Dr. Charles Lawrence, of Boston, to demonstrate whether or not products of bacterial activity have been absorbed. Dr. Cotton[1] recommends the complement-fixation test for streptococci for this purpose, with which he has made extensive experiments. The skin test, as used for proteid poisoning, is more readily available, and if it continues to prove reliable when verified by the complement-fixation test and bacteriological study of the tooth roots it will be of the greatest value.

The most common oral diseases from which absorption takes place are alveolar abscesses, pus pockets, pyorrheal infections, infections around impacted teeth, as well as more extensive bone infections in the jaws, such as ostitis, osteomyelitis and infected cysts. A systematic roentgen examination of the teeth and jaws is necessary in all these conditions, and with few exceptions a complete set of dental films should be taken.

The case of Mr. G. is a good illustration: he complained of pain in his back and shoulders, which incapacitated him for work, as he was a chauffeur. Roentgen examination of the shoulders and spine revealed no bony changes, which led to the conclusion that the disease was of recent standing. He had a careful physical examination and no cause was found to which his trouble might have been attributed. A complement-fixation test of the blood showed a 3+ reaction to hemolytic streptococci, 3+ to Streptococci viridantis and 3+ to the colon bacillus. The skin test reacted positively to hemolytic streptococci, Streptococci viridantis and pneumococci. No skin test was made for the colon bacillus. Roentgen pictures were taken of all the teeth, which showed many abscesses, as seen in Figs. 580 to 589. The left upper first and second molars, the left lower first and second molars, the right upper central and lateral incisors and the first molar and the right lower first and second molars were extracted. Pure cultures

[1] Cotton, Henry A.: The Relation of Oral Infection to Mental Diseases, The Journal of Dental Research, vol. i, No. 3, p. 269.

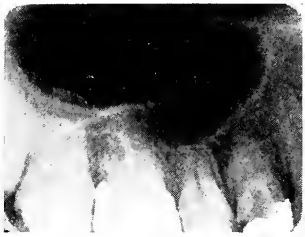

FIG. 580

FIG. 581

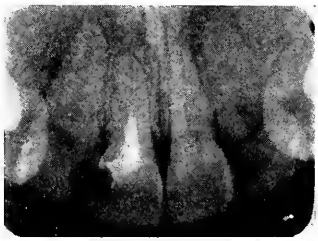

FIG. 582

FIG. 583

FIG. 584

FIG. 585

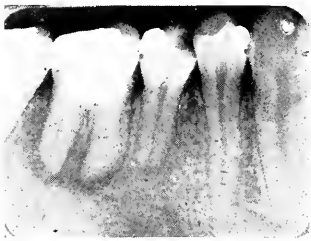

FIG. 586

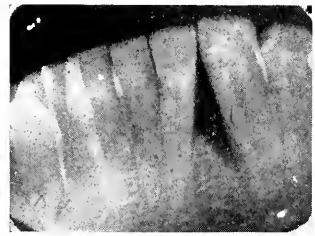

FIG. 587

FIG. 588

FIG. 589

of Streptococci viridantis and hemolytic streptococci were obtained. The patient improved very rapidly, so that he was able to go to work very soon, and is now driving a truck.

ROENTGEN EXAMINATION OF THE TEETH IN DISEASES OF THE MAXILLARY SINUSES.

Maxillary sinusitis in its various forms is, according to Brophy, in about 75 per cent. of the cases due to diseases of the teeth. Acute infections may be caused by careless instrumentation (Fig. 591),

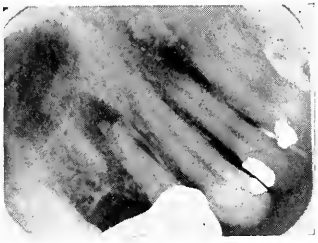

FIG. 590

FIG. 591

FIG. 592

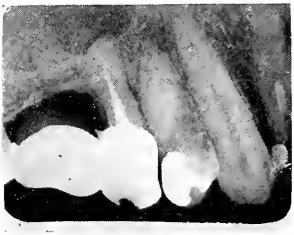

FIG. 593

or pushing of an infected root into the antrum. Chronic abscesses on the upper teeth very frequently cause chronic infection of the antra, with polypoid degeneration of the mucous membrane. This condition often develops without the patient's knowledge and is discovered only in routine examination. If large abscesses are seen in the roentgen pictures of the upper molars and bicuspids, as shown in Figs. 590 to 592, sinus disease should always be considered as a possibility. Roentgen pictures of the head should be taken for investigation of the sinuses (Figs. 594 and 595), and, on the other hand, in cases of sinus symptoms or sinus disease the teeth should not be neglected and their

condition must be investigated roentgenographically. Maxillary sinusitis caused by a tooth and cured by its extraction is illustrated in the following case: The tooth in question, a right upper bicuspid, had been devitalized for several years on account of an exposure made when preparing the tooth for a cohesive gold filling. About one year ago a roentgenogram was taken, which showed a very slight bone infection. The root canal was treated experimentally by various modern methods and then filled under strict asepsis. Later a bridge was attached to the

FIG. 594

tooth, which became slightly tender, and one morning three months later a fulness and throbbing sensation was felt in the region of the right maxillary sinus when stepping hard and a small amount of gelatinous substance was discharged through the right nostril. An anterior-posterior roentgen picture taken the same day (Fig. 594) showed the right sinus to be dense, and on transillumination it was entirely dark. The tooth shown in Fig. 593 was extracted at once and a probe passed into the alveolar socket, which showed, however, that

there was no opening through the floor of the antrum. No further treatment was resorted to; the symtoms disappeared and, after seven weeks, the sinus was clear on transillumination and in the roentgen picture (Fig. 595).

FIG. 595

ROENTGEN EXAMINATION OF THE TEETH IN TRIFACIAL NEURALGIA.

The extensive area of distribution of the trifacial nerve and its frequent communications with other cranial nerves and the sympathetic system explains the clinical manifestations that pain and irritation originating from some dental or oral cause may be referred to very distant parts of the face and head, including the ear (otalgia dentalis), the eye, the nose and accessory sinuses. Such pain may be continuous, intermittent or periodic; it may be intense, sharp, throbbing or dull, and it may be a sensation of obscure, indefinable pressure. It sometimes results in more serious nervous disorders, such as insomnia, melancholy and epilepsy.

The suffering that goes with these conditions is often intense, and if of sufficient duration wears the patient out. The cause may be difficult to ascertain and the condition calls for a careful study with temperature and electrical tests as well as painstaking roentgen examination both of the entire side of the affected jaws and the teeth. Frequent etiologic factors are impacted and unerupted teeth, obscure pericemental infections and affections of the dental pulp, such as irritation from improperly fitting bridges, poor fillings, pulp nodules (Fig. 596) and infection from decay starting either underneath the gum or continuing, on account of insufficient sterilization, after the tooth has been filled. An illustration is to be found in the follow-

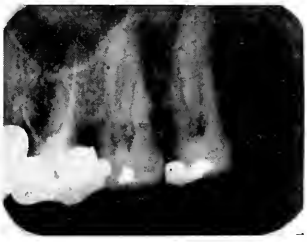

FIG. 596

FIG. 597

FIG. 598

ing case report. Mrs. V. G. L. had attacks of neuralgia on the left side of the face at intervals. For three days she had been in severe pain, which was especially located in the ear and zygomatic region. Roentgen examination (Fig. 597) showed a large radiolucent area also a radiolucent area indicating infection at the apex of the tooth. From these findings we conclude that the pulp is diseased. The operative findings revealed a pulp which was necrotic. In another case the cause was found in the upper jaw. Miss R. had had periodic headaches in the back of the head for several years. They were quite severe and always on the right side. Sometimes the whole half of the head would ache. Roentgen examination (Fig. 598) showed

infection of the right upper first and second molars, with formation of a small cyst, also an unerupted, impacted third molar. The pressure exerted by this tooth caused the well-illustrated tipping of the second molar. A frontal plate of the sinuses was negative. Extraction of the three molars was decided upon, and during the operation the antrum was opened and, after irrigation, closed with sutures. The treatment relieved the symptoms.

SPECIAL ROENTGEN STUDY OF DENTAL DISEASES.

It has already been stated that a roentgenogram is not a picture of disease but a record of the changes in the radiability of the tissues, brought about by pathologic processes or surgical interference. In interpreting a roentgen picture the history and clinical manifestations should also be considered, as they often will be of great help. One of the best means of learning to read roentgen pictures is by carefully studying typical illustrations in a text-book,[1] which are reproduced with the full history, symptoms and clinical signs, pathologic report and findings during and after the operation or treatment. The purpose of this chapter, therefore, is to show the reader such typical cases, giving, if possible, photographs of specimens of similar pathologic conditions to illustrate how the disease affects the tissue and its radiability.

Although this contribution is to be restricted to the roentgenology of conditions which concern operative dentistry the author intends to include such lesions and diseases as are closely associated with the teeth. The operator should be familiar with their pathology and diagnosis, so as to be able to differentiate them from simpler affections of the teeth, recognizing them early and advise the patient in time. For example, large cysts are frequently treated with root-canal medication and an extensive osteomyelitis, as pyorrhea.

Abnormal Dentition.

Irregular Eruption.—If temporary teeth decay early and become abscessed, or if they are retained too long, it is advisable to investigate the progress of development and the size of the permanent teeth by means of roentgen pictures. The permanent teeth may be prevented from erupting on account of impaction of the temporary teeth. In the case illustrated by Fig. 599, a child, aged twelve years, lacked the second bicuspid in the lower jaw. No temporary second molar could be seen, but part of the tooth was visible

[1] Thoma, K. H.: Oral Roentgenology, Boston, M. C. Cherry.

through a perforation in the gum, which had the appearance of showing a broken-down root. Roentgen examination showed the entire crown of the second temporary molar impacted between the first molar and the first bicuspid. Its roots had been absorbed, but its retention prevented normal eruption of the second bicuspid. A similar condition is shown in another case (Fig. 600). A girl, aged twelve years, had a temporary molar which was entirely under the

FIG. 599

FIG. 600

gum, impacted between the two permanent teeth. Its roots showed signs of resorption, but the second bicuspid was mal-shaped and showed only rudimentary development.

Misplacement of a tooth germ is frequently the cause of permanent teeth not erupting. In the case shown in Fig. 601 a space was held open for the permanent cuspid for a long time until a roentgenogram showed it to be entirely out of position.

FIG. 601

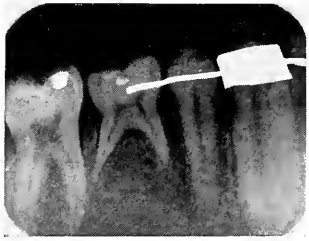

FIG. 602

Sometimes, however, the permanent teeth are entirely missing. A large roentgen picture should always be taken to make sure they have not migrated to a position outside the realm of the small dental film. In the case shown in Fig. 602, a child, aged fourteen years, the second temporary molar was retained, while all the other bicuspids had erupted. The roentgen picture showed slight resorption at the root apices and absence of the permanent tooth which should take its place.

In congenital absence of temporary teeth the permanent ones may be missing also. In the case of a boy, aged twelve years (Fig. 603), the temporary lateral incisor had never come through. By means of roentgen diagnosis it was found that not only the temporary but also the permanent lateral was entirely missing.

If the temporary tooth is present and is retained it is important to know whether its roots have become absorbed or whether they show a normal condition. The author has seen healthy temporary teeth with well-shaped roots and vital pulps in patients up to the age of forty.

FIG. 603

Artificial Eruption.—Many times, especially in younger people, unerupted teeth can, in favorable cases, be erupted artificially. After locating the exact position of an unerupted tooth by the roentgen methods the gum is incised and the bone overlying the tooth removed, so that part of the enamel is exposed. The tissue is then cauterized and packed with rubber tissue. After forty-eight hours the packing can be removed and, if proper care is taken, without causing any bleeding. A small loop of platinum wire is then cemented into a hole drilled into the tooth. To this may be attached an extension from the orthodontia arch wire, by means of which gradual force is applied until the tooth is moved to its normal position. To illustrate what may be done the following case of Dr. Alfred Rogers' serves as an illustration. Fig. 604 shows the condition two days after the author had operated on an unerupted cuspid, the appliances having just been attached. After nine months the tooth was almost in its

FIG. 604

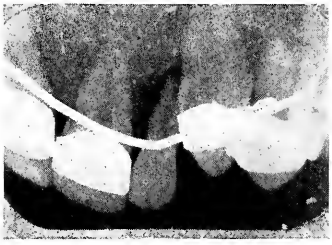

FIG. 605

FIG. 606

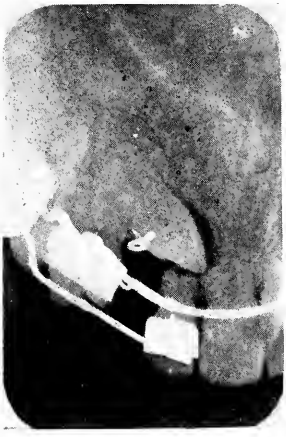

FIG. 607

FIG. 608

proper position, except that a certain amount of rotating was still necessary. The condition at this time is shown in Fig. 605. Not always, however, can such successful results be obtained. In the case illustrated by Fig. 606, which shows the condition before treatment and Fig. 607, which shows the tooth after attachment of the appliances, constant force was applied for ten months with apparently no result whatever, as seen in Fig. 608. The cuspid is still in its old position, probably firmly impacted over the resorbed surface of the lateral. Examine also the apices of the roots of the other incisors. They are all vital, the condition of the roots being due to incomplete formation.

FIG. 609

FIG. 610

Replacement by Bridge-work.—If bridge-work is contemplated to replace a missing tooth, the history of which is not entirely known, it is better to ascertain by means of a roentgen picture whether it is embedded in the jaw. This precaution may save the patient considerable trouble. In the case of an adult patient a bridge was constructed by her dentist to replace a cuspid which was missing. Sometime later the lateral incisor began to get very sore, with a feeling of pressure in the anterior part of the jaw on that side. The dentist advised removing the pulp in the lateral, or removal of the bridge, without further investigating the real cause of her condition. The trouble is clearly shown in Fig. 609 to be due to an unerupted cuspid. The effort of the cuspid to erupt resulted in pressure on the root of the lateral incisor. Another case is shown in Fig. 610. The patient said that the central incisor felt sore from time to time. Roentgen examination showed an unerupted cuspid pressing against the root of the central in its effort to grow out of the jaw.

Unerupted and Impacted Molars.—The third molars being the last teeth to take their position in the dental arch are most frequently found to be unerupted and impacted. This is principally due to underdevelopment of the jaws, which fail to grow large enough to accommodate all the teeth. Their position in the jaw varies greatly. They may be partly erupted but prevented from entire eruption by a bulging distal surface of the second molar or the ascending ramus. At other times they may be entirely unerupted. Unerupted teeth are either in upright position, mesially or distally inclined, but are sometimes at a great distance from their proper places. They may be found in any part of the ramus or maxillary bone, as illustrated in two cases in the author's text-book on *Oral Roentgenology*,[1] first edition, Figs. 33 and 189.

Unerupted molars are frequently the cause of obscure feelings of pressure and neuralgic symptoms, which may be continuous, intermittent or periodic. The pain may be intense, sharp, throbbing or dull, and may be referred to distant parts of the face and head. Local conditions, especially infection, are often associated with partly erupted teeth. After the gum has been pierced by the cusps of the tooth, an orifice is made which allows food and bacteria to enter between the enamel of the tooth and its overlying soft tissue. The condition frequently is aggravated by biting on the inflamed tissue during mastication. The inflammation then spreads to the neighboring tissue, causing a trismus of the muscles of mastication, so that the mouth can be opened but very little. The submaxillary lymph glands become enlarged and tender, with marked swelling on the side of the face and neck. One sequel may be pharyngitis, sometimes even leading to the formation of a pharyngeal abscess, simulating a peritonsilar abscess. In the case of Mr. R. B. T. such a condition is exemplified. He presented a history of repeated trouble with the left lower third molar. The last attack was the worst, being accompanied by large swelling, difficulty in swallowing, trismus of the muscles of the jaws and pus discharge around the tooth. He consulted a laryngologist, as he thought the primary trouble was in the throat. Roentgen examination (Fig. 611), however, disclosed an impacted lower third molar with a large cavity in the crown, apparently involving the pulp and causing an extensive infection of the surrounding parts.

Another complication occurs if pressure exerted by the impacted tooth causes absorption of part of the second molar. A good example is shown in Fig. 612. The patient had suffered neuralgic pains for

[1] Thoma, K. H.: Oral Roentgenology, Boston, M. C. Cherry.

several weeks. The roentgen picture revealed a partly erupted upper third molar, which caused pressure absorption on the distal surface

FIG. 611

FIG. 612

of the second molar to such an extent that the pulp barely escaped involvement.

Roentgen examination is the most valuable means, and sometimes the only one, by which unerupted teeth can be discovered. The size of the picture should be such as to include the entire tooth and

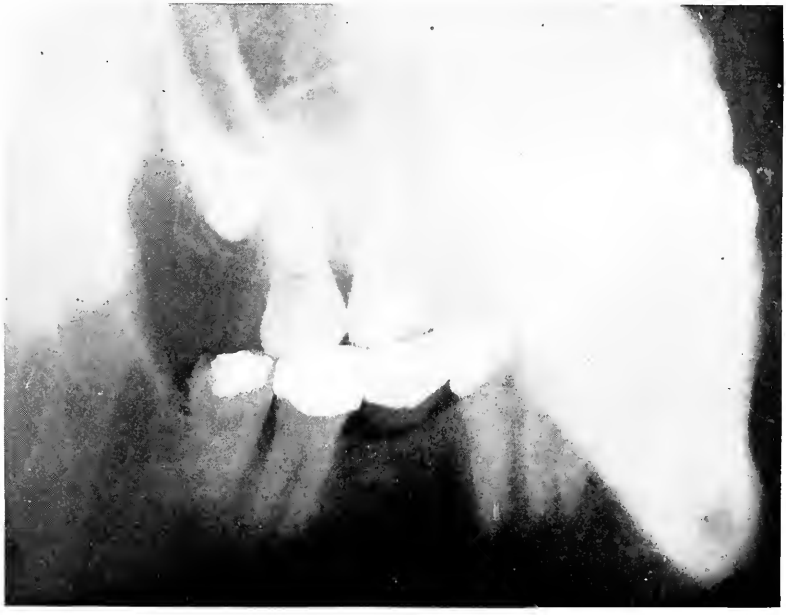

FIG. 613

a considerable portion of the surrounding structures. A roentgenogram which shows only part of the tooth is, of course, sufficient to

reveal its presence. To the surgeon who must remove it, however, such a film is useless, for he needs exact information as to the number, size and shape of the roots and the position of the tooth and its relation to the bone of the ramus. Fig. 613 shows an extra-oral picture of an unerupted upper third molar impacted under the distal surface of the tooth in front. Note also the root formation of the third molar in the lower jaw. Another case is illustrated in Figs. 614 and 615. The patient, aged nineteen years, suffered for several years with periodic headaches, especially on the right side in the region of the frontal sinuses, with indefinite subjective symptoms of pressure in the back of the head. At times the pain disappeared entirely and then a period of suffering followed. Roentgen pictures, showing unerupted third molar teeth, had been taken two years before the patient presented for examination. These teeth, however, apparently did not exert pressure against those in front (Fig. 614), and were, for this reason, considered innocent. Roentgen examination two years

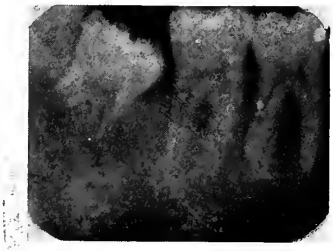

FIG. 614

FIG. 615

after the first plates had been taken (Fig. 615) showed that the lower molar had grown into a position which one would not have expected from the position shown in the first plate (Fig. 614). It was decided to remove all four third molar teeth, which resulted in complete relief from all the symptoms. This case demonstrates the fact that pain is often caused by the development of the roots of the teeth against the inferior alveolar nerve.

Supernumerary Teeth.—These may be well-formed teeth or in rudimentary peg-shaped form. They may be erupted in natural position or outside the dental arch. Fig. 616 shows a roentgen picture of the jaw of a girl, aged seventeen years. The orthodontist has kept open a space for the cuspid which was slow in erupting. A picture was taken to find out what its position was. The roentgen finding, however, showed that the tooth about to erupt was a supernumerary bicuspid, the cuspid being unerupted and quite a distance from its normal place. In another case a small rudimentary molar was seen

behind the second molar. The roentgen picture revealed a fourth unerupted molar of normal size (Fig. 617).

FIG. 616

FIG. 617

Follicular and Dentigerous Cysts.—Other disturbances of normal dentition of a more serious character are caused by abnormal development of a tooth follicle during the developmental stage of a tooth. Instead of a tooth a cyst may be formed, in which case it is called a follicular cyst. Such cysts may be formed from the enamel organ without the development of a tooth. In other cases, however, one or more teeth may be found in the cyst, when it is called dentigerous. Sometimes only masses of calcified tooth particles are produced, and these may be composed of enamel, dentin, cement and dental pulp. Occasionally they also contain bone. Such a lesion is spoken of as a cystic odontoma. Calcified tissue, however, is not always formed, and microscopic examination may show a mass of enamel organs with cylindrical epithelial cells. Typical ameloblasts are sometimes developed, and these may be found laying down enamel. This is called a cystic adamantonoma.

The cyst sac is usually composed of a fibrous membrane lined by epithelium, which may be in a single layer, stratified or epidermoid in character. The liquid contained in the sac is clear and straw-colored, originating principally from a secretion by the epithelial cells. Cholesterin crystals are usually present, and if infection has taken place it is contaminated by pus.

Roentgen diagnosis is of greatest help, as there is often little clinical indication, and the symptoms may be very misleading. The roentgen picture also gives valuable information as to the cause, extent and type of cyst and helps in determining the mode of operation. Teeth in dentigerous cysts can be located fairly accurately, which facilitates

their removal. Extra-oral exposures or large intra-oral films should be taken, as small ones seldom cover more than a part of the lesion. The dark area representing radiolucency, due to absorption of bone, is defined by a light line, the cortical layer of bone which forms the wall of the bone cavity.

In the case of Si. (Fig. 618), a man, about sixty-five years old, the patient complained of a bad-smelling fluid escaping from a sinus in the third molar region. The second and third molars were missing. The second molar had been extracted a short time before, but this

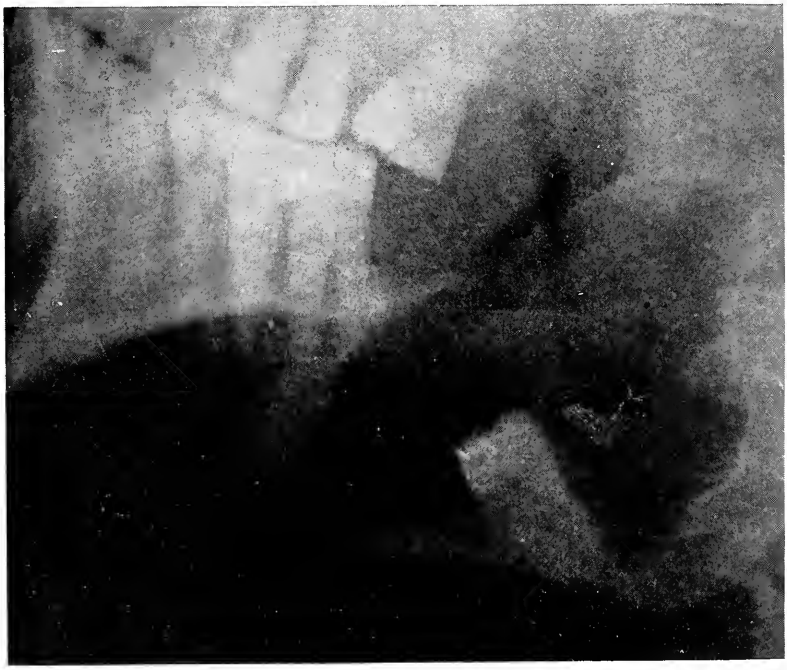

FIG. 618

did not improve the complaint. Roentgen examination by means of a small dental film showed a dark area at the root of the first molar, but no impacted tooth. A large plate was then taken (Fig. 618). This shows a large dark area extending to the lower border of the mandible and almost to the angle of the ramus. The area is surrounded by a distinct light line, the typical picture of a cyst. The third molar is found near the angle of the jaw. A diagnosis was made of dentigerous cyst, infected from the mouth. In the case of W. W. (Fig. 619), that of a boy, aged nine years, the following history

was given: his mother first noticed a swelling in the left upper side of the jaw in the cuspid region about one year previous to the consultation. She thought it was the cuspid about to erupt. There

FIG. 619

FIG. 620

FIG. 621

was no pain or soreness. A little later the left upper first temporary molar started to feel tender. It was filled, treated and refilled by a dentist, and finally fell out. Nearly a year later a slight swelling on

the left side of the face and side of the nose was noticed by his physician, who referred him back to the dentist, from whom he was sent to the author. Physical examination revealed little besides the swelling on the face. The alveolar process showed no signs of a cyst. Roentgen pictures, however, showed a large dentigerous cyst containing an unerupted cuspid, apparently encroaching somewhat on the maxillary sinus, and being located between the alveolar process, the nasal cavity and the palatal process. In another case, that of a boy, aged sixteen years, the patient noticed a swelling under his upper lip for several months, the left upper central and lateral incisors being somewhat tender to the touch. His dentist opened the left upper lateral incisor, removed the pulp and treated the root canal. Whenever the root-canal dressing was changed a yellowish fluid escaped through the tooth. The treatments failed to help the condition and the gum was lanced several times without result. The patient was sent in for consultation on November 8, 1918, at which time a roentgen picture (Fig. 620) was taken and from this and the clinical evidence a diagnosis of cystic odontoma was made. Fig. 621 shows a microscopic picture of the cyst with its contents.

Traumatic Injuries of Teeth.

Injuries, especially of the front teeth, are a frequent occurrence in children and occasionally in adults with accidental injuries. The teeth may become dislodged and sometimes are forced deep into the tissues. A case of the latter type is exemplified in the following patient: a young girl, as a result of falling down stairs, had a badly cut lip and tongue. No teeth could be seen in the anterior part of the upper jaw. The roentgenogram (Fig. 622) shows that the temporary incisors were driven into the jaw, the permanent teeth escaping injury.

Teeth which are loosened by an accident may be fractured or only broken out of the process. A roentgen picture will help to determine the condition. If no fracture has occurred and the tooth is retained it should be examined from time to time to find out whether the pulp remains normal. Fractures of teeth sometimes show plainly when roentgenographed, especially when the fracture occurs in a transverse direction or in a plane vertical to the film. If the plane of fracture is parallel to the film there may be some difficulty in making a correct diagnosis. The patient whose roentgen film is shown in Fig. 623 was in a motor cycle accident. The upper front teeth were slightly broken at the edges. The left upper incisor was very tender and there was a slight swelling over the gum. The roentgen examination shows

fracture of the root. The small radiolucent area at the apex indicates the beginning of an apical abscess.

Another case is shown in Fig. 624. From an accident the bicuspid had been fractured in a horizontal plane, as can be seen in the illustration, with a dark area indicating bone infection surrounding the site of the fracture.

FIG. 622

FIG. 623

FIG. 624

FIG. 625

Posts of crowns and bridge abutments are sometimes the cause of a fractured root, as illustrated by the following case: the patient whose roentgen ray is shown in Fig. 625 had a Richmond crown on a second bicuspid. The gum was inflamed and the tooth sensitive. Roentgen examination showed that the post had caused a vertical fracture of the roots.

Dental Caries.

Cavities in the incisors and occlusal surfaces of the posterior teeth are easily recognized. Proximate cavities in molars and bicuspids, however, are frequently overlooked and decay under a filling often cannot be recognized before considerable harm has resulted. The roentgen method has not yet come into general use to

find obscure cavities in routine examination, but judging from incidental findings in systematic search for infectious lesions it might be well worth while to use the roentgen ray for this purpose. Decay

FIG. 626

FIG. 627

under fillings and crowns of various types may escape notice in the most careful instrumental examination. Its timely recognition is, of course, of greatest value not only in cases in which there is obscure

FIG. 628



FIG. 629

pain, but particularly to prevent the infection of dental pulps. Caries is recognized in a roentgenogram as a dark area, due to increased radiability, which is due partly to decalcification of the dentin by

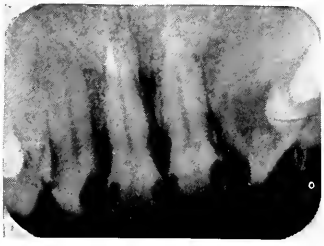

FIG. 630

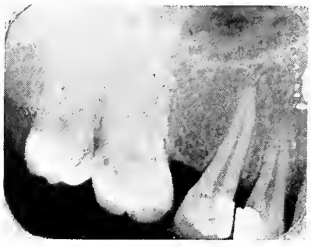

FIG. 631

bacterial ferments and partly to actual loss of tooth substance. Fig. 626 shows a roentgenogram of a molar tooth with a large cavity at the distal surface. Figs. 627 and 628 show obscure cavities under

fillings. In the first there was slight pain from hot and cold food; in the two latter a neuralgic pain of the jaw, caused by the cavity at the distal side under the cervical part of a filling. Fig. 629 shows a crowned first molar with decay at the cervical margin on the distal side.

When caries extends deep into the tooth substance it produces a protective reaction, which very probably is also called into activity if large fillings are inserted without an insulating layer of cement. The irritating action of the infection, as well as chemical and thermal influences, stimulate deposit of secondary dentin, which, of course, decreases the size of the pulp chamber. This can be easily recognized in any roentgen picture of the teeth. Fig. 630 shows upper incisors with large cavities at both sides. The pulps have receded, due to deposits of secondary dentin, filling the pulp canal in the crown entirely. Fig. 631 shows recession of the pulp in an upper first bicuspid, due to a large disto-occlusal filling.

FIG. 632

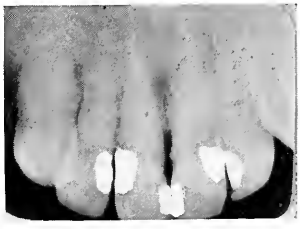

FIG. 633

Cavity Fillings.

Different filling materials have a different degree of radiability. Porcelain cement fillings often appear the same in a picture as a cavity, on account of their radiolucency. Oxyphosphate cements also are more radiolucent than the substance of a tooth, and, therefore, give a similar picture. Metal fillings, of course, are completely radiopaque and gutta-percha offers a similar barrier to the rays. Fig. 632 shows an upper central incisor with a gutta-percha root canal filling. On its distal side a porcelain cement filling has been inserted. Compare the radiability of the tooth with the porcelain filling and the gutta-percha. Fig. 633 shows upper incisors with two gold fillings in each central and another gold filling in the mesial surface of the right lateral incisors.

Every dental roentgenologist could produce a large number of films showing poor gold, amalgam, cement and gutta-percha fillings and gold inlays. Large overhangs injuring the peridental membrane and

alveolar bone, as well as lack of contact points giving occasion for the formation of so-called food-pockets, are the most frequently observed evils. A collection of such cases is shown in Figs. 634 to 639.

FIG. 634

FIG. 635

The first film (Fig. 634) shows amalgam fillings with rough overhangs extending down between the teeth, causing periodontal inflammation and pockets. Fig. 635 shows lack of contact points between

FIG. 636

FIG. 637

the two molars and roughness of the filling in the second molar at the cervical margin. Fig. 636 shows an extensive overhang at the mesial side of a lower second molar, which was the cause of an inflam-

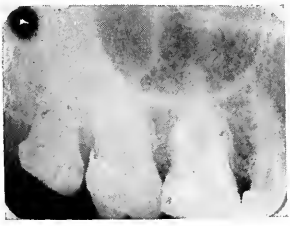

FIG. 638

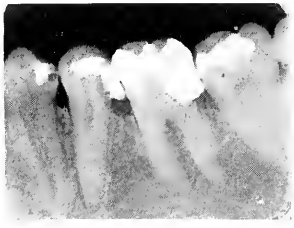

FIG. 639

matory reaction of the investing tissues. In Fig. 637 amalgam fillings of ragged outline are shown, with decay under the mesial portion of the fillings, both in the first and second molar, as well as lack of proper contact points. A gold inlay is shown in Fig. 638 in an upper second

molar. There is lack of contact with the third molar tooth. Note the feather edge at the cervical margin, distal side. Roentgen film (Fig. 639) shows a disto-occlusal gold inlay in the lower first molar, fitting poorly at the cervical margin. Note also the poor filling at the distal side of the second bicuspid, with decay underneath.

Restoration by Crown and Bridge-work.

A careful, systematic study of crown and bridge-work gives evidence of the fact that very little attention is paid to the condition of the teeth or roots, which are used as abutments. The problem is, by many, regarded as a purely mechanical one, simply to restore the masticating efficiency and the appearance, and any tooth which is useful as a mechanical support is retained without investigation of its condition. This short-sightedness often makes it necessary to destroy bridges of very recent construction in order to remove an abutment which is causing extensive periapical infection or to treat the root canal of a tooth in which the pulp has become infected.

Roentgen Diagnosis before Planning Crown and Bridge-work.—Before undertaking any restoration the teeth which are to be used as abutments should be carefully roentgenographed. It is necessary to determine whether a tooth is vital or whether its pulp is infected. If it is devitalized the quality of its root-canal filling should be investigated and possible bone infection around the apex of the tooth should be discovered. If there be a chronic alveolar abscess present the outline of the root may be found to be either normal or pathologically changed. In the latter case there may be absorption or hypercementosis of the apex. Sometimes unerupted teeth are discovered and quite frequently there are broken-off roots, over which the gum may have completely healed, in the alveolar process which is to be covered by a bridge. Fig. 640 shows the case of a young man who had three porcelain crowns on upper incisors. These crowns were of very good appearance, but after a short time, when his general health became poor, an acute process set in, causing acute suppurating ostitis of the jaw. A roentgen picture, taken at this time, showed bone infection around the roots, and the apical part of the pulp canals was entirely unfilled. It also revealed partial root-canal filling in a bicuspid, to which was attached a gold crown and dummy. This tooth also shows slight infection around the apex of the root. Fig. 641 shows a case in which a large fixed bridge had been constructed to replace several missing teeth. Sometime after the bridge had been cemented into place the central incisor began to get sore. A roentgen picture revealed an unerupted cuspid pressing against the root of the incisor.

Fig. 642 shows a small bridge attached to a vital bicuspid. When the patient was seen she complained of soreness in the gum, and, without

FIG. 640

FIG. 641

a roentgen picture, one might have been led to believe that the pulp in the bicuspid had become infected. The picture, however, showed

FIG. 642

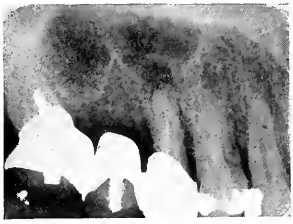

FIG. 643

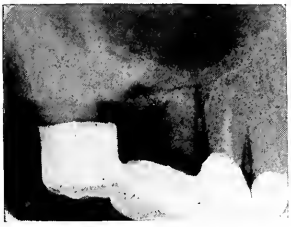

FIG. 644

FIG. 645

that one of the apices of the first bicuspid had been left in the jaw and the dark area around it showed there was a good-sized abscess

connected with this root. Fig. 643 is a picture of a bridge made seven years ago. The patient had no symptoms. Only the anterior abutment is shown in this picture. There is a partial root-canal filling and a large area around the apex, indicating bone involvement. The floor of the antrum is clearly outlined. Examination of the antrum revealed abnormal condition. There are also pockets at each side of the tooth. Fig. 644 shows a bridge in the mouth of a patient who had been suffering from arthritis for about a year. He had several abscesses on other teeth. The illustrated bridge is attached to a bicuspid with corkscrew root-canal filling and a molar, which shows decay at the mesial side under the crown. A root has been left under the bridge and the patient complained of soreness of the gum. Clinical examination showed an inflammatory condition, due to lack of hygiene and probably also infection from the root. Fig. 645 shows a roentgenogram of a patient who complained of slight pain on the right side of the face and discharge from the nose. A roentgen picture of the maxillary sinuses verified the clinical findings of a diseased antrum. Besides an infected pulp in the right upper first molar, due to decay, there is a second bicuspid holding a small bridge. The pulp in the bicuspid must have become infected, as evidenced by the changes around its apex, which indicate the pathologic condition of the bone. In addition there is an infected root underneath the dummy.

The Pulp of the Bridge Abutment.—Since our better knowledge of the pathologic conditions, both local and systemic, so frequently caused by devitalized teeth, we have been impressed with the seriousness of pulp extirpation. Whenever possible restoration should be made without sacrifice of the pulps in normal teeth. If, however, the pulp has become involved from decay, or if there is danger that pathologic processes may start after the bridge is made, it is, of course, better to consider its removal under favorable conditions. A careful roentgen study should be made to determine whether root treatment is advisable. The various steps in the root-canal treatment should be checked up by means of other pictures, as described later. It is a mistake to believe that a tooth must be devitalized for the attachment of a gold or porcelain jacket crown. The author has seen many roentgenograms of teeth which were perfectly normal after carrying crowns for a long time. Fig. 646 shows an upper bicuspid with a gold crown which has been on the tooth more than ten years without causing any pathologic condition. Fig. 647 shows two jacket crowns on a cuspid and bicuspid with normal pulps.

If pulp disease is found it may have started when the tooth was prepared or chronic infection of the pulp and periapical tissues may have existed before the crown was made. Again, the pulp disease

may have been caused by decay starting under poorly fitting crowns and unclean bridges or from improper root-canal work. Fig. 648 shows a jacket crown on a tooth with signs of periapical infection, due to

FIG. 646

FIG. 647

chronic pulpitis. Fig. 649 reveals extensive chronic bone infection around the root of a lateral incisor to which a porcelain crown had recently been attached. The apical part of the canal is not filled,

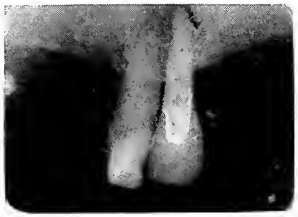

FIG. 648

FIG. 649

the infection probably having existed before treatment was undertaken by the dentist. Fig. 650 shows a first molar with a gold crown. At its mesial side a cavity had formed, which almost separated the

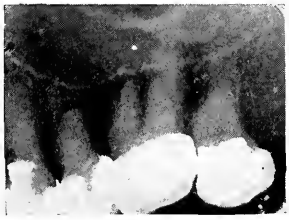

FIG. 650

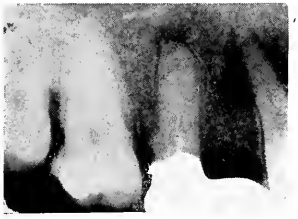

FIG. 651

mesio-buccal root. Fig. 651 is a roentgenogram of a patient who had a slight infection at the apex of a bicuspid, the root canal of which had not been properly treated before the bridge was attached. Note also the large area around the cuspid.

Technical Construction.—Perfect mechanical results are quite as important as proper diagnosis. Fixed bridges are, of course, contra-indicated in patients who will not take proper care of their teeth

FIG. 652

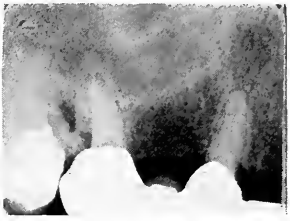

FIG. 653

and mouth, and unless they are willing to have regular prophylactic treatments and to do their part at home, removable bridge-work only should be considered. Fig. 652 shows a bridge which caused infection

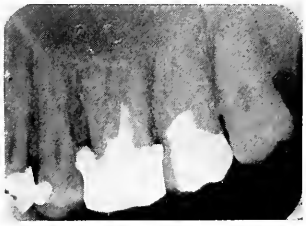

FIG. 654



FIG. 655

of the abutments and loss of almost all the alveolar structure on account of septic conditions. In the bridge shown in Fig. 653 decay had progressed underneath a crown to such an extent as to separate



FIG. 656

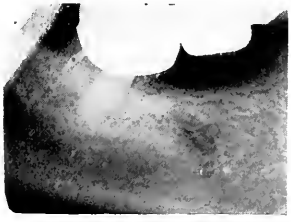

FIG. 657

almost entirely the roots from the crown. The fit, or misfit, at the cervical margin can be shown up very nicely in roentgen pictures, as seen in Fig. 654, which shows that a large surplus of cement has been

left at the mesial side in the interproximate space. Fig. 655 shows a crown with a large overhang at the mesial side. Fig. 656 shows the very poor fit of a gold crown at the cervix, and in Fig. 657 an extreme overhang at the margin of the mesial side is shown.

FIG. 658

FIG. 659

Good work can also be proved by means of roentgen pictures. Figs. 658 and 659 show two cases in point. The first (Fig. 658) shows a bridge with inlay attachments in the lower jaw. The other picture, Fig. 659, illustrates another case. Both of these show beautiful fits.

Pulp Disease and Treatment of Root Canals.

The greatest benefit the dentist has derived from the roentgen ray is, without doubt, its use in diagnosing conditions of pulps and root canals and to check up the progress of root-canal cleaning and filling. This work has heretofore been very unsatisfactory, not only on account of obscure conditions which could not be properly diagnosed, but, for the same reason, because of the small percentage of perfect results obtained. The following general conclusions of the result of root-canal operation, performed without the aid of the roentgen method may be drawn from examining many thousands of roentgenograms.

1. A very small percentage of devitalized teeth show perfect root canal fillings. Of these some show entirely normal conditions of the periapical tissue, as far as one is able to judge from a perfect roentgen picture, while others reveal decided periapical changes notwithstanding the fact that the whole canal, as far as the apex, may have been filled. Whether such conditions are due to periapical infection having occurred before the root canal operation was performed, and having persisted, or whether they represent an infection which took place during or after the filling of the canal, cannot be ascertained. Fig. 660 is a roentgen picture of a tooth with a perfect root-canal filling, done twenty-one years ago. The periapical tissue appears normal. Fig. 661 shows a tooth with a perfect root-canal filling and periapical infection.

2. A certain number of roentgen pictures show up accidents which happened during the root-canal operation. The most frequent ones are caused by motor-driven root-canal instruments. They are also due to miscalculation of the direction of the canal or to crooked roots. Fig. 662 illustrates a case in which a perforation is seen in the lateral incisor. The channel, which is very large, extends to the distal side and must have been made by a burr or engine reamer. Fig. 663 shows another case. A first bicuspid, with a porcelain crown attached by means of a post, revealed no visible root-canal filling, and the post is seen to extend just through the distal surface of the root. There is a radiolucent area both at the apex of the tooth and on the side, indicating that infection has occurred in both places.

3. Poor root-canal fillings, on account of anatomic conditions or calcifications obstructing the canal, are not so frequently found as

those due to faulty technic, which will be considered later. Fig. 664 shows an anatomic vagary which made a perfect root-canal

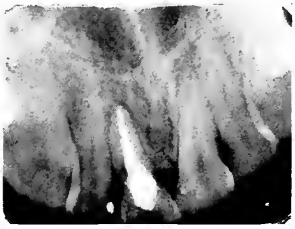

Fig. 660

Fig. 661

filling impossible. The root of the second bicuspid is very crooked, but it must be admitted that even in this case a better result might

Fig. 662



Fig. 663

have been expected. In Fig. 665 the canal in the lateral is obstructed by calcareous deposits and makes root-canal treatment impossible.

Fig. 664

Fig. 665

4. By far the largest percentage of poor root-canal fillings are caused by improper and careless technic, and because before the use of the roentgen ray there was no means of telling whether the operation was successful or not. No doubt in most cases the work was done

as well as possible under the circumstances, but today there is no excuse for working in the dark. A small percentage of partly filled root canals show no periapical infection. Whether this is due to

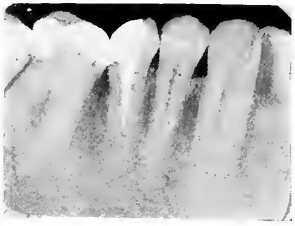

FIG. 666

FIG. 667

perfect sterilization and aseptic methods or to antiseptic preparations used in connection with the filling it is difficult to determine. Fig. 666 shows a lower bicuspid with the root only half-filled. Although

FIG. 668

FIG. 669

the tooth had been in this condition for many years the peridental membrane and the bone around the apex show no changes whatever. However, the majority of teeth with poor and incomplete root-canal

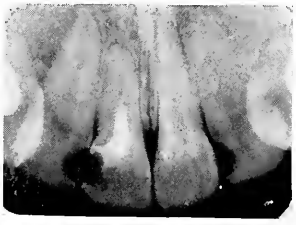

FIG. 670

FIG. 671

fillings show involvement of the periapical tissue, affecting not only the peridental membrane but also the tooth tissue and the bone. Teeth bearing porcelain crowns attached by means of posts invariably

have poor root-canal fillings. This may be because crown and bridge-workers do not pay enough attention to the proper treatment and filling of root canals or because frequently the root filling is torn out of the canal when using reamers to fit the post. Fig. 667 illustrates such a case. Pictures of teeth showing partial filling, a broken instrument in the canal, cork-screw filling and poorly condensed fillings are presented in Figs. 668, 669, 670 and 671.

Fig. 672

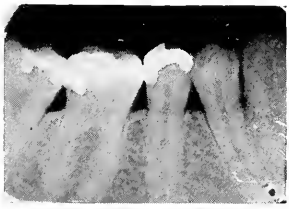

Fig. 673

Roentgen Diagnosis of Pathologic Changes of the Pulp.—Secondary Dentin, Pulp Nodules and Calcifications.—These are the only changes of the pulp which can actually be demonstrated in a roentgenogram. In the case of secondary dentin the outline of the root canal is changed, while pulp nodules and calcifications cause a direct change in the radiability of the pulp. The nodules may be round or oblong and calcifications may close up and obstruct the entire lumen of the root canal. Fig. 672 is a picture of the left lower

Fig. 674

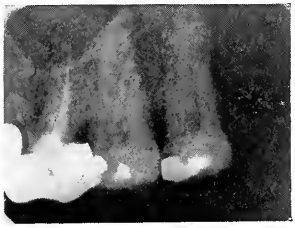

Fig. 675

molars of a patient who had worn down the occlusal surfaces of his teeth. Secondary dentin had formed, decreasing the size of the pulp chamber. Compare the size of the pulp chambers in the first and second molars. Fig. 673 shows large calcareous deposits in the pulp chamber of the first molar. Fig. 674 shows formation of calculi in the canals of both central incisors. Note also the accessory foramen in the left central incisor. Fig. 675 reveals a round pulp nodule in the

pulps of two upper molars. The patient had attacks of neuralgia at intervals on this side of the face, which had become more severe, including also the ear, three days before he was examined. Removal of the pulps in both the second and third molars permanently relieved all symptoms. In Figs. 676 and 677 calcareous deposits in the pulp canals of teeth are shown.

FIG. 676

FIG. 677

Pulp Infection and Necrosis.—Inflammatory and infectious changes cannot be directly demonstrated by means of the roentgen ray, but by comparing clinical symptoms and roentgen findings it is sometimes possible to make important discoveries. Fig. 678 is a roentgenogram of the anterior teeth in the lower jaw. The patient had been suffering a great deal of pain for two nights. A cavity is seen in the lateral incisor near the cervical margin, extending close to the pulp. The pain, therefore, is due to a pulpitis in this tooth and was caused by

FIG. 678

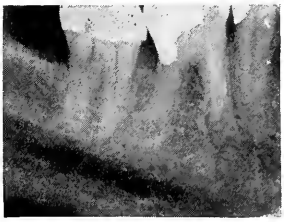

FIG. 679

infection from the decay. Another patient had been suffering from neuralgic pain on the right side. Clinical examination revealed nothing important, but there was a history of the pulp in the first molar having been capped. Fig. 679 shows that the filling extends close to the pulp. Slight changes are noticeable around the apices of both roots, but these have not the appearance of typical periapical infection. From these findings a diagnosis of necrosis of the pulp in the first molar may be made. The operative findings confirmed the diagnosis.

Frequently it is possible to draw the necessary deductions from the roentgenogram alone in order to make a diagnosis of pulp disease. This is especially important in all cases of chronic pulpitis without history or symptoms. As soon as the infection spreads from the pulp through the apical foramen, changes can be demonstrated in the periapical tissue. If these findings are seen connected with a tooth in which the root canal has never been treated, and if, in addi-

FIG. 680

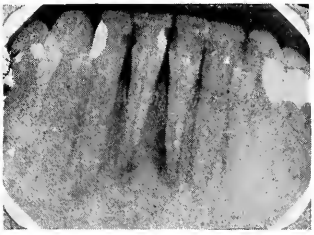

FIG. 681

tion, we can demonstrate some causative factor, the diagnosis of pulp disease may be made with certainty. Fig. 680 shows periapical changes around the roots of the upper first molar. There is also decay at the cervical margin under the filling. The diagnosis, therefore, is chronic pulpitis and periapical infection. Fig. 681 is an interesting study. Periapical infection, apparently caused by pulp disease, is revealed on all four lower incisors. Many porcelain cement fillings and two gold fillings appear in the crowns. Whether the infection

FIG. 682

FIG. 683

originated because the patient neglected to have the cavities excavated and filled when they were small or whether it was due to some action of the porcelain cement is not so easily determined. Attention has already been drawn to pulp disease caused by crowns and bridges. This is usually due to an infection having occurred before the crown is cemented on the tooth (Fig. 682), or to decay which starts under the gum or under a poorly fitting crown after the cement has washed out.

Fig. 683 shows such a condition in which pulp infection has been caused by decay at the distal side under the crown of the first bicuspid; there is also decay under the inlay in the second bicuspid.

In the cases mentioned so far the infection of the pulp started from the crown of the tooth and extended through the canal into the periapical tissues. In some cases the infection travels along the peridental membrane, forming a pus pocket at the side of a tooth. On reaching the apex pulp infection occurs as illustrated in Fig. 684.

Fig. 684



Fig. 685

The patient had some pain in the left side of the lower jaw, and after a roentgenogram was taken the left lower first molar was extracted. The symptoms continued off and on and did not entirely disappear. A few days before the author saw the patient the pain had grown worse and the second molar had become loose and sore. A roentgen picture taken at this time is shown in Fig. 684. Apparently the pocket had existed between the first and second molar and is still visible in

Fig. 686

Fig. 687

the negative. The infection had spread from this pocket to the apex of the second molar, causing infection of the pulp.

Another possibility of pulp infection is presented by the case shown in Fig. 685. It discloses periapical infection on the lateral incisor which had been treated. The tooth next to it, although perfectly sound, with no cavity or filling, had an infected pulp, which reacted to the heat test. It had become infected from the periapical infection, which had spread from the neighboring tooth.

Prognostic Roentgen Examination before Treating Pulps or Root Canals.—Before undertaking any pulp canal operation, no matter whether the pulp be normal or diseased, it is absolutely necessary to

FIG. 688

FIG. 689

make a careful diagnosis of the condition of the root and root canal by means of the roentgen ray. The root may show abnormal devel-

FIG. 690

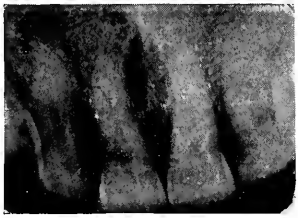

FIG. 691

opment or deviations in the number, size and location of the root canals. Fig. 686 shows two bent bicuspid roots and Fig. 687 a very

FIG. 692

FIG. 693

badly curved root of an upper first bicuspid. Root-canal treatment would be contra-indicated in a case like this.

The apical part of the tooth presents many variations besides decided curves at the very end. We frequently find one or more accessory foramina, and the number of root canals is not as staple as one might be led to believe from the older text-books on dental anatomy. Two canals are frequently found in the lower bicuspids; even three occasionally, while the mandibular cuspids and incisors quite often have bifurcated canals leading to a common foramen. The lower molars sometimes present in each root two canals and the third molars are, of course, always uncertain. In young teeth the apical foramen is very large and funnel shaped (Fig. 688), while we sometimes find lack of proper development in vital teeth, as seen in Fig. 689. The patient, who had had orthodontic treatment, had a roentgen picture taken to locate the permanent cuspid, which was missing. The roentgenogram showed also a very peculiar condition at the apices of all four incisors, from which one might be led to believe that absorption had taken place. Fig. 690 shows a bifurcated root canal in a lower first bicuspid and in Fig. 691 an accessory canal is shown in an upper central incisor. Two canals are seen in both lower bicuspids in Fig. 692 and Fig. 693.

Pathologic changes outside the tooth, but closely connected with the root canal, should also be properly diagnosed before deciding on the method of treatment. The author has seen cases in which root canals have been treated for months without ever getting a sterile condition. Roentgenograms of these cases revealed conditions which never could have been affected by root-canal medication nor by thermal or electrolytic treatment. Necrosis of the cementum at the apical part of the root and extensive bone infection, as well as enormous cysts, are often revealed by roentgen examination. Such cases are cited under the headings in which their pathology and diagnosis are discussed.

The Roentgen Ray as an Aid in Root Canal Cleaning.—The importance of the removal of every particle of pulp tissue, whether normal or diseased, from the canal or canals of a tooth has only recently been fully realized. It is also important to properly and completely ream the root canal and to enlarge it slightly either by mechanical or chemical means, so as to facilitate the filling of the canal. The only safe and sure way to determine whether the canal is properly prepared for successful filling is by taking roentgenograms. If the operator has a roentgen machine by his chair he can insert broaches and take pictures with the rubber dam on, developing the films at once and so losing no time. When taking pictures the rubber dam clamp should be removed and replaced with heavy ligatures, to avoid confusion in the picture. If the film is to be taken at some future time, or if the patient is to be referred to a roentgenologist,

fine wires with looped ends can be inserted into the canals, together with a root-canal dressing, after which the cavity is sealed as usual. The process should be repeated until a picture shows the wire inserted to the very end of the root.

FIG. 694

FIG. 695

The Roentgen Ray as an Aid in Root Canal Filling.—The filling of root canals should also be checked up by means of roentgen pictures. Gutta-percha or chloropercha, or the solution

FIG. 696

which forms when the root-canal point dissolves in the chloroform and rosin when Callahan's method is used, are of radiopaque nature

FIG. 697

FIG. 698

and show clearly in the roentgenogram. This investigation should be made immediately after the filling is placed in the canal, because at that time it is easy to condense it further, press it deeper into the

canal or remove it, so that it can be replaced by a more perfect one. Figs. 694 to 698 show pictures taken for the cleaning and filling of the canals of a lower molar. In Fig. 699 a root-canal filling with a so-called "capping" at the apex is shown. The canal in Fig. 700 is filled just to the apex, and in Fig. 701 the canal filling of a central incisor is shown to include both the main and accessory foramina.

FIG. 699

FIG. 700

FIG. 701

Checking up Devitalized Teeth by the Roentgen Method.— It is highly commendable to take roentgenograms of devitalized teeth at certain intervals to find out whether they remain normal or become absorbed and cause bone infection. If a slight periapical infection existed when the root canal was treated the tooth should again be examined after six months, and after one year to ascertain whether the bone changes have been repaired. If this is found to be the case it indicates that the tooth is sterile and is being tolerated by the system.

Periapical Infection.

Before discussing the roentgen method of diagnosing periapical infection it is first necessary to review briefly the pathology of such conditions. The infection caused by pulp disease starts, as a rule, at a natural opening of the root canal, the apical foramen. We, however, occasionally find infection at the side of a root, generally on account of accidental perforation of the root by an engine reamer or other root-canal instruments. If such injury is followed by infection an abscess may form at this point, and we speak of it as a lateral abscess. Fig. 702 shows such a root with a lateral abscess. If a perforation is made between the roots of a multi-rooted tooth and infection occurs it is spoken of as an inter-radicular abscess. Such a case is shown in Fig. 703 in which the floor of the pulp chamber has been perforated.

Periapical infection originating from a diseased dental pulp may follow either of two chains of pathologic changes. The first is of a destructive nature and begins with a reaction causing all the symptoms of acute inflammation, while the other, from the beginning, is characterized by a mild and chronic reaction, which starts and continues without giving any local symptoms.

FIG. 702

FIG. 703

Acute Periapical Infection.—This condition starts as acute periodontitis and involves a violent inflammatory reaction of the tissue. Serum and polymorphonuclear leukocytes infiltrate the tissue, causing an increase in volume of the peridental membrane, which results in the well-known symptom which gives the impression that the tooth has become elongated. Purulent exudations soon accumulate, the cells of the periodontal membrane and the surrounding bone being destroyed, and the condition is then called an acute alveolar abscess. This may spread and cause suppurating ostitis of greater extent or else the pus may soon find an outlet to the surface *via* the Haversian canals, which penetrate the outer cortical layer of the bone. When the pus collects under the periosteum a reaction sets in at once, causing a widespread serous infiltration of the soft parts, cheek or neck. Finally the pus burrows a channel through the soft tissue, forming a fistula into the mouth, nose, maxillary sinus or outside of the face. After this process of destruction has reached its climax nature makes an attempt at repair and the acute symptoms disappear; but unless the cause (a diseased pulp or necrosed root apex) is removed the condition becomes chronic. In this stage it may last for an indefinite period, with the fistula discharging pus if the destructive process becomes more active, or closing up for a time if the defensive system predominates, only to reopen with more or less marked subacute symptoms when suppuration again becomes more active.

The roentgen picture shows at first an increased space between the

alveolar socket and the apex of the tooth. This is a sign of periodontitis. Pus, which accumulates in the cancellous part of the bone, may cause a tremendous reaction in the tissues before enough bone destruction has taken place to become visible in the roentgen picture. At other times, especially if the apex of the tooth is near the surface, the pus may gather under the soft tissues without affecting the bone to any great extent, and so give no roentgenographic record. A case which exemplifies this is that of a patient who had suffered from a swelling under the lip for several days. Clinical examination showed a protruding upper lip and large swelling on the gum. The anterior teeth in the upper jaw had large fillings, gold in the lateral and porcelain in the central incisor. Both were loose and tender to the touch. Fig. 704 shows no radiolucent area, as might perhaps be expected with such large abscess formation. The lateral incisor was opened and the pulp found to be very putrescent. An incision on the labial part of the gum released about an ounce of pus.

FIG. 704

FIG. 705

FIG. 706

Sometimes, however, the bone becomes extensively involved before an outlet is made. In such cases a large radiolucent area is usually found around the apex of the tooth. A case of acute alveolar abscess of this nature is seen in Fig. 705. The central incisor had recently been filled on the labial side. The tooth then started to ache and the condition became worse. When examined the left central incisor was very loose and tender and the two neighboring teeth were also slightly affected. The gum was swollen and the lip protruded. Roentgen examination showed a large radiolucent area, apparently starting from the left central incisor. The infection must have spread from the pulp to the bone, causing extensive suppurative ostitis.

When the acute stage is over the bone destruction, of course, is still recognizable in the roentgen picture, although the outer swelling

may have disappeared entirely. Slight pus formation continues in the chronic stage, the exudation either being absorbed or discharged through a fistula when there is sufficient accumulation. Fig. 706 shows a case of chronic alveolar abscess which had become more active. The pulp was infected, and when the roentgenogram was taken the patient was having a subacute attack. The amount of bone dissolved is clearly indicated by the radiolucent area.

Blind Abscess or Dental Granuloma.—The difference between an acute alveolar abscess and a blind abscess, or dental granuloma should be clearly understood. The former is a suppurative inflammation and involves a process of destruction of the peridental tissues, dissolving them into pus. The latter is a reaction to a mild injurious agent, stimulating inflammatory new growth as we see in specific infections, as the tuberculous granuloma (tubercle) and the syphilitic granuloma (gumma, syphiloma). Active suppuration does

Fig. 707

not occur at first, but an exacerbation may change the pathologic picture so as to simulate a typical acute alveolar abscess. The blind abscess, or granuloma, begins and continues to grow without giving any symptoms. The defensive system of the body takes care of the slight amount of pus formed, which is absorbed through the lymphatics or blood channels. When speaking of a blind abscess, therefore, we must think of a focal accumulation of leukocytes and lymphocytes in the newly formed granulation tissue rather than of a cavity filled with pus. Sometimes a dental granuloma is described as being a tumor, but this is not correct, as it is distinctly of infectious origin and histologically presents a picture of chronic inflammation.

The disease, of course, spreads at the expense of the bone. After the stratum durum of the alveolar socket has disappeared the infection spreads into the medullary spaces, destroying the trabeculæ of the cancellous part of the bone. The process, however, is not

always restricted to the inner part of the bone. When the tooth apex is near the surface, or if the lesion is extensive, the outer cortical layer frequently becomes involved. The Haversian canals are next

FIG. 708

FIG. 709

implicated and enlarged, a condition which is easily recognizable in a skull, by the many small holes on the surface of the bone (osteoporosis) (Fig. 707). The outer plate may be attacked so extensively

FIG. 710

FIG. 711

that a part of it disappears entirely, as seen in Fig. 708. It is evident that if a hole has formed in the outer wall of the bone the picture of the abscess cavity will be much more intense (Fig. 709). Similar

FIG. 712

bone infection is shown around two old decayed roots of a lower molar in Fig. 710, as illustrated by a similar case in the upper jaw shown in Fig. 711. If the disease spreads it may result in a regular granulating

ostitis, as shown in Fig. 712, where the infection caused extensive bone destruction without giving symptoms or causing excessive suppuration.

The first reaction which occurs in the peridental membrane is

FIG. 713

FIG. 714

called proliferating periodontitis, which appears in the roentgen picture as a dark shadow of very moderate size. Fig. 713 shows a devitalized cuspid, with partial root-canal filling and a slight radiolu-

FIG. 715

FIG. 716

cent area at the very apex of the tooth. A proliferating periodontitis, but a slightly more extensive one, is seen in Fig. 714, where a cuspid with partial root-canal filling is involved. The dark area around

FIG. 717

FIG. 718

the apex is slightly larger. Figs. 715 and 716 show blind abscesses, or granulomata, of usual size, both on lateral incisors. There is a fine difference in the two pictures. Fig. 715 shows a blind abscess of the

granulating ostitis type, while Fig. 716 shows a granuloma which would develop into a periodontal cyst. The difference in the roentgenographic aspect of these conditions lies in the light outline of the dark area in Fig. 716, which is typical of cyst pictures (see paragraph on Periodontal Cysts). It is a common occurrence to find blind abscesses of larger size, such as that seen in Fig. 717 on two teeth. Note the gradual change from diseased to normal tissue. This is typical and indicates the spreading character of the disease. Fig. 718 shows a larger area still, which is usually spoken of as granulating ostitis. More extensive cases are described under a special heading on bone disease.

It should be noted that the roentgenogram does not show whether the periapical infection is of acute or chronic character. It shows loss of bone and, on account of the space where the bone has been destroyed being radiolucent, a dark area appears in the picture. The density of this area in the film depends upon various factors. If the abscess cavity is shallow and on the surface, or inside the jaw only, with massive cortical layers of bone on each side, as in the mandible, the radiability is but little affected. When, however, the cavity is large in proportion to the thickness of the bone, or with a large opening through the outer or inner wall of the bone, the radiability greatly increases, resulting in a well-defined dark picture. The contents of the abscess cavity affects the radiability very slightly; whether it is filled with liquid pus or inflammatory granulation tissue makes little difference. A large amount of cholesterin, however, may decrease the radiability, as the author had occasion to observe once or twice, when the abscess almost looked as if it had healed.

The fact that blind abscesses develop and exist without causing pain or giving other local symptoms of inflammation makes their discovery impossible without the use of the roentgen ray. Teeth with necrotic roots and extensive involvement of the surrounding bone often remain in the jaw of the unsuspecting individual, unrecognized by the dentist unless he makes careful roentgen examination of all the teeth.

The importance of recognizing such conditions is clearly proved if cultures are made from the pus-soaked tooth after its extraction, although its odor should be sufficient proof. It is today almost an offence of negligence to give an opinion as to the condition of a patient's mouth without first making a careful roentgen diagnosis.

Complications Caused by Periapical Infection.—When considering the frequent occurrence of these localized bone abscesses around the teeth it is surprising that one does not encounter more often a spreading of the infection to adjoining teeth, extensive involvement of the jaws

and adjoining cavities of the face. The reason for the infection remaining localized on one tooth is not easily explained, but one seldom gets involvement of the teeth on each side if they are perfectly normal. In Fig. 719, however, we see a devitalized lateral incisor with partial root-canal filling and periapical infection. The picture of the abscess cavity shows that it is connected also with the root of the central incisor, the root canal of which has never been opened. The patient, after being told of the condition, did not believe that it was of any consequence, as it had never given her any trouble. Nothing was done to either of the teeth. She came to the office two days later with well-marked symptoms of pulpitis in the central incisor. A similar case is shown in Fig. 720. The diseased pulp in the left central with a porcelain filling apparently attached with two platinum posts caused infection of the right central, which was otherwise entirely normal. Infection and pus discharge sometimes persists after extrac-

FIG. 719

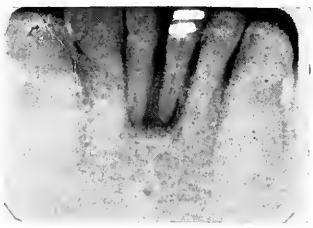

FIG. 720

tion of a tooth. This may be due to the fact that two teeth were involved. If, for example, treatment had been undertaken in the case shown in Fig. 719 without having a roentgen diagnosis made, probably only one tooth would have been extracted, the other giving no clinical symptoms. The abscess on the second tooth would, of course, have continued as long as the tooth was retained. Such a case is presented by a patient who had a lower second bicuspid extracted. Pus, however, continued to discharge through the alveolar socket where the tooth had been removed. The roentgen picture is shown in Fig. 721 and clearly discloses an abscess around the apex of the first bicuspid, with a definite channel to the place where the other tooth had come out.

Bone infection is, however, not always eliminated by simply extracting the tooth. This is shown in the next case. The patient said that the upper lateral incisor had been opened and the pulp removed

two years previous to examination. The root was perforated and finally extracted a year and eight months later. When seen by the author a boil had formed near the wing of the nose. The roentgenogram in Fig. 722 shows the condition. A bridge had been attached to the cuspid to replace the lateral incisor and in the bone is seen a dark area, which indicates the site of the original abscess cavity. When opening it from the labial side of the gum it was found to be filled with inflammatory granulation tissue, containing a slight amount of pus.

In another case the nasal cavity was involved. The patient had a swelling of the face and complained that for two days pus had discharged from her nose. The upper central incisor was very sore and a roentgen examination was resorted to for diagnosis of the condition. Fig. 723 shows the picture in which a dark area is seen over the central incisor. The tooth had a necrotic pulp, and after extracting it a probe could be passed into the nose through a fistula.

FIG. 721

FIG. 722

FIG. 723

Infection of the maxillary sinuses has already been dealt with at length under a separate heading. The importance of careful investigation of the teeth in sinus disease cannot be impressed too strongly.

Other more serious complications are seen by the oral surgeon in increasing numbers and quite frequently are entirely overlooked by the dentist, or are improperly diagnosed. Among these belong the various bone infections and periodontal cysts, which are also of infectious origin. Such diseases will be considered under a special heading.

Condition of the Tooth Apex.—Periapical infection, especially if it is of long standing, causes changes in the cementum of the tooth. Nutrition is usually disturbed, the cells of the apical part of the periodental membrane may become destroyed and the cementum, which is very porous and easily absorbes the products of inflammation, becomes pus-soaked. In this condition the tooth becomes an obnoxious foreign body, which nature tries to eliminate. Osteoclastic absorp-

tion starts on the surface of the cement, which then presents a roughened appearance. Marked indentations are formed and the cement, and later also the dentin, dissolves. The recognition of this condition in a roentgen picture is of greatest importance, because it indicates that only one kind of treatment is possible, either root resection or extraction. The apex, in such a state, is a dead piece of bone, and, like a sequestrum, has to be removed before healing can take place.

FIG. 724

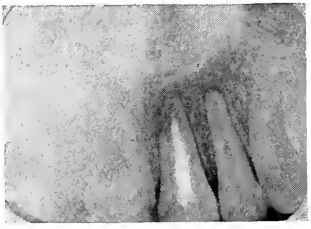

FIG. 725

There is no medicinal treatment which could restore such a tooth to its normal condition. If the periapical infection is of recent origin the outline of the root is usually well defined and clear in a roentgenogram, which shows that the cementum has not been attacked as yet. Fig. 715 illustrates such a case. When the cement becomes affected first an indistinct outline of the apex of the root only may be observable. Later we can see resorption of the root, due to osteoclasia. Fig. 724 shows a lateral incisor and a cuspid with periapical

FIG. 726

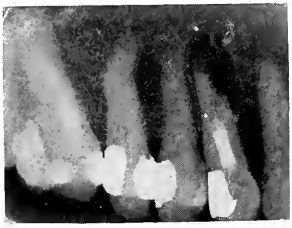

FIG. 727

infection. In both teeth resorption is clearly indicated at the root apex. In Fig. 725 a central incisor with partial root-canal filling is seen showing a peculiar dark area, indicating resorption at the side of the apex. Two upper bicuspids with decided loss of tissue at the apices are shown in Fig. 726. A similar case, in which the disease has become more extensive, is illustrated in the roentgenogram of a cuspid (Fig. 727). Careful study is necessary to detect resorption on

the mesial root of the first molar in Fig. 728. The distal root shows only a roughness, which may be hardly noticeable in the printed reproduction of the negative, on account of loss of detail, while a perfectly normal outline of the cement is seen on the roots of the twelve-year molar.

FIG. 728

FIG. 729

Hypercementosis in various stages may be found in connection with some of these infections, due to the stimulation of some cementoblasts, which have survived. Fig. 729 shows such a condition on the mesial root. Loss of tissue can be noticed at the very apex, but on both sides of the root end a decided enlargement has taken place. It is not necessary to mention that this makes extraction much more difficult.

Bone Repair Following the Treatment of Periapical Infections.—The roentgen picture not only serves to diagnose properly the extent of the involvement of the periapical tissues, that is, the bone and tooth root, but furnishes also a means of checking up the progress of bone repair no matter whether the treatment was medicinal, electrolytic or surgical. It should be remembered that bone formation is the only thing shown and that it takes from six months to a year for healing to be distinctly noticeable. One should not, however, be too optimistic when a change is found in the roentgen picture, as a temporary improvement may, for some time, decrease the extent of bone infection but does not necessarily imply a cure. It is also important to regulate the exposure and development so that the two pictures to be compared are about the same in these respects and the contrast, density and angle of exposure will be parallel in the two films. If healing is progressing properly bone bridges should be seen filling the cavity in a uniform manner.

Figs. 730 to 732 show a case in which root-canal treatment was started in December, 1916, under strictly aseptic care. Ionization was employed and the canal filled after the treatment was completed. Fig. 731 shows the root-canal filling and progress of healing after a period of three months. In December, 1919, a new film was taken.

This is shown in Fig. 732 and reveals definite resorption at the apex of the root, although the abscess area at the side of the tooth has healed.

FIG. 730

FIG. 731

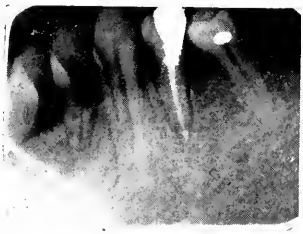

FIG. 732

FIG. 733

FIG. 734

FIG. 735

FIG. 736

Another case of periapical infection, on a lower second molar, is shown in Fig. 733. The pulp in this tooth had recently become infected. It was removed and the root canal treated from May 2 to May 15, 1919, and filled on May 23. The condition at that time is shown in Fig. 733. A new picture, taken March 1, 1920 (Fig. 734), records the healing as it had progressed up to that time.

After apicoectomy, or root resection, the healing process can also be checked up by the roentgen method. A film should be taken immediately after the operation for use later in comparison. Fig. 735 reproduces a roentgen picture taken just after such an operation. The apices of the two upper incisors were resected and the dark area in the bone around these roots represents the size of the cavity. Fig. 736 shows the same case after two years. The former abscess cavity had entirely filled in with bone.

Alveolar Infection.

Injury and infection of the gingivæ and the neck of a tooth causes an inflammatory condition which can easily be recognized in the mouth if careful examination be made. There are a great many causes for gingival inflammation, the chief one being traceable to poor dentistry in such work as fillings, poorly fitting crowns and lack of contact points between the teeth. Such dental shortcomings have already been discussed in the chapter on these subjects. The inflammation next spreads to the periodontal membrane and attacks the cervical part of the alveolar process. At this stage changes are visible in roentgenograms. At first an irregular outline is seen on the bone edge between the teeth; later when the disease spreads along the root of the tooth, more bone becomes absorbed, so that a pus pocket forms at the side of the tooth, progressing generally in a vertical direction. On account of the bone being replaced by inflammatory granulation tissue a picture of a pocket is clearly recorded in the roentgen film, and, as a rule, the cause is also discernible. Interradicular infection sometimes results from cervical infection of the alveolar process, the disease spreading to the alveolar septum between the roots of a multi-rooted tooth, often forming an abscess, which closely resembles clinically any of the stages of an acute alveolar abscess, due to disease of the dental pulp. The roentgen picture, therefore, is an important means of differential diagnosis. Fig. 737 shows a pocket on both the mesial and distal sides of the first bicuspid, caused by a poorly fitting gold crown. Fig. 738 reveals a large pocket between the second bicuspid and molar. The space between these two teeth was constantly filled with stagnant food. In Fig. 739 another

large pocket between two molars is shown. This condition was probably caused by lack of contact between the two teeth. Fig. 740 illustrates a case in which there was a pocket between the two molars

Fig. 737

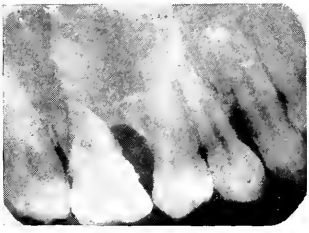

Fig. 738

Fig. 739

Fig. 740

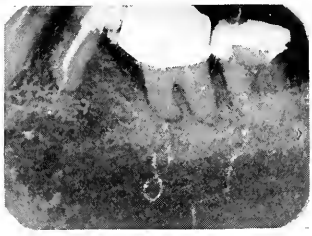

Fig. 741

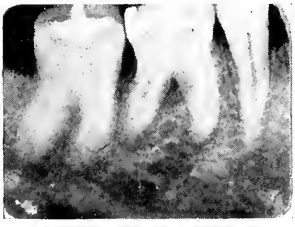

Fig. 742

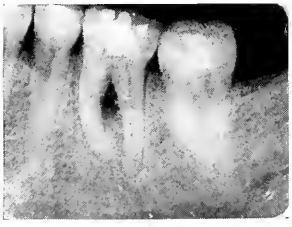

Fig. 743

in the lower jaw. The contour of the gold crown on the molar was not sufficiently built out to close the space. In Fig. 741 the cause of a pocket between a bicuspid and molar is seen to be due to an overhanging gold crown and also to some excess filling material which was left between the gold crown and the distal side of the bicuspid. In Fig. 742 an inter-radicular abscess appears on a lower molar. It was caused by a pus pocket and inflammation of the gum at the buccal side. Fig. 743 also shows an inter-radicular abscess. The dark area between the roots indicates the abscess, which has replaced the bone of the alveolar septum, and at the inner surface of the roots deposit of serumal calculus can be seen, which leads to the conclusion that the condition has existed for a considerable time.

Pyorrhea Alveolaris.—Pyorrhea alveolaris can be demonstrated roentgenographically just as soon as the bone becomes involved. If one roentgen picture of only part of the mouth is examined and an occasional pus pocket is found a diagnosis of pyorrhea should never be made, as this may be due to some local traumatic cause. It is necessary to have clinical confirmation of roentgen diagnosis of alveolar infection and pus pockets on most of the teeth, as pyorrhea is not a disease which confines itself to one part of the mouth. Roentgen evidence is especially valuable to show the extent of the disease and the amount of bony support which remains to hold the teeth firmly in place. In the early stages we see only an irregular outline at the alveolar margin, the compact part having been destroyed, so that the outline of the bone between the teeth is irregular and has a spongy appearance. Later the stratum durum, the cortical part of the alveolar socket, becomes dissolved and a wider space than is normally occupied by the peridental membrane can be seen between the tooth and bone. More and more of the bone is then destroyed and regular pockets form. In cases of very long standing we may find places where the entire alveolar socket has disappeared, leaving a funnel-shaped pocket, the alveolar bone between the teeth often being entirely destroyed, so that finally the teeth are only supported by the gum and consequently become extremely loose. At this stage a pulpitis usually sets in, sometimes causing an acute alveolar abscess. The cementum of the tooth not only becomes pus-soaked, but also is covered with scales of serumal calculus, which can easily be discerned in a good roentgen film. The roentgenogram reveals principally pockets at the sides of the teeth, and, while these may be extremely deep, there may be sufficient bone lingually and buccally to support the tooth, so that it appears very firm. On the other hand large pockets may exist at the labial and lingual surfaces when the roentgen picture shows normal bone at the mesial and distal sides.

The illustrations are all of one part of the mouth, showing various degrees of pyorrhea. The same condition could be demonstrated

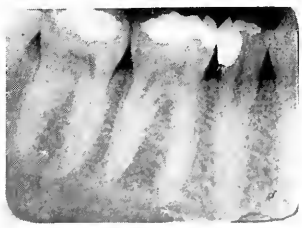

FIG. 744

FIG. 745

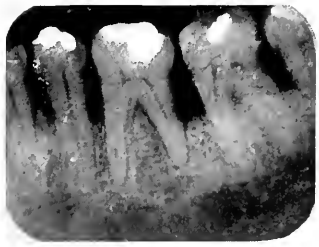

FIG. 746

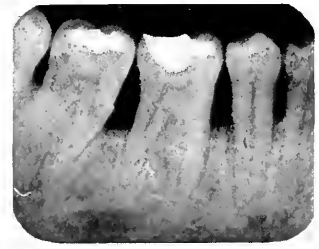

FIG. 747

FIG. 748

FIG. 749

FIG. 750

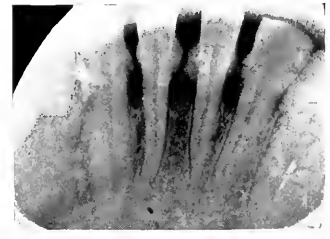

FIG. 751

on other teeth. Fig. 744 shows a case in which there was a perfectly normal condition of the alveolar process. Note the normal peridental

membrane, the stratum durum lining the alveolar sockets and continuing as a dense layer of bone at the alveolar margin between the teeth. Fig. 745 shows a case in which the bone has just started to become involved. Figs. 746 and 747 both show loss of bone between the teeth. The marginal part of the alveolar bone shows a spongy, irregular appearance, but no deep pockets have been formed. Figs. 748 and 749 are two cases in which the pockets have formed at the sides of the teeth, indicated by the dark, wedge-shaped spaces along the roots. Fig. 750 shows an extreme case in which extensive bone destruction has occurred around the mesial root of the first molar. The inter-radicular septum of the tooth has also been entirely lost. The pulp is probably infected and calcareous deposits are seen at the distal side of the first bicuspid and on the molar roots. Fig. 751 shows the lower incisors of a pyorrhea case, with large deposit of salivary calculus at the alveolar margin.

Bone Infection.

If we consider the frequency of dental infections it is surprising how rarely we find very extensive bone infection and serious involvement of the adjoining structures and the alveolar process. The reason for this is probably to be found in the bountiful blood supply of the bone in the immediate neighborhood of the roots of each tooth, from which a defensive system is built up to prevent the spreading of infection, carrying away the products of bacterial activity so successfully that there is but seldom an outlet or fistula formed to the face or gum. Peridental infections sometimes result in extensive lesions of the jaw, as well as radicular or periodontal cysts, which are also of the infectious type. It is a deplorable fact that they are generally not recognized for a long time and the general practitioner of dentistry often treats devitalized teeth associated with large bone infections for months by means of root-canal medication without making an accurate diagnosis, and, therefore, the jaws are frequently seriously involved when the patient finally consults a roentgenologist or oral surgeon. Every operator should be familiar with various types of bone infection and recognize them clinically and roentgenographically.

Diffuse Osteomyelitis.—Diffuse osteomyelitis of the jaws is, fortunately, a rare occurrence. The author has seen only five typical cases during the past five years. One, in the upper jaw, healed rapidly after the removal of several sequestra. The other four, occurring in the mandible, were much more serious. In one case there was spontaneous fracture at the angle of the jaw before the patient noticed

any diseased condition. In all of these cases the disease was very stubborn, new sequestra formed continually, involvement of formerly unaffected parts could not be prevented and with the best of care it took months for complete recovery.

FIG. 752

FIG. 753

For comparison, Fig. 752 shows the anterior part of an entirely normal upper jaw. Fig. 753 reveals a blind abscess, or granuloma, on a devitalized central incisor. In diffuse osteomyelitis we find roentgenographically, at first, a rarefied condition in the entire cancellous part

FIG. 754

FIG. 755

of the jaw. This is due to changes caused by infection in the marrow spaces. Figs. 754 and 760 show the typical appearance of the first stage of the disease. Later necrosis sets in, sequestra are formed, and, in the roentgen picture, channels are seen which can be compared with

the appearance of worm-eaten wood. Fig. 755 shows a case of osteomyelitis with bone necrosis in the upper jaw. The patient, a girl, aged nineteen years, complained that her mouth had been feeling sore for about eight months, although two teeth had been extracted and replaced by a bridge. The bridge was later taken off and the gum lanced without giving relief. When the patient was presented for consultation a roentgen picture was taken at once, which showed a typical case of osteomyelitis with bone necrosis. When operated upon a large sequestrum was found loose and removed with the left upper central incisor and first bicuspid attached to it. There were also two other bone sequestra found. The healing progressed quickly and without complication. Another case is shown in Fig. 761, the earlier stage of which appears in Fig. 760. The patient, Mrs.

FIG. 756

FIG. 757

L., had been in perfect health. On December 24, 1915, she had a tooth "capped" by her dentist. December 26 the tooth was extracted by another dentist on account of an abscess. December 28 the patient went to the hospital and received palliative treatment. On January 18, 1916, she complained of pain in the entire lower jaw, inability to open her mouth and soreness of the teeth. Temperature, 99.5° F. Examination revealed that the only teeth of the mandible present were the front ones from the left lower first molar to the right lower second bicuspid. All these teeth were extremely loose and there was evidence of the right lower first molar having recently been extracted. All the remaining upper teeth were firm and in good condition. At first the roentgen plates showed only a rarefied area extending from one side of the mandible to the other. Surgical

treatment was started at once and several sequestra removed. The disease spread as far as the angle of the jaw on the left side, when, on March 2, the roentgen picture showed the more advanced stage seen in Fig. 761.

Ostitis.—This is a bone infection of a more extensive type, developing often from periapical infections. It may be of the suppurative type, accompanied by violent acute symptoms, but more often is of a chronic character, developing from chronic periapical infection. This type is called granulating ostitis. It may involve large portions of the jaw and several teeth without causing much swelling or pain. A fistula is seldom formed, and when it does occur is due to an exacerbation causing more active pus formation. It may lead to the nose, the mouth, the outside of the face or the maxillary sinuses. The roentgen

FIG. 758

FIG. 759

picture shows an area of dark appearance, usually of irregular outline, with very indistinct margins, due to a gradual change from healthy to diseased tissue. Fig. 756 shows a case of granulating ostitis of large dimensions. Compare this picture with Figs. 752 to 759 and note the difference in the general appearance and outline.

Radicular or Periodontal Cysts.—The radicular cyst is of inflammatory, infectious origin and is developed from a blind abscess, or granuloma, a chronic inflammatory lesion which forms at the apex of an infected tooth. Epithelial rests, remnants from the enamel organ, are frequently found in the normal peridental membrane and, through irritating influences, such as those exerted by chronic inflammation, these are caused to proliferate, forming chains of epithelium which grow like a network through the lesion. Having a tendency

to grow between vital and necrosed tissue the epithelium soon forms an entire lining of the abscess cavity. Accumulation of broken-down tissue and exudates causes extension of the cyst. It often grows to tremendous size at the expense of the bone, which disappears through pressure absorption. The bone may become so thin that a cracking sound can easily be heard on palpation. In the upper jaw cysts may encroach on the nasal cavity or develop inside the maxillary sinus, sometimes filling it almost completely, a condition which is very difficult to diagnose. In the lower jaw they are found in the body of the mandible as well as in the ramus. Radicular cysts sometimes have apparently no connection with a tooth root. In such cases the

FIG. 760

guilty tooth may have been extracted, the cyst having escaped notice at the time, or there may have been left in the jaw an epitheliated granuloma, which developed into a cyst later.

Just how long cysts remain unnoticed depends a great deal on their location and rapidity of growth and upon accidental changes in the pathologic development. Symptoms may appear as changes in the facial contour, such as swellings on the cheek or side of the mandible, on the hard palate or under the lip. Distention of the cyst is often evidenced by indefinable obscure pressure and occasionally causes displacement of some of the teeth. Pain is extremely rare, but in two cases I have seen complete paresthesia of the lower lip, due to

FIG. 761

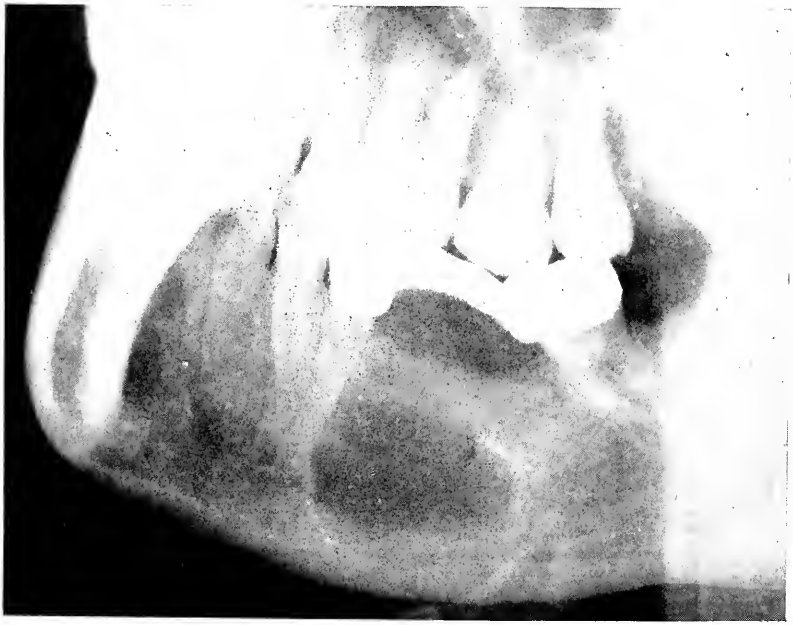

FIG. 762

involvement of the inferior alveolar nerve. A cyst with an opening into the mouth is noticed by the discharge of its excretion, which causes a bad taste and a disagreeable odor in the mouth. Secondary infection, which occurs through the diseased pulp canal or pus pocket of an adjacent tooth frequently causes symptoms of acute or subacute dental abscesses and, subsiding, may leave a fistula on the gum, which often leads to faulty treatment.

The diagnosis of a cyst is easily made by means of the roentgen ray. The roentgen examination should be made on large films or plates, as the small ones seldom cover more than part of the lesion. The cyst cavity appears as a black area on the negative, because it decreases the resistance which in normal bone conditions is put in the way of the rays. The bone immediately surrounding the cavity, however, is usually cortical and dense and so we find the typical picture of a cyst showing a light, but distinct, surrounding line, well illustrated in Figs. 758, 759 and 762. In case of cysts the roentgen picture is also an aid in making a differential diagnosis as well as to give exact information regarding the shape, size and location of the lesion. It shows its relation to important neighboring structures, such as the inferior alveolar nerve, the maxillary sinus and the nose. It will show the number of teeth involved and be a valuable guide for the operative technic.

INDEX.

A

Abnormal dentition, diagnosis of, 705
Abscess, pericemental, 573
Alloys for amalgam *See* Amalgam.
for plates and solders. *See* Gold.
of gold, 347–349
Alveolectomy, external, 642
modified, 643
Amalgam, 349
annealing of, 363
buying of, 377
chemical relations of, 375
classes of, 353–354
classification of, 377
composition of, 352–360, 361
contraction of, 356–363
copper, 375
expansion of, 356–363, 365
fillings of, 241
flow of, 372
keeping of, 377
manipulation of, 379–386
nature of, 349
pluggers for, 245
preparation of cavity for, 241
properties of, 349
strength of, 355, 366
thermal relations of, 375
washing of, 374
Anatomy, surgical, 588, 589
of teeth, 24–39
Anemia, 502
Anesthesia for dentin, 522
injection for, 514
at incisive foramen, 518
at infra-orbital foramen, 516
at mandibular foramen, 519
at maxillary tuberosity, 517
at mental foramen, 521
at posterior palatine foramen, 518
subperiosteal, 514
local, 498
agents for, 503–510
areas anesthetized, 517–526
armamentarium for, 510
conduction, 499–514
for operations other than extractions and pulp removal, 524
history of, 498
Anesthesia, local, means of producing, 499
physiologic action of, 500
places for injection, 517–526
for pulps of teeth, 521
technic of, 514
terminal, 499–514
for pulp, 521–524
injections for, 521
Anesthetics for sensitive dentin, 463
Angina, Vincent's, 575
Annealing of alloys, 363
of gold, 343
Antisepsis in root-canal operations, 442
Antiseptic cements. *See* Copper oxyphosphates.
Antiseptics, 177
Apical foramen, filling of, 445
Apicoectomy, 646
indications and contra-indications for, 646
technic of, 649
Arches, dental, relationships of, 55–57
shapes of, 53
Arthritis, 125
Articulation of teeth, 23
Atmospheric pressure, occlusion of teeth and, 667
Atrophy, senile, 580
of teeth, 23
Attachments for bridges, 284–298
Auto-intoxication, 551

B

Bacteria, 547
Bicuspids, canals of, 444
extraction of, 596, 603
Bleaching of teeth, 473
cataphoresis in, 490
chlorine in, 475
dioxid of hydrogen in, 475
of sodium in, 475
Harlan's method of, 487
iodine in, 475
light in, 493
McQuillan's method of, 487
sulfur dioxid in, 475
Truman's method of, 480
Bloodvessels of peridental membrane, 117
of pulp, 92–93

Bridge attachments, 284–298
preparation of cavities for, 284–298
Brushes, tooth, 171
how to use, 173–174
Burnishers, 316, 317, 319
Burs, 183
fissure, 183
inverted cones, 183
round, 183
tapered, 183

C

Calcification of teeth. *See* Anatomy of.
Calculi, 153–154, 545
diagnosis of, 678
Canals, root, preparation and filling of, 431–453
treatment of, 411
Canines, anatomy of deciduous series, 54
of permanent series, 28, 42
Caries, diagnosis of, 717
prevention of, 134
susceptibility to, 188
Casting of gold inlays, 278–281
Cataphoresis in bleaching of teeth, 490
Cavities, classification of, 196
class I, preparation and filling of, 198
II, preparation and filling of, 204
III, preparation and filling of, 210
IV, preparation and filling of, 213
V, preparation and filling of, 217
filling of, 164.
preparation of, instruments for, 182
for porcelain inlays, instruments for, 300
system of, 187
for amalgam, 241
for bridge attachments, 284–298
for cements, 252
for gold foil, 187–218
inlays, 261–284
for gutta percha, 249
for porcelain inlays, 299
tapered, 284–298
Cell activity, occlusion of teeth and, 664
Cement, fillings of, 252
Cementation of gold inlays, 282
of porcelain inlays, 334–338
Cementoblasts, 106
Cements 386
copper oxyphosphates, 390
germicidal. *See* Copper oxyphosphates.
mixing of, 400
preparation of cavities for, 252
Cements, properties of, 386, 396–400
silicate, 252, 254, 338, 395
silver. *See* Copper oxyphosphates.
zinc oxyphosphates, 387–388
Cementum, exostosis of, 98
formation of, 96
function of, 95
hypertrophies of, 98
nature of, 95
structure of, 96–97
Charts, roentgenogram, 495
Chemicals for root-canal treatment, 411-414
Children's teeth, filling of, 255–312
Chlorapercha, 449
Chlorine in bleaching of teeth, 475
use of, in root canals, 416
Clamps, rubber dam, 187–217
Cocaine, 506
Concretions, removal of, 153
Conduction anesthesia, 499–514
Conductivity of gold, 346
Contact, proximate, 165
Contours, 165
Contraction of amalgam, 356–363
Copper amalgam, 375
oxyphosphates, 390
liquid portion *See* Zinc oxyphosphates.
powder portion, 390
Cresol-formalin, use of, in root canals, 415
Cuspids, canals of, 444
extraction of, 595, 603
Cysts, diagnosis of, 713–756

D

Deciduous teeth, 23, 54
extraction of, 606
filling of, 255
Deglutition, occlusion of teeth and, 666
Dental floss, 175
Dentifrices, 175
Dentin, 81
anesthesia for, 522
composition of, 81
derivation of, 81
granular layer of Tomes, 85, 88, 89, 97
hypersensitive, 454
pathology of, 454
symptoms of, 458
treatment of, 458
innervation of, 454
interglobular spaces of, 86
junction of, with enamel, 86
matrix of, 82
structural elements of, 82
tubuli of, 82–91
direction of, 84
Dentistry, operative, description of, 179
preventive, description of, 122–127

Dentition, abnormal, diagnosis of, 705
Devitalized teeth, 698
retention of, 699
Diabetes mellitus, 550
Diagnosis. *See* Roentgen diagnosis.
Dichloramin-T, use of, in root canals, 416
Diets, 141
Dioxid of hydrogen in bleaching of teeth, 475
of sodium in bleaching of teeth, 475
Disclosing solution, 161
Discoloration of teeth, 467
causes of, 467
rationale of process, 469
special, 495
treatment of, 467
which can be removed, 473
Ductility of gold, 341

E

Electrolysis, use of, in root canals, 419-422
Enamel margins, 195
of teeth, 63
cementing substance of, 65
cleavage of, 69
composition of, 64
derivation of, 63
incremental lines of, 74
rods of, 65
direction of, 72, 194
stratification bands of, 73
strength of, requirements for, 75
structural element of, 65
Endocarditis, 125
Endosmosis, electric, for sensitive dentin, 464
Ethyl chlorid, 503
Eucapercha, 261
Exostosis, 98
Expansion of amalgam, 356–363, 365
of gold, 344
Expression, occlusion of teeth and, 667
Extension for prevention, 137, 188
Extirpation of pulps of teeth, 723
Extraction of teeth, 588–642
accidents during, 621
bicuspids, 596, 603
contra-indications for, 591
cuspids, 595, 603
deciduous, 606
hemorrhage following, 626
impacted, 630, 637
incisors, 593, 594, 602
indications for, 591
instruments for, 608–641
management of patient for, 592
molars, 598–600, 604, 637
pathology involved in, 634
post-operative pains in, 629
treatment in, 628–640
pre-operative treatment in, 628
Extraction of teeth, roots, 607
supernumerary, 607
unerupted, 630, 637

F

Files for finishing, 238
Filling of apical foramen, 445
materials, properties of, 339
of pulp chambers, zinc oxychlorid for, 482
of root canals, 431–453
Fillings of amalgam, 241
of cement, 252
finishing of, 237
of gold, 218
of gutta-percha, 249
of inlays, 261–299
radiolucency of, 719
Films, 160
for roentgenograms, 679–683
development of, 684
Finishing fillings, 237
files for, 238
of gold inlays, 281
knives for, 238
saw for, 238
strips for, 240
Fissure burs, 183
Floss, dental, 175
Forms of teeth, diversities in, 22
Formula for alloys for amalgam. *See* Amalgam.
for plates and solders. *See* Gold.
Furnaces, 329
Fusing of porcelain inlays, 317–326

G

Germicidal cements. *See* Copper oxyphosphates.
Gingivitis, ulcerative, 582
Glycogen in saliva, 140
Gold, 339
alloys of, 347–349
conductivity of, 346
ductility of, 341
expansion of, 344
fillings of, 218
foil, preparations of cavities for, 187–218
hardness of, 342
inlays, 261
as bridge attachments, 284–298
casting of, 278–281
cavities for, 262–270
conflicting opinions concerning, 284–298
preparation of, 261–284
cementation of, 282
finishing of, 281
gold for, 289

Gold inlays, indirect method for, 283–321, 323
pattern for, 271
investing of, 274
removal of, 277
malleability of, 342
melting-point of, 340
oxidation of, 346
pluggers for, 231–233
preparation of, for fillings, 218
properties of, 339
solubility of, 346
specific gravity of, 340
tensile strength of, 344
volatility of, 341
Granular layer of Tomes, 85, 88, 89, 97
Gums, retraction of, 579
Gutta-percha, 401, 449
employment of, 404
fillings of, 249
preparation of cavities for, 249
properties of, 401, 403
radiolucency of, 719
with other materials, 410

H

Hardness of gold, 342
Harlan's method of bleaching teeth, 487
Haversian canals, 117
Hemorrhage following extraction of teeth, 626
High-pressure syringes, 523
Histology of teeth, 59
Hunter's "Anathematization of American Dentistry," 123
Hygiene movement, oral, 138
Hypersensitive dentin, 454
pathology of, 454
symptoms of, 458
treatment of, 458
Hypertrophy, 98
Hypodermic syringes, 511, 512

I

Impacted teeth, diagnosis of, 710
extraction of, 630, 637
Incisive foramen, injection at, for anesthesia, 518
Incisors, anatomy of deciduous series, 54
of permanent series, 24, 39
canals of, 444
extraction of, 593, 594, 602
Infection, diagnosis of, 137, 743, 749
Infra-orbital foramen, injection at, for anesthesia, 516
Injection for anesthesia, 514
at infra-orbital foramen, 516
at incisive foramen, 518
at mandibular foramen, 519
at maxillary tuberosity, 517
Injection for anesthesia at mental foramen, 521
for other operations than extractions and pulp removal, 524
at posterior palatine foramen, 518
of pulp, 521
subperiosteal, 514
Inlays, fillings of, 261, 299
gold, 261
as bridge attachments, 284–298
casting of, 278–281
cavities for, 262–270
conflicting opinions concerning, 284–298
cementation of, 282
finishing of, 281
gold for, 289
indirect method for, 283, 321–323
pattern for, 271
investing of, 274
removal of, 277
porcelain, 299
cavities for, 299–314, 336
preparation of, instruments for, 300
cementation of, 334–338
colors of, 332
furnaces for, 329
fusing of, 317–326
indirect method for, 321
matrix for, 314–323
shading of, 333
Instruments for cavity preparation, 182
chisels, 182
hatchets, 182
hoes, 182
trimmers, marginal, 182
for extraction of teeth, 608–641
for fillings, 231, 233, 245
for finishing fillings 237–258
plastic, 250
sharpening of, 184
sterilization of, 431, 511, 514
Intestinal intoxication, 552
Intoxication, auto-, 551
intestinal, 552
Iodine in bleaching of teeth, 474

K

Knives for finishing, 238

L

Light in bleaching of teeth, 493
Local anesthesia, 498. *See* Anesthesia, local.
Lymphatic system of teeth, 58
Lymphatics of peridental membrane, 119
of pulp, 92–93

M

McQuillan's method of bleaching teeth, 487
Malleability of gold, 342
Mal-occlusion of teeth, 668
etiology of, 668
treatment for, 670
appliances and technic for 673
retention, 674
time of, 670
Mandibular foramen, injection at, for anesthesia, 519
Mastication, occlusion of teeth and, 666
Matrix, use of, 242–248
Maxillary sinuses, diseases of, diagnosis of, 701
tuberosity, injection at, for anesthesia, 517
Melting-point of gold, 340
Mental foramen, injection at, for anesthesia, 521
Mercury, 380
Mixing cements, 400
Molars, anatomy of deciduous series, 54
of permanent series, 34, 46
canals of, 444
extraction of, 598–600, 604, 637
Morphology of teeth, 21
Muscular action, occlusion of teeth and, 665
Myocarditis, 125

N

Necrosis, diagnosis of, 731
Nerve tissue of peridental membrane, 117–120
Nervous system of teeth, 57
Neuralgia, diagnosis of, 703
Nitro-hydrochloric acid, use of, in root canals, 413
Novocaine, 509

O

Occlusion of teeth, 653
development of, 655–656
forces governing, 663
atmospheric pressure, 667
attention and muscular tone, 667
cell activity, 664
deglutition, 666
expression, 667
mastication, 666
muscular action, 665
respiration, 666
nomenclature and classification, 668
normal, 654
Occlusion of teeth, traumatic, 544
Odontoblasts, 89–90. *See* also Teeth.
Operative dentistry, description of, 179
Oral hygiene movement, 138
prophylaxis, 139–151
sepsis, 127
Orthodontia, principles of, 653. *See* also Occlusion.
Osteoclasts, 109
Osteomyelitis, diagnosis of, 753
Ostitis, diagnosis of, 756
Oxidation of gold, 346
Oxyphosphates of copper, 390
liquid portion, 387
powder portion, 390
of zinc, 387–388
liquid portion, 387
powder portion, 388–389

P

Pain, cause of, 456
post-operative, 629
Palatine foramen, posterior, injection at, for anesthesia, 518
Paste polisher, 162
Patient, instructions to, 170
Pericemental abscess, 573
Pericementum, 98
Peridental affections, 133
membrane, 98
arrangement of, 99–103
bloodvessels of, 117
cellular elements of, 105
cementoblasts of, 106
changes in , with age, 121
epithelial structure of, 112–115
functions of, 98
giant cells of, 98
lymphatics of, 119
nerves of, 117–120
osteoclasts of, 109
structural elements of, 98
Permanent teeth, 23, 24
Pigments, source of, 467
Planing instruments, 159
Plaques, 160
Pluggers for amalgam, 245
for gold, 231–233
Pneumococci, 125, 669
Pockets, pyorrheal, 169
Poisons, systemic, 550
Polishing cups, 162
teeth and fillings, 161
Porcelain inlays, 299
cavities for, 299–314, 336
preparation of, 299
instruments for, 300
cementation of, 334–338
colors of, 332
furnaces for, 329
fusing of, 317–326
indirect method for, 321

Porcelain inlays, matrix for, 314–323
shading of, 333
Potassium sodium, use of, in root canals, 412
Preventive dentistry, description of, 122, 127
Prophylaxis, oral, 139–151
Pulp, anesthesia for, 521–524
canals, disease of, diagnosis of, 727, 730, 731
cavities of teeth, 52, 53
chambers, filling of, zinc oxychlorid for, 482
of teeth, bloodvessels of, 92–93
derivation of, 89
enervation of, 94
extirpation of, 723
function of, 94
layer of Weil of, 92
lymphatics of, 92–93
membrana eboris of, 89
nerve tissue of, 94
odontoblasts of, 89, 90
structure of, 89
sensory, 95
Pus, 559
Pyorrhea alveolaris, 527
cause of, 534–542
definition of term, 527
diagnosis of, 554, 751
general principles of, 537
healed lesions of, 582
history of, 527–534
operative procedures for, 536
prevention of, 149
pockets of, 169
treatment of, 561

R

Radiolucency of fillings, 719
of gutta-percha, 719
Records for root-canal work, 451
Respiration, occlusion of teeth and, 666
Retraction of gums, 579
Roentgen diagnosis, 675
in abnormal dentition, 705
of abscesses or granulomata, 740
of bone repair, 747
of caries, 717
of cysts, 713–756
in diseases of maxillary sinuses, 701
of pulp canals, 727, 730, 731
for impacted and unerupted teeth, 710
nomenclature of, 675
of osteomyelitis, 753
of ostitis, 756
of pulps of teeth, 723–727
of pyorrhea alveolaris, 751
in root canal fillings, 736
in somatic disease, 698
Roentgen diagnosis for supernumerary teeth, 712
for trifacial neuralgia, 703
Roentgenogram, 675
angle of rays, 679
exposure for, 683
development of films, 684
interpretation of, 688
mounting of, 695
production of rays, 676
recording of, 695
tubes for, 677
use of, in root-canal work, 446
Roentgenology, 675
Root canals, 431
preparation and filling, 431–453
equipment for, 431–442
treatment of, 411
chemical, 411
electric, 419–430
therapeutic, 414
fillings, making of. *See* Root canals.
removal of, 451
Roots of teeth, arrangement of, 52, 53
extraction of, 607
Round burs, 183
Rubber dam, application of, 185, 443
clamps, 187, 217

S

Saliva, glycogen in, 140
sulphocyanate in, 140
Saw for finishing, 238
Scalers, 156, 157, 158
Sedatives for sensitive dentin, 463
Senile atrophy, 580
Separators, 210
Sepsis, oral, 127
Shading of inlays, 333
Silicate cements, 395
Silver cements. *See* Copper oxyphosphates.
Solubility of gold, 346
Specific gravity of gold, 340
Stains, 160
Staphylococci, 125, 669
Sterilization of instruments, 431, 511–514
of root canals, 411, 414, 427
Streptococci, 125
Stresses, amount of, in mastication, 180
relief of, 168
Subperiosteal injection for anesthesia, 514
Sulci, protection of, 170
Sulfur dioxid in bleaching of teeth, 475
Sulphocyanate in saliva, 140
Sulphuric acid, use of, in root canals, 413
Supernumerary teeth, diagnosis of, 712
extraction of, 607
Suprarenal capsule, 504
Surgeon's knot, 187
Surgery, 558
extraction of teeth, 558–642

Surgery, other surgical procedures, 642–652
Syringes, high-pressure, 523
hypodermic, 511, 512

T

Tapered burs, 183
Teeth, 17
anatomy of deciduous, 54
calcification of, 55
canines, 54
incisors, 54
molars, first, 54
second, 54
occlusal surfaces of, 55
permanent, mandibular, 39
canines, 42
incisors, first, 43
second, 45
molars, first, 46
second, 49
third, 50
premolars, first, 43
second, 45
maxillary, 24
canines, 28
incisors, first, 24
second, 26
molars, first, 34
second, 36
third, 38
premolars, first, 30
second, 32
arches of, dental, shape of, 53
articulation of, 23
atrophy of, with age, 23
bleaching of, 473
cataphoresis in, 490
chlorine in, 475
dioxid of hydrogen in, 475
of sodium in, 475
Harlan's method of, 487
iodine in, 475
McQuillan's method of, 487
sulfur dioxid in, 475
Truman's method of, 480
calcification of. *See* Anatomy of.
canines, 19
mandibular, 19
maxillary, 19
cementum of, exostosis of, 98
formation of, 96
function of, 95
hypertrophies of, 98
nature of, 95
structure of, 96–97
dentin of, composition of, 81
granular layer of Tomes, 85, 88, 89, 97
interglobular spaces of, 86
junction of, with enamel, 86
matrix of, 82
Teeth, dentin of, structural elements of, 82
tubuli of, 82–91
direction of, 84
devitalized, 698
retention of, 699
discoloration of, 467
causes of, 467
rationale of process, 469
special, 495
treatment of, 467
which can be removed, 473
diversities in shape of, 22
enamel of, cementing substance of, 65
cleavage of, 69
composition of, 64
derivation of, 63
incremental lines of, 74
rods of, 65
direction of, 72
stratification bands of, 73
strength of, requirements for, 75
structural elements of, 65
extraction of, 588–642
accidents during, 621
bicuspids, 596, 603
contra-indications for, 591
cuspids, 595, 603
deciduous, 606
hemorrhage following, 626
impacted, 630, 637
incisors, 593, 594, 602
indications for, 589
instruments for, 608–641
management of patient for, 592
molars, 598–600, 604, 637
pathology involved in, 634
post-operative pains in, 629
treatment in, 628, 640
pre-operative treatment in, 628
roots, 607
supernumerary, 607
unerupted, 630, 637
genesis of, 59
histology of, 59
impacted, diagnosis of, 710
extraction of, 630, 637
incisors, first and second, 18
central and lateral, 18
mandibular, 18
maxillary, 18
lymphatic system of, 58
mal-occlusion of, 668
etiology of, 668
treatment of, 670
appliances and technic for, 673
retention, 674
time of, 670
mammalian formula of, 20
molars, first, second, third, 20
deciduous, 20
permanent, 20

Teeth, morphology of, 21
nervous system of, 57
occlusion of, 653
classification of, 668
development of, 655
forces governing, 663
atmospheric pressure, 667
attention, 667
cell activity, 664
deglutition, 666
expression, 667
mastication, 666
muscular action, 665
tone, 667
respiration, 666
nomenclature of, 668
normal, 654
peridental membrane of, 98
arrangement of, 99–103
bloodvessels of, 117
cellular elements of, 105
cementoblasts of, 106
changes in, with age, 121
epithelial structures of, 112–115
functions of, 98
giant cells of, 98
lymphatics of, 119
nerves of, 117–120
osteoclasts of, 109
structural elements of, 98
premolars, first and second, 19
known as bicuspids, 19
mandibular, 20
pulp of, bloodvessels of, 92–93
cavities of, 52–53
enervation of, 94
extirpation of, 723
function of, 94
sensory, 95
layer of Weil of, 92
lymphatics of, 92–93
membrana eboris of, 89
nerve tissue of, 94
odontoblasts of, 89, 90
structure of, 89
roots of, arrangement of, 52–53
succession of, 23
deciduous or milk, 23
permanent, 23
Teeth, supernumerary, diagnosis of, 712
extraction of, 607
types of, 166
unerupted, diagnosis of, 710
extraction of, 630, 637
vascular system of, 57
Tensile strength of gold, 344
Terminal anesthesia, 499–514
Therapeutics of root-canal treatment, 414
Tomes, granular layer of, 85, 88, 89, 97
Tooth brushes, 171
how to use, 173–174
Traumatic occlusion, 544
Traumatism, 580–543
diagnosis of, 716
Trifacial analysis, diagnosis of, 703
Truman's method of bleaching teeth, 480
Tubuli of dentin, 82, 91. *See* also Teeth.

U

Ulcerative gingivitis, 582
Unerupted teeth, diagnosis of, 710
extraction of, 630, 637

V

Vascular system of teeth, 57
Vincent's angina, 575
Volatility of gold, 341

W

Wadelstaedt tie, 187

X

X-rays. *See* Roentgenogram.

Z

Zinc oxychlorid for filling pulp chambers, 482
oxyphosphates, 387–388
liquid portion, 387
powder portion, 388–389

DATE DUE

SEP - 8 1998		SEP 2 9 1998	

Demco, Inc. 38-293

COLUMBIA UNIVERSITY LIBRARIES (hsl.stx)
RK 501 W21 1920 C.1
The American text-book of operative dent
2002399296

W21
1920

ward

text book of operative